

Sutureless Glueless Conjunctival Autograft for Primary Pterygium Surgery

Abd Allah Alhousseiny Abdel Gawad, Riad Alzaher Hassan, Ahmed Mostafa Ismail*

Department of Ophthalmology, Faculty of Medicine, Al-Azhar University, Damietta, Egypt

* Corresponding author: Ahmed Mostafa Ismail, Mobile: (+20) 01010000204, E-mail: optic.chiasma@yahoo.com

ABSTRACT

Background: Pterygium is a fibrovascular growth of an abnormal conjunctival tissue that progressively encroaches the limbus and then onto the cornea invading its superficial layers. It is a common ophthalmic condition seen mostly in dry, dusty areas.

Objective: The aim of the current study was to evaluate the sutureless glueless conjunctival autograft for primary pterygium surgery as regard technique, complications and success rate.

Patients and methods: This prospective study included a total of 30 patients with primary nasal pterygium, attending at Outpatient Clinic of Ophthalmology Department, Al-Azhar University, Damietta. This study was conducted between March 2017 to March 2018. **Results:** When comparing post-operative values at the end of third month with the first month we have found no difference in corneal state for all patients. The patient with corneal opacity was as the first month and had no difference in corneal state or BCVA. We detected one patient (3.3%) having recurrent pterygium. Finally when comparing post-operative values at the sixth month with the third month, we have found another patient who was reported with recurrent pterygium. Thus, the recurrence rate was 2 patients (6.7%) among all studied patients and the other values were approximately the same.

Conclusion: This study suggests that sutureless glueless conjunctival autograft technique is a safe, simple, easy of performance, has less surgical time and very effective for the management of primary pterygium.

Keywords: Sutureless Glueless Conjunctival Autograft, Pterygium.

INTRODUCTION

Pterygium occurs predominantly on the nasal limbus, although temporal pterygium rarely occurs in isolation. Double-head pterygium, that is nasal and temporal pterygia in the same eye is rare. In studies by Dolezalová, the incidence was found to be (2.5%)⁽¹⁾.

Histologically, pterygium is characterized by centripetal growth of a leading edge of altered limbal epithelial cells followed by a squamous metaplastic epithelium with goblet cell hyperplasia and an underlying stroma of activated, proliferating fibroblasts; neovascularization; inflammatory cells; and extracellular matrix (ECM) remodeling⁽²⁾.

It is thought to be caused by increased light exposure, dust, dryness, heat and wind. Although it can be easily excised, it has a high rate of recurrence ranging from (24% to 89%)⁽³⁾.

Recently, with the popularity of conjunctival autograft and use of antimetabolites such as mitomycin C and 5-Fluorouracil the incidence of recurrence has been greatly reduced up to (12%)⁽⁴⁾.

UV light may produce damage to the cellular DNA, RNA, and extracellular matrix and may induce expression of cytokines and growth factors important in the development of pterygium⁽⁵⁾.

It was described that the pterygium was associated with human papilloma virus (HPV) with the predisposing factor as dry heat and it also behaves as a neoplasm revealed by the presence of 8-hydroxydeoxyguanosine in the pterygial tissue that suggested the role of oxidative stress as a key factor in its causation⁽⁶⁾.

The active processes unleashed include inflammation, tissue invasion and degradation, angiogenesis, fibrosis, proliferation and apoptosis with

involvement of matrix metalloproteinases (MMPs), cytokines, and growth factors (GFs). The presence of an inflammatory mass on the ocular surface may predispose the patient to a "pseudo-dry eye syndrome"⁽⁷⁾.

Conjunctival autografting after pterygium excision seems to be the best method, giving both long-term safety and effectiveness in reducing the recurrence rate (2% – 39%)⁽⁸⁾.

The conjunctival autograft is attached with sutures, which may be associated with complicated surgical techniques, prolonged operating time, prolonged postoperative patient discomfort, and suture-related complications⁽⁹⁾.

Scanty data exists evaluating success of sutureless and glue free limbal conjunctival autograft for the management of primary pterygium⁽¹⁰⁾. The results were very encouraging as they suggested that sutureless and glue free limbal conjunctival autografting following pterygium excision is a simple, safe, effective, without much complications and economical option for the management of primary pterygium⁽⁹⁾.

The aim of the current study was to evaluate the sutureless glueless conjunctival autograft for primary pterygium surgery as regard technique, complications and success rate.

PATIENTS AND METHODS

This prospective study included a total of 30 patients with primary nasal pterygium, attending at Outpatient Clinic of Ophthalmology Department, Al-Azhar University, Damietta.

Ethical approval:

Written informed consent from all the subjects were obtained. This study was conducted between March

2017 to March 2018. **Approval of the ethical committee was obtained.**

Preoperative evaluation:

- 1- **History taking:**
 - A. onset, course and duration of pterygium formation progression.
 - B. History of any ocular trauma, ocular surgery, systemic disorder and drug intake.
- 2- **General examination:** Review for systemic diseases as diabetes mellitus, hypertension, bleeding tendency and liver diseases.
- 3- **Laboratory investigation:** Complete blood count (CBC), coagulation profile (CP), fasting plasma glucose, 2 hours postprandial blood glucose (PPG), liver and kidney function tests.
- 4- **Preoperative ophthalmological examination:** All patients underwent complete ophthalmic examinations including:
 - A. Uncorrected visual acuity (UCVA) and best corrected visual acuity (BCVA), were evaluated by Landot C optotype using Snellen's chart.
 - B. Refraction using Nidek automated refractometer.
 - C. Slit lamp examination to assess corneal clarity and pterygium grade.
 - D. Intraocular pressure (IOP) by Goldman Applanation tonometer.
 - E. Fundus examination: slit lamp biomicroscopy using non-contact Volk 90 Diopter lens.
 - F. Assessment of ocular motility in all directions of gaze.
 - G. Examination of ocular adnexa.
 - H. Digital anterior segment photography.

Surgical Technique:

In the holding area topical anesthetic drops are started. We had used (Tetracaine 0.5%) one drop to the designated eye. This gave the patient a chance to compare the sensation or lack of sensation between the two eyes. At the operating table the affected eye was cleaned and draped, and a second dose of topical anesthetic is instilled. This second dose is with (Xylocaine gel 4%) which is considerably stronger and excellent for advancing anesthesia to the conjunctiva and the site of peribulbar anesthesia injection prior to the injection of Carbocaine.

The syringe with 5 cc of Carbocaine 2% was brought slowly from the side, to minimize visibility by the operated eye. Then we injected Carbocaine peribulbarly by using 25-gauge needle which was slipped gently at infra orbital notch then pressing over the eye till complete akinesia was performed.

The upper face was prepped with Povidine Iodine 5% solution and the designated eye draped. Care was taken to ensure adequate breathing space under the drape as there was no assisted oxygen provided in the office setting.

All surgeries were performed by one surgeon, firstly the wire speculum was applied over operated eye. The lid speculum was then inserted and the remainder. Also, ocular sterilization with a drop of Povidine Iodine 5% was used.

The initial incision was made into the body at a point (2-4 mm) distal to the limbus which would generally involve most of the pterygium, then the body of pterygium was totally dissected in retrograde manner including conjunctiva and Tenon's capsule till reached the limbus.

Excision of the head after the incision into the body then removal only the affected tissue with the affected corneal part by using Colibri forceps in *continuous circular technique*.

We Measured the scleral area to be covered by caliber. When the area to be covered is less in size, the more successful the graft would be.

Then curettage was applied over sclera and excised corneal parts by using blade 15 or crescent blade till the sclera became avoided of conjunctiva and Tenon's capsule and the cornea became completely clear (**B**).

Harvesting the free graft done from the superior aspect of the conjunctiva. We used blunt dissection to avoid buttonholing the graft after marking the size of the graft.

The graft was excised from the upper bulbar conjunctiva by scissor through removing of conjunctiva and leaving Tenon's capsule after measured it later to measure of excised part and adding 1 mm over excised part.

The last part of graft to be removed was the limbal part by blade 15 or crescent blade. Then the scissor till removed totally (**B**).

Positioning the free graft done without it losing contact with the host surface. It is imperative to lay it flat on the moistened cornea with the sub conjunctival side down and then slide it into position on the scleral bed. The original limbal edge was opposed to the cornea at the corresponding limbus. Stretch the graft at the limbus so it maintains contact. It was covered the exposed sclera entirely and slightly overlap the cut edges of the conjunctiva.

Fixation the free graft in place and applied over bare sclera by tying forceps and squeezing the graft by using hock about 5 minutes till be sure that it became stable.

Then wire speculum was removed carefully. Then the tight bandage was applied for next 48 hours without removal except during treatment.

After the operation all patients were received the same standard medications for 4 weeks, consisting of an eye drops combination of (0.3% Tobramycin and 0.1% Dexamethasone) and antibiotic (Gatifloxacin 0.3%) eye drops and *tear substitutes* beginning with five times daily and tapered gradually every 5 days.

Post-operative Follow Up:

one day after surgery: Slit lamp examination for:

1. Discover any early complications as graft fallen, iritis and scleritis and discovered localized epithelial defect, graft edema or sub graft hemorrhage.
2. Cornea for clarity and edema.

The operated eye was patched with tight bandage (3–4 days) with eye drops combination of (0.3% Tobramycin and 0.1% Dexamethasone) and antibiotic (Gatifloxacin 0.3%) eye drops 5 times daily and tapered gradually every 5 days and tear substitutes 5 times daily till the end of the 1st month.

one week after surgery:

1. Slit lamp examination was performed to ensure that:
 - i. The graft is in place.
 - ii. Corneal re-epithelialization. If corneal re-epithelialization becomes complete, the operated eye would be unpadding.
2. Best corrected visual acuity (BCVA).
3. Intraocular pressure (IOP).
4. Fundus examination: slit lamp biomicroscopy using non-contact Volk 90 Diopter lens, direct and indirect ophthalmoscopy.

one month after surgery:

1. The 1st month, evaluate stability of graft or any late complications.
2. Slit lamp examination.
3. Best corrected visual acuity (BCVA).
4. Intraocular pressure (IOP). Fundus examination: slit lamp biomicroscopy using non-contact Volk 90 Diopter lens, direct and indirect ophthalmoscopy.

The patients were instructed to use fluorometholone eye drops 3 times daily and tear substitutes 4 times daily till the end of this month.

Three months after surgery:

1. The 3rd month, evaluate the recurrence.
2. Slit lamp examination.
3. Best corrected visual acuity (BCVA).
4. Intraocular pressure (IOP).
5. Fundus examination: slit lamp biomicroscopy using non-contact Volk 90 Diopter lens and indirect ophthalmoscopy.

Six months after surgery: The 6th month, evaluate the recurrence and success rate.

1. Slit lamp examination.
2. Best corrected visual acuity (BCVA).
3. Intraocular pressure (IOP).
4. Fundus examination: slit lamp biomicroscopy using non-contact Volk 90 Diopter lens and indirect ophthalmoscopy.

Statistical analysis

Recorded data were analyzed using the statistical package for social sciences, version 20.0 (SPSS Inc., Chicago, Illinois, USA). Quantitative data were expressed as mean± standard deviation (SD). Qualitative data were expressed as frequency and percentage.

The following tests were done:

- Independent-samples t-test of significance was used when comparing between two means.
- Chi-square (x²) test of significance was used in order to compare proportions between two qualitative parameters.
- The confidence interval was set to 95% and the margin of error accepted was set to 5%. The p-value was considered significant as the following:
 - P-value <0.05 was considered significant.
 - P-value <0.001 was considered as highly significant.
 - P-value >0.05 was considered insignificant.

RESULTS

Table (1): Preoperative data among studied populations.

		Statistics
Sex	Male	17 (56.7%)
	Female	13 (43.3%)
Age (years)		41.23±7.07; 28-53
Eye	Right	18 (60.0%)
	Left	12 (40.0%)
Grade	I	6 (20.0%)
	II	18 (60.0%)
	III	6 (20.0%)
Refraction	Sphere	0.025±0.68; -1.0 - 1.25
	Cylinder	-0.52±0.28; -1.0 - 0.0
	Axis	78.10±60.93; 0.0 - 172.0
UCVA	6/9	21 (70.0%)
	6/12	6 (20.0%)
	6/6	3 (10.0%)
BCVA	6/9	9 (30.0%)
	6/6	21 (70.0%)
IoP		14.86±1.54; 12.0 - 18.0

In the present work, 56.7% of studied populations were males and 43.3% were females. The patient age ranged from 28 to 53 yeas and the mean age was 41.23 years. The condition was on the right eye in (60.0%) and on the left side in (40.0%) of studied populations. The grade of disease was first in (20%), second in (60.0%) and third in (20.0%).

The patient UCVA was 6/9 in (70.0%), 6/12 in (20.0%) and 6/6 in (10%), while the BCVA was 6/9 in (30.0%) and 6/6 in (70.0%) among studied populations. Finally, IoP ranged from 12 to 18, and the mean IoP was 14.86 mmHg.

Table (2): Results in the first postoperative day.

		Statistics
Graft position	In position	28 (93.3%)
	Displaced / Fallen	2 (6.7%)
Graft edema	Yes	5 (16.7%)
	No	25 (83.3%)
Sub-graft hemorrhage	Yes	6 (20.0%)
	No	24 (80.0%)
Cornea	Epithelial defect	30 (100.0%)
	Complete re-epithelialization	0 (0.0%)
Early complications	None	30 (100.0%)

At the first postoperative day, (93.3%) of grafts were in position while (6.7%) were displaced partially; graft edema was reported in (16.7%) and sub-graft hemorrhage was reported in (20.0%). All studied corneas revealed epithelial defect and there were no early complications.

Table (3): Results at the first postoperative week.

		Statistics
Graft position	In position	30 (100.0%)
Graft edema	Yes	0 (0.0%)
	No	30 (100.0%)
Sub-graft hemorrhage	Yes	1(3.3%)
	No	29 (96.7%)
Cornea	Complete re-epithelialization	30 (100.0%)
	Incomplete epithelialization	0 (0.0%)
BCVA	6/9	6(20.0%)
	6/6	24(80.0%)
Fundus	Normal	30 (100.0%)
	Abnormal	0 (0.0%)
IoP		15.90±1.72; 13- 19

At the end of the first postoperative week, all grafts were in position (100.0%); graft edema was not reported in any patient but sub-graft hemorrhage was reported in (3.3%); the BCVA was 6/9 in (20%) and 6/6 in (80.0%); the fundus was normal in all studied corneas. The IoP ranged from 13 to 19, and the mean values were 15.90 mmHg.

Table (4): Results at the end of the first postoperative month.

		Statistics
Graft position	Totally attached	30 (100.0%)
Cornea	Totally clear	29 (96.7%)
	Corneal opacity	1 (3.3%)
BCVA	6/9	6 (20.0%)
	6/6	24 (80.0%)
Fundus	Normal	30 (100.0%)
	Abnormal	0 (0.0%)
Complications	Granuloma	1 (3.3%)
	None	29 (96.7%)
IoP		14.80±1.18; 12-16

At the end of the first postoperative month, all grafts were in positions and totally attached; and corneal opacity was reported in 1 patient (3.3%). The BCVA was 6/9 in (20.0%) of and 6/6 in (80.0%) for the other patients and fundus was normal in all cases. The complications were in the form of granuloma, and were reported in (3.3%) among studied populations. The IoP ranged from 12 to 16 mmHg, and the mean value was 14.80±1.18.

Table (5): Results at the end of the third postoperative month.

		Statistics
Cornea	Clear	29 (96.7%)
	Corneal opacity	1 (3.3%)
BCVA	6/9	6 (20.0%)
	6/6	24 (80.0%)
Fundus	Normal	30 (100.0%)
	Abnormal	0 (0.0%)
Recurrence	Yes	1 (3.3%)
	No	29 (96.7%)
IoP		15.30±1.29; 13 -17

At the end of the third postoperative month, the cornea was clear in (96.7%) of studied subjects, while corneal opacity was reported in one patient (3.3%); The BCVA was 6/9 in (20%) and 6/6 in (80.0%); the fundus was normal among all studied patients and the recurrence rate was reported (3.3%). The IoP ranged from 13 to 17 and the mean value was 15.30 mmHg.

Table (6): Results at the end of the sixth postoperative month.

		Statistics
Cornea	Clear	9 (96.7%)
	Corneal opacity	1 (3.3%)
BCVA	6/9	6 (20.0%)
	6/6	24 (80.0%)
Fundus	Normal	30 (100.0%)
	Abnormal	0 (0.0%)
Recurrence	Yes	2 (6.7%)
	No	28 (93.3%)
IoP		15.30±1.02; 14-17

At the end of the sixth postoperative months, the cornea still clear in (96.7%), while corneal opacity was reported in (3.3%); the BCVA was 6/9 in (20.0%) and 6/6 in (80.0%); the fundus was normal in all cases and the recurrence rate was reported (6.7%). The IoP ranged from 14-17; the mean value was 15.30 mmHg.

Table (7): IoP among studied populations at different points of time.

IoP	Statistics	P values
Preoperative	14.86±1.54	
At the end of the first Po week	15.90±1.72	P1 = 0.009*
At the end of the first Po month	14.80±1.86	P2 = 0.23 (ns)
At the end of third Po month	15.30±1.29	P3 = 0.18(ns)
At the end of the sixth Po month	15.30±1.02	P4 = 0.16 (ns)

P1: Comparison between values at the end of the first postoperative week and preoperative values. **P2:** Comparison between values at the end of the first postoperative month and preoperative values. **P3:** Comparison between values at the end of the third postoperative month and preoperative values. **P4:** Comparison between values at the end of the sixth postoperative month and preoperative values.

In the present work, IoP significantly increased at the end of the postoperative week when compared to preoperative values (15.90±1.72 vs 14.86±1.54 respectively). However, IoP showed non-significant difference at any of next points of time when compared to preoperative values.

CASE

Case no. 1:

46 years old male patient with 3 years history of pterygium progression. There was no history of any ocular trauma, ocular surgery, systemic disorder and drug intake. Pre operative assessment reveals that she had primary nasal pterygium grade (I) of her left eye (Figure 1), her UCVA was 6/9 and BCVA 6/6, IoP was 13 mmHg, cornea was normal clear, no limitation of eye movement in all directions and fundus examination was normal.

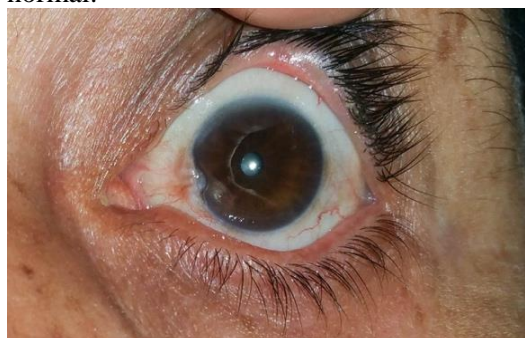

Figure (1): Pre operative primary nasal pterygium grade (I).

In the first day post-operative the graft was in position (Figure 2), there was corneal epithelial defect, no graft edema, no sub graft hemorrhage and no evidence of early complications.

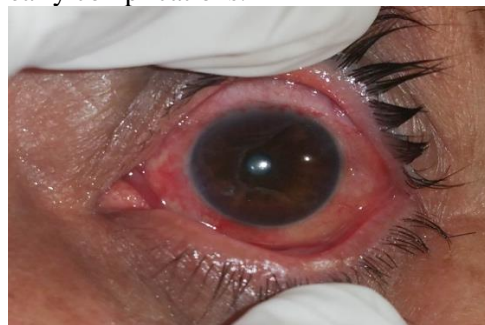

Figure (2): At the first post operative day, the graft was in position, no graft edema, no sub graft hemorrhage but there was corneal epithelial defect. one week later, the graft was in position (Figure 3), there was no corneal epithelial defect (complete re-epithelization), no graft edema, no sub graft hemorrhage, BCVA was 6/6, IoP was 14 mmHg and fundus was normal.

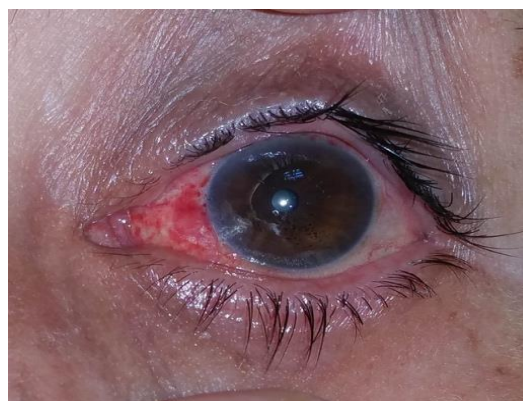

Figure (3): At the first post operative week, the graft was in position, no graft edema, no sub graft hemorrhage and the cornea had a complete re-epithelization.

At the first month post operative, the graft was in position (totally attached), there was no corneal epithelial defect, no graft edema, no sub graft hemorrhage (Figure 4), BCVA was 6/6, IoP was 13 mmHg, fundus was normal and no evidence of late complications.

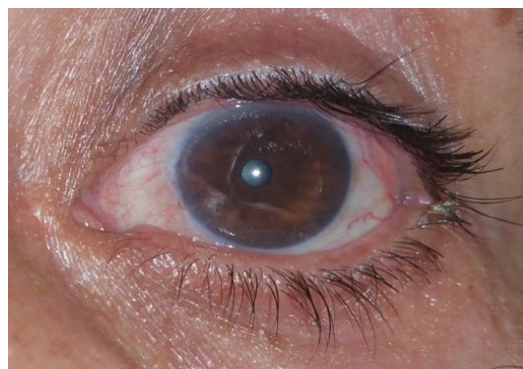


Figure (4): At the first post operative month, the graft was totally attached, no graft edema, no sub graft hemorrhage and no corneal epithelial defect.

At the 3rd month post operative the cornea was clear (**Figure 5**), BCVA was 6/6, IoP was 13 mmHg, fundus was normal and no evidence of recurrence.

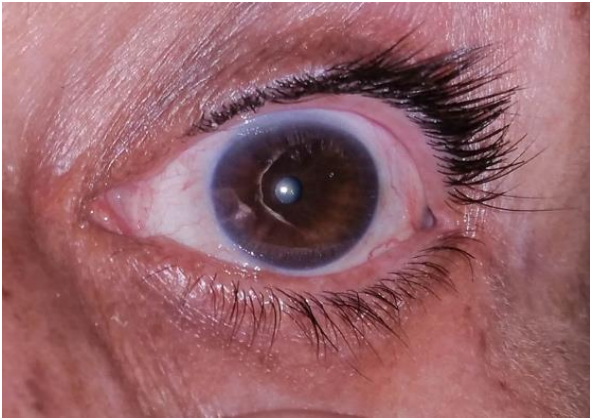


Figure (5): At the end of third post operative month, the cornea was clear and no evidence of recurrence.

At the 6th month post operative the cornea was clear (**Figure 6**), BCVA was 6/6, IoP was 14 mmHg, fundus was normal and no evidence of recurrence.

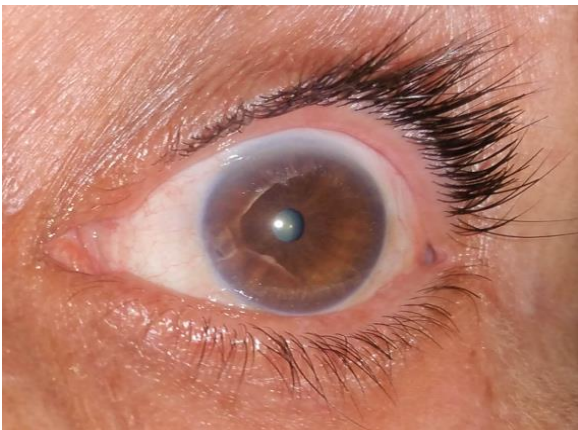

Figure (6): At the end of sixth post operative month, the cornea was clear and no evidence of recurrence.

DISCUSSION

This study conducted on **30** patients attending the outpatient clinic of Al-Azhar University Hospital (Damietta). We assessed the success rate and recurrence after the sutureless glueless graft after pterygium excision in patients with primary nasal pterygium.

In this study, all patients underwent sutureless glueless graft after primary nasal pterygium excision. (**43.3%**) of patients were female and (**56.7%**) were male. (**60%**) of patients were with their right eye and (**40%**) were with left eye. The grade of pterygium ranged between (**I**), (**II**) and (**III**). The patient age ranged from (**28** to **53**) yeas and the mean age was (**41.23**) years.

According to treatment, Surgical excision, which is the treatment of choice for pterygium, can be divided into 2 types: *simple excision* (the bare-sclera technique) and *excision with grafting* (conjunctival or amniotic membrane grafting). Recurrence is the most common undesirable outcome of pterygium excision. Several

factors increase the recurrence rate after surgery, such as the activity of the pterygium ⁽¹¹⁾.

We had performed “*sutureless glueless graft*” under local anesthesia using firstly (Tetracaine 0.5%) one drop to the designated eye then s second dose of topical anesthetic is instilled. This second dose was with (Xylocaine gel 4%) which was considerably stronger and excellent for advancing anesthesia to the conjunctiva and the site of peribulbar anesthesia injection. Xylocaine gel 4% reduces pain and burning discomfort that resulting from infiltration of the skin and subcutaneous tissues with local anesthetic solutions, which is often severe enough to be the most unpleasant part of a surgical procedure especially for patients with needle phobia. After that we injected peribulbar (Carbocaine 2%) to achieve complete akinesia. The Long-lasting anesthesia with peribulbar anesthesia permitted performing our surgical procedure with low pain perceived by patients, minimally invasive surgery, prevention of graft displacement during surgery and hence short duration of surgery. Then followed by cleaning and sterile draping.

In 2018 there was a study comparing the efficacy of different concentrations of topical lidocaine gel with standard subconjunctival anesthesia. They enrolled 45 consecutive patients with 3 different groups who underwent primary pterygium surgery. Group 1 received subconjunctival lidocaine and proparacaine drops as needed during surgery. Group 2 received 2% lidocaine gel and group 3 received 5% lidocaine gel. And they demonstrated that the use of lidocaine gel at concentrations of 2% and 5% in pterygium surgery was as effective as subconjunctival injection of lidocaine in reducing intraoperative and postoperative pain, producing significantly less pain during initial administration of the anesthetic ⁽¹²⁾.

We applied in our technique topical local anesthesia drops using (Tetracaine 0.5%) with (Xylocaine gel 4%) and peribulbar injection (Carbocaine 2%) to achieve complete akinesia during surgery. We noticed the efficacy of this combination during our study in which there was no any complain of pain during the operation for all studied patients hence allowed us to operate comfortably.

Almost of the pterygium surgery procedures depend on steps of the bare sclera technique with some modifications.

In our procedures we started with *initial conjunctival incision* into the body at a point (**2-4 mm**) distal to the limbus, which would generally involve most of the pterygium by Wescott scissor, then the body of pterygium was totally dissected in retrograde manner including conjunctiva and Tenon’s capsule till reached the limbus, then we *excised the head* and remove the affected tissue with the corneal part by using Colibri forceps in continuous circular technique in manner which is similar to the other pterygium surgery procedures.

on the otherwise, the “*conjunctival flaps technique*” consists of the same previous steps of bare

sclera procedure, in addition to *conjunctival flaps* which are fashioned by making superior and inferior relaxing incisions in the conjunctiva at its juncture with the limbus. Then *Initial closure* with non-absorbable suture, and finally *completed closure* with the conjunctival flaps oriented ⁽¹³⁾.

But in “*The transposition technique*”, after of *initial incision* at the head of the pterygium and *the dissection is carried back* to a point on the sclera about (2-4 mm) distal to the limbus, *a small incision* into the superior edge of the lesion, *the head is rotated superiorly* and *sutured to the distal cut edge* of the superior conjunctiva, *the proximal cut edge* of the superior conjunctiva is undermined, *a relaxing incision is made* and *the resulting flap is brought down and sutured* to the inferior edge of the cut conjunctiva, *The overlapping conjunctival flaps are secured* to each other and to the sclera with non absorbable sutures ⁽¹³⁾.

on the otherwise, in our procedure after we *excised the head* and remove the affected tissue with the corneal part we measured the area to be covered by a caliber after the curettage was applied over sclera and corneal excised parts by using blade 15 or crescent blade till the sclera became avoided of conjunctiva and Tenon’s capsule and the cornea became completely clear. We didn’t applied cautery over the bleeding points as we would depend on clotted blood later for fixation of our graft.

After that *harvesting the free graft* from the supertemporal aspect of the bulbar conjunctiva through removing of conjunctiva and leaving Tenon’s capsule after measured it later to measure of excised part and adding 1 mm over excised part and the last part of graft to be removed was the limbal part by blade 15 or crescent blade then by Wescott scissor till removed totally.

But during our harvesting the graft, the small buttonhole was done in 3 cases among all patients. But we continued and positioning it over the bare area. At the end of the first post-operative month, they were completely healed.

After we removed the graft totally, the *positioning of the free graft* should be done without it losing contact with the host surface in which the original limbal edge should be apposed to the cornea at the corresponding limbus and *fixation the graft* in place and applied over bare sclera by two tying forceps and then squeezing the graft by using 2 hocks about 5 minutes till be sure that it became stable. Then we remove the speculum and notice the graft, if we find any displacement, we should put the speculum again and apply more squeezing over the displaced area by the hocks till be sure that it became attached. And finally, the tight bandage is applied for next 48 hours without removal except during treatment.

In “*conjunctival autograft technique*”, the procedure is considered by many surgeons to be the gold standard. Almost of its steps are similar to our procedure steps that consists of *initial incision* into the body of the pterygium, *excision of the head* continues the incision into the body and remove the affected

tissue, *harvesting the free graft* from the superior aspect of the conjunctiva, *positioning the graft* without it losing contact with the host surface and finally *suturing the free graft* in place with non-absorbable sutures or by using fibrin glue instead of sutures ⁽¹³⁾.

The use of fibrin glue during pterygium surgery was first described by Cohen and McDonald in 1993 to avoid complications related sutures, since then various studies have been published regarding the safety and efficacy of fibrin glue in ophthalmic surgery the fibrin glue is used to attach the autograft in place. Two to three drops of the glue were placed on the scleral bed through the duploject injector which is specially designed for it, then the conjunctival autograft was immediately flipped over the area of conjunctival defect ⁽¹⁴⁾.

After the operation all patients were received the same standard medications for 4 weeks, consisting of an eye drops combination of (0.3% Tobramycin and 0.1% Dexamethasone) and antibiotic (Gatifloxacin 0.3%) eye drops and tear substitutes beginning with five times daily and tapered gradually.

In our study at the 1st day post-operative, the grafts of 28 patients (**93.3%**) were in position; while two patients (**6.7%**) had partial graft displacement (one of both was inferiorly displaced and the other was nasally displaced) and underwent to repositioning under slit lamp by hock after topical anesthesia eye drops instillation then recovered the operating eye by tight bandage. The graft edema was reported in 5 patients (**16.7%**) and sub-graft hemorrhage was reported in 6 patients (**20.0%**). All studied corneas revealed corneal epithelial defect (**100.0%**) and we had no early complications (**0.0%**).

According to the patients with graft displacement, when follow up at the next 2nd day post-operative, the grafts were totally in place and there was no any displacement and we recovered the operating eye by tight bandage again.

After the first post-operative week in our study we noticed that all 30 grafts were in their position (**100.0%**) including the previous 2 displaced grafts. The graft edema in 30 eyes became 0 (**0.0%**) and also the sub-graft hemorrhage reduced to (**3.0%**) in all 30 patients; the BCVA was 6/9 in (**20%**) and 6/6 in (**80.0%**); the fundus was normal in all studied patients. and there was no any epithelial defect in all 30 eyes as the complete corneal re-epithelialization had done. The IoP ranged from 13 to 19, and the mean values were 15.90 mmHg.

At the end of the first postoperative month, all grafts were in positions and totally attached; and corneal opacity was reported in one patient (**3.3%**). We decided to follow up the patient with corneal opacity during the next months through using eye lubricants. The BCVA was 6/9 in (**20.0%**) of and 6/6 in (**80.0%**) for the other patients and fundus was normal in all cases.

The complications were in the form of granuloma and were reported in (**3.3%**) among studied populations. The patient with granuloma underwent to excision of granuloma was received the same previous treatment which consisted of eye drops combination of (0.3%

Tobramycin and 0.1% Dexamethasone) and antibiotic (Gatifloxacin 0.3%) eye drops and *tear substitutes* beginning with four times daily and tapered gradually through 4 weeks and when follow up one week later, the site of excision was totally free.

According to the small buttonhole was done in 3 cases during their operations, they were completely healed at the end of this month. The IoP ranged from 12 to 16 mmHg, and the mean value was 14.80 ± 1.18 .

At the end of the third postoperative month, the cornea was clear in (96.7%) of studied subjects, while corneal opacity was reported in the previous one patient (3.3%). The BCVA was 6/9 in (20%) and 6/6 in (80.0%); the fundus was normal among all studied patients and the recurrence of pterygium was reported in one patient (3.3%) among all patients. The IoP ranged from 13 to 17 and the mean value was 15.30 mmHg.

At the end of the sixth postoperative months, the cornea still clear in (96.7%), while corneal opacity was reported in (3.3%) in the same previous patient. the BCVA was 6/9 in (20.0%) and 6/6 in (80.0%); the fundus was normal in all cases and there was recurrence in two eyes (6.7%) among all studied patients with no increase in size of the pterygium case that reported at the end of the third postoperative month. The IoP ranged from 14-17; the mean value was 15.30 mmHg.

The advantages of "bare sclera technique" are easy procedure, has the least surgical time among all procedures and least post-operative discomfort (15). While *the conjunctival flaps technique* is a simple procedure which is the surgeon's preference and is recommended for all primaries, small recurrences and especially double-headed lesions. It features the same attached blood supply, blood vessels oriented vertically away from the limbus, ease of performance, fast healing and single wound (13).

According to "*conjunctival autograft*" the technique is the surgeon's preference for primary degenerative pterygium in older eyes with thin conjunctiva and no glaucoma and for degenerative recurrences. In the absence of double headed pterygium and there may not be enough tissue available for the required two wounds, this procedure is considered by many surgeons to be the gold standard for prevention of recurrence after pterygium surgery (13).

on the other wise "*mucosal graft technique*" is limited due to difficulty harvesting the mucosal tissue, the requirement of two wounds for healing, possible infection due to bacterial content, postoperative pain and high incidence of granuloma (16).

In some cases of "*transposition technique*", it may be cosmetically unacceptable but necessary to reduce the continued destruction of the cornea by the lesion (13).

In our study, as regard "*sutureless glueless graft technique*" rather than the complications of peribulbar anesthesia as retrobulbar hemorrhage, optic neuropathy, globe penetration or perforation, the complications of the surgery may include complications that similar to the complications of conjunctival autograft with sutures or glue as the requirement of two wounds for healing,

postoperative pain, epiphora and granuloma. it may also include early graft displaced or fallen with eye rubbing as that was reported during our study.

"*The mucosal graft technique*" features an average recurrence rate of (10 - 25%) which is partly due to the severity of the lesion, a high inflammation response and relatively slow re-epithelialization during wound healing (13).

In our study "*sutureless glueless graft technique*", the rate of pterygium recurrence was (6.7%) after following up during 6 months. But further controlled studies are needed to demonstrate the long-term outcomes of recurrence rate for this procedure because the 6 months is considered as a short period for judge the recurrence rate clearly.

CONCLUSION

It could be concluded that sutureless glueless conjunctival autograft technique is a safe, simple, easy of performance, has less surgical time and very effective for the management of primary pterygium.

We found that this procedure had no more complications associated with sutures and glue of other pterygium excision procedures, with less post-operative discomfort, fast healing and economical option for the management of primary pterygium surgery with the recurrence rate was (6.7%).

Further controlled studies are needed to demonstrate the potential advantages and long-term outcomes of this procedure.

REFERENCES

1. **Shreesha K K, Dandapani R, Nitin NT et al. (2017):** Double-head pterygium excision with modified vertically split-conjunctival autograft: Six-year long-term retrospective analysis. *Indian J ophthalmol.*, 65(8): 700–704.
2. **Jeanie C, Minas TC, Lien TT et al. (2011):** ophthalmic Pterygium. *Am J Pathol.*, 178(2): 817–827.
3. **Gupta VP (1997):** Conjunctival transplantation for pterygium. *DJo.*, 5:5–12.
4. **Shaaban AM (2014):** Comparison between sutureless and glue free versus sutured limbal conjunctival autograft in primary pterygium surgery. *Saudi Journal of ophthalmology*, 28:292-298.
5. **Di GN, Wakefield D, Coroneo MT (2006):** UVB-mediated induction of cytokines and growth factors in pterygium epithelial cells involves cell surface receptors and intracellular signaling. *Invest ophthalmol Vis Scz.*, 47(6):2430–2437.
6. **Tsai YY, Cheng YW, Lee H et al. (2005):** oxidative DNA damage in pterygium. *Mol Vis.*, 11:71-75.
7. **Li M, Zhang M, Lin Y et al. (2007):** Tear function and goblet cell density after pterygium excision. *Eye*, 21(2):224- 228.
8. **Ang LP, Chua JL, Tan DT (2007):** Current concepts and techniques in pterygium treatment. *Curr opin ophthalmol.*, 18:308.
9. **Xu F, Li M, Yan Y et al. (2013):** A novel technique Of sutureless and glueless conjunctival autografting in pterygium surgery by electrocautery pen. *Cornea*, 32(3):290-5.
10. **Malik KPS, Goel R, Gupta A et al. (2012):** Efficacy

of sutureless and glue free limbal conjunctival autograft for primary pterygium surgery. Nepal J ophthalmol., 4: 230-35.

11. **Tan DT, Chee SP, Dear KB *et al.* (1997):** Effect of pterygium morphology on pterygium recurrence in a controlled trial comparing conjunctival autografting with bare sclera excision. Arch ophthalmol., 115:1235–40.
12. **Pereira F, Shiroma HF, Urias MG *et al.* (2018):** Pilot Study Comparing Topical Anesthetic Agents in Pterygium Surgery: Subconjunctival Injection Versus 2% Lidocaine Gel Versus 5% Lidocaine Gel. Cornea, 37(2):194-198.
13. **Alfred LA (2009):** Pterygium - A Practical Guide to Management. Jaypee Brothers Medical Publishers (P) Ltd. [https://www.amazon.com/Pterygium-Practical-](https://www.amazon.com/Pterygium-Practical-Management-Alfred-Anduze/dp/8184487258)
14. **Santosh K, Roohie S (2018):** Pterygium excision and conjunctival autograft: A comparative study of techniques. Oman J ophthalmol., 11(2): 124–128.
15. **Hovanesian JA, Behesnilian AS (2012):** Pterygium excision with a conjunctival autograft and prophylactic placement of subconjunctival amniotic membrane surrounding the excision site. In: Hovanesian JA, editor. Pterygium: Techniques and Technologies for Surgical Success. Thorofare, NJ: Slack Incorporated, Pp. 101–110.
16. **Forbes J, Collin R, Dart J (1998):** Split thickness buccal mucous membrane grafts and Beta irradiation in the treatment of recurrent pterygium. Br J ophthalmol., 82(12):1420-3.