

## SEX DETERMINATION IN EGYPTIANS BY MEASURING LENGTH AND BREADTH OF FORAMEN MAGNUM AT COMPUTED TOMOGRAPHIC IMAGES OF SKULL

Samira M. Saleh \*, Walaa Ahmed Allam \*\* and Hend Nabil Mahmoud \*\*\*

\*Department of Forensic Medicine and Clinical Toxicology, Faculty of Medicine, South Valley University; \*\*Department of Forensic Medicine and Clinical Toxicology, Faculty of Medicine, Sohag University; \*\*\* Department of Radiology, Faculty of Medicine, South Valley University

### Corresponding Author:

Samira M. Saleh: Assistant professor of Forensic Medicine & Clinical Toxicology, Department of Forensic Medicine & Clinical Toxicology, Faculty of medicine, Qena. South Vally University. Egypt.

E-mail: [samirasaleh13@yahoo.com](mailto:samirasaleh13@yahoo.com) Tel: 01065454062

### Abstract

**Background:** Identification of human skeletal remains is of major importance in medico-legal situations such as criminal cases, mass disasters and human rights abuse investigations. Sex can be established by gross examination of skeleton using metric and morphological techniques. Sexing the skeleton which is intact and entire is certainly easier and reliable with high accuracy as against done with only a part of the skeleton. A sexing accuracy of 90–95% from whole skeleton, pelvis, or one hip bone and 80% accuracy from skull alone. The occipital bone remains well protected and well preserved structure by huge volume of soft tissues, this makes occipital bone useful in the sex determination. **Aim of the study:** To document and analyze the dimensions of foramen magnum and to investigate its reliability in sex prediction at computed tomographic images of adult human skull. **Methods:** This study was carried on 100 Computed Tomographic images of the skull of adult persons (50 males and 50 females). The length and breadth of foramen magnum were measured. **Results:** There is significant difference between the length of foramen magnum in males and females ( $p = 0.00$ ) and there is significant difference between the breadth of foramen magnum in males and females ( $p = 0.00$ ) and there is no significant difference between different ages after puberty. **Conclusion:** There is statistically significant expression of sexual difference in the foramen magnum dimensions, which may prove useful and reliable in predicting sex in partial remains by discriminant function analysis when other methods tend to be inconclusive.

**KEY WORDS:** Foramen magnum; Computer tomography; Morphometry; Sex determination.

### INTRODUCTION

Identification of skeletalized human remains has an important role in many legal problems as in crimes of murder, mass disasters and in investigations of human rights abuse (Saunders and Yang, 1999)

Sex can be estimated by examination of skeleton grossly using metric and morphological techniques. Sexing the skeleton which is intact and entire is certainly easier and reliable with high accuracy as against done with only a part of the skeleton or fragmented skeletal remains (Babu et al., 2012).

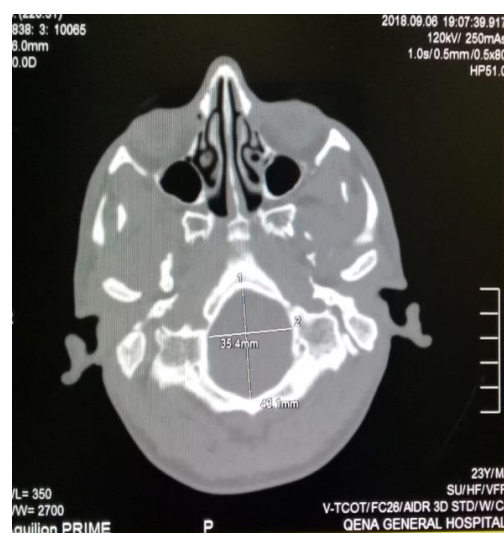Sex estimation reach about 95% accuracy from whole skeleton, pelvis, or one hip bone, but it is only 80% accuracy when using skull alone (**Tracy, 2005**).

Skull bone parts usually has the advantage of withstand bad conditions of burial, natural calamities, mass disasters, terroristic activities, specially the occipital bone which remains well protected and well preserved by huge volume of soft tissues. This makes occipital bone useful in the sex determination (**Gapert et al., 2008**).

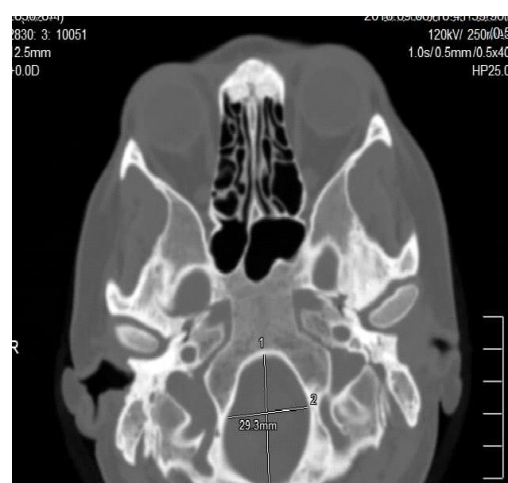
Thickness of skull base and the anatomical position of foramen magnum (FM) prevent any damage due to physical insult and inhumation (**Gruber et al., 2009**).

The transverse diameter of foramen magnum is less than 1/3 of the distance between the two mastoid processes. The anterior border of FM is formed by basilar process of the occipital bone, the lateral borders are formed by left and right ex- occipitals, while the posterior border is formed by the supraoccipital part of occipital bone (**Scheuer and Black, 2004**).

Usually the dimensions of FM will remain constant after second decade of life and will differ in male and female. It is three dimensional, oval or circular apertures within the central basal region of occipital bone (**Stand ring, 2008**).



**Figure (1):** Foramen magnum of male patient.



**Figure (2):** Foramen magnum of female patient.

Ante-mortem and post-mortem radiographs have an important role in identification of human remains and computed tomography (CT) scan has a significant role in these situations. (**Uthman et al., 2012**).

CT scan has the advantage of accurate measurements and allocation of the craniometric points other than on conventional radiographs. CT scan has minimal superimposition of structures and gives good visualization of little differences of density. (**White and Pharaoh, 2010**)

Ante mortem versus post mortem roentgenograms is a good established method in identification, the introduction of computed tomography (CT) has given more imaging modalities to work with, so identification has become possible by comparing ante mortem and postmortem CT scans. (Smith et al., 2002)

The purpose of the present study to analyze and document the dimensions of FM and to investigate their reliability in sex prediction at computed tomographic images of adult human skull.

## **SUBJECTS&METHODS**

### **SUBJECTS**

The present study conducted on 100 Computed Tomographic human skull images from the latest CT scans of the skull for patients who arrived to department of radiology, South Valley University hospitals, after the obtaining of approval from University Hospital ethics committee and informed consent from all the included patients selected according to the inclusion criteria: Age from 18-60 years, from both sex, without bone disease or skull or vertebral column fracture.

### **METHOD**

This study was carried on 100 CT images of the skull of adult persons (50 males and 50 females). CT scans were obtained using a CT scan machine; type Helical CT. Length (anteroposterior diameter) and breadth (transverse diameter) of the FM were measured, then the data will be subjected to descriptive and discriminant analysis.

### **STATISTICAL ANALYSIS**

The data was assessed by SPSS software, version 17. The P values less than 0.05 were considered statistically significant. The data subjected to SPSS Student T test and Logistic regression to evaluate the accuracy of foramen magnum measurements in sex estimation in human

## **RESULTS**

The mean length of FM in males (37.22) is larger than in females (33.53). There is a significant difference between length of the FM in males and females (p value = 0.000) (table 1 & figure 3).

The mean breadth of FM in males (30.34) is larger than in females (28.12). There is significant difference between the breadth (transverse diameter) of FM in males and females (p value = 0.000) (table 2 & figure 4).

The mean of different ages in both sexes there is no significant difference between different ages after puberty (p value = 0.295) (Table 3).

For detection of the most accurate for differentiation between male and female through foramen magnum, we do logistic regression and find that the length is more accurate than breadth (p value=.001) as shown in (Table 4).

**Table (1):** Statistical analysis of the mean of anteroposterior diameter of FM in both sexes using student T test

Sex	N	Mean	SD	P value
M	50	37.22	3.38	.000
F	50	33.53	3.16	

P values are shown as:

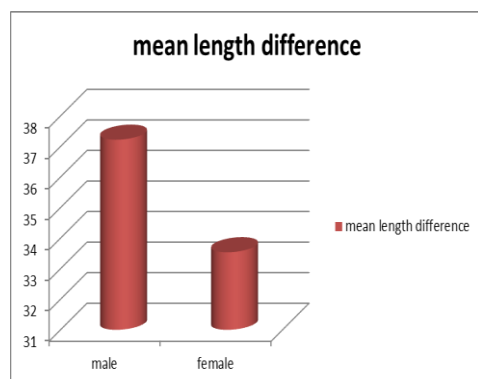
P < 0.05 (significant)

P < 0.01 (highly significant)

P < 0.001 (very highly significant)

SD: Standard deviation

NS: Non significant



**Figure (3):** Representing the mean difference of foramen magnum length in males and females.

**Table (2):** Statistical analysis of the mean of the transverse diameter of FM in both sexes using student T test

Sex	N	Mean	SD	P value
M	50	30.34	2.86	.000
F	50	28.12	1.95	

P values are shown as:

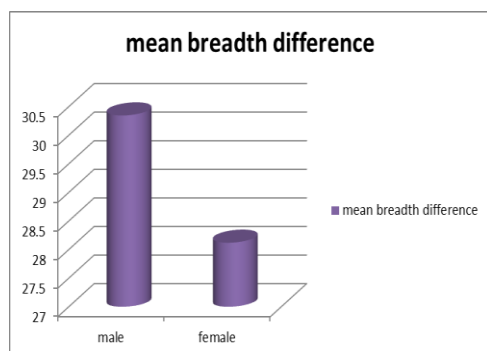
P < 0.05 (significant)

P < 0.01 (highly significant)

P < 0.001 (very highly significant)

SD: Standard deviation

NS: Non significant



**Figure (4):** Representing the mean difference of foramen magnum breadth in males and females

**Table (3):** Statistical analysis of the mean of the different ages in both sexes using student T test

Sex	N	Mean	SD	
M	50	39.40	13.83	.295
F	50	36.64	12.32	NS

P values are shown as:

P < 0.05 (significant)

P < 0.01 (highly significant)

P < 0.001 (very highly significant)

SD: Standard deviation

NS: Non significant

**Table (4):** Logistic regression

		B	Sig.
Step 1 <sup>a</sup>	Length	-0.295	0.001
	Breadth	-0.230	0.05
	Constant	17.100	0.000

## DISCUSSION

The FM is considered a major landmark of base of the skull and of particular interest in anthropology, forensic medicine and anatomy. Its anatomical position beneath a depth of soft tissue make it less vulnerable to destruction or fragmentation by the effects of inhumation processes in comparison to facial and other cranial bones (Westcott and Moore-Jansen, 2001).

A considerable interest has been attracted to foramen magnum for the purposes of sex determination (Gapert et al., 2008).

**Teixeria, 1983** was probably one of the first studies which focused on estimation of sex which is based on the foramen magnum size.

In the present study we measure the dimensions of FM to prove its reliability and accuracy in prediction of sex at computed tomographic images of adult human skull.

In our study there is a significant difference between the mean length of FM in males and females. Also there is a highly significant difference between the mean breadth of FM in males and females.

The mean of length and breadth of FM is larger in males than females, so dimensions of foramen magnum are valuable and reliable in identification of sex.

Our findings were similar with the results reported on the British sample as well as on Indian populations where significant differences were reported between males and females for FM length and FM breadth (**Gapert et al., 2009 & Raghavendra et al., 2012 and Gargi et al., 2018**).

In Nigerian study done on ethnic group involving 100 skulls, **Ukoha et al., 2011** concluded that there was sexual dimorphism in the dimensions of foramen magnum between male and female skulls. Another study done by **Jain et al. 2013**, in north India involving 68 skulls of adult males and females, confirmed its sexing potential. **Burdan et al., 2012** in ethnic group of European eastern, using 3D CT images of 313 skulls of individuals that revealed higher significantly mean values of the length, breadth, and the area of FM in males more than in females

Also many studies analyze the measurements of the FM using different metric means for instance

direct measurement on skull base, radiographs, or CT scans and found that the FM shows sexual dimorphism (**Patel and Mehta, 2014**).

The width of FM of the Brazilian skulls showed high significant predominance in males more than females. This may be related to the fact that the vertebral arteries, nerves and meninges pass through the base of skull. Thus, the area of FM is larger in males than females due to the larger skeletal muscle structure in men (**Enlow and Hans, 2006**).

Another Indian study reported sexual dimorphism by analysing the dimensions of the FM in three-dimensional (3D) CT with 81% accuracy in determining the gender (**Raghavendra et al., 2012**).

In our study for detection of the most accurate for differentiation between male and female through foramen magnum, we do logistic regression and find that the length is more accurate than breadth (p value=.001).

These results were in accordance with **Burdan et al., 2012** who stated that there is a significantly positive correlation between the length and breadth of FM and also in accordance with with a study done by **Shanthi and Lokanadham, 2013** in south Indian ethnic group on 100 skulls which revealed a highly significant *p* value less than 0.001 for sagittal diameter and a significant *P* value for the transverse diameter.

In contrast to our results **Gruber et al., 2009** did not find sexual dimorphism in foramen magnum diameters of skulls from Central Europe. Another study in India (**Deshmukh and Devershi, 2006**) has reported that the measurements of foramen magnum are not reliable in sex determination. **kanchan et al.,**

**2013** stated that craniometric analysis of FM should be only used as a supportive finding in sex estimation of fragmentary remains of skull. **Moodley et al., 2019** also found that the morphology of the FM only presented significant differences in age and not in the sex of an individual in South African Black Population.

Significance of these observations in sex estimation varied according to the ethnic group which involved, study sample size and the statistical analysis applied in the study (**Kamath et al., 2015**).

## CONCLUSIONS

- In our study there is a statistically significant expression of sexual difference in FM dimensions.

- Significance of FM measurements in sex estimation are variable according to the ethnic group, size of the study sample, and statistical analysis applied on the study

- It suggests the reliability, usability and accuracy of computed tomography in forensic identification.

- There is no difference at foramen magnum between different ages as foramen magnum dimensions do not change after puberty.

## REFERENCES

- Babu, Y.P.R.; Tanuj, K.; Yamini, A.; Prashanth, N. and Kotian, M.S. (2012):** Sex estimation from foramen magnum dimensions in an Indian population, *Journal of Forensic & Legal Medicine*, 19:162-167.
- Bilgea, Y.; Sema, K. P.; Yeşim, D.; Üner, Ü. and Yücel, Y.İ. (2003):** The identification of a dismembered human body: a multidisciplinary approach. *Forensic Sci. Int.*, 137 (2–3): 141-146.
- Buridan, F.; Szumito, J. and Walocha, J. (2012):** Morphology of the foramen magnum in young Eastern European adults. *Folia Morphologica*, 71(4): 205–216.
- Deshmukh, A.G. and Devershi, D.B. (2006):** Comparison of Cranial Sex Determination by Univariate and Multivariate Analysis. *J. Anat. Soc. India*, 55: 48–51.
- Enlow, D.H. and Hans, M.G. (2006):** *Nocoes basicas sobre crescimento facial*. 1. ed.: Ed. Santos,: 79-98.
- Gargi, V.; Prakash, S. M.; Malik, S.; Nagaraju, K.; Goel, S. and Gupta S. (2018):** Sexual dimorphism of foramen magnum between two different groups of Indian population: A cross-sectional cone-beam computed tomography study. *J. Forensic Sci. Med.*, 4: 150-155.
- Gapert, R.; Black, S. and Last, J. (2008):** Sex determination from the occipital condyle: Discriminant function analysis in an eighteenth and nineteenth century British sample. *Am. J. Phys. Anthropol.*, 138(4): 384-394.
- Gapert, R.; Black, S. and Last, J. (2009):** Sex determination from the foramen magnum: discriminant function analysis in an eighteenth and nineteenth century British sample. *International Journal of Legal Medicine*, 123(1): 25–33
- Gruber, P.; Henneberg, M.; Böni, T. and Rühli, F. J.(2009):** Variability of human foramen magnum size. *Anatomical Record.*, 292(11) :1713–1719.

- Jain, S. K.; Choudhary, A. K. and Mishra P. (2013):** Morphometric evaluation of foramen magnum for sex determination in a documented north Indian sample. *Journal of Evolution of Medical and Dental Sciences*, 2: 8093–8098.
- Kamath V. G.; Asif, M.; Radhakrishna, S. and Ramakrishna, A. (2015):** Binary Logistic Regression Analysis of Foramen Magnum Dimensions for Sex Determination *Anat. Res. Int.*, 459428. Published online 2015 Aug 5. doi: 10.1155/2015/459428 PMID: PMC4540976.
- Kanchan T., Anadi Gupta, and Kewal Krishan (2013):** Craniometric Analysis of Foramen Magnum for Estimation of Sex. *International Journal of Medical, Health, Biomedical, Bioengineering and Pharmaceutical Engineering*. 7 (7): 378-380.
- Moodley, M.; Rennie, C.; Lazarus, L. and Satyapal, K. S. (2019):** The Morphometry and Morphology of the Foramen Magnum In Age And Sex Determination Within The South African Black Population Utilizing Computer Tomography (CT) Scans. *Int. J. Morphol.*, 37(1): 251-257.
- Patel, R. and Mehta, C.D. (2014):** Morphometric study of foramen magnum at the base of human skull in South Gujarat. *IOSR Journal of Dental and Medical Sciences (IOSR-JDMS)*, 13(6): 23-25.
- Raghavendra, Y. P.; Kanchan, T.; Attiku, Y.; Dixit, P. N. and Kotian, M. S. (2012):** Sex estimation from foramen magnum dimensions in an Indian population. *Journal of Forensic and Legal Medicine*, 19(3): 162–167.
- Saunders, S.R. and Yang, D. (1999):** Sex determination: XX or XY from the human skeleton. In: Fairgrieve SI. *Forensic osteological analysis*. Charles C. Thomas, Springfield, IL: 36–59.
- Scheuer, L. and Black, S. (2004):** *The juvenile skeleton*. Elsevier, London, 1-19
- Shanthi, C. H. and Lokanadham, S. (2013):** Morphometric study on foramen magnum of human skulls. *Medicine Science*, 2:792–798.
- Smith, D.R.; Limbird, K.G. and Hoffman, J.M. (2002):** Identification of human skeletal remains by comparison of bony details of the cranium using computerized tomographic (CT) scans. *J. Forensic Sci.*, 47: 937-939.
- Stand ring, S. (2008):** *Gray's Anatomy the Anatomical Basis for Clinical Practices*. London, UK: Elsevier Churchill Living Stone Publishing Company, (39).
- Steyn, M. and Işcan M.Y. (1998):** Sexual dimorphism in the crania and mandibles of South African whites. *Forensic Sci Int.*, 98: 9–16.
- Teixeria, W.R. (1983):** Sex identification utilizing the size of Foramen Magnum. *Am. J. Forensic Med. Pathol*, 3: 203-206.
- Tracy, L.R. (2005):** Determining the sex of human remains through cranial morphology *J. Forensic Sci.*, 50: 493-500.
- Ukoha, U.; Egwu, O. A.; Okafor, I. J.; Anyabolu, A. E.; Ndukwe, G. U. and Okpala, I. (2011):** Sexual dimorphism in the Foramen Magnum of Nigerian adult. *International Journal of*

Biological and Medical Research,  
2: 878–881.

**Uthman, A.; Al-Rawi, N. and Al-Timimi, J. (2012):** Evaluation of foramen magnum in gender determination using helical CT scanning. *Dentomaxillofacial Radiology*, 41: 197–202.

**Westcott, D.J. and Moore-Jansen, P.H. (2001):** Metric variation in the human occipital bone: Forensic Anthropological Applications *Journal of Forensic Sciences*, 46 (5): 1159-1163.

**White, S. and Pharaoh, M. (2010):** *Oral Radiology Principles and Interpretation*, Philadelphia, (6).



## الملخص العربي تحديد الجنس في المصريين عن طريق قياس طول وعرض الثقبه العظمي في صور الاشعة المقطعية للجمجمة

سميرة محمد صالح\*، هند نبيل محمود\*\*، ولاء احمد علام\*\*\*  
\*قسم الطب الشرعي والسموم الاكلينيكية، كلية طب قنا، جامعة جنوب الوادي  
\*\*قسم الاشعة التشخيصية، كلية طب قنا، جامعة جنوب الوادي  
\*\*\* قسم الطب الشرعي والسموم الاكلينيكية، كلية الطب، جامعة سوهاج

يعتبر تحديد البقايا الهيكلية البشرية ذا أهمية كبيرة في الحالات الطبية القانونية مثل القضايا الجنائية والكوارث الجماعية والتحقيق في انتهاكات حقوق الإنسان حيث يمكن تحديد الجنس عن طريق الفحص الشامل للهيكل العظمي باستخدام التقنيات المترية والمورفولوجية. ويعتبر تحديد الجنس مع هيكل عظمي سليم وكامل سهل وموثوق به بدقة عالية مقارنة مع جزء فقط من الهيكل العظمي حيث تبلغ نسبة دقة تحديد الجنس 95-90% من الهيكل العظمي كله و 80% من الجمجمة وحدها ومن مميزات الجمجمة ان العظم القذالي محمي بشكل جيد ومحافظ عليه من خلال الأنسجة الرخوة المحيطة به ، مما يجعل العظم القذالي مفيداً في تحديد الجنس.

**الهدف من الدراسة:** لتوثيق وتحليل الثقبه العظمي والتحقق من موثوقيتها في التنبؤ بالجنس في الصور المقطعية التصويرية للجمجمة البشرية البالغة.

**الطريقة:** تم إجراء هذه الدراسة عن طريق قياس طول واتساع الثقبه العظمي على 100 صورة لأشعة مقطعية لعدد 100 جمجمة لأشخاص بالغين (50 ذكر و 50 انثى).

**النتائج:** هناك فرق كبير بين طول الثقبه العظمي في الذكور والإناث وهناك فرق ذو دلالة إحصائية بين اتساع الثقبه العظمي في الذكور والإناث مع عدم وجود فرق ذو دلالة إحصائية بين الأعمار المختلفة بعد البلوغ.

**الخلاصة:** هناك تعبير ذي دلالة إحصائية للفرق الجنسي في أبعاد الثقبه العظمي ، والتي قد تثبت فائدتها وموثوقيتها في التنبؤ بالجنس في البقايا الجزئية عن طريق تحليل الوظيفة التمييزية عندما تميل الطرق الأخرى إلى أن تكون غير حاسمة.