



## Effect of Low-Dose Doxycycline and Bisphosphonate on Osteoprotegrin Expression in Ligature Induced Periodontitis in Diabetic Rats (An Experimental Study)

Zeinab Shalaby<sup>(1)</sup>, Naglaa Shawki<sup>(2)</sup>, Marwa El Sheikh<sup>(3)</sup> and Mai Shafik<sup>(4)</sup>

Codex : 07/1601

dentaljournal.forgirls@yahoo.com

### ABSTRACT

**Objective:** To evaluate the effect of mono and combined therapy of low dose doxycycline (LDD) and Bisphosphonate (BPs) on ligature-induced periodontitis in Diabetic rats by immunohistochemical analysis of the expression of osteoprotegerin (OPG) and by immunohistomorphometric analysis. **Methods:** Fifty adult Wistar rats were divided into five study groups as follows: 1) group 1 = diabetes control; 2) group 2 = diabetes + periodontitis; 3) group 3 = diabetes + periodontitis + LDD; 4) group 4 = diabetes + periodontitis + clodronate; and 5) group 5 = diabetes + periodontitis + LDD + clodronate. LDD and clodronate were given as a single agent or as combination therapy during the 7 days of the post-experimental periodontitis period. On day 7, the rats were sacrificed, the mobility of the tooth was recorded, and block biopsies were removed. The gingival tissues were analyzed histologically and immunohistochemically for expression of OPG. Data analysis was performed statistically by Kruskal-Wallis and post hoc Tukey tests. **Results:** The greatest mean value was recorded in group 5, followed by group 4, then group 3. Using Tukey's post hoc test; there was a significant difference ( $p < .0001$ ) between groups 1, 2, 4 and 5 respectively while non significant difference was found between group 1 and 3. Comparing group 2 with groups 3, 4 and 5 a significant difference was found. Comparing groups 3 with groups 4 and 5 non significant difference was found between groups 3 and 4 while a significant difference was found between groups 3 and 5. Lastly, non significant difference was found between groups 4 and 5.

### KEYWORDS

*Bisphosphonate;*  
*diabetes mellitus;*  
*doxycycline;*  
*periodontium.*

1. Assistant Lecturer of Oral Medicine, Periodontology, Diagnosis and Radiology Department, Faculty of Dental Medicine for Girls, Al-Azhar University.
2. Associate Professor of Oral Medicine, Periodontology, Diagnosis and Radiology Department, Faculty of Dental Medicine for Girls, Al-Azhar University.
3. Lecturer of Oral Biology Department, Faculty of Dental Medicine for Girls, Al-Azhar University
4. Lecturer of Oral Medicine, Periodontology, Diagnosis and Radiology Department, Faculty of Dental Medicine for Girls, Al-Azhar University

## INTRODUCTION

Periodontal disease is a chronic inflammatory disease initiated by oral microbial biofilm with complex interactions between the plaque biofilm and host immune inflammatory response that results in gingival inflammation, loss of attachment, bone destruction, and eventually the loss of teeth in severe cases<sup>(1)</sup>.

The influence of DM on the oral cavity has been well researched, and studies have reported diabetes as a risk factor for gingivitis and periodontitis. Several epidemiological studies have shown that a positive correlation between degree of glycemic control and periodontal disease prevalence and progression<sup>(2)</sup>.

The importance of the host inflammatory response in periodontal pathogenesis presents the opportunity for exploiting new treatment strategies for periodontitis by means of host response modulation. Host modulatory therapy (HMT) is a treatment concept that aims to decrease tissue destruction and regenerate the periodontium by modifying destructive aspects of the host response and upregulating regenerative responses<sup>(3)</sup>.

A variety of different drug classes have been evaluated as hostmodulation agents, including the following; bisphosphonates (BPs), such as clodronate, non-antimicrobial formulations of tetracycline (low-dose doxycycline [LDD]), chemically modified non-antimicrobial tetracycline (CMT); and non-steroidal anti-inflammatory drugs<sup>(4)</sup>.

Under physiological conditions, a dynamic balance is established between bone formation and resorption. However, if the balance switches towards enhanced bone resorption, then bone destructive pathology will occur. The long-sought molecular mechanisms behind the cell-to-cell interaction that regulate bone resorption were elucidated in the late 1990s<sup>(5)</sup>.

Osteoproteogrin (OPG) is a member of the TNF receptor superfamily and has a very important role in the skeletal system, acting as a decoy receptor for RANK-RANKL (Receptor activator of NF- $\kappa$ B ligand) binding. It binds to RANKL with high specificity and thus, prevents osteoclasts differentiation and activation and osteoclast apoptosis.

Among various biomarkers of bone destruction, the investigation of OPG in biological analyzes of relevance may deliver reliable information on the state of periodontal disease<sup>(6)</sup>. Thus, the role of OPG marker was well documented in periodontal disease which could be a good indicator of molecular diagnostic value for the disease.

## MATERIALS AND METHODS

Fifty healthy adult male Wistar rats weighing an average of 250 to 300g were utilized in experiments. The animals were housed in separate plastic cages in the animal house of Faculty of Pharmacy, Al Azhar University in accordance with the local guidelines for animal experimentation.

### Animal Grouping:

The animals were divided into five experimental groups 10 days after streptozotocin administration.

Group I: It comprised 10 rats representing diabetic control, in which each rat was gavaged orally daily with 1mL carboxymethylcellulose (CMC).

Group II: It comprised 10 diabetic rats with induced periodontitis, in which each rat was gavaged orally daily with 1mL CMC.

Group III: It comprised 10 diabetic rats with induced periodontitis. Each rat was gavaged daily 1 mL CMC containing doxycycline hydrochloride (6mg/kg) by oral administration<sup>(4)</sup>.

Group IV: It comprised 10 diabetic rats with induced periodontitis. Each rat was administered daily bisphosphonates clodronate(25 mg/kg) by intramuscular injection<sup>(4)</sup>.

Group V: It comprised 10 diabetic rats with induced periodontitis. Each rat was gavaged orally 1 mL CMC containing doxycycline hydrochloride (6mg/kg) and received an intramuscular injection of bisphosphonates clorodonate (25 mg/kg) daily<sup>(4)</sup>.

Drug administration was started at the time that periodontitis was induced after 7-12 days<sup>(4)</sup>.

After 7 days of the drug therapy, all rats were anesthetized and sacrificed. Block biopsy samples, including the gingiva and alveolar bone tissue (3-3 mm), were removed from the buccal maxillary molar region for immunohistochemical and histomorphometric analyses. The samples were fixed in 10% formalin- buffered saline for 24 to 72 hours and decalcified with formic acid for 1 to 2 weeks, and then 4-mm paraffin blocks were processed for immunohistochemical analysis.

### Evaluation of OPG Immunostaining by Image Analysis

Leica Qwin 500 image analyzer computer system (England) at the Pathology Department, Faculty of Dental Medicine Al Azhar University-Girls branch, was used to detect OPG immunostained cells.

The image analyzer consisted of a colored video camera, colored monitor, hard disc of IBM personal computer connected to the microscope, and controlled by Lieca Qwin softwear (fig.1,2).

## RESULTS

### Immunohistochemical analysis

The examination of the specimens of group I after the immunohistochemical staining with osteoproteogrin(OPG) showed a generalized weak positive reaction of OPG to the bone forming cells. The group II which represented the diabetes with induced periodontitis showed negative reaction of OPG.

The examination of the specimens of group III showed a clearly noticed positive reaction to OPG. The group IV showed that immune-histochemical expression of OPG increased. In group V, the OPG showed various degree of positive immune

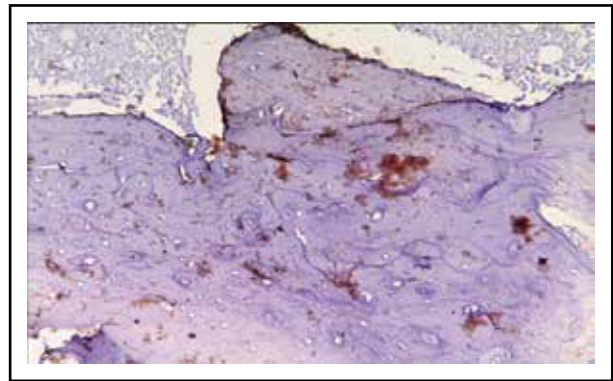


Fig. (1) A photomicrograph showing positive OPG immune staining all over the bone area

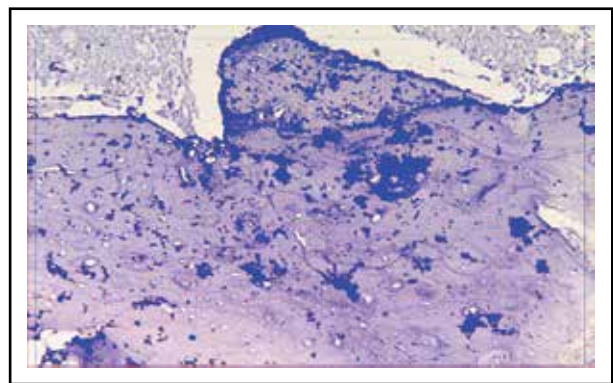


Fig. (2) A photomicrograph showing areas of OPG immunes staining masked by binary color

reaction from moderate in the degree of stainability but with high distribution all over the bone trabeculae to strong stain beside it.

### Immunohistomorphometric Analysis

The greatest mean value was recorded in group 5, followed by group 4, then group 3. Using Tukey's post hoc test; there was a significant difference ( $p < .0001$ ) between groups 1, 2, 4 and 5 respectively while non significant difference was found between group 1 and 3.

Comparing group 2 with groups 3, 4 and 5 a significant difference was found. Comparing groups 3 with groups 4 and 5 non significant difference was found between groups 3 and 4 while a significant difference was found between groups 3 and 5. Lastly, non significant difference was found between groups 4 and 5 (**Tables 1; Fig. 3**).

**Table (1)** Comparison of mean and standard deviation of area percent of OPG expression among five groups.

	Group1	Group 2	Group 3	Group 4	Group 5
Mean	7.138 <sup>c</sup>	2.798 <sup>d</sup>	9.372 <sup>b,c</sup>	12.136 <sup>a,b</sup>	14.389 <sup>a</sup>
Std Dev	1.365	1.164	2.544	2.636	1.337
Max	7.617	4.815	12.521	17.357	16.428
Min	4.927	2.067	6.223	10.177	12.452
F value	22.72				
P value	<.0001*				

\* Significant at  $p < 0.05$ .

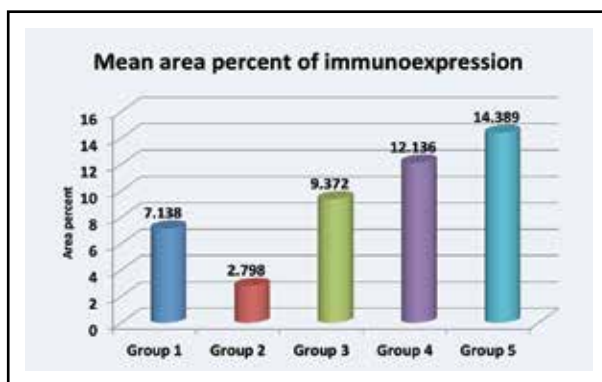


Fig. (3) Column chart showing mean area of immunoeexpression of OPG among all groups

## DISCUSSION

Diabetes mellitus and periodontal disease showed marked association. The relationship between glucose levels and periodontal disease is well documented <sup>(7)</sup>.

Many epidemiological studies had suggested that diabetes and poor glycemic control may be important risk factors for periodontal disease. The association of diabetes with periodontitis is widely accepted <sup>(8)</sup>.

In experimental periodontitis and diabetes research, rodents had been the most used animals given their short generation time, small size, ability to work with large numbers of animals <sup>(9)</sup>.

The advantage of chemically induced diabetes models is the low cost because the disease can be induced in regular, easily accessible laboratory rat strains, such as Wistar and Sprague-Dawley <sup>(10)</sup>.

Streptozotocin had been used in this study because it is a simple, inexpensive and of available method <sup>(11)</sup>.

Ligature induced periodontitis had been used in this study. The ligature model is based on environmental changes with growth of indigenous bacteria as a consequence of tying ligatures around molars resulting in periodontal breakdown <sup>(12)</sup>.

Among different host modulatory agents, low dose doxycycline was selected in the current study. Doxycycline has been used both experimentally and clinically to control and inhibit bone resorption <sup>(3,11,13)</sup>.

Most of previous studies had reported that SDD therapy in combination with non-surgical periodontal therapy can inhibit the activity of collagenases in GCF and gingival tissue of patients with CP with no systemic risk factors for periodontitis <sup>(14,15,16)</sup>.

The bisphosphonates were the second agents utilized as they act through their ability to inhibit osteoclast activity and have been used in a variety of bone disorders including osteoporosis, tumor-associated osteolysis, arthritis and periodontitis <sup>(17)</sup>.

Several animal studies have examined the effects of local or systemic bisphosphonate delivery on alveolar bone resorption by using the experimental periodontitis model <sup>(4,17,18,19)</sup>.

Osteoprotegrin had been utilized as biological marker for bone metabolism in this study as OPG revealed to be a key regulatory mechanism in osteoclast differentiation and activity.

The results of current study revealed that mean area of immunoeexpression of osteoprotogrin, the higher expression was in groupV: (14.39), followed by group IV: (12.14), then group III:(9.4) and group I: DM( 7.2) and finally group II: ( 2.8). Interestingly, the p-value showed a highly significant difference (<0.01) between various groups.

There was a significant difference in mean area percent of immunorexpression of OPG between group I and group II. These finding could be explained by complex interactions of various cytokines, growth factors and hormones in diabetes mellitus. The difference in the balance of these mediators can lead to changes in the expression of OPG in the experimental tissues indicating more alveolar bone loss with DM <sup>(20,21)</sup> .

Upon comparing the mean area percent of OPG immunorexpression in group I (7.2) and group III (2.8), there was a non significant difference. However, group III showed higher value of immunorexpression of OPG than group I DM. These could be contributed to the effect of doxycycline which reduce periodontal tissue destruction by reversing the inhibitory effect of periodontal infection on collagen synthesis<sup>(22)</sup>. These finding was in agreement with Ramamurthy et al., 2002 and Ozdemire et al., 2012 who reported significant reduction in MMPs and cytokines after administration of LDD.

The results of the present study were in agreement with the meta analysis which based on three studies supported the evidence that LDD adjunctive therapy post-treatment effects <sup>(23)</sup>.

The immunorexpression of OPG showed a non statistical significant difference between group IV (12.14) and group V (14.39). However, group V showed a higher level of osteoproteogrin expression thus the combined therapy worked in reducing alveolar bone destruction and the two drugs showed a synergistic effect.

These could be explained by double action of both LDD and BPs in reduction of bone loss by decrease number of osteoclast and delay osteoclast recurment by LDD <sup>(24)</sup> also by BPs which act as inhibitors of osteoclast function in order to suppress bone resorption and improve bone mineral density

Contrasy to our results, Yaffe et al., in 2003 explored the local delivery of doxycycline, clorodronate, and combined efficacy of these drugs on

alveolar bone loss in rats. Their results demonstrated that doxycycline alone was most effective and clorodronate was also effective. Howeve, combined treatment of clorodronate and doxycycline showed no additive effect. This finding was explained by the high concentration (10%) of doxycycline in the doxycycline preparation.

Both low dose doxycycline and bisohosphanate as amono-or combined therapy resulted in favourable immunorexpression of osteoprotogrein. Combined therapy of doxycycline and bisphosphonates showed superior results than monotherapy. Therefore, an important emphasis of new therapies should involve the development and evaluation of therapeutic strategies to target immune cell-mediated periodontal disease.

## REFERENCES

1. Grover H.S., Luthra S. Molecular mechanisms involved in the bidirectional relationship between diabetes mellitus and periodontal disease. *Journal of Indian Society of Periodontology* .2013; 17(3):292-301.
2. Stankoa P., Hollab L.I. Bidirectional association between diabetes mellitus and inflammatory periodontal disease. A review. *Biomed Pap Med Fac Univ Palacky Olomouc Czech Repub.* 2014; 158(1):35-8.
3. Preshaw P.M., Hefti A.F., Jepsen S., Etienne D., Walker C., Bradshaw M.H. Subantimicrobial dose doxycycline as adjunctive treatment for periodontitis. A review. *Journal of Clinical Periodontology*. 2004; 31: 697-707.
4. Ozdemir S.P., Kurtisx B., Tuter G., Bozkurt S., Gultekin S., Senguven B., et al. Effects of Low-Dose Doxycycline and Bisphosphonate Clodronate on Alveolar Bone Loss and Gingival Levels of Matrix Metalloproteinase-9 and Interleukin-1b in Rats With Diabetes: A Histomorphometric and Immunohistochemical Study. *J Periodontol* .2012; 83 (9):1172-82.
5. Lerner U.H. New Molecules In The Tumor Necrosis Factor Ligand And Receptor Superfamilies With Importance For Physiological And Pathological Bone Resorption. *Critical Reviews in Oral Biology and Medicine*. 2004; 15: 64-81.
6. Buduneli N. , Kinane D.F. Host-derived diagnostic markers related to soft tissue destruction and bone degradation in periodontitis. *Journal of Clinical Periodontology*.2011; 38(11): 85-105.

7. Tsai C., Hayes C., Taylor G.W. Glycemic control of type 2 diabetes and severe periodontal disease in the US adult population. *Community Dent Oral Epidemiol*. 2002;30:182-92.
8. Mealey B.L., Oates T.W. Diabetes mellitus and periodontal disease – AAP-Commissioned Review. *J Periodontol*. 2006; 77:1289-303.
9. Cheng W.C., Huang R.Y., Chiang C.Y. “Ameliorative effect of quercetin on the destruction caused by experimental periodontitis in rats,” *Journal of Periodontal Research*.2010; 45(6): 788–95.
10. Brondum E., Nilsson H., Aalkjaer C. Functional abnormalities in isolated arteries from Goto-Kakizaki and streptozotocin-treated diabetic rat models. *Horm Metab Res*. 2005; 37(1):56-60.
11. Akbarzadeh A., Norouzian D., Mehrabi M.R., Jamshidi Sh., Farhangi A., Verdi A., et al. Induction of Diabetes by Sterptozotocin In rats. *Indian Journal of Clinical Biochemistry*. 2007; 22 (2): 60-4.
12. Carla C., Andersen P., Flyvbjerg A., Buschard K., Holmstrup P. American Association for Laboratory Animal Science. Relationship Between Periodontitis and Diabetes: Lessons From Rodent Studies. 2007;61 (1):53–9.
13. Yaffe A., Herman A., Bahar H., Binderman I. Combined local application of tetracycline and bisphosphonate reduces alveolar bone resorption in rats. *Journal of Periodontology*.2003; 74:1038–42.
14. Golub L.M., McNamara T.F., Ryan M.E. Adjunctive treatment with subantimicrobial doses of doxycycline: effects on gingival fluid collagenase activity and attachment loss in adult periodontitis. *J Clin Periodontol*.2001; 28: 146–56.
15. Emingil G., Atilla G., Sorsa T., Luoto H., Kirilmaz L., Baylas H. The effect of adjunctive low-dose doxycycline therapy on clinical parameters and gingival crevicular fluid matrix metalloproteinase-8 levels in chronic periodontitis. *J Periodontol*.2004; 75: 106–15.
16. Lee J.Y., Lee Y.M., Shin S.Y. Effect of subantimicrobial dose doxycycline as an effective adjunct to scaling and root planing. *J Periodontol*.2004; 75: 1500–08.
17. Bartold P., Melissa D., Cantley, David R., Haynes. Mechanisms and control of pathologic bone loss in periodontitis. *Periodontology* 2000. 2010; 53:55–69.
18. Ouchi N., Nishikawa H., Yoshino T., Kanoh H., Motoie H., Nishimori E., et al. Inhibitory effects of YM175, a bisphosphonate, on the progression of experimental periodontitis in beagle dogs. *Journal of Periodontal Research*.1998; 33:196–204.
19. Tani-Ishii N., Minamida G., Saitoh D., Chieda K., Omuro H., Sugaya A., et al. Inhibitory effects of incadronate on the progression of rat experimental periodontitis by *Porphyromonas gingivalis* infection. *Journal of Periodontology*.2003; 74: 603–09.
20. Schmidt A.M., Yan S.D., Wautier J.L., Stern D. Activation of receptor for advanced glycation end products: A mechanism for chronic vascular dysfunction in diabetic vasculopathy and atherosclerosis. *Circ Res*. 1999; 84:489-97.
21. Grossi S.G. Treatment of periodontal disease and control of diabetes: An assessment of the evidence and need for future research. *Ann Periodontol*. 2001; 6: 138-45.
22. Karimbux N.Y., Ramamurthy N.S., Golub L.M., Nishimura I. The expression of collagen I and XII mRNAs in *Porphyromonas gingivalis*-induced periodontitis in rats: The effect of doxycycline and chemically modified tetracycline. *J Periodontol*. 1998; 69:34-40.
23. Sgolastra F., Petrucci A., Gatto R., Giannoni M., Monaco A. Long-term efficacy of subantimicrobial-dose doxycycline as an adjunctive treatment to scaling and root planing: a systematic review and meta-analysis. *J Periodontol*.2011; 82: 1570–81.
24. Bezerra M.M., Brito G.A., Ribeiro R.A., Rocha F.A. Low-dose doxycycline prevents inflammatory bone resorption in rats. *Brazilian Journal of Medical and Biological Research*.2002; 35: 613–6.