

# Unusual presentation of a Gartner duct cyst in early pregnancy

Lydia A. Fein, Brittany Mason, Austin J. Zanelotti and Jose A. Carugno

Original  
Article

Department of Obstetrics and Gynecology, University of Miami Miller School of Medicine

---

## ABSTRACT

**Introduction:** Gartner ducts are vestigial remnants of the mesonephric ducts that regress after the eighth week of embryologic development. In the adult female, remnant Gartner ducts from the mesosalpinx to the cervix via the broad ligament and are typically located along the anterolateral vaginal wall. Cysts can arise when the ducts become obstructed and secretions from the remnant epithelium accumulate. Gartner duct cysts represent only about 11% of benign vaginal cysts. They often occur in pregnancy, but typically in the third trimester.

**Aim of Study:** The purpose of this case report is to present a very unusual case of Gartner duct cyst that presented during the first trimester of pregnancy with our management strategy.

**Patients and Methods:** After a 19-year-old primiparous patient presented with a painful midline vaginal mass in her first trimester, ultrasound and MRI were used to obtain the diagnosis of Gartner duct cyst. Bedside incision and drainage was performed to avoid general anesthesia for surgical excision.

**Results:** The patient's symptoms resolved after drainage, and she continued her pregnancy without complication. Complete healing of prior incision occurred with mild re-accumulation of glandular fluid. The patient had further symptoms.

**Conclusion:** Gartner duct cyst should be on the differential diagnosis for a woman who has a midline vaginal cyst, even though they more typically occur more laterally. General anesthesia in the first trimester of pregnancy should be avoided. Therefore, we suggest bedside incision and drainage as an option for the management of symptomatic Gartner duct cysts in the patient who is not the ideal candidate for surgical excision.

**Key Words:** Cyst, gartner, vagina.

**Received:** 06 August 2017, **Accepted:** 11 August 2017

**Corresponding Author:** Lydia A. Fein, MD, Department of Obstetrics and Gynecology, University of Miami Miller School of Medicine, **Tel.:** 305-585-5640, **E-mail:** lafein@med.miami.edu

**ISSN:** 2090-7265

## INTRODUCTION

Gartner ducts are vestigial remnants of the mesonephric ducts that regress after the eighth week of embryologic development (Eilber & Raz, 2003). These structures extend from the mesosalpinx to the cervix via the broad ligament and are typically located along the anterolateral vaginal wall. Cysts can arise when the ducts become obstructed and secretions from the remnant epithelium accumulate. Gartner duct cysts represent only about 11% of benign vaginal cysts (Pradhan & Tobon, 1986). They are most often asymptomatic, small (<2 centimeters), and found incidentally on pelvic exam. They do, however, have the propensity to become symptomatic when obstructed. Common reported symptoms include the sensation of a large pelvic mass, dyspareunia, pelvic pain, or urinary symptoms including dysuria, urinary retention, or lower urinary tract infection (Dolan, *et al.*, 2017). Gartner duct cysts can present as isolated findings or associated with other genitourinary abnormalities such as ectopic ureter,

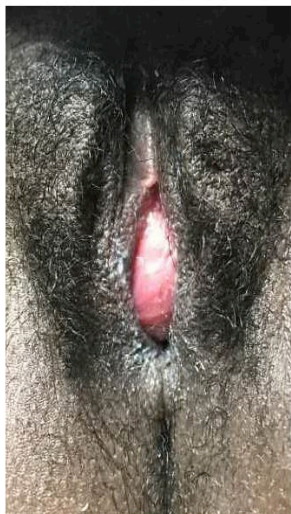
unilateral renal agenesis, or structural uterine anomalies. Given close proximity to other structures and overlapping symptoms, differential diagnosis must include urethral diverticulum, urethral prolapse, skene duct cyst, or pelvic organ prolapse. MRI is the imaging modality of choice to ascertain the correct diagnosis (Rios *et al.*, 2016; Heller, 2015). However, definitive diagnosis of Gartner duct cysts can only be made by histology. In pregnancy, Gartner duct cysts are typically diagnosed in the third trimester (Arumugam, *et al.*, 2007; Boujenah, *et al.*, 2014). We present a very unusual case of Gartner duct cyst that presented during the first trimester of pregnancy.

**Aim:**

The purpose of this case report is to present a very unusual case of Gartner duct cyst that presented during the first trimester of pregnancy with our management strategy. This study was exempt from Institution Review Board approval.

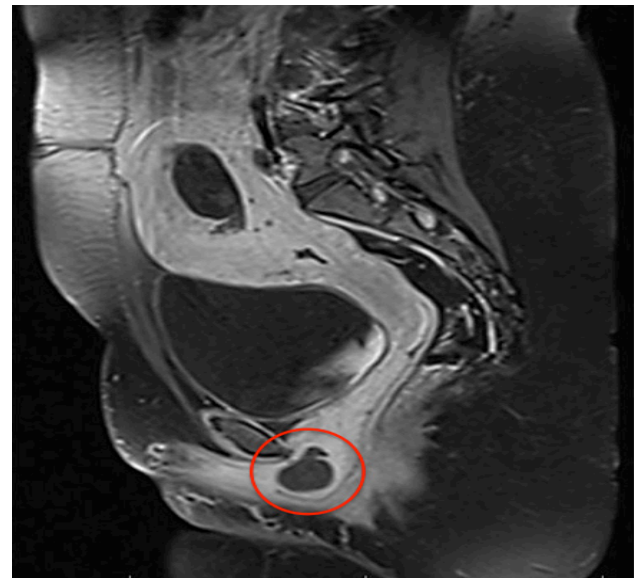
### Case Report

The patient is a 19-year-old primigravid who presented to the emergency room at 9 weeks gestation complaining of a painful vaginal mass. She reported noticing a small “bump” in her vagina that steadily grew over one week, becoming increasingly painful. She reported dysuria but denied other urinary symptoms. She additionally reported no vaginal discharge and had no signs or symptoms of local or systemic infection. On external exam, a vaginal mass was seen occupying the vaginal introitus (Fig. 1). Bimanual exam was performed and the mass was exquisitely tender to palpation and non-fluctuant, originating from the distal one third of the anterior vaginal wall along the



**Fig. 1:** Anterior vaginal wall lesion occupying the introitus on initial vaginal exam.

midline, and extending to the external urethral meatus. An abdominal ultrasound revealed a heterogeneous fluid collection in the anterior vaginal wall, measuring 3.6 x 2.1 x 3.1 centimeters. Given concern for urethral involvement, an MRI was obtained that confirmed the finding of a heterogeneous collection limited to the vagina with concern for hemorrhagic or infected Gartner duct cyst (Fig. 2). No further genitourinary abnormalities were observed. Incision and drainage was performed under local anesthesia. Purulent fluid was obtained and sent for culture, which was ultimately negative. The patient’s symptoms resolved after drainage, and she continued her pregnancy without complication. Complete healing of prior incision occurred with mild re-accumulation of glandular fluid.



**Fig.2:** MRI of the pelvis demonstrating a Gartner duct cyst within the anterior vaginal wall, delineated by the red circle.

### DISCUSSION

Enlargement of Gartner duct cysts is often associated with pregnancy, particularly in the third trimester (Arumugam, *et al.*, 2007; Boujenah, *et al.*, 2014). This presentation of a Gartner duct cyst was unusual given that the patient was in her first trimester of pregnancy, but also given its location along the vaginal midline. As the mesonephric ducts regress bilaterally, they follow a path that is anterolateral to the urethra. Therefore, a Gartner duct cyst arising from the midline is a rare occurrence and leads to a broad differential diagnosis that favors urethral abnormalities or pelvic organ prolapse. In our young patient without risk factors, pelvic organ prolapse is considered unlikely and the use of MRI was helpful in excluding urethral origins of the mass. Given the patient’s symptoms, expectant management was not appropriate and surgical excision versus incision and drainage were considered.

The largest series regarding management of Gartner duct cysts included 29 cases and all were treated by complete surgical excision or marsupialization due to symptoms or increasing size. Intra- and post-operative complications were low and recurrence occurred in only one patient (Cope *et al.*, 2017). Other published isolated case reports also support similar management strategies (Escuerdo *et al.*, 2014). When symptomatic, surgical management with duct excision may have been considered first line. However, our patient was in her first trimester of a desired pregnancy and the risks of surgical management were taken into consideration, including risk of miscarriage and possible teratogenicity with exposure to general anesthesia (Cheek & Baird, 2009) and risk of blood loss and cervical damage given close proximity of the cyst and vasculature of the vagina. Therefore, our patient was offered bedside incision and drainage under local anesthesia, which is considered safe in pregnancy. This proved to be a successful.

---

## CONCLUSION

Given the positive outcome of our approach to care, we suggest this as an option for the management of symptomatic Gartner duct cysts in the patient who is not the ideal candidate for surgical excision. While it does not allow for histologic confirmation of the cyst, it provides symptomatic relief and definitive resolution.

## CONFLICT OF INTEREST

There are no conflicts of interest.

---

## REFERENCES

1. Arumugam AV, Kumar G, Si LK, Vijayanathan A. Gartner duct cyst in pregnancy presenting as a prolapsing pelvic mass. *Biomedical Imag Interv J* 2007; 3(4): e46.
2. Boujenah J, Ssi-yan-kan, G, Prevot S, Chalouhi GE, Deffieux X. Vaginal Gartner duct cyst presenting as a cystocele during pregnancy. *Eur J Obstet Gynecol Reprod Biol* 2014; 180; 202- 04.
3. Cheek TG, Baird E. Anesthesia for nonobstetric surgery: Maternal and fetal considerations. *Clin Obstet Gynecol* 2009; 52(4): 535 -545.
4. Cope AG, Laughlin-Tommaso, SK, Famuyide AO, Gebhart JB, Hopkins MR, Breitkopf DM. Clinical manifestations and outcomes in surgically managed Gartner duct cysts. *J Minim Invasive Gynecol* 2017; 24(3): 473- 477.
5. Dolan MS, Hill C, Valea FA. Benign Gynecologic Lesions. In Lobo RA, Gershenson DM, Lentz GM, Valea FA, eds. *Comprehensive Gynecology*. Philadelphia: Elsevier; 2017 pp370 -422.
6. Eilber KS, Raz S. Benign cystic lesions of the vagina: A literature review. *J Urol* 2003; 170: 717 -722.
7. Escudero RM, Navas Martinez MC, Castillo OA. Vaginal gartner cysts: clinical report of four cases and a bibliographic review. *Gen Urol* 2014; 67(2): 181- 184.
8. Heller DS. Benign tumors and tumor-like lesions of the vulva. *Clin Obstet Gynecol* 2015; 58(3): 526- 535.
9. Pradhan S, Tobon H. Vaginal cysts: a clinicopathologic study of 41 cases. *Int J Gynecol Pathol* 1986; 5:35.
10. Rios SS, Pereira LCR, Santos CB, Chen ACR, Chen JR, and Vogt MF. Conservative treatment and follow-up of vaginal Gartner duct cysts: A case series. *J Med Case Rep* 2016;10(147):1- 4.