



A COMPARATIVE PROSPECTIVE CLINICAL STUDY OF TWO DIFFERENT IMPLANT SYSTEM WITH ZIRCONIA ABUTMENT FOR CEMENTED SINGLE TOOTH RESTORATION

Sahar Abdel Wahab⁽¹⁾ and Shadia Abdel-Hameed Elsayed⁽²⁾

Codex : 03/1610

sahar_abdalwahab@yahoo.com
shadiaelsayed25@gmail.com

ABSTRACT

Statement of problem. Treatment of tooth loss in the anterior maxilla can involve difficult functional, esthetic, and psychological problems, especially in young patients with otherwise good dentition. **Purpose.** The purpose of this study was to provide a comparative evaluation of two different implant system (Biohorizons and Dentium) with zirconia abutment in cemented single-tooth restorations. **Material and methods.** This prospective study of 45 single-tooth replacements with 22 Biohorizons and 23 Dentium dental implants was performed in 30 patients. The patients were selected from the outpatients' clinic, Faculty of Dental Medicine, Al- Azhar University during the period October 2010 to October 2013. The custom zirconia abutments were fabricated. The restoration was an all ceramic crown for cementation with a framework in zirconia. The first clinical and radiographic follow up was performed one week after crown placement for all patients (baseline examination) then at four, eight and twelve months after crown placement, all patients were recalled and participated in the annual examination. **Results.** The clinical parameters (plaque and peri-implant gingival indexes) measured at the baseline and 1-year follow-up examination showed non significant differences in Biohorizons and Dentium and gave a satisfactory results. There is a significant difference in probing depth where the Biohorizons gave better result. The bone loss in Biohorizons was lesser than that in Dentium. The mean marginal bone loss was slightly higher (non significant) in the maxilla for both implant systems. During the 1-year follow up period, the survival rate was 100% in Biohorizons implant system and 95.6% in Dentium implants. The titanium screws that attached the abutment to implant were loosened within a few months of insertion of the permanent crown in two cases of Dentium implant. Subjectively all patients were satisfied with their single-tooth restorations supported by both dental implants. **Conclusion.** Within the limitation of the present study, favorable results obtained with the application of the Biohorizons implant system that supported cemented single-tooth crowns with custom zirconia abutment especially in the anterior region of the maxilla. Further studies are necessary to evaluate the long-term success.

KEYWORDS

Dental implants;
cemented single implant;
clinical study

CONFLICTS OF INTEREST

The authors declare no conflict of interest

1. Associate Professor of Fixed Prosthodontics department, Faculty of Dental Medicine for Girls, Al-Azhar University. Corresponding author.
2. Lecturer of Oral and Maxillofacial Surgery, Faculty of Dental Medicine for Girls, Al-Azhar University. Corresponding author.

INTRODUCTION

Replacement alternatives for the missing tooth include removable or fixed partial dentures as well as adhesive restorations.⁽¹⁾described the technique of using endosseous, root formed implants to replace missing single teeth in the anterior maxilla. The advantage of utilizing implants for single tooth replacement was related not only to aesthetic demands but also to the fact that adjacent teeth were not engaged in the prosthetic rehabilitation. This technique was subsequently applied not only to edentulous sites in the anterior segments but also to load carrying posterior parts of the dentition .²⁻¹¹

Zirconia abutments supporting single-tooth implant crowns showed a survival rate of 100% over 3–4 years.¹²⁻¹³The 3-year results from a randomized controlled clinical trial comparing customized zirconia and titanium abutments showed no difference in the outcome from technical, biological or aesthetical points of view.¹⁴A recent review did not identify more than these three clinical studies.¹⁵That study found no difference in mucosal discoloration between zirconia and titanium abutments, thus contradicting a previous study.¹⁶ The results of zirconia abutments are thus very promising but more clinical investigations are warranted.

Cement retained crowns have several advantages over screw retained crowns. The most important is no longer a need to develop a screw access opening in the occlusal or facial surface of the implant crown restoration. However cement retained crowns are not as retrievable as screw retained crowns in the event that the abutment and crown have to be repaired. One survey of commercial dental laboratories suggested that the number of screw retained restorations was decreasing .

Some authors suggest that the screw-retained prosthesis offers reversibility and more stability and security at the implant–abutment prosthetic

interface.¹⁷ Others¹⁸⁻¹⁹emphasize the advantages of the cement-retained prosthesis, including more versatile esthetics, passive placement, and simplicity of the technique. One shared characteristic of screw- and cement-retained implant prostheses is that the abutment is screwed into the implant.²⁰

It was presented that, the outcome of a meta-analysis of 13 studies including 4750 single-tooth implants of the Bra°nemark Systems (Nobel Biocare, Gothenburg, Sweden), In the studies surveyed, only 19 failures were reported.²¹ In a recent systematic review, it founded that, the incidence of biological and biomechanical complications associated with the use of implants for single-tooth replacement. Eight prospective studies with at least 5 years of follow-up were identified. From the data reported it was evident that the incidence of (i) implants that were lost before loading (0.8%) and during function (2.5%) as well as (ii) technical complications (0.5 incidence/ patient) in this type of rehabilitation was small but appeared to be dependent on the implant system used.²¹

Purpose of this study was to evaluate clinical outcome of custom made Zirconia abutments for cemented single tooth restoration in Biohorizons versus Dentium implant up to 1- year after insertion.

MATERIALS AND METHODS

Study Design

This study evaluate the records of patients treated with cemented single tooth implant restoration using custom made Zirconia abutments and two different implant system Biohorizons (Laser-lok, Birmingham, USA) versus Dentium (Dentium Co., Ltd in Korea). From October 2011 to October 2013. In total, 45single tooth implants (22 Biohorizons and 23 Dentium) were placed in 30 patients (17 women and 13 men). The median age of the patients was 23 years with a range from 17 to 55 years. Patients selected from the outpatients' clinic, Faculty of Dental Medicine, Al- Azhar University.

Patients

All the patients were examined before treatment. The inclusion criteria was a tooth gap with healthy non-restored neighbor teeth, all patients were free from debilitating systemic diseases, with normal maxillo-mandibular relationship, free from any signs of TMJ disorders, free from any local and general contraindications for implant surgery. Residual alveolar ridge is covered with firm and even compressible mucosa. Patient must be free from abnormal habits as bruxism, clenching and grinding. None of the patients received any grafts or other treatments for improving the anatomy of implantation site. Patients who were found suitable and accepted the invitation to participate were included in the study and received the implant and prosthodontics treatment required.

Digital and visual examinations were done and any pathologic conditions were excluded. The intact edentulous ridge was examined for any inflammation, soreness or ulcer before proceeding to the surgical procedure. Size and shape of the arches and alveolar ridges were evaluated, palpation for any undercuts or any bony specules, and an assessment of remaining tissue types and inter-arch space. A preoperative digital Orthopantomogram used as standard screening radiograph for all patients to detect any pathologic bony changes before Cone beam computerized tomography (CBCT).

Cone beam x ray: Soredex x-ray (SOREDEX x-ray machine 3D company with the specification of 60x60mm 3-D standard resolution. 58Kv, 15 m) machine was used for preoperative assessment and planning of potential implant site for all patients to evaluate length, width, quality and density of bone via cross sectional cuts in three dimensions records (axial, coronal and Sagittal). After informing the patient about the treatment plan they were asked to sign a written consent including the line of treatment and need of the regular recall and follow up. Primary and secondary impressions were taken and casts were poured into stone material to construct radiographic transparent acrylic template. The template was polished, finished and checked in the patient's mouth. A circular hole 1mm depth at implant site of the transparent template using round bur were done and then a metal standardized marking spheres of 4mm diameter were fixed into the hole at implant potential site.

Implant length and width was determined from examined CBCT axial, coronal and sagittal cuts using soft ware viewer program and virtual implant planning procedures. After the preoperative radiographic planning, this radiographic stent will be modified by removing the metallic spheres and making circular holes in the site of implant axis placement and became a surgical template. (Fig.1)

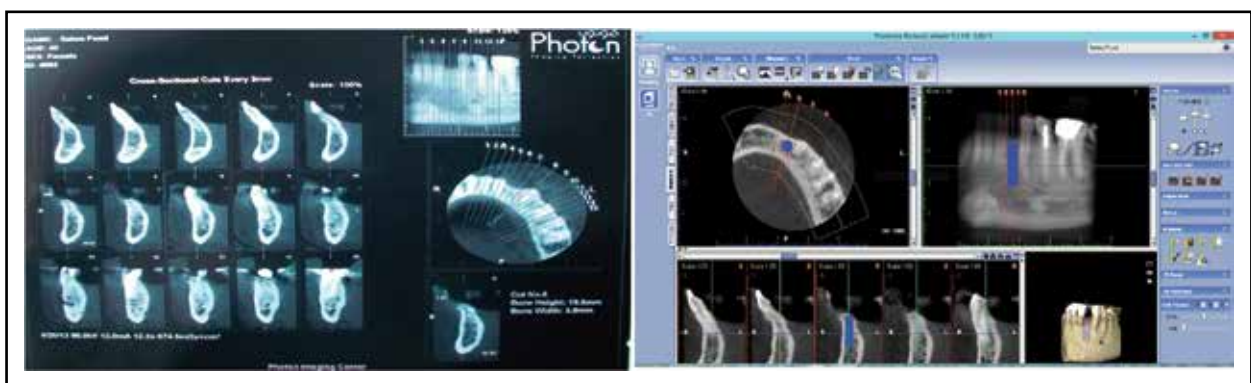


Fig. (1) Preoperative photograph of cross sectional cuts of CBCT in lower right canine with implant tracing measurement and virtual implant planning.

Surgical Procedures

Presurgical medication was given to the patient such as Antibiotics and anti-inflammatory (to reduce postoperative edema) after the surgery, anti septic mouth wash was also instructed to the patient three times per day for 3 days prior to surgery.

Flapless surgical technique was planned for the patients, the Surgical preparation was begun with a no.4 surgical round bur in a high-speed hand piece which was introduced through the soft tissue; Soft tissue depth was measured first to add its depth to the predetermined implant depth (trans mucosal insertion of the bur without punch-out). The thickness of soft tissue to bone was measured, making it easier to maintain correct depth with each implant drill.

First stage surgery: Using the surgical template that was seated on bone to ensure appropriate positioning of the osteotomy sites. A pilot drill 1.5mm in diameter was used at the previously determined implant site, and then sequential drills used to widen the prepared osteotomy to the determined depth and width. Drilling was done with low speed high torque motor system and a hand-piece with internally irrigated sharp drills. Implant position may be slightly more palatal as compared to a fixed prosthesis depending on how much ridge restoration has occurred. A guide pin (Paralleling rods) is inserted into the osteotomy site to ensure that the implant hole will be parallel as possible to the neighboring tooth long axis. Once the osteotomy was completed, the pre-planned implants 'type, length and size were placed. Titanium implant (Dentium) tapered design with conical internal hex connection between implant and abutment surface with double thread and sandblasting with large grits and acid etching S.L.A (Dentium Co, Ltd. Korea) and (tapered internal implant and laser lock with beveled collar and surface resorb able blast texturing HA, Birmingham, USA) were selected, the implant was screwed in the prepared site until resistance was met. For more tightening and control of the fixture stability, hand wrench of the surgical kit and hex driver were used in clockwise direction. Once in

place, a protective cover screws were screwed deep to the fixtures allowing surrounding gum tissue over the implant site to heal and Osseo integration to occur. The patients were instructed to eat soft diet for 2 weeks. Regular recall appointments of patients were done. A healing period of 3 months was allowed to assure complete Osseo integration of the implants.

After three months, the second stage surgery was done, patients were inspected for Osseo integration. Osseo integration was confirmed by clinical and radiographic parameters. (Fig.2) No mobility and no peri-implant radiolucency with new bone formation on the postoperative radiograph was the indication of successful implant Osseo integration. The cover screw was removed from the implant body using screw driver. Irrigation with saline is gently done to remove any debris entrapped in the implant body at the site of the cover screw. Healing cap was inserted for two weeks to allow for better gingival collar adaptation around implant crest.

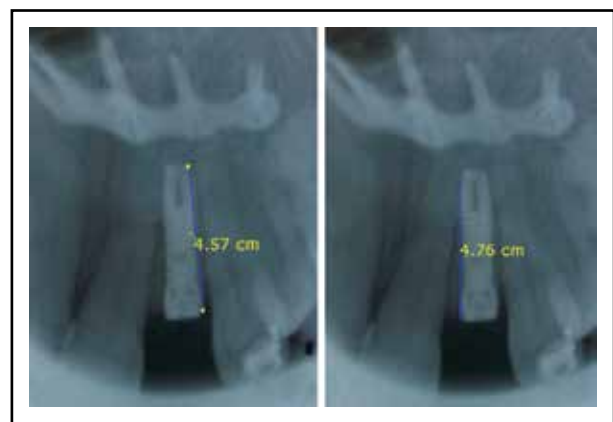


Fig. (2) Immediate Postoperative photograph showing mesial and distal bone height measurement of upper lateral incisor implant.

Prosthetic procedures

The prosthetic treatment was provided by specialists in prosthetic dentistry. A closed tray technique using the indirect transfer coping was selected. An impression was taken on implant level with a polyether material (Impregum, Penta

3M Espe AG, Seefeld, Germany). The customized zirconia abutments were fabricated with the use of a CAD/CAM-system (Procera, Nobel Biocare AB, Gothenburg, Sweden).

After a clinical check, the screws of zirconia abutments were tightened to 30 Ncm using a calibrated torque wrench and an .050" (1.25mm) hex driver according to the manual of the manufacturer . Counter-torque may be applied by grasping the abutment using an abutment clamp or hemostat. The screw holes were blocked out with temporary filling material. If the margin was subgingival, retraction cord was necessary. A full-arch impressions were made using conventional crown and bridge impression techniques.

Lava™ Frame Zirconia mill blanks were used for the fabrication of frameworks for all-ceramic restorations (Lava™ framework Ceramic, 3M ESPE AG, Seefeld, Germany). The frameworks are designed at the Lava Scan™ . After milling, the frameworks were dyed with one of the seven Lava Frame Shade dyeing liquids as required to achieve the desired tooth color, then sintered. Lava™ Ceram was used for veneering (Lava™ Ceram, 3M ESPE AG, Seefeld, Germany). The interior surfaces of the crowns cleaned and blasted with aluminum oxide $40\mu\text{m}$, A conventional glass ionomer cement was used (Ketac™ Cem, 3M ESPE AG, Seefeld, Germany). (Fig.3)

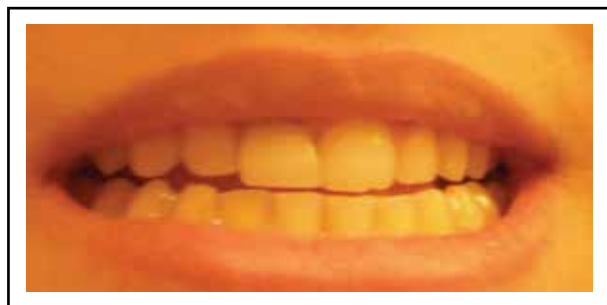

Fig. (3) Clinical photograph showing upper right central incisor single crown cemented to Biohorizons implant fixture

After the prosthodontics treatment, all the patients received oral hygiene instructions by a licensed dental hygienist. The patients approved to be motivated and were instructed in home care procedures.

The first clinical and radiographic follow up was performed one week after crown placement for all patients (baseline examination). Four, eight, twelve months after crown placement, all patients were recalled and participated in the annual examination. The patients were asked to contact the clinic whenever they had problems with their crowns or implant.

Registration and clinical examination

All patients' records were scrutinized and the following patient and treatment data were registered on a form for each patient: sex, age at insertion of the restoration, number and type of restorations, implant position, surgical and prosthodontics failures from baseline up to the last visit at the clinic.

The technical recordings comprised fractures of the abutment, crown and veneering porcelain, loss of retention of the abutment (abutment screw loosening), and change of vertical crown position. The restorations were examined in accordance with the Californian Dental Association (CDA) system for quality evaluation for dental care (CDA 1977).

The biological parameters included mobility of the implant (yes or no), The degree of plaque formation was assessed by Turesky modification of Quigly and Hein plaque index²²: 0, no plaque; 1, small discontinuous flecks of plaque; 2, continuous band up to 1mm of the cervical third; 3, plaque not more than one third of the crown, 4, plaque range from one third to two third of the crown, 5, plaque more than two third of the crown.

The peri-implant gingival index according to Loe and Silness²³ was used in assessing each implant. The maximum degree of inflammation of the gingiva that surrounded the implant was assessed with the following criteria: 0, no inflammation;

1, slight inflammation and slight changes in color and surface, bleeding on probing; 2, moderate inflammation, redness and hyperplasia of the gingiva, and bleeding on pressure; and 3, acute inflammation, highly red and hyperplastic gingiva, tendency to spontaneously bleed and ulcerate.

Probing depths were measured in millimeters from the mucosal/gingival margin to the bottom of the pocket, from the mesial, distal surfaces of the implants. For each implant, the mean probing depth was calculated.

Radiographs of the implants and restorations were made with the long-cone paralleling technique using plates at baseline, and at follow-up visits. The radiographs were analyzed for the presence of continuous peri-implant radiolucency and the location of marginal bone levels around the implants. The marginal bone level of each implant was evaluated and was measured as the distance in 0.1 mm increments from the implant/ abutment border (implant shoulder) to the most coronal point where the marginal bone met the implant. Measurements were made on both the mesial and sides of the implants. From these measurements the mean bone loss was assessed for each implant.

Occlusal contacts between the restoration and opposing teeth were recorded in the maximal intercuspal position (MIP) and at 3mm lateral excursion as present or absent using an 8-mmthick occlusion foil (TrollFoil, Trollh tteplast AB, Trollh ttan, Sweden). Esthetical evaluation was performed by the examiner according to a four-point scale (1= excellent, 4 =very poor).

Questionnaire

The patient judged the appearance and function of the restoration using a VAS-scale (0 not at all satisfied, 100 extremely satisfied). The questionnaire also included questions about awareness of bruxism (tooth grinding/tooth clenching) at night and during the day (every night/day=2, some night/day per week =1, very seldom or never = 0).

Statistical analysis

Descriptive statistics was used for presenting the data. The data were presented as percentage (%) of subjects, mean (M) and standard deviation (SD) values. Regression model using 1-way analysis of variance(ANOVA)was used in testing significance of plaque index, peri-implant gingival index, probing depth and bone loss to implant systems, and their interactions on different implant systems. The significance level was set at $p < 0.05$.

RESULTS

The reasons for the 45 missing teeth to be replaced were : trauma (n =30), root fracture (n=9), other and unknown reasons (n=6). Distribution of 45 single tooth implant restorations by region (Table 1). Most implants (62.2%) were placed in anterior maxilla.

Table (I) Distribution of 45 single tooth implant restorations by region.

Region	Maxilla		Mandible		
	B*	D**	B *	D**	
Incisor	9	8	-	8	
Canine	2	1	-	-	
Premolar	1	3	5	2	
Molar	-	-	5	1	
Total crowns	24		21		45

*Biohorizons implants

** Dentium implants

Table 2 showed the plaque index scores measured on the crowns at baseline and 12 months follow-up examinations. On average the degree of plaque formation on the single-tooth crowns supported by either Biohorizons or Dentium implants was low: degree 0 in 63.6%, 69.6% and degree 1 in 30.4 %, 36.4% in both groups respectively at the baseline. At 4- months, degree 0 in 68.2%,78.3% and degree 1 in 21.8 %,31.8%. At the 8- month, degrees 0 in 82.6%, 88.4%, degree 1 in9.1%,13% and grade

2 in 4.3%,4.5% of the crowns in both groups. At 12-month grade 0 in 82.6%, 86.4% grade 1 in 9.1%, 13.0%and grade 2 in 4.3%,4.5% in both groups.

At baseline and 12 months examinations, The peri-implant gingival index scores were low. The gingival index scores at baseline were degrees 0 in 65.2%,75.7% and 1 in 27.3%, 34.8%, in Biohorizons and Dentium respectively. The gingival index scores at 4-month were degrees 0 in

73.9%,77.3 %and I for 22.7%, 26.1% . At 8-month, grade 0 in 86.4 %,91.3%,grade 1 in 8.7%,9.1 % and grade 2in 0.0%,4.5% . At 12-month, grade 0 and 1 in 91.3%,95.1% and 4.5%,8.7% respectively.

Table 3,4 showed that in Dentium the mean of plaque index was (0.3±0.4) and in gingival index was (0.2±0.3), while in Biohorizons the mean of plaque index was (0.2±0.4) and (0.1±0.4) in gingival index.

Table(2) Percentage of subjects in plaque index, peri-implant gingival inflammation, probing depth and bone loss in Biohorizons and Dentium during follow-up periods.

Measurement	Base line	Four months	Eight months	Twelve months
Plaque index	0.0 1.00	0.0 1.00	0.0 1.00 2.00	0.00 1.00 2.00
Biohorizons	1.6 30.4	68.2 21.8	82.4 9.1 4.3	82.4 9.1 4.3
Dentium	69.6 36.4	78.3 31.7	88.6 13 4.5	86.6 13.0 4.5
Peri-implant gingival index	0,00 1.00	0.00 1.00	0.00 1.00 2.00	0.00 1.00
Biohorizons	65.2 27.3	73.9 22.7	86.4 8.7 0.0	91.3 4.5
Dentium	77.3 34.8	73.9 26.1	91.3 9.1 4.5	95.1 8.7
Probing depth	0-1	0-1	1-1 1-2	0-1 1-2
Biohotizons	100	100	56.5 31.8	52.2 36.4
Dentium	100	100	68.2 43.5	63.6 47.8
Bone loss	<0.5	<0.5	<0.5 >1	<0.5 >1
Biohorizons	100	100	52.2 31.8	43.5 36.4
Dentium	100	100	68.2 47.8	63.6 56.5

Table(3) Mean and standard deviation of different variables in Dentium implant.

	N	Min	Max	Mean	SD
Plaque index	88	0	2	0.3	0.4
Gingival index	88	0	2	0.2	0.3
Probing depth	88	1	2	1.0	0.3
Bone loss	88	1	2	1.0	0.2
Valid N	88				

Table(4) Mean and standard deviation of different variables in Biohorizons implant.

	N	Min	Max	Mean	SD
Plaque index	92	0	2	0.2	0.4
Gingival index	92	0	1	0.1	0.4
Probing depth	92	1	2	0.1	0.4
Bone loss	92	1	2	0.1	0.4
Valid N	92				

Table 5 showed 1-Way ANOVA test which used to compare between groups and within groups, indicated that, the clinical parameters (plaque and peri-implant gingival indexes) measured at the baseline and 12 months follow-up examination showed non significant differences in Biohorizons and Dentium implants ($p > 0.05$).

Table 6 showed, at the baseline and 4-month examination the probing depth values were 0-1 mm in 100% in Biohorizons and Dentium. At 8-month were 0-1 mm and 1-2 mm in 56.5% and 31.8% in Biohorizons, 68.2% and 43.5% in Dentium. At 12-month were 0-1mm and 1-2mm in 52.2%

and 36.4% in Biohorizons, 63.6% and 47.8% in Dentium. The mean of probing depth in Dentium was (1.0 ± 0.3) and in Biohorizons was (0.1 ± 0.4) .

1-way ANOVA analysis results of probing depth Table 3,4 showed that, there was a significant effect on mean values (p -value < 0.05). The mean of probing depth in Dentium implants were (1.0 ± 0.3) while in Biohorizons implants were (0.1 ± 0.4) . Biohorizons implants had significant mean value ($p < 0.05$) compared to Dentium implants. The probing depth in Biohorizons implants lesser than the Dentium implants.

Table(5) 1-way ANOVA showing the effect of different variables in Biohorizon and Dentium implants systems.

	Sum of squares	df	Mean square	F	p-value
Plaque index	0.732	7	0.105	0.444	0.837ns
Between groups	40.468	172	0.35		
Within groups	41.200	179			
Total					
Gingival index	1.781	7	0.254	1.574	0.146ns
Between groups	27.797	172	0.162		
Within groups	29.578	179			
Total					
Probing depth	7.545	7	1.078	8.722	0.001*
Between groups	21.255	172	0,124		
Within groups	28.800	179			
Total					
Bone loss	9.296	7	1.328	10.470	0.001*
Between groups	21.516	172	0,127		
Within groups	31.111	179			
Total					

ns; non-significant (p -value > 0.05), * significant (p -value < 0.05)

Table(6) Mean and standard deviation of Marginal bone loss during 1-year follow –up.

		Mean	SD	t-value	p-value
Biohorizons	Maxilla	1.67	0.492	2.86	0.01*
	Mandible	1.17	0.389		
Dentium	Maxilla	1.80	0.422	3.428	0.003*
	Mandible	1.18	0.405		

* Significant ($p < 0.05$).

The radiologic examination results demonstrated marginal bone loss, at base line and 4-month examination the value were less than 0.5mm in 100% in both implant systems. At 8-month bone loss less than 0.5 in 52.2% and 68.2% in Biohorizons and Dentium. The bone loss more than 1mm in 31.8% and 47.8% respectively. At 8-month bone loss less than 0.5 in 43.5% and more than 1 in 36.4% in Biohorizons. The bone loss less than 0.5 in 63.6% and more than 1 in 56.5% in Dentium. 1-way ANOVA revealed that there was a significant differences (p <0.05) in bone loss in 8-month and 12-month. The bone loss at 12-month higher than 8-month. Table 3,4 showed that, the bone loss in Biohorizons(0.1±0.4) lesser than that in Dentium(1.0±0.2).

The mean marginal bone loss in Dentium in maxilla was(1.80±0.422) and in mandible was (1.18±0.405) there was a significant difference in bone loss (p-value <0.05). In Biohorizons, the mean

marginal bone loss in maxilla was(1.67±0.492) and in mandible was (1.17±0.389) there was a significant differences in bone loss between maxilla and mandible (p-value 0.01) (Table 6) The marginal bone loss was slightly higher (non -significant) in the maxilla for both implant systems than mandible (Table 7).

During the 12- months follow up period, the survival rate was 100% in Biohorizons implant system and 95.6% in Dentium. The titanium screws that attached the abutment to implant were loosened within a few months of insertion of the permanent crown. Both of these two screw loosening occurred in the maxillary anterior region. These problems were resolved by removal of the crown and retightening the screws. During the 12-months follow –up examinations, Subjectively all patients were satisfied with the esthetics and function of their single-tooth restorations supported by either Biohorizons or Dentium implants.

Table (7) Marginal bone loss in maxilla and mandible during 1-year follow- up

		t-value	p-value		t-value	p-value
Biohorizon	Maxilla	0.647	0.508ns	Mandible	0.092	0.928ns
Dentium	Maxilla			Mandible		

ns; non-significant (p>0.05).

DISCUSSION

The results of this study are based on 30 patients who participated in this prospective short-term study. All implant surgeries were performed by one surgeon following the same surgical protocol. This study represents a preliminary comparative evaluation of 22 Biohorizons and 23 Dentium dental implants with custom zirconia abutment for cemented single-tooth restorations.

In this study single-tooth replacements were supported by dental implants of the Dentium and

Biohorizons dental implant systems. The Dentium single-tooth implant is a two-stage implant made of commercially pure titanium. In the Biohorizons system, the abutment is connected to the implant with a titanium abutment screw. Both hollow screw (HS) and hollow cylinder (HC) implants were inserted. For the Biohorizons system the attachment between abutment and implant is secured with a cone-screw connection with laser seal.

As a rule, radiographic findings that reveal continuous peri-implant radiolucency document early implant failure. The clinically stable

implant and healthy soft tissues, confirmed good osseointegration in all implants. Clinical symptoms such as plaque index, peri-implant gingival inflammation, and probing depth are signs of failing implants during the maintenance period. In this study, both implant groups demonstrated non-significant degrees of plaque formation and peri-implant gingival inflammation at the baseline (1 week after the crown placement) and during the 1-year follow-up examinations which indicate good clinical health of the implants. The results from pocket depth measurements indicated that the mean value in Biohorizons was (0.1 ± 0.4), and the mean value in Dentium was (1.0 ± 0.3). 1-way ANOVA revealed that Biohorizons implants had significant mean value ($p < 0.05$) compared to Dentium implants. The probing depth in Biohorizons implants was lesser than the Dentium implants. These values were of the same average magnitude as reported in other single-tooth implant studies.²⁴⁻²⁵

The assessment of changes in marginal bone height is considered an important parameter in evaluating implant success.^{16,19,24} In this study, with the radiographs taken at one week after crown placement as a baseline, There was a statistically significant changes in height of the bone margin between the baseline and 1-year follow-up examinations were observed. The mean value of bone loss in Biohorizons was (0.1 ± 0.4), and (1.0 ± 0.2) in Dentium. The bone loss in Biohorizons lesser than that in Dentium. Implants showed low bone loss values that were similar to those reported earlier for Biohorizons implants.²⁶

Considering the criteria of implant success, in which the marginal bone resorption is ≤ 1 mm in the first year, the preliminary findings of Biohorizons single-tooth implants seem to fall within this success criteria.

The marginal bone loss was more noticed in Dentium implant cases this may be due to the Biohorizons proprietary laser lock technology which scientifically proven to reduce bone loss compared to traditional implants.²⁷

Both systems demonstrated that the average bone loss tended to be slightly higher in the maxilla during the 1-year observation period. This finding might be due to differences in remodeling capacity and remodeling rate between maxillary and mandibular bone. Because of the rich vascular supply and the cancellous character of the maxillary bone, much of the remodeling after implant installation could take place during the healing period, whereas the slower reacting mandibular bone would demand an extended period of time for the same purpose.

The clinical appearance of the peri-implant tissues was more deteriorated in Dentium implant system than the Biohorizons system and this may be due to excessive marginal bone loss. The grit-blasted and/or acid-etched implants had manufacturing methods that create random surfaces that vary from point to point on the implant and alter cell reaction depending on where each cell comes in contact with the surface.²⁸⁻³⁰

The marginal bone loss was less noticed in Biohorizons implant due to Laser-Lok micro channels which is a series of cell-sized circumferential channels that are precisely created using proprietary laser ablation technology. This technology produces extremely consistent micro channels that are optimally sized to attach and organize both osteoblasts and fibroblasts.³¹ The Laser-Lok microstructure also includes a repeating nanostructure that maximizes surface area and enables cell pseudopodia and collagen micro fibrils to interdigitate with the Laser-Lok surface. Our results were comparable with the published results.^{32,33}

In this study, the Dentium titanium screws that attached the abutment to the implant were loosened within a few months of insertion of the permanent crown. Both of these two abutment screw loosening occurred in the maxillary anterior region. That demonstrated inefficacy of the cone-screw connection of the implant and abutment in Dentium implant. Previous studies with other implant systems

have reported that single-tooth implant-supported restorations constitute a potential risk for abutment screw loosening.³⁴

CONCLUSION

The results of this study demonstrated that the short term success of Biohorizons implants that supported single-tooth crowns were excellent. During the observation time of 1 year, the plaque index, peri-implant gingival index, probing depth and marginal bone loss were favorable. The Biohorizons implant is favorable in anterior region of maxilla. Subjectively all patients were satisfied with their single-tooth restorations.

Clinical significance

The favorable clinical results of this short-term study support the potential of Biohorizons dental implants with custom zirconia abutment for cemented single tooth restoration, especially in anterior region of maxilla.

REFERENCE

- Jemt, T., Lekholm, U. & Gröndahl, K. A 3-year follow-up study of early single implant restorations ad modum Bra°nemark. *The International Journal of Periodontics & Restorative Dentistry* 1990;10:341–349.
- Laney, W. R., Jemt, T., Harris, D., Henry, P. J., Krogh, P. H. J., Polizzi, G., Zarb, G. A. & Herrmann, I. Osseointegrated implants for single-tooth replacement: progress report from a multicenter prospective study after 3 years. *The International Journal of Oral & Maxillofacial Implants* 1994; 9: 49–54.
- Henry, P. J., Laney, W. R., Jemt, T., Harris, D., Krogh, P. H. J., Polizzi, G., Zarb, G. A. & Herrmann, I. Osseointegrated implants for single-tooth replacement: a prospective 5-year multicenter study. *The International Journal of Oral & Maxillofacial Implants* 1996;11: 450–455.
- Palmer, R. M., Smith, B. J., Palmer, P. J. & Floyd, P. D. A prospective study of Astra single tooth implants. *Clinical Oral Implants Research* 1997;8: 173–179.
- Palmer, R. M., Palmer, P. J. & Smith, B. J. A 5-year prospective study of Astra single tooth implants. *Clinical Oral Implants Research* 2000;11: 179–182.
- Andersson, B., Ördman, P., Lindvall, A-M. & Bra°nemark, P-I. Cemented single crowns on osseointegrated implants after 5 years: results from a prospective study on CeraOne. *International Journal of Prosthodontics* 1998;11:212–218.
- Scheller, H., Urgell, J. P., Kultje, C., Klineberg, I., Goldberg, P. V., Stevenson-Moore, P., Alonso, J. M., Schaller, M., Corria, R. M., Engquist, B., Toreskog, S., Kastenbaum, F. & Smith, C. R. A 5-year multicenter study on implant-supported single crown restorations. *The International Journal of Oral & Maxillofacial Implants* 1998;13:212–218.
- Schwartz-Arad, D., Samet, N. & Samet, N. Single tooth replacement of missing molars: a retrospective study of 78 implants. *Journal of Periodontology* 1999;70, 449–454
- Bahat, O. Bra°nemark system implants in the posterior maxilla: clinical study of 660 implants followed for 5–12 years. *The International Journal of Oral & Maxillofacial Implants* 2000;15, 646–653.
- Naert, I., Koutsikakis, G., Duyck, J., Quirynen, M., Jacobs, R. & van Steenberghe, D. Biologic outcome of single-implant restorations as tooth replacements: a long-term follow-up study. *Clinical Implant Dentistry and Related Research* 2000; 2:209–218454
- Polizzi, G., Rangert, B., Lekholm, U., Gualini, F. & Lindström, H. Bra°nemark system wide platform implants for single molar replacement: clinical evaluation of prospective and retrospective materials.. *Clinical Implant Dentistry and Related Research* 2000; 2:61–69.
- Gläuser, R., Sailer, I., Wohlwend, A., Studer, S., Schibli, M. & Schärer, P. Experimental zirconia abutments for implant-supported single tooth restorations in esthetically demanding regions: 4-year results of a clinical study. *The International Journal of Prosthodontics* 2004; 17: 285–29
- Canullo, L. Clinical outcome study of customized zirconia abutments for single-implant restorations. *The International Journal of Prosthodontics* 2007; 20: 489–493.
- Zembic, A., Sailer, I., Jung, R.E. & Hammerle, C.H. Randomized-controlled clinical trial of customized zirconia and titanium implant abutments for single-tooth implants in canine and posterior regions: 3-year results. *Clinical Oral Implants Research* 2009; 20: 802–808.
- Nakamura, K., Kanno, T., Milleding, P. & Örtengren, U. Zirconia as a dental implant abutment material: a systematic review. *The International Journal of Prosthodontics* 2010;23: 299–309.

16. Jung, R.E., Pjetursson, B.E., Glauser, R., Zembic, A., Zwahlen, M. & Lang, N.P. A systematic review of the survival and complication rates of implant supported single crowns (SCs) after an observation period of at least 5 years. *Clinical Oral Implants Research* 2008; 19:119–130.
17. Zarb GA, Schimdt A. The longitudinal clinical effectiveness of osseointegrated dental implants: the Toronto study. Part II: the prosthetic results. *J Prosthet Dent* 1990;64:53-61.
18. Weber HP, Kim DM, Ng MW, Hwang JW, Fiorellini JP. Peri- implant soft tissue health surrounding cement and screw retained implant restoration: a multi-center, 3-year prospective study. *J clinical oral implant research* 2006;17:375-9.
19. Andersson B, Odman P, Lindvall AM, Brånemark PI. Cemented single crowns on osseointegrated implants after 5 years: results from a prospective study on CeraOne. *Int J Prosthodont* 1998; 11:212-8.
20. Davarpanah M, Martinez H, Celletti R, Tecucianu JF. Three-stage approach to aesthetic implant restoration: emergence profile concept. *Pract Proced Aesthet Dent*. 2001; 13:761-7; quiz 768, 721-2
21. Berglundh, T., Persson, L. & Klinge, B. A systematic review of the incidence of biological and technical complications in implant dentistry reported in prospective longitudinal studies of at least 5 years. *Journal of Clinical Periodontology* 2002; 29 : 197–212.
22. Gertrude A. Quigley, John W. Hein. Comparative cleansing efficiency of manual and power brushing Original Research Article *The Journal of the American Dental Association*, 1962; 65, 26-29
23. McClanahan SF1, Bartizek RD, Biesbrock A. Identification and consequences of distinct Löe-Silness gingival index examiner styles for the clinical assessment of gingivitis. *J Periodontol*. 2001;72(3):383-92.
24. Roos-Jansa °ker, A.M., Lindahl, C., Renvert, H. & Renvert, S. Nine-to fourteen-year follow-up of implant treatment. *Journal of Clinical Periodontology* 2006; 33: 290–295.
25. HEK Bae, MK Chung, IH Cha, DH Han. Marginal Tissue Response to Different Implant Neck Design. *J Korean Acad Prosthodont*. 2008; 46: 6.
26. GE Pecora, R Ceccarelli, M Bonelli, H Alexander, JL Ricci. Clinical Evaluation of Laser Microtexturing for Soft Tissue and Bone Attachment to Dental Implants. *Implant Dent*. 2009;18:57-66.
27. C Shapoff, B Lahey, P Wasserlauf, D Kim. Radiographic Analysis of Crestal Bone Levels on Laser-Lok® Collar Dental Implants. *Int J Periodontics Restorative Dent* 2010;30:129-137
28. SR Frankel, J Simon, H Alexander, M Dennis, JL Ricci. Osseointegration on metallic implant surfaces: effects of microgeometry and growth factor treatment. *J Biomed Mater Res*. 2002;63: 706-13.
29. BD Boyan, Z Schwartz. Surface Topography Modulates Osteoblast Morphology. *Bone Engineering* (editor: JE Davies). Chapter 21. Published by Em2 Inc., Toronto, Canada. 2000.
30. A Wennerberg, T Albrektsson. Effects of titanium surface topography on bone integration: a systematic review. *Clin Oral Implants Res*. 2009; Sep;20 Suppl 4:172-84.
31. M Nevins, DM Kim, SH Jun, K Guze, P Schupbach, ML Nevins. Histologic Evidence of a Connective Tissue Attachment to Laser Microgrooved Abutments: A Canine Study. *International Journal of Periodontics & Restorative Dentistry*. 2010;30:3.
32. Moraschini, L.A. da C. Poubel, V.F. Ferreira, E. dos S.P. Barboza Evaluation of survival and success rates of dental implants reported in longitudinal studies with a follow-up period of at least 10years: a systematic review Article *Int J of Oral and Maxillofac Surg* In Press, Corrected Proof, Available online 20 November 2014
33. Cehreli MC, Uysal S, Akca K. Marginal bone level changes and prosthetic maintenance of mandibular overdentures supported by 2 implants: a 5-year randomized clinical trial. *Clinic implant Dent Relat Res* 2010; 1:12.
34. Haas R, Mensdorf-Pouilly N, Mailath G, Watzek G, Br-nemark. single tooth implants: A preliminary report of 76 implants. *J Prosthet Dent* 1995;73:274-9.