



Root Resorption Investigated With Con Beam Computed Tomography End of Orthodontic Treatment With Fixed Appliance

Yasser Ali Ahmed Thabet ⁽¹⁾, Abumadyan Nasser Ahmed Aqrabe ⁽¹⁾, Redwan Alaslmy ⁽²⁾
and Mohamed Sobhy Mohamed⁽³⁾,

Codex : 06/1610

dentaljournal.forgirls@yahoo.com

ABSTRACT

Objective: To examine the prevalence of orthodontically induced root resorption after treatment and the correlation with resorption found after 7 months of treatment. **Materials and Methods:** One hundred forty patients (12–19 years) treated with fixed appliances and extraction of four premolars were examined with con beam computed tomography before treatment, after 7 months of treatment (n=87), and at the end of active treatment. The Malmgren Index was used to describe the degree of root resorption. **Results:** Resorption root severe (>2 mm, score 3) was found in 30% of the patients at the end of treatment. Extreme root resorption was found in two patients. Root resorption was seen more frequently in the maxillary incisor region. There was no correlation between the severities of root resorption after 7 months and the amount observed at the end of treatment. **Conclusions:** It was diagnosed significant resorption in clinical in 30% of the patients, but no correlation with the resorption seen after 7 months was found. Radiographic examination after 7 months of orthodontic treatment will not reduce the number of patients who will have teeth with severe root resorption.

INTRODUCTION

Since the 1960's there has been a consensus that orthodontic treatment contributes to external apical root resorption (EARR).⁽¹⁾ In other reported that, the 97.3% of the patients revealed some form of EARR post-treatment.⁽²⁾ The large variation is the result of several factors, including examination methods, definition of root resorption, and type of appliances and forces used.

The literature poses a correlation between root resorption at an early stage of treatment (3–9 months) and the occurrence of severe resorption

1. Associate Professor in Orthodontics Department, Faculty of Dentistry, Ibb University .
2. Associate Professor in Restorative Department, Faculty of Dentistry, Sana'a University.
3. Professor in Removable Prosthodontics Department, Faculty of Dentistry, Gazan University.

at the end of orthodontic treatment⁽³⁻⁵⁾. In a study, they stated that the average root-shortening due to orthodontic tooth movement is approximately 10%, and it ranges from 1,2 -1,5 mm.⁽⁶⁾ A shortening of the total root length of 10% will in most cases not cause any problems for the tooth's function. This is possibly because most of the periodontal ligament (PDL)-fibers are in the upper 2/3 of the root.⁽⁷⁾

The severity can however, be grouped into different stages as described⁽⁸⁾. An index-score from 1-4 is often preferred (fig.1).

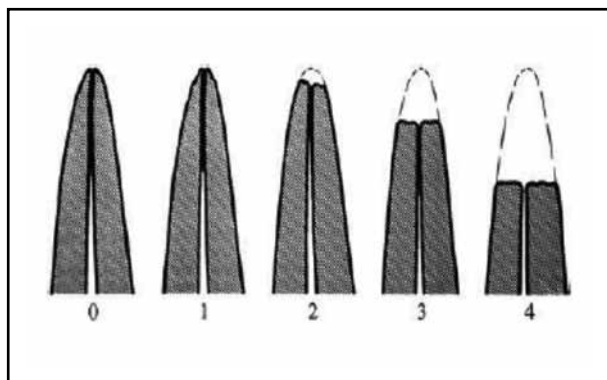


Fig. (1) Root resorption index according to Levander, 1999(8).

1. Irregular root contour.
2. Root resorption apically, less than 2mm. (Minor).
3. Root resorption apically, from 2mm- 1/3 of the root's length (Severe).
4. Root resorption exceeding 1/3 of the root's original length (Extreme).

When the EARR becomes severe, (reaches score 3 or 4) there is reason for concern. The numbers of reported severe EARR vary considerably in the literature. There was a report that 16, 5% of the patients in their study suffered from severe EARR post-treatment,⁽⁹⁾ In other report they found an incidence of severe EARR of approximately 40%.⁽¹⁰⁾ Whenever there is severe EARR, the longevity of the tooth may be compromised, and this is one of the most troubling complications for orthodontists.

Radiography is the most commonly used tool for diagnosing root resorption. Panoramic imaging, also called pantomography, is a technique that produces a single tomographic picture of the facial structures

and surrounding structures, and has a broad covering of both jaws. The images are not high resolution images, so sharp details cannot be studied as with periapicals. The radiation dose though is quite low, and the procedure is usually well tolerated by the patient.⁽¹¹⁻¹³⁾

Today, most orthodontists require an cone beam computed tomography (CBCT) was introduced in the late 1990s,^(14,15) and studies generally show lower radiation doses from CBCT units than from conventional CT examinations.^(16,17) The CBCT technique, in combination with multiplanar reconstructions, has the advantage of optimal visualization of each tooth position that occur during orthodontic treatment,⁽²⁰⁾ thus enhancing reproducibility. The aims of the present study are therefore, to: (1) investigate the prevalence and degree of EARR after treatment with fixed appliances in all permanent teeth, from first molar to first molar; and (2) investigate the correlation of the severity of root resorption with that seen after 7 months of treatment.

MATERIALS AND METHODS

Subjects

CBCT investigation is routinely performed on orthodontic patients at the United Dental and Orthodontics Clinic in Yemen republic. Radiographs of consecutive incoming patients from February 2012 to July 2015 were used for the purposes of this study. The patients had to meet pre-defined inclusion criteria: age 12–19 years, Class I malocclusion, Class II malocclusion, crowding, and overjet <5 mm. Further, the treatment plan should comprise extraction of one premolar in each quadrant. One hundred sixty-three patients agreed to take part in the investigation, and at the end of the study 140 patients (79 female, 61 male) remained in the study. A randomized subsample of 87 patients (51 female, 36 male) also underwent a radiographic examination 7 months after the start of their orthodontic treatment. The mean age of the patients was 16.3 years (standard deviation [SD] 1.64 years; range,

12.0–19.2 years) and the mean treatment time was 19.4 months (SD 4.6 months).

CBCT Examination

CBCT was used on all subjects before and after treatment; CBCT was also performed in 87 randomly selected patients after 7 months of treatment. Tooth length was measured in millimeters on the

reformatted images parallel to the long axis of the tooth/root and then converted into an index (Figure 1) originally designed for intraoral radiography⁽⁸⁾. Only a few roots were unscorable at one or two assessments, but the distal root of the lower first molar was, in many cases, outside the imaged volume (Table 1). All assessments were made by one independent, blinded examiner.

ROOT RESORPTION DIAGNOSED WITH CBCT

Table (1) *Percentage of Teeth with a Root Resorption score of 2 or more at the End of Orthodontic Treatment in 140 patients*

| Tooth no.™ | N | Score 2 (%) | Score 3 (%) | Score 4 (%) |
|------------|-----|-------------|-------------|-------------|
| 16/26 | 290 | 6.7 | | |
| 15/25 | 300 | 6.4 | 1.2 | |
| 13/23 | 310 | 7.3 | 3.5 | |
| 12/22 | 311 | 40.0 | 37.2 | 10.6 |
| 11/21 | 313 | 31.5 | 9.7 | 0.7 |
| 36/46d | 223 | 3.7 | | |
| 36/46m | 295 | 3.4 | | |
| 35/45 | 282 | 3.8 | 0.3 | |
| 33/43 | 305 | 7.2 | 4.5 | |
| 32/32 | 317 | 21.5 | 18.9 | 1.4 |
| 31/41 | 298 | 13.9 | 2.8 | 3.2 |

FDI tooth-numbering system used; lower molars are presented with both mesial (m) and distal (d) roots because of the higher Number of unscorable distal roots.

Statistics

The relationship between resorption after 7 months of treatment and at the end of treatment was analyzed with Spearman’s rank correlation analysis. Analysis of variance was used to evaluate resorption at end of treatment in conjunction with the number of teeth affected and duration of treatment. P > .5 was considered not statistically significant.

RESULTS

Root resorption was considered to be present only if a score of 2 or higher was registered. (Fig.2) shows the distribution of root-resorbed teeth according to the counts in each tooth group seen at the end of treatment, and Table 1 presents the percentages of resorbed teeth. The extent of root resorption was significantly larger (P < .05) in the maxilla than in the mandible, and EARR was more common in anterior teeth than in posterior teeth (Figure 2).

At the end of treatment, minor resorption (score 2) was noted in 78 patients (55.7%), severe

resorption(score 3) was found in 42 patients (30.0%), and extreme resorption (score 4) was found in the lower jaw in one patient. In the lower jaw, severe root resorption (score 3) was detected in seven patients and the most susceptible tooth was the canine, while moderate root resorption (score 2) was most prevalent in the lower incisors. Root resorption was also seen on the posterior teeth, and a score of 2 was reported in several first molars: 10 upper rights, 6 upper left, 8 lower left, and 5 lower rights. No correlation was found between the severity of root resorption at 7 months and that at the end of treatment ($R=0.05, P=NS$),and there was no relationship between the length of treatment and the severity of

root resorption found inthe patients (Fig.3).

Progression of Root Resorption from 7 Months to End of Treatment

In the five patients with the most severe resorption,the condition was unchanged in four subjects and worsened in one by the end of treatment. In the 12 cases with moderate resorption, the severity increased in four patients and was unchanged in eight. In the 72 patients where no noticeable resorption was seen after 7 months, 56 had developed a resorption score of 2 or higher by the end of treatment (Fig. 4).

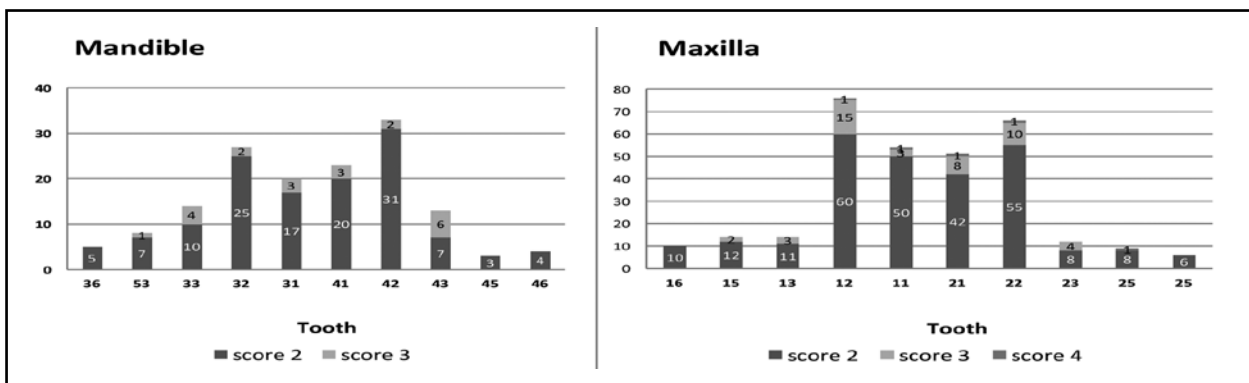
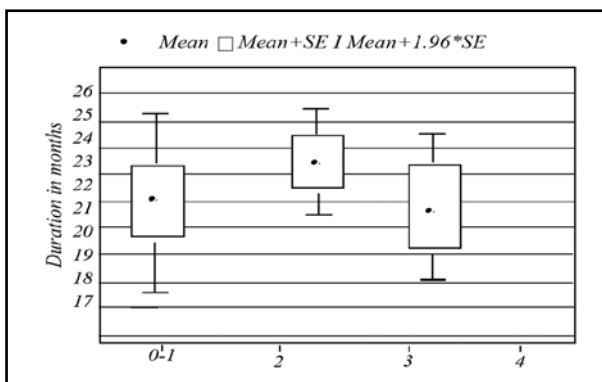


Fig. (2) Distribution of root resorbed teeth (scores 2-4) according to the counts in each tooth group at the end of treatment.



Root resorption at end of treatment (score 0-4).

Fig. (3) Distribution of patients with different resorption scores in relation to the treatment duration.




Figure (4) Flowchart of patients with different root resorption scores at 7 months and change until the end of treatment.

DISCUSSION

Methods radiographic for assessing root length cannot reliably compensate for inherent radiographic distortion,^(12,13) and several studies have demonstrated that conventional intraoral radiography is not a reliable technique for detecting external root resorption in its early stages.^(18,19) To minimize their errors in radiographic evaluation, this study design included the use of CBCT.

Resorption at the end of treatment was almost only seen in the upper incisor region, in agreement with clinical experience, but rarely shown with appropriate methods⁶ apart from a previous publication of the same material⁽²⁰⁾ and a few older studies⁽²¹⁾ and a recent study.⁽²²⁾ Most studies investigating root resorption have focused on the upper incisors.^(23, 26) In other place they found, using a CBCT appliance and root resorption index, moderate root resorption in 19% of the examined teeth, and two maxillary anterior teeth (1%) displayed severe resorption at the end of treatment. The corresponding values in the present study were 16% and 4%. However, the present study is the first one to be conducted in the country of Yemen.⁽²²⁾ Present finding of another study was that there was no correlation between treatment duration and the severity of root resorption. This is in agreement with the results of some studies and contradicts others.⁽²⁷⁾ One explanation of the lack of agreement may be that the current patient sample was fairly homogenous and the amount of tooth movement was fairly similar.

The current and earlier¹⁶ studies confirmed, in agreement with other studies,^(4,5) that some patients developed EARR during the first stage of treatment with fixed appliances. However, we could not confirm any correlation between the degree of resorption at 6 months and that seen at the end of treatment (Fig. 4). Of the five subjects with the most severe resorption (score 3) seen after 7 months of treatment, a temporary halt of 3 months was performed in four

of them. However, even in one of the patients whose treatment was temporarily halted, the resorption continued, and extreme resorption (score 4) was diagnosed at the end of treatment. Twenty of the

25 patients (of those examined at 7 months) who had teeth with severe resorption (score 3) at the end of treatment did not show any tendency toward root resorption after 7 months (Fig. 4).

The results of this study clearly demonstrate that there is no advantage in taking radiographs as early as after 7 months of treatment to reduce the number of patients with severe or extreme root resorption. Radiographs at 7 months only expose patients to unnecessary radiation. Intermediate radiographs, if used, should be obtained at a later stage of treatment; perhaps 1 year after the start of an orthodontic treatment would be feasible. The results of this study also show that one or two radiographs of the upper incisors should be sufficient for detecting resorption of the most vulnerable teeth. However; even then, it is uncertain whether severe root resorption can be avoided.

CONCLUSIONS

- In the end of orthodontic treatment, minor resorption (score 2) was noted in 78 patients (55.7%), severe resorption (score 3) was found in 42 patients (30.0%), and extreme resorption (score 4) was found in only one patient.
- There was no correlation between the severity of root resorption seen after 7 months and the findings at the end of treatment.
- Treatment duration did not have any impact on the amount of resorption at the end of treatment.
- Radiographic examination after 4–7 months of orthodontic treatment is too early and will not reduce the number of patients who will have severe root resorption.

REFERENCES

1. DeShields. A study of root resorption in treated class II, div. 1 malocclusions. *Angle Orthod.* 1969; 39: 231-45.
2. Thongudomporn U, Freer TJ. Anomalous dental morphology and root resorption during orthodontic treatment: a pilot study. *Aust J Orthod.* 1998; 15: 162-72.
3. Weltman B, Vig KW, Fields HW, Shanker S, Kaizar EE. Root resorption associated with orthodontic tooth movement: a systematic review. *Am J Orthod Dentofacial Orthop.* 2010; 137(4):462-76.
4. Smale I, Artun J, Behbehani F, Doppel D, van't Hof M, Kuijpers-Jagtman AM. Apical root resorption 6 months after initiation of fixed orthodontic appliance therapy. *Am J Orthod Dentofacial Orthop.* 2005 Jul; 128(1):57-67.
5. Levander E, Malmgren O. Evaluation of the risk of root resorption during orthodontic treatment: a study of upper incisors. *Eur J Orthod.* 1988 Feb; 10(1):30-38.
6. Sameshima GT, Sinclair PM. Characteristics of patients with severe root resorption. *Orthod Craniofacial Research* 2004; 7: 108-14.
7. Henry, Weinman. The pattern of root resorption and repair of human cementum. *J Am Dental Association* 1951; 42: 270-90.
8. Levander E. Studies on orthodontically- induced apical root resorption. Thesis, Karolinska Institutet 1999.
9. Linge BO, Linge L. Apical root resorption in upper anterior teeth. *Eur J Orthod.* 1983; 5: 173-83.
10. Thongudomporn U, Freer TJ. Anomalous dental morphology and root resorption during orthodontic treatment: a pilot study. *Aust J Orthod.* 1998; 15: 162-72.
11. Stratomas S, Geenty JP, Petocz P, Darendeliler MA. Accuracy of linear and angular measurements on panoramic radiographs taken at various positions in vitro. *Eur J Orthod.* 2002; 24: 43-52.
12. Katona TR. Flaws in root resorption assessment algorithms: role of tooth shape. *Am J Orthod Dentofacial Orthop.* 2006; 130(6): 619-27 & 698.
13. Katona TR. The flaws in tooth root resorption assessment algorithms: the role of source position. *Dentomaxillofac Radiol.* 2007; 36(6):311-16.
14. Arai Y, Tammsalo E, Iwai K, Hashimoto K, Shinoda K. development of a compact computed tomographic apparatus for dental use. *Dentomaxillofac Radiol.* 1999 Jul; 28(4):245-48.
15. Mozzo P, Proccacci C, Tacconi A, Martini PT, Andreis IA. A new volumetric CT machine for dental imaging based on the can-beam technique: preliminary result. *Eur Radiol.* 1998; 8(9):1558-64.
16. Schulze D, Heiland M, Thurmman H, Adam G. Radiation exposure during midfacial imaging using 4- and 16-slice computed tomography, cone beam computed tomography system and conventional radiography. *Dentomaxillofac Radiol.* 2004 Mar; 33(2):83-86.
17. Tsiklakis K, Donta C, Ggavala S, Karayianni K, Kamenopoulou V, Hourdakakis CJ. Dose reduction in maxillofacial imaging using low dose cone beam CT. *Eur J Radiol.* 2005 Dec; 56(3):413-17.
18. Chapnick L. External root resorption: an experimental radiographic evaluation. *Oral Surg Oral Med Oral Pathol.* May 1989; 67(5):578-82.
19. Andreasen FM, Sewerin I, Mandel U, Andreasen JO. Radiographic assessment of simulated root resorption cavities. *Endod Dent Traumatol.* 1987 Feb; 3(1):21-27.
20. Lund H, Gro'ndahl K, Hansen K, Gro'ndahl HG. Apical root resorption during orthodontic treatment. *Angle Orthod.* 2012 May; 82(3):480-87.
21. Goldson L, Henrikson CO. Root resorption during Begg treatment; a longitudinal roentgenologic study. *Am J Orthod.* 1975 Jul; 68(1):55-66.
22. Dudic A, Giannopoulou C, Leuzinger M, Kiliaridis S. Detection of apical root resorption after orthodontic treatment by using panoramic radiography and cone-beam computed tomography of super-high resolution. *Am J Orthod Dentofacial Orthop.* 2009 Apr; 135(4):434-37.
23. Blake M, Woodside DG, Pharoah MJ. A radiographic comparison of apical root resorption after orthodontic treatment with the edgewise and Speed appliances. *Am J Orthod Dentofacial Orthop.* 1995 Jul; 108(1):76-84.
24. DeShields RW. A study of root resorption in treated Class II, Division I malocclusions. *Angle Orthod.* 1969 Oct; 39(4):231-45.
25. Mavragani M, Boe OE, Wisth PJ, Selvig KA. Changes in root length during orthodontic treatment: advantages for immature teeth. *Eur J Orthod.* 2002 Feb; 24(1):91-97.
26. Taithongchai R, Sookkorn K, Killiany DM. Facial and dentoalveolar structure and the prediction of apical root shortening. *Am J Orthod Dentofacial Orthop.* 1996 Sep; 110(3):296-02.
27. Weltman B, Vig KW, Fields HW, Shanker S, Kaizar EE. Root resorption associated with orthodontic tooth movement: a systematic review. *Am J Orthod Dentofacial Orthop.* 2010; 137(4):462-76.