



The Effect of Demineralized Dentin Matrix Graft alone and Combined with Statin and Propolis on Bone Repair. (A Histological Study)

Mena F. Abd-Allah⁽¹⁾, Mona H. M. Farid⁽²⁾, Nahed S. Korany⁽³⁾ and Heba A. Adawy⁽⁴⁾

Codex : 01/1610

dentaljournal.forgirls@yahoo.com

Paper extracted from doctor thesis entitled "The Effect of Demineralized Dentin Matrix Graft alone and Combined with Statin and Propolis on Bone Repair. (A Histological and Scanning Electron Microscopic Study)"

KEYWORDS

Bone repair, demineralized dentin matrix, statin, propolis.

ABSTRACT

Aim: The aim of the present study was to evaluate the effect of demineralized human dentin matrix graft alone and when combined with statin and propolis on bone repair in bone defects in the tibia of rabbits histologically. **Materials and Methods** Fifteen adult male rabbits (weight 2 to 2.5 kg) were used in this study. In each rabbit four holes were created (two in each tibia), one was left empty as control, the second was packed with DDM slices, the third was packed with DDM slices saturated with statin and the last one was packed with DDM mixed with propolis. The animals were sacrificed at 2, 4 and 6 weeks postoperatively and the bone specimens were processed for histological analysis. **Results:** There was a significant increase in the newly formed bone tissue in DHDM and DHDM/statin groups and the DHDM/statin group presented excellent organization of the formed bone. **Conclusion:** The DHDM was biocompatible with the bone repair and stimulated bone tissue formation. Addition of statin markedly accelerated the bone repair while propolis caused delay in the early stages of repair.

INTRODUCTION

The three essential elements for tissue regeneration are a scaffold, cells and growth factors to act on these cells⁽¹⁾. Demineralized human dentin matrix (DHDM) has got several advantages such as processing easiness, relatively low cost, biocompatibility and ability to stimulate angiogenesis and bone formation^(2,3). The delayed inductive properties of the calcified dentin and bone may be related to the inhibition of BMPs-release by hydroxyapatite (HAp) crystals⁽⁴⁾. Completely DDM induced bone formation in rabbit muscle at only 4 weeks, while calcified

1. Assistant Lecturer of Oral and Dental Biology, Faculty of Dental Medicine for Girls, Al- Azhar University.
2. Professor and Head of Oral and Dental Biology Department, the Former Dean of Faculty of Dental Medicine for Girls, Al- Azhar University.
3. Professor of Oral Biology and Vice Dean of Faculty of Oral and Dental Medicine, Cairo University
4. Assistant Professor of Oral and Dental Biology, Faculty of Dental Medicine for Girls, Al- Azhar University.

dentin needed 8-12 weeks after implantation^(5,6). Radiographic and histomorphometric studies of autogenous demineralized dentin matrix (ADDM) on repair of bony defects in parietal bones and mandibles of rabbits showed that the ADDM slices accelerated bone repair compared to the control groups. And ADDM was completely incorporated in the newly formed bone tissue and resorbed during the bone remodeling process^(7,8). The use of allogenic DDM resulted in heterotopic bone formation of allogenic DDM and no signs of inflammation or graft rejection occurred⁽⁹⁾. Human DDM was used as a xenograft and it had increased expression of vasoendothelial growth factor (VEGF) and accelerated the healing process in rats tooth sockets⁽²⁾.

Statins are cholesterol lowering drugs used for treatment of hyperlipidemia and arteriosclerosis. They are specific, competitive inhibitors of the 3-hydroxy-3-methylglutaryl coenzyme A (HMG-CoA) reductase enzyme.⁽¹⁰⁻¹³⁾ Lovastatin and simvastatin had stimulating effect on the BMP-2 promoter resulting in a strong positive effect on bone formation⁽¹⁴⁾. In addition, both simvastatin and pitavastatin increased human osteoblast differentiation respectively as measured by alkaline phosphatase expression and mineralization or expression of BMP-2 and osteocalcin^(15,16). In addition to osteoblastic differentiation, statins may also inhibit bone resorption⁽¹⁷⁾. The stimulating effect of local simvastatin on bone formation was reported in rat clavalial defects and incisal sockets^(18,19).

Propolis has a complex composition and the proportions of the various materials found in the propolis are related to the place and time of collection. In general, raw propolis is composed of around 50% resins, 30% waxes, 10% essential oils, 5% pollen and 5% of various organic compounds. It has antibacterial, antifungal, antiviral, antioxidant and anti-inflammatory properties⁽²⁰⁻²²⁾. Systemic administration of propolis reduced the periodontitis-related alveolar bone loss in rats⁽²³⁾. Another study on systemically given propolis on fracture healing

revealed that, the bone mineral density was higher and the radiological and histological evaluation scores were better than the controls⁽²⁴⁾. On the other hand, topical application of propolis hydroalcoholic solution accelerated wound healing with no effect on socket healing⁽²⁵⁾.

Bone repair has several histological patterns including: *endochondral bone repair* occurs in an environment of interfragmentary space and mobility, *primary bone repair* occurs in an environment of no interfragmentary space and rigid stability and *direct bone repair* without a cartilage phase occurs in an environment of interfragmentary space > 0.1 mm with rigid stability⁽²⁶⁾.

Some studies about the effect of DHDM on bone repair were conducted but few if any were available about the effects of DHDM when used with statins and propolis, so these effects had been investigated in this study. The aim of the present study was directed to evaluate the effect of demineralized human dentin matrix graft alone and when combined with statin and propolis on bone repair in bone defects in the tibia of rabbits histologically.

MATERIALS AND METHODS:

1-DHDM preparation

DHDM was obtained from human teeth without carious lesion or other pathology. The roots were cut and cleaned from dental pulp and periodontal ligament⁽²⁾. Teeth roots were washed with saline at 2°C and then immersed in the 0.6N-hydrochloric acid solution at 2°C until complete demineralization (from 15-30 days). The specimens were then washed with distilled water for total acid removal and then cut into slices with frozen microtomy (Cryostat). These slices were immersed in a box filled with ethyl alcohol 70° ethyl alcohol and stored at 2°C until use within one month⁽³⁾.

2- Statin

Statin solution was obtained by dissolving 10 mg simvastatin (Zocor® tablet, MERCK & CO,

Inc, NJ, USA) in water for injection to the concentration of 2.5 mg/ml. The grafts were prepared 15 minutes before grafting by immersing DDM slices in statin solution.

3-Propolis

Propolis was obtained in liquid form (AL- Asal AL Barey CO, Kingdom Saudi Arabia). One drop was mixed with DDM graft and another one was added over the surface of the defect after graft insertion.

4-Animal Model

Fifteen adult male rabbits (weight 2 to 2.5 kg) were used in this study. They were caged individually in a specially designed wire cages and were fed standard rabbit chows plus water ad-libitum.

5-Surgical experimental design procedure

The surgical procedures were done after intramuscular administration of anaesthetic solution of ketamine (50 mg/kg) and Xylazin (20 mg/kg). Prior to surgery, the skin was shaved and next cleaned with a mixture of iodine and 70% ethanol. The upper part of the tibia was exposed by making a 5 cm linear incision through the skin, fascia and periosteum in the medial surface of the tibia. Sterile round burs no. 4 were used to create two holes in each tibia, under sufficient coolant, by means of turbine powered hand piece. In the left tibia, two holes were drilled; one was left empty and used as control, while the DDM slices were packed in the other. In the right tibia, two holes were drilled; one was packed with DDM slices saturated with statin and the other was packed with DDM mixed with propolis. Five animals were sacrificed at 2, 4 and 6 weeks postoperatively. The bone segments containing the created defects were removed and the specimens were divided in control, DDM, DDM/statin and DDM/propolis groups. Specimens were fixed in 10% calcium formol, decalcified in EDTA and processed for H&E stain for histological analysis.

RESULTS

After 2 weeks, the holes of control group appeared covered with bony cap formed of irregular newly formed bone trabeculae and the bone defect was filled by connective tissue and some bone trabeculae while the holes grafted with DDM alone demonstrated more pronounced bone formation through the whole defect in addition to the formation of new bone on the periosteal and endosteal surfaces of adjacent old pre-existing bone. Bone matrix appeared deposited on the surface of DDM and in its surrounding fibrous tissue. The DDM and statin group demonstrated pronounced bone formation where the new bone trabeculae were thicker than those in the DDM group. The holes of DDM and propolis appeared closed by fibrous tissue enclosing the DDM slices and the deposition of new bone trabeculae was seen in the deep part adjacent to bone marrow and close to the old pre-existing bone. (Fig. 1)

After 4 weeks, the control holes appeared covered with thick bony cap containing several new osteons surrounded by marked spaces and the DDM holes appeared filled by new bone containing typical compacted osteons with few wide spaces in the middle part. The DDM/statin holes were filled with well organized bone and active bone remodeling was observed while the holes grafted with DDM and propolis were filled by disorganized new bone containing numerous islands of woven bone. (Fig. 2)

After 6 weeks all the holes were filled with bone which appeared not organized in the control group, well organized with clear remodeling in DDM group, similar to normal bone in DDM/statin group and in DDM/propolis the cortical bone showed multiple variable sized and shaped marrow cavities and was covered by thick periosteum.

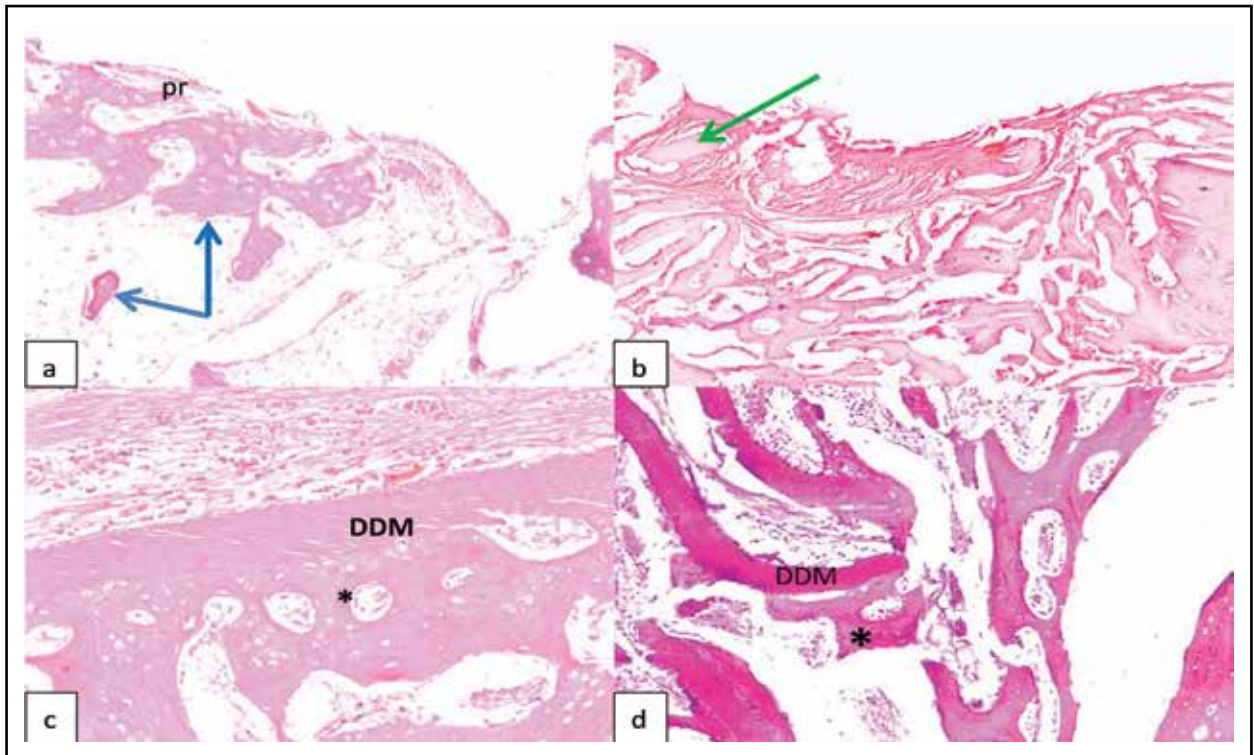


Fig. (1) Photomicrographs at 2 weeks of a) the control group, b) the DDM group, c) the DDM/statin group and d) the DDM/propolis group showing: new bone trabeculae in control (blue arrows), DDM slices surrounded by fibrous tissue in DDM group (green arrow) and new bone trabeculae (asterisk) on the surface of DDM (DDM) in DDM/statin & DDM/propolis groups. (H&E Orig. Mag. X100)

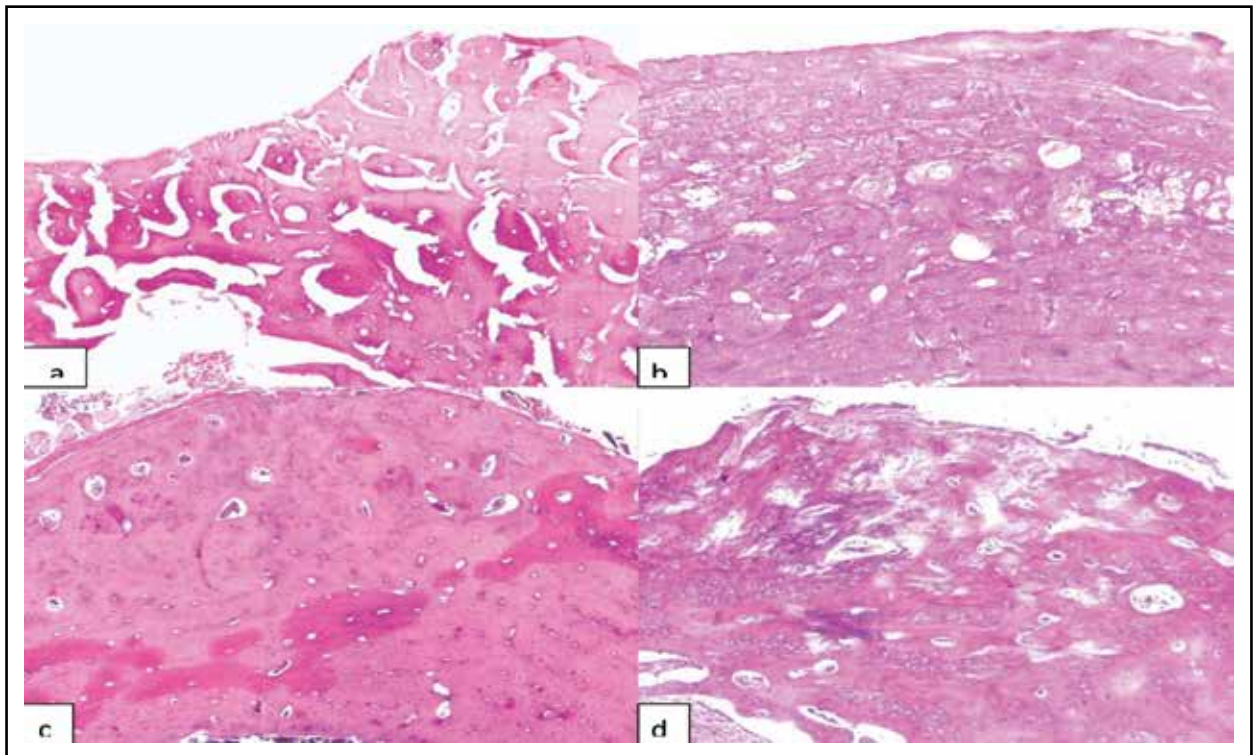


Fig. (2) Photomicrographs at 4 weeks of a) the control group, b) the DDM group, c) the DDM/statin group and d) the DDM/propolis group (H&E Orig. Mag. X40)

DISCUSSION

Rabbit is one of the most commonly used animal models, and it ranks first among all the animals used for musculoskeletal research⁽²⁷⁾. It was reported that there was similarity in bone mineral density between rabbits and human⁽²⁸⁾. In the present study, DHDM was used as xenograft in bone defects of rabbits and showed proper biocompatibility appeared in the incorporation of the DHDM graft to the newly formed bone tissue with negligible host immune reaction. This was in accordance with several previous studies which used DHDM as xenograft or allograft for bone reconstruction in oral surgery and bone defects with high success rate, despite the antigenic potentiality of this type of graft^(2,29,30).

The source of repair cells following a fracture or osteotomy of bone can be from the inner osteogenic layer of the periosteum, the osteoprogenitor cells associated with the blood vessels of the Haversian systems of exposed bone, the endosteal cells (endosteum) lining the inner cortex, the undifferentiated mesenchymal cells of the bone marrow, and (according to some) the “soft tissue” undifferentiated cells of the surrounding muscle and connective tissue based on their ability to differentiate as needed⁽²⁶⁾. DDM samples at 2 weeks showed a common finding which was the encapsulation of DDM slices by fibrous tissue forming some plaques and bone matrix was deposited on the surface of the DDM slices and in their surrounding fibrous tissue. These observations were running with previous studies which described intense attraction of the demineralized dentin for fibroblasts and within 24 hours fibroblasts surrounded the graft and fused with its surface^(4,31). According to these studies, there was induction of alkaline phosphatase not only in the enveloping fibroblasts but also, in their neighbors at some distance from the transplant so they thought that DDM had transformed fibroblasts into osteoblasts which laid down bone matrix. At 2 weeks DDM group showed pronounced new bone formation through the whole and also bone was formed on the periosteal and the endosteal surfaces of the adja-

cent old pre-existing bone which might be the result of stimulation of the osteogenic cells in the periosteum and endosteum. Some authors believe that the use of slices of DDM as a graft induces a neovascularization inside the bone defect and that undifferentiated mesenchymal cells in the perivascular region of the newly formed vessels could be induced to differentiate into osteoblasts by the action of growth factors such as BMP from the DDM^(7,8).

When DDM graft was combined with statin, bone formation became more evident than DDM alone. These positive results are in agreement with and support the findings of several previous studies about the osteogenetic activity of statin^(14,18,19). The basic mechanistic findings have suggested that the statins exert their bone anabolic effects by differentiating mesenchymal cells into osteoblasts via up-regulating BMP-2 and protecting osteoblasts from apoptosis.⁽³²⁾ In addition, statins have been suggested to be anti-osteoclastic by reducing the osteoclast differentiation and activity^(33,34). Statins also produced increased proliferation and differentiation of progenitors of endothelial cells providing new vessels required for new bone formation⁽³⁵⁾.

Addition of propolis to the DDM graft in the same group caused marked delay in bone formation through the defect where the DDM slices appeared surrounded by dense fibrous tissue. Bone matrix deposition on the surface of DDM slices was seen only in the depth of the defect and adjacent to the old bone (near to the bone marrow or adjacent vessels of old bone as a source of blood supply). The absence of positive effect of topical propolis on bone repair was demonstrated in previous studies where propolis produced no effect on socket wound healing and critical bone defects in rats^(25,36). Propolis showed strong suppressive effects against VEGF-induced angiogenesis⁽³⁷⁾. This may be responsible for the delay in the osteogenic action of DDM in the defect area away from the bone marrow or blood supply. Also, the anti-inflammatory effect of propolis may retard bone repair as the inflammatory stage is the first during bone repair⁽³⁸⁾.

The results obtained from the current study proved the positive effect of DHDM on bone repair and the combination of statin with DHDM resulted in synergistic effect that greatly promoted bone healing. On the other hand, topical application of propolis with DHDM resulted in marked delay in bone repair in the initial stage

REFERENCES

1. Yagihashi K, Miyazawa K, Togari K, Goto S. Demineralized dentin matrix acts as a scaffold for repair of articular cartilage defects. *Calcif Tissue Int.* 2009, 84:210-20.
2. Reis-Filho C, Silva E, Martins A, Pessoa F, Gomes P, et al. Demineralized human dentine matrix stimulates the expression of VEGF and accelerates the bone repair in tooth sockets of rats. *Arch Oral Biol.* 2012, 57: 469-76.
3. Almeida J, Alves J. Efeito da matriz dentinária humana no reparo alveolar de ratos: avaliação histológica e imunohistoquímica. *RGO.* 2007, 2:133-38.
4. Huggins C, Wiseman S, Reddi A. Transformation of fibroblasts by allogeneic and xenogeneic transplants of demineralized tooth and bone. *J Exp Med.* 1970, 132:1250-58.
5. Bang G, Urist M. Bone induction in excavation chambers in matrix of decalcified dentin. *Arch Surg.* 1967, 94:781-89.
6. Yeomans J, Urist M. Bone induction by decalcified dentine implanted into oral, osseous and muscle tissues. *Arch Oral Biol.* 1967, 12: 999-1008.
7. Gomes M, dos Anjos M, Nogueira T, Guimaraes S. Autogenous demineralized dentin matrix for tissue engineering applications: radiographic and histomorphometric studies. *Int J Oral Maxillofac Implants.* 2002, 17:488-97.
8. Carvalho V, Tosello D, Salgado M, Gomes M. Histomorphometric analysis of homogenous demineralized dentin matrix as osteopromotive material in rabbit mandibles. *Int J Oral Maxillofac Implants.* 2004, 19:679-86.
9. Bang G. Induction of heterotopic bone formation by demineralized dentin in guinea pigs: antigenicity of the dentin matrix. *J Oral Pathol.* 1972, 1:172-85.
10. Todd P, Goa K. Simvastatin. A review of its pharmacological properties and therapeutic potential in hypercholesterolaemia. *Drugs.* 1990, 40:583-607.
11. Kishida Y, Naito A, Iwado S, Terahara A, Tsujita Y. Research and development of pravastatin. *Yakugaku Zasshi.* 1991, 111:469-87.
12. Henwood J, Heel R. Lovastatin. A preliminary review of its pharmacodynamic properties and therapeutic use in hyperlipidaemia. *Drugs.* 1988, 36:429-54.
13. Hunninghake D. Therapeutic efficacy of the lipid-lowering armamentarium: the clinical benefits of aggressive lipid-lowering therapy. *Am J Med.* 1998, 104:9-13.
14. Mundy G, Garrett R, Harris S, Chan J, Chen D, et al. Stimulation of bone formation in vitro and in rodents by statins. *Sci.* 1999, 286:1946-49.
15. Maeda T, Matsunuma A, Kawane T, Horiuchi N. Simvastatin promotes osteoblast differentiation and mineralization in MC3T3-E1 cells. *Biochem Biophys Res Commun.* 2001, 280:874-77.
16. Ohnaka K, Shimoda S, Nawata H, Shimokawa H, Kaibuchi K, et al. Pitavastatin enhanced bmp-2 and osteocalcin expression by inhibition of rho-associated kinase in human osteoblasts. *Biochem Biophys Res Commun.* 2001, 287:337-42.
17. Tsartsalis A, Dokos C, Kaiafa G, Tsartsalis D, Antonios K, et al. Statins, bone formation and osteoporosis: hope or hype? *Hormones.* 2012, 11:126-39.
18. Thylin M, McConnell J, Schmid M, Reckling R, Ojha J, et al. Effects of simvastatin gels on murine calvarial bone. *J Periodont.* 2002, 73: 1141-48.
19. Sato D, Nishimura K, Ishioka T, Kondo H, Kuroda S, Kasugai S. Local application of simvastatin to rat incisor socket: carrier-dependent effect on bone augmentation. *J Oral Tissue Engin.* 2005, 2: 76-80.
20. Molan P. Why honey is effective as a medicine. The scientific explanation of its effects. *Bee World.* 2001, 82: 22-40.
21. Park Y, Alencar S, Aguiar M. Botanical origin and chemical composition of Brazilian propolis. *J. Agric. Food Chem.* 2002, 50: 2502-6.
22. Almas K, Dahlan A, Mahmoud A. Propolis as a natural remedy: An update. *Saudi Dental J.* 2001, 13: 45-49.
23. Toker H, Ozan F, Ozer H, Ozdemir H, Eren K, et al. A morphometric and histopathologic evaluation of the effects of propolis on alveolar bone loss in experimental periodontitis in rats. *Periodontol.* 2008, 79: 1089-94.
24. Guney A, Karaman I, Oner M, Yerer M. Effects of propolis on fracture healing: an experimental study. *Phytother Res.* 2011, 25:1648-52.
25. Magro Filho O, de Carvalho A. Application of propolis to dental sockets and skin wounds. *J. Nihon Univ. School Dentistry.* 1990, 32: 4-13.

26. Shapiro F. Bone development and its relation to fracture repair. The role of mesenchymal osteoblasts and surface osteoblasts. *European Cells and Materials*. 2008, 15:53-76.
27. Neyt J, Buckwalter J, Carroll N. Use of animal models in musculoskeletal research. *Iowa Orthop J*. 1998, 18:118-23.
28. Wang X, Mabrey J, Agrawal C. An interspecies comparison of bone fracture properties. *Bio-med Mater Eng*. 1998, 8:1-9.
29. Blumenfeld I, Srouji S, Lanir Y, Laufer D, Livne E. Enhancement of bone defect healing in old rats by TGF- β and IGF-1. *Exp Gerontol*. 2002, 37:553- 65.
30. Liu G, Zhao L, Zhang W, Cui L, Liu W, Cao Y. Repair of goat tibial defects with bone marrow stromal cells and betatricalcium phosphate. *J Mater Sci Mater Med*. 2008, 19: 2367- 76.
31. Kim S, Byeon J, Um I, Lim S, Kim S, et al. Experimental study on human demineralized dentin matrix as rhBMP-2 carrier In vivo. *J Dent App*. 2015, 2: 269-73
32. Bessho K, Tagawa T, Murata M. Purification of rabbit bone morphogenetic protein derived from bone, dentin, and wound tissue after tooth extraction. *J Oral Maxillofac Surg*. 1990, 48: 162-69.
33. Oryan A, Kamali A, Moshiri A. Potential mechanisms and applications of statins on osteogenesis: current modalities, conflicts and future directions. *J control Release: Off J Control Release Soc*. 2015, 215:12–24.
34. Zhang Y, Bradley A, Wang D, Reinhardt R. Statins, bone metabolism and treatment of bone catabolic diseases. *Pharmacol Res*. 2014, 88:53–61.
35. Dimmeler S, Aicher A, Vasa M, Rihm C, Adler K, et al. HMG-CoA reductase inhibitors (statins) increase endothelial progenitor cells via the PI 3-kinase/Akt pathway. *J Clin Invest*. 2001, 108: 391-97.
36. Pereira N, Issa J, Nascimento C, Pitol D, Ervolino E, et al. Effect of alveolex on the bone defects repair stimulated by rhBMP-2: Histomorphometric study. *Microsc Res Tech*. 2012, 75:36-41.
37. Izuta H, Shimazawa M, Tsuruma K, Araki Y, Mishima S. Bee products prevent VEGF-induced angiogenesis in human umbilical vein endothelial cells. *BMC Complement Alter Med*. 2009, 9:1-10.
38. Recker R. Embryology, anatomy, and microstructure of bone, in *Disorders of Bone and Mineral Metabolism*. New York: Raven, 1992, pp 219–40.