

Dietary Supplementation of Quercetin and the Reproductive Functions in Hypertensive Male Rats

AHMED A. ABD AL-FATTAH, M.D.* and YASSER M. ABD EL-RAOUF, M.D. **

The Departments of Physiology* and Internal Medicine, Metabolism Unit**, Faculty of Medicine, Tanta University, Egypt

Abstract

Background: Hypertension is considered one of the commonest medical problems and affects more than 25% of the general population, with its prevalence increases with age. It is associated with a wide variety of health challenges like stroke, heart failure, renal failure and reproductive disorders.

Aim of Study: The prevention of hypertension induced reproductive impairment remains unclear. Hence, the aim of the present study was to investigate the possible protective effects of quercetin on male reproductive functions in L-NAME- induced hypertensive rats.

Material and Methods: 50 Male Wister Albino rats (200-220g) were divided into 5 groups 10 per each. G1: The control group was placed on the basal diet (received saline with the same volume used to dissolve L-NAME and quercetin by gavage) for 4 weeks. G 2: The Quercetin group was administered with Quercetin 50mg/Kg b.w. by gavage for 4 weeks. G 3: The L-NAME group (hypertensive induced group received L-NAME (40mg/Kg/day by gavage) for 4 weeks. G 4: The L-NAME plus atenolol received L-NAME plus atenolol (10 mg/kg/day) by gavage for 4 weeks. G 5: The L-NAME plus Quercetin received L-NAME (40mg/Kg/day) plus quercetin 50mg/Kg b.w. by gavage for 4 weeks.

Results: Quercetin abrogated the mean blood pressure elevation induced by L-NAME. Administration of quercetin increased the antioxidant enzyme activities and glutathione, whereas it suppressed the oxidative stress biomarkers and the arginase activity. Quercetin significantly restored hypertension induced impairment of luteinizing hormone (LH), follicle stimulating hormone (FSH) and testosterone hormone. Quercetin improves the sperm motility and viability. Histopathological findings supported our results.

In Conclusion: Quercetin supplementation may be considered a beneficial approach targeting reproductive deficits in male hypertensive patients.

Key Words: : Quercetin – Hypertension – Fertility.

Introduction

HYPERTENSION is a chronic medical condition in which the blood pressure (BP) in the arteries is elevated [1]. It is considered a major public health

Correspondence to: Dr. Ahmed Abd Al-Fattah,
E-Mail: pacemaker107@gmail.com

epidemic and affects more than 25% of the general population, with its prevalence increasing with age. It is associated with a wide variety of health challenges like stroke, heart failure and renal failure [2].

Evidence suggests that hypertension is associated with an impairment of male sexual function, [3] but their pathophysiological pathways are yet to be clearly elucidated.

L-NAME (N-nitro-L-arginine methyl ester) which is considered an inhibitor of nitric oxide (NO) biosynthesis is used to induce hypertension experimentally. NO can act as a free radical scavenger, inactivating and even inhibiting production of superoxide anions. This suggests a beneficial role for NO in the male reproductive system [4].

Cell structure and function is the focus of disruption by oxidative stress. The imbalance of antioxidants and free radicals represented a key affective item. There are a variety of enzymes ameliorating the effect of free radicals in the normal physiologic conditions, including superoxide dismutase, catalase, glutathione peroxidase and glutathione reductase [5].

The association of hypertension with increased incidence of male sexual dysfunction includes problems related to libido, erection and ejaculation [6]. In addition, it has also been reported to cause male infertility via a decrease in blood flow to the testis [7].

A reduction of blood flow to various vital organs of the body as a result of vasoconstriction of the arterial vessels is one of the principal manifestation of hypertension. NO can act as a free radical scavenger, inactivating and even inhibiting production of super oxide anions which cause lipid peroxidation, a process which leads to functional impairment of spermatozoa [8].

Quercetin is one of the flavonoids, present in fruits, vegetables, plant-derived foods and medicines. Quercetin has been reported to improve neurobehavioral changes, neuronal and hepatic oxidative damage as well as apoptosis adult rats [9,10].

Quercetin is well known to possess multiple biological activities including antioxidant and free radical scavenging activities as well as a potential anti-carcinogenic activity [11]. The aim of the present study was to investigate the possible protective effects of quercetin on male reproductive functions in L-NAME-induced hypertensive rats.

Patients and Methods

Experimental animals: 50 Male Wister Albino rats (200-220g) were purchased from the Faculty of Science Tanta University 2016. All animal experiments were undertaken with the approval of Ethical Animal Research Committee of Tanta University. The animals were housed at temperature 20-22°C, exposed to alternate cycles of 12h dark/light throughout the study and fed chow ad libitum. All rats had free access to distilled water. Animals were kept for 2 weeks for acclimatization.

Chemicals: Quercetin and L-NAME were obtained from Sigma-Aldrich, Egypt.

Experimental design: Rats were randomly divided into 5 groups 10 per each. Control group served as a normotensive control group (received saline with the same volume used to dissolve L-NAME and quercetin by gavage throughout the experiment (4 weeks). The Quercetin group: Was administered intragastrically with Quercetin dissolved in normal saline at a concentration of 50mg/Kg b.w. for 4 weeks. The L-NAME group (hypertensive group received L-NAME (40mg/Kg/day, dissolved in normal saline by gavage for 4 weeks). The L-NAME plus atenolol: Received L-NAME (40mg/Kg/day) plus atenolol (10mg/kg/day) orally for 4 weeks. The L-NAME plus Quercetin: Received L-NAME (40mg/Kg/day) plus quercetin 50mg/Kg b.w. for 4 weeks [4].

In all rats, systolic blood pressure (SBP), diastolic blood pressure (DBP) and mean arterial blood pressure (MAP) were measured in awaken animals 24h after the last treatment by tail-cuff plethysmography. $MAP = DBP + 1/3$ pulse pressure. Rats were conditioned with the apparatus before measurements were taken (Kent Scientific; Rat Tail Blood Pressure System for rats and mice, India).

Following blood pressure monitoring, the final weights of the rats were taken and blood samples from retro-orbital venous plexus were collected in heparin as anticoagulant. Blood was centrifuged at 3500g for 10 minutes for obtaining plasma. Excision of the testis and epididymis and their tissues were blotted with filter paper, weighted and processed for further biochemical and histological assay. The organo-somatic indices (OSI) were determined using the formula, $OSI = 100 \times \text{organ weight (g)}/\text{body weight}$.

Sperm motility and viability assays:

The sperms were collected immediately according to the method described by Zemjanis [12]. The data were expressed as percentage of sperm progressive motility. Sperm viability was determined according to established procedures [13]. The serum total testosterone level was measured by ELISA method using DRG Elisa testosterone kit (Germany) according to the standard protocol supplied by the kit manufacturer [14]. Serum LH hormone and FSH were estimated according to the instructions postulated [15,16] respectively.

Nitric oxide (NO) content in testes and epididymis supernatant was estimated according to a method described by the manufacturer. Testis and epididymis nitrite and nitrate levels were expressed as Nano mole of NO/milligram of protein [17].

The arginase activity of testis and epididymis from normotensive and hypertensive rats were assay as described by Mendez et al., [18].

The GSH level in the testis and epididymis was measured according to the method described by Bradford using serum albumin as standard [19].

Lipid peroxidation was determined as the formation of thio barbituric acid reactive substances (TBARS) according to a previously published study [20]. TBARS tissue levels were expressed as $\mu\text{molMDA}/\text{mg}$ of protein.

Glutathione-S-transferase activity was determined according to the method of Habig et al., [21].

Total thiol content (T-SH) was determined according to the method previously described by Akinyemi et al., [22].

Reactive oxygen species (ROS) production was estimated using the method described by Lovato et al., [23].

Histopathological examination was performed according to the method described and established [24].

Statistical analysis: All values were expressed as mean ± SD. SPSS version 16.0 was used for statistical analysis. Data were statistically analyzed using one-way ANOVA for multiple group comparison. Significance was set at $p \leq 0.05$.

Results

Mean arterial blood pressure body, weight gain and organo-somatic indices of the testes and epididymis in L-NAME-induced hypertensive rats:

Oral administration of L-NAME elevates the final MAP significantly when compared with the control group and quercetin groups. There was a significant hypotensive effect of quercetin and atenolol with no significant difference between atenolol and quercetin groups. The MAP was still higher in atenolol and quercetin groups compared with both the control and quercetin groups (Fig. 1). The body weight gain and organo-somatic indices of the testes and epididymis in all groups remain unaffected during this study (Table 1).

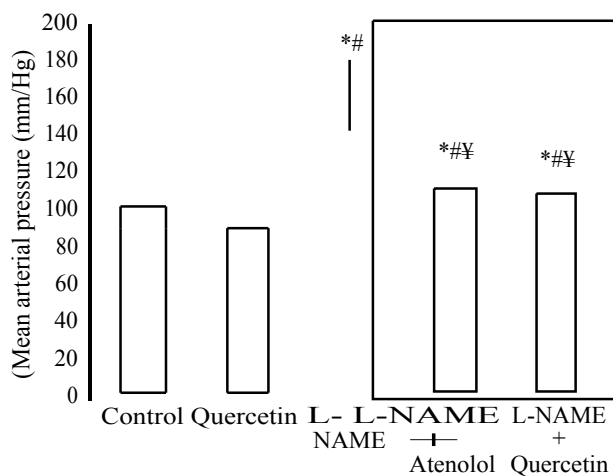


Fig. (1): Mean arterial blood pressure (mm Hg).

*: Means significant compared with the control group.
#: Means significant compared with the quercetin group.
¥: Means significant compared with the L-NAME group.
π: Means significant compared with the L-NAME + Atenolol group.

Table (1): Body weight gain and organo-somatic indices (OSI) of the testes and epididymis.

	Body weight gain (g)	OSI of the testis	OSI of the epididymis
Control	30.36±5.1	1.25±0.06	0.13±0.04
Quercetin	31.8±4.6	1.33±0.07	0.14±0.03
L-NAME	32.4±2.1	1.20±0.06	0.11±0.04
L-NAME + Atenolol	31.5±3.2	1.25±0.04	0.12±0.04
L-NAME +Quercetin	30.4±3.14	1.24±0.05	0.11±0.03

*: Means significant compared with the control group.
#: Means significant compared with the quercetin group.
¥: Means significant compared with the L-NAME group.
π: Means significant compared with the L-NAME + Atenolol group.

Sperm progressive motility and viability:

L-NAME hypertensive group showed a significant reduction of epididymal sperm motility and viability compared to the control and the quercetin groups. Significant improvement of sperm motility and viability was observed after quercetin supplementation to the hypertensive L-NAME group. The same was observed following atenolol therapy. No significant difference was present when comparing the L-NAME plus atenolol to L-NAME plus quercetin (Figs. 2,3).

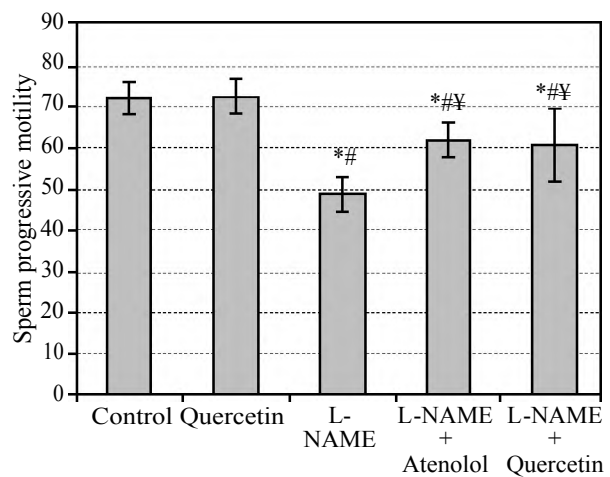


Fig. (2): Epididymal sperm progressive motility%.

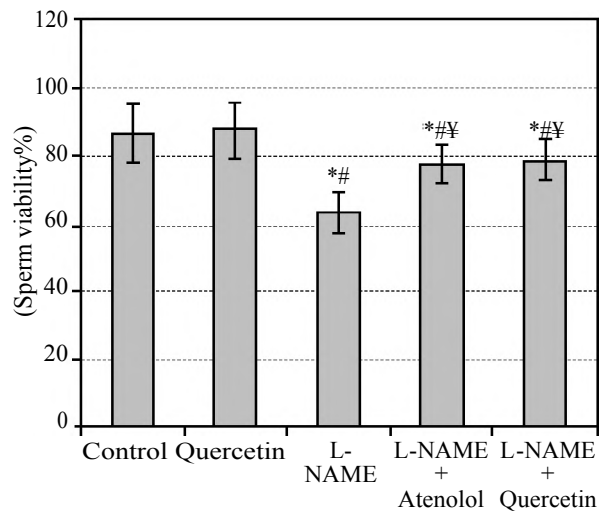


Fig. (3): Epididymal sperm viability%.

*: Means significant compared with the control group.
#: Means significant compared with the quercetin group.
¥: Means significant compared with the L-NAME group.
π: Means significant compared with the L-NAME + Atenolol group.

Testosterone concentration, LH, FSH, Nitric oxide (NO) level and arginase activity:

Serum testosterone, LH and FSH levels were significantly reduced in hypertensive group. Quercetin and atenolol administration significantly restored the hormonal levels. Regarding testosterone, treatment with quercetin or atenolol restored

its normal level, however concerning LH and FSH, there was a significant difference when comparing the treated groups with the control and quercetin groups (Figs. 4-6).

Nitric oxide (NO) level was reduced in the testicular and epididymal tissues in hypertensive rats. Significant elevation of NO in both L-NAME plus quercetin and L-NAME plus atenolol but still lower than the control and quercetin groups. Testicular and epididymal arginase activity were increased significantly in hypertensive animals. Significant reduction of testicular and epididymal arginase activity following quercetin and atenolol therapy of hypertensive induced rats was reported. However, no significant changes were observed when comparing epididymal arginase levels in L-NAME treated with either quercetin or atenolol

groups compared with both control and quercetin groups (Table 2).

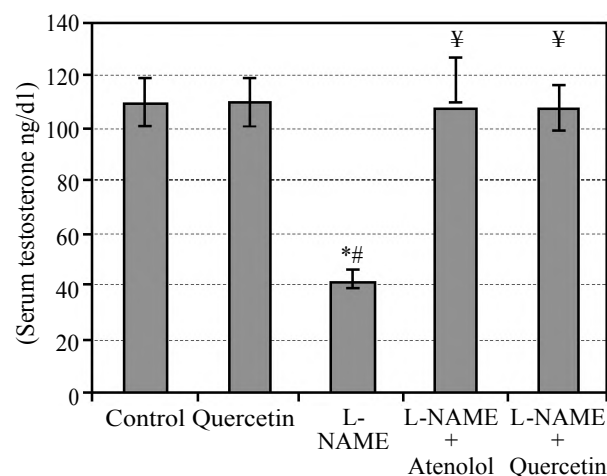


Fig. (4): Serum testosterone (ng/dl).

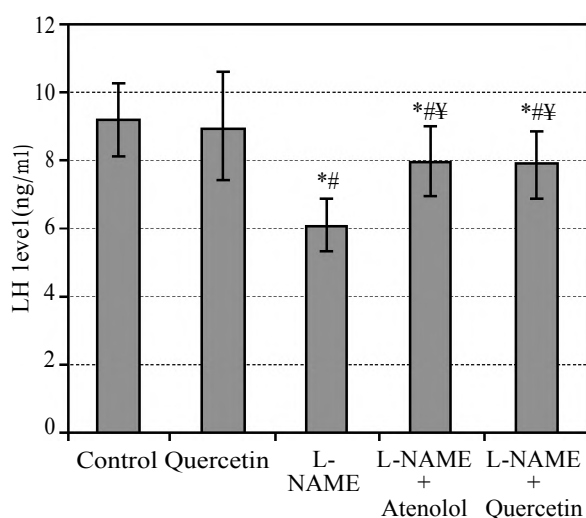


Fig. (5): Serum LH (ng/ml).

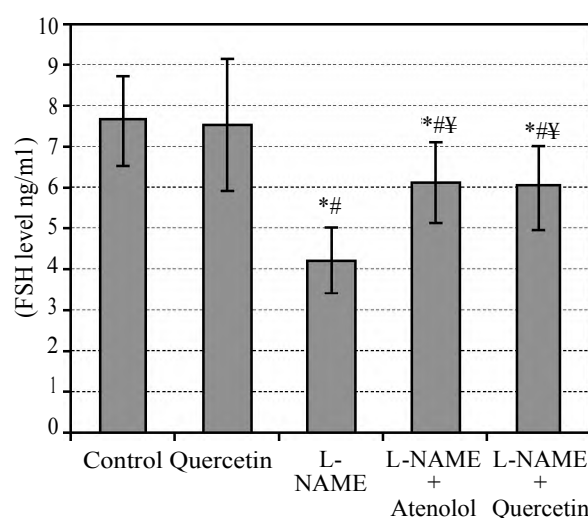


Fig. (6): Serum FSH (ng/ml).

Table (2): Nitric oxide (NO) and arginase activity in testicular and epididymal tissues.

Parameter	Control	Quercetin	L-NAME	L-NAME + Atenolol	L-NAME + Quercetin	F
NO Testis (nmol NO/mg protein)	26.8±3.71	26.38±3.63	5.75±1.25*#	12.87±1.85*#¥	13±2.06*#¥	119.006
NO Epididymis (nmol NO/mg protein)	0.89±0.12	0.92±0.13	0.39±0.08*#	0.71±0.11*#¥	0.71±0.12*#¥	43.990
Testis Arginase Activity (µmol/mg protein/min)	9.6±1.89	9.5±1.92	20±4.08*#	12.6±2.01*#¥	12±2.26*#¥	27.621
Epididymis Arginase Activity (µmol/mg protein/min)	21.1±3.54	21.2±3.7	42.8±7.13*#	20±3.2¥	21±2.6¥	50.688

*: Means significant compared with the control group.

#: Means significant compared with the quercetin group.

¥: Means significant compared with the L-NAME group.

π: Means significant compared with the L-NAME + Atenolol group.

Antioxidant status in testicular and epididymal tissues:

L-NAME administration produced a pronounced decrease in the GSH and T-SHs levels and elevation in the ROS and TBARS. Quercetin

supplementation as well as atenolol produced a significant increase of the GSH and T-SHs with a concomitant decrease in the ROS and TBARS compared with L-NAME hypertensive group (Table 3).

Table (3): GSH, T-SH and ROS in testicular and epididymal tissues.

Parameter	Control	Quercetin	L-NAME	L-NAME + Atenolol	L-NAME + Quercetin	F
Testis GSH (nmol/mg protein)	187.7±23.87	189.7±24.58	81.6±13.98*#	177.9±16.6¥	177.6±10.03¥	53.139
Epididymis GSH (nmol/mg protein)	103.1±16.45	102.7±16.36	40.4±6.58*#	88.6±14.17*#¥	89.3±14.59*#¥	33.408
Testis T-SH (nmol/mg protein)	617.7±62.08	619.7±64.42	397.1±64.76*#	609.3±72.13¥	608.9±71.94¥	20.868
Epididymis T-SH (nmol/mg protein)	352±36.45	352.8±37.59	155.7±17.53*#	296.4±22.62*#¥	294.4±21.16*#¥	80.686
ROS Testis (% control)	98.7±19.21	97.8±18.89	172±21.74*#	133.9±16.46*#¥	134.4±17.92*#¥	26.377
ROS Epididymis (% control)	93.5±14.6	93.7±15.02	145.4±23.65*#	106.4±17.62¥	105.1±16.86¥	14.287

*: Means significant compared with the control group.
 #: Means significant compared with the quercetin group.
 ¥: Means significant compared with the L-NAME group.
 π: Means significant compared with the L-NAME + Atenolol group.

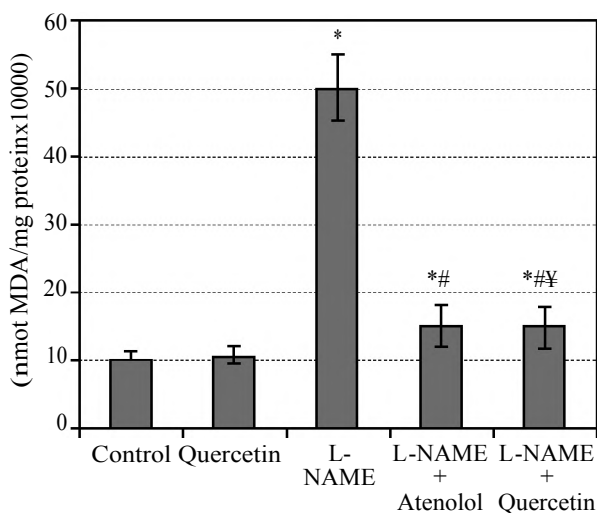


Fig. (7A): Testis TBARS (n mol MDA/mg protein x10000).

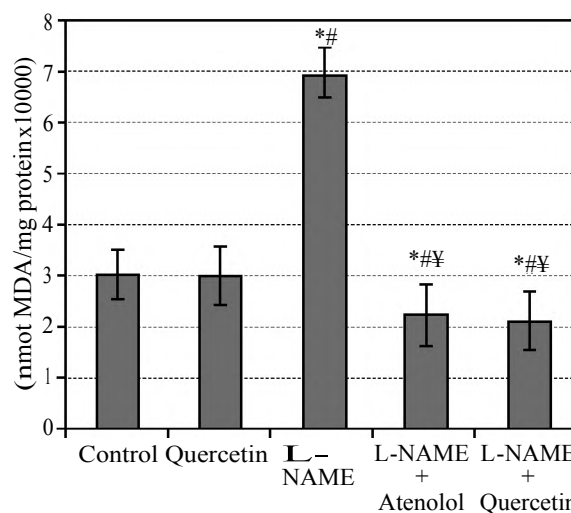


Fig. (7B): Epididymis TBARS (n mol MDA/mg protein x10000).

Histopathological examination:

Histopathological examination of the control and quercetin groups showed Normal testicular tissue with seminiferous tubules (Figs. 8,9 A,B). L-NAME hypertensive group showed testicular damage, marked widening of interstitial spaces and reduction of spermatogenesis (Fig. 10A,B).

L-NAME plus atenolol group showed mild improvement in the seminiferous tubules structure and narrowing of the interstitial spaces (Fig. 11A,B). L-NAME plus quercetin showed marked improvement of the seminiferous tubular structure and marked narrowing of the interstitial spaces (Fig. 12A,B).

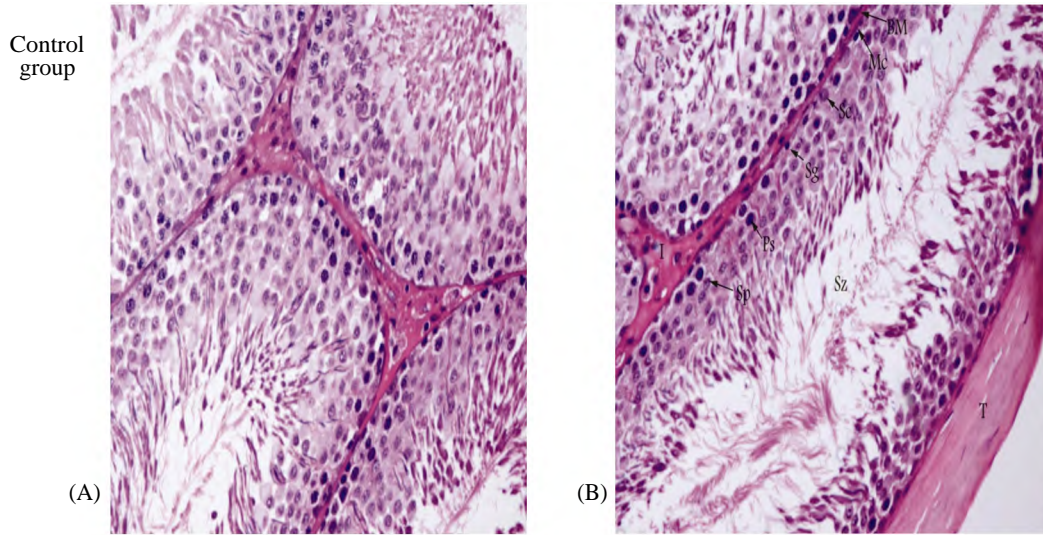


Fig. (8): Normal testicular tissue with seminiferous tubules (H&E, Mic. Mag.200X).

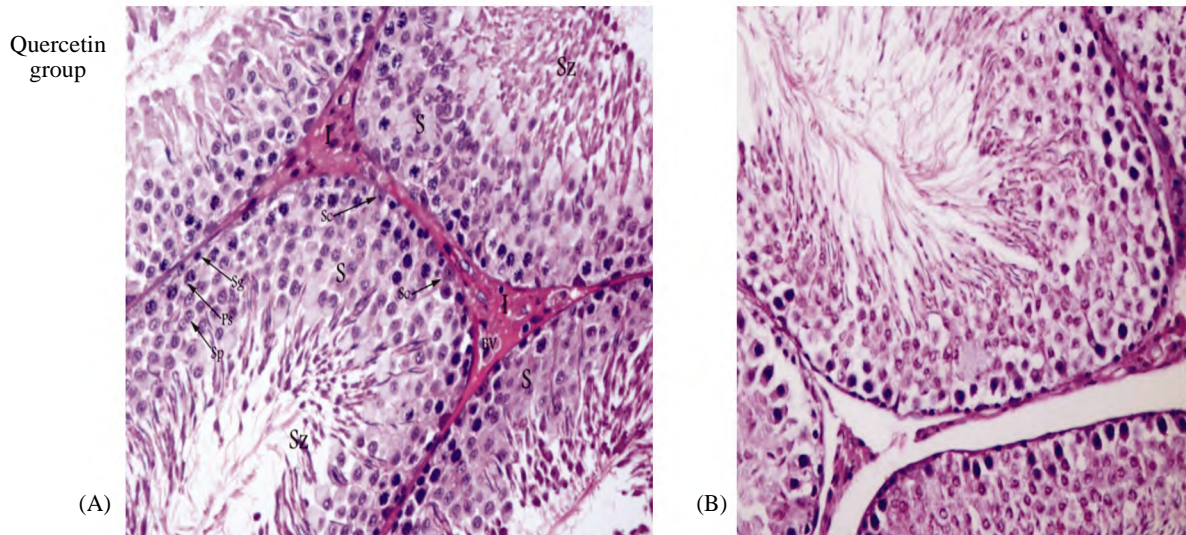


Fig. (9): Quercetin group with healthy testicular tissue and normal seminiferous tubules (H&E, Mic.Mag.200X)

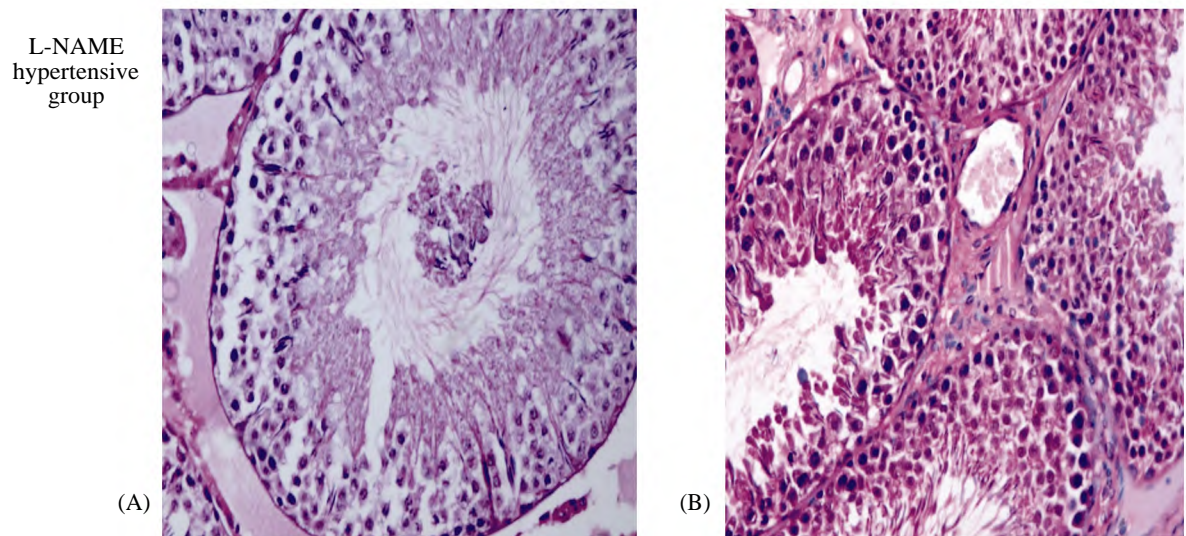


Fig. (10): Testicular tissue of L-NAME hypertensive group with testicular damage, marked widening of interstitial spaces and reduction of spermatogenesis (A-H&E, Mic. Mag. 200X) (B-H&E, Mic. Mag. 400X)

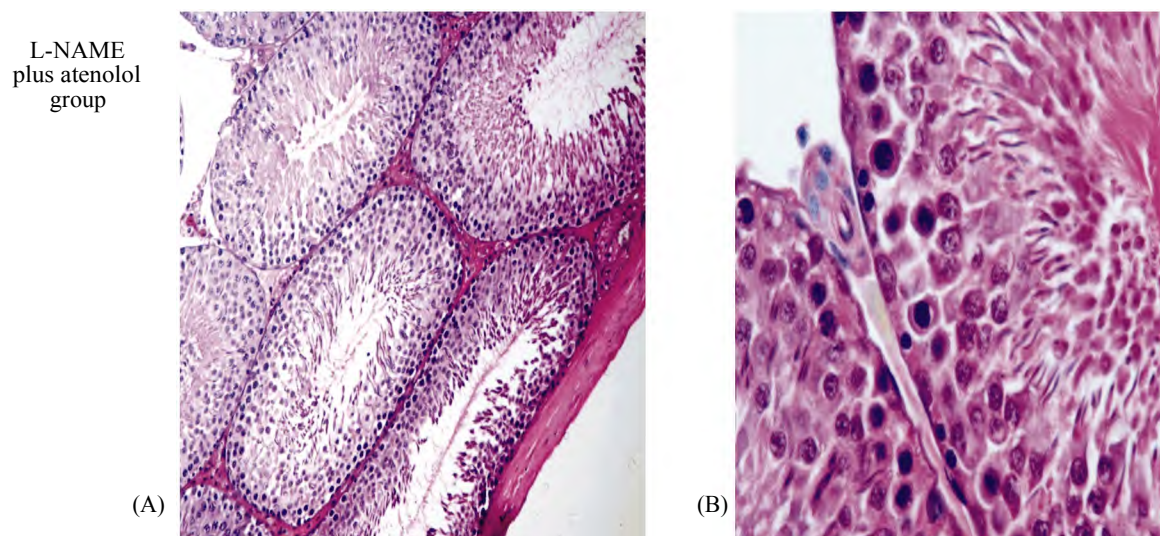


Fig. (11): Testicular tissue of L-NAME plus atenolol with mild improvement in the seminiferous tubules structure and narrowing of the interstitial spaces (A-H&E, Mic. Mag.200X-B-A-H&E, Mic. Mag. 400X).

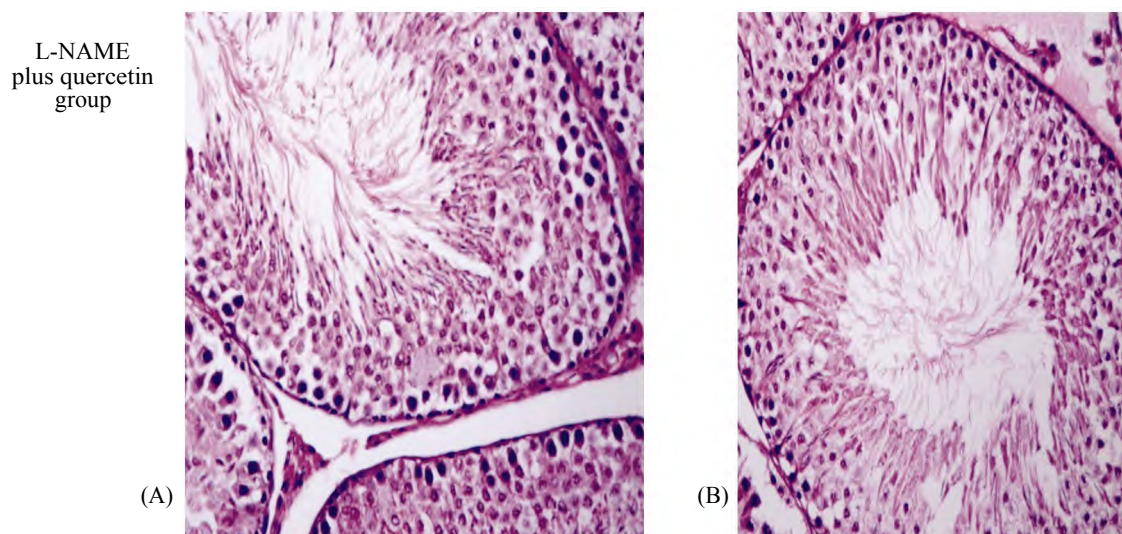


Fig. (12): Testicular tissue of L-NAME plus quercetin with moderate improvement in the seminiferous tubules structure and narrowing of the interstitial spaces (H&E, Mic. Mag.200X).

Discussion

There is a growing interest in the use of biologically active plant substances, as potent antioxidants in assisted reproduction technologies [25,26]. Some polyphenols such as quercetin have a powerful antioxidant effect [27,28]. Antioxidant supplements have been used in cryopreservation and culture media [29,30].

The link between hypertension and male fertility was reported in many studies [31,32]. Our study postulated an important evidence that quercetin reduced the reproductive disability associated with hypertension. Quercetin attenuated the L-NAME induced blood pressure elevation and improved the hypertensive mediated abnormalities especially in sperm motility and viability, antioxidant status

and endocrine functions. Furthermore, quercetin abrogated the elevation of oxidative stress parameters.

The mechanisms explaining the effects of quercetin on blood pressure modulation are not fully understood, with alteration in cell signaling and expression of genes being the most probable. Different meta-analytical studies had shown a significant blood pressure lowering effect of quercetin.

L-NAME had a pronounced elevation effect on the ABP by inhibition of NOS with a subsequent increase in the peripheral resistance and high blood pressure [4]. L-NAME induces NO-deficient hypertension via inhibition of NOS with subsequent increase of the total peripheral resistance and high blood pressure.

NO inhibition affects sperm motility and viability so, NO is regarded as an important mediator of male reproduction. NO serves as a free radical scavenger and inhibits the production of superoxide anions. These superoxide anions are considered the leading cause of lipid peroxidation with subsequent impairment of spermatozoa [22].

The balanced state between the antioxidants as GSH and T-SH and ROS production is essential for normal spermatogenesis together with the sperm function and the male fertility. Hypertension creates imbalance between the antioxidant status and the ROS generation [33].

In this study, significant elevations of ROS and TBARS in hypertensive rats with subsequent reduction of GSH and T-SH values were reported. This leads to the damage of the testicular and epididymal tissues. Excessive production of lipid peroxidation parameters may lead to overconsumption of GSH and T-SH. The GSH and T-SHs levels were decreased in the epididymis and the testis. GSH reduction may suggest overutilization to withstand oxidative damage. Reduction of T-SHs may be due to reduction of its substrate or inhibition by excessive free radicals in the hypertensive group. Quercetin prevented the reduction of GSH and T-SH levels with subsequent reduction of ROS and TBARS levels in the testes and the epididymis of L-NAME hypertensive rats.

Quercetin prevents ROS production [34]. Quercetin was found to be one of the most powerful flavonoids for protection against the reactive oxygen species that are produced during the normal oxygen metabolism or induced ROS [35].

L-NAME induced hypertension was associated with marked reduction of LH, FSH and testosterone levels with a definite hormonal imbalance. Normally, LH from the anterior pituitary gland acts on the testicular interstitial cells of Leydig to stimulate testosterone hormone secretion. Testosterone together with FSH act on the Sertoli cells to stimulate spermatogenesis. The interstitial cells of Leydig are the main source of testosterone which is essential for spermatogenesis. Reduction of testosterone level in the L-NAME hypertensive rats may be due to damage of testicular and epididymal tissues due to oxidative stress or secondary to decreased LH level [21]. The same results were mentioned by Morakino and his group [11]. The changes of sperm motility and viability could result from decreased hormonal concentrations associated with hypertension. This reduction of the sperm motility and viability may result in its inability to

reach the site of fertilization and penetration of zona pellucida [36].

Normal blood flow to the testis and epididymis is essential for spermatogenesis. Any effective reduction of testicular and epididymal perfusion will participate in reduction of male fertility [37].

Endothelium nitric oxide synthase (eNOS) needs L-arginine and O₂ for (NO) and citrulline manufacture. L-Arginine is also utilized by arginase enzyme, that helps conversion of L-arginine into L-ornithine and urea. Arginine is considered a substrate for both nitric oxide synthase and arginase which is a key point in NO/c GMP. Up-regulation of one enzyme leads to down regulation of the other and vice versa. In our study, there was a significant rise of arginase level in the L-NAME hypertensive group compared with both the control and the quercetin groups with significant reduction in L-NAME plus quercetin and L-NAME plus atenolol groups. Increased arginase activity in L-NAME hypertensive group may be due to the inhibition of eNOS by L-NAME so, favoring the arginase pathway. Reduction of NO impairs the testicular and epididymal tissue perfusion [38].

The interesting finding in our study was that B blocker (atenolol) had improved the oxidative stress in hypertensive animals. Different previous studies had postulated a potential link between the sympathetic activity and oxidative stress. Monoamine oxidases catalyze oxidative deamination of catecholamines. Thus, oxidation of catecholamines is a source of reactive oxygen species (ROS) [39].

The knowledge that β -adrenergic stimulation is the main driver of ROS generation in mitochondria has indicated the use of β -adrenergic receptor blockers to reduce oxidative stress in cardiac failure [40].

There was histopathologic damage without significant change in the weights of the testis and the epididymis following hypertension induction using L-NAME.

Testicular damage marked widening of interstitial spaces and reduction of spermatogenesis as evidenced by appearance of focal area of sperm maturation arrest. The histopathological alterations observed may be due to direct or indirect effect of elevated ROS with subsequent induction of lipid peroxidation and disturbance of the structure and the functions of the testis and the epididymis [1]. However, quercetin and atenolol administration effectively reduced these testicular and epididymal lesions supporting the biochemical data.

Conclusion:

This study highlights the importance of quercetin on reproductive abnormalities in L-NAME hypertensive rats. The restoration of the hypertensive related reproductive dysfunctions are achieved by quercetin antioxidant and antihypertensive effects. Quercetin administration may be a good approach to minimize the reproductive deficits in hypertensive patients. Quercetin might be considered as an add-on therapy for hypertension and hypertensive related reproductive dysfunctions. The beneficial effect of β adrenergic blockers and oxidative stress needs further studies to be elucidated clearly.

Conflict of interest:

The authors have no conflicts of interest.

Acknowledgment:

This study was supported by Prof. Mohamed Alsheref, Prof. of Pathology, Faculty of Medicine, Tanta University.

References

- 1- ADEDARA I.A. and FAROMBI E.O.: Chemoprotection of ethyleneglycol monoethyl ether induced reproductive toxicity in male rats by kolaviron, isolated biflavonoid from *Garcinia kola* seed, *Hum. Exp. Toxicol.*, 31: 506-17, 2012.
- 2- MORAN E., ODDEN M.C., THANATAVEERAT A., TZONG K.Y., RASMUSSEN P.W., GUZMAN D., et al.: Cost-effectiveness of hypertension therapy according to 2014 guidelines, *New Engl. J. Med.*, 372: 447-455, 2015.
- 3- DUSING R.: Effect of the angiotensin II antagonist valsartan on sexual function in hypertensive men, *Blood Press. Suppl.*, 12: 29-34, 2003.
- 4- ADEDARA A.I., ALAKE E.S., ADEYMO O.M., OLAJIDE O.L., AJIBADE O.T. and FAROMBI O.E.: Taurine enhances spermatogenic function and antioxidant defense mechanisms in testes and epididymis of L-NAME- induced hypertensive rats. *Biomedicine & Pharmacotherapy*, 97: 181-189, 2018.
- 5- SIES H., CARSTEN B.C. and JONES P.D.: Oxidative stress. *Annu. Rev. Biochem.*, 86: 715-48, 2017.
- 6- VLACHOPOULOS C., IOAKEIMIDIS N., TEREANTES-PRINTZIOS D., AZNAOURIDIS K., ROKKAS K., AGGELIS A., et al.: Plasma total testosterone and incident cardiovascular events in hypertensive patients, *Am. J. Hypertens.*, 26: 373-381, 2013.
- 7- MALLICK C., MANDAL S., BARIK B., BHATTACHARYA A. and GHOSH D.: Protection of testicular dysfunctions by MTEC, a formulated herbal drug, in streptozotocin induced diabetic rat, *Biol. Pharm. Bull.*, 30: 84-90, 2007.
- 8- LOVATO F.L., ADEDARA I.A., BARBISAN F., MOREIRA K.L., ROCHA U.M. and DA CRUZ I.B.: Quercetin ameliorates polychlorinated biphenyls-induced testicular DNA damage in rats, *Andrologia.*, 48: 51-58, 2016.
- 9- THOMAS B.C., RONALD D.J., BEYERS T.Q., ROMERO M., RAJESH R.S. and JOHN C.S.: Lifelong quercetin enrichment and cardioprotection in Mdx/Utrn \pm mice, *American Journal of Physiology-Heart and Circulatory Physiology*, 312: no. 1., 2017.
- 10- SELVAKUMAR K., BAVITHRA S., GANESH L., KRISHNAMOORTHY G., VENKATARAMAND P. and ARUNAKARANA J.: Polychlorinated biphenyls induced oxidative stress mediated neurodegeneration in hippocampus and behavioral changes of adult rats: Anxiolytic-like effects of quercetin. *Toxicol. Lett.*, 222: 45-54, 2013.
- 11- MURAKAMI A., ASHIDA H. and TERAJO J.: Multitargeted cancer prevention by quercetin. *Cancer Lett.*, 269: 315-325, 2008.
- 12- ZEMJANIS R.: Collection and evaluation of semen, in : R. Zemjanis (Ed.), *Diagnostic and Therapeutic Technique in Animal Reproduction*, 2nd ed., William and Wilkins Company, Waverly Press, Inc. Baltimore. Maryland. USA, pp. 139-153, 1970.
- 13- ADEDARA I.A. and FAROMBI E.O.: Kolaviron protects against ethylene glycol monoethyl ether-induced toxicity in boar spermatozoa. *Andrologia.*, 46: 399-407, 2014.
- 14- AZU O.O.: Testicular morphology in spontaneously hypertensive rat model: Oxidant status and stereological implications, *Andrologia.*, 47: 123-137, 2015.
- 15- BROWN J.L., KERSEY D.C. and WALKER S.L.: Assessment of luteinizing hormone and prolactin LH, FSH, PRL 116 immunoactivity in Asian and African elephant urine using assays validated for serum. *Gen. Comp. Endocrinol.*, 169: 138-143, 2010.
- 16- HASHIZUME T. and KASUYA E.: Methodology for the study of the hypothalamic-pituitary hormone secretion in cattle. *Anim. Sci. J.*, 80: 1-11, 2009.
- 17- MIRANDA K.M., ESPAY M.G. and WINK D.A.: A rapid, simple spectrophotometric method for simultaneous detection of nitrate and nitrite, *Nitric Oxide.*, 5: 62-71, 2001.
- 18- MENDEZ J.D., SOSA A. and PALOMAR-MORALES M.: Effect of l-arginine on arginase activity in male accessory sex glands of alloxan-treated rats, *Reprod. Toxicol.*, 16: 809-813, 2002.
- 19- BRADFORD M.M.: A rapid and sensitive method for the quantitation of microgram quantities of protein utilizing the principle of protein-dye binding, *Anal. Biochem.*, 72: 248-254, 1976.
- 20- OHKAWA H., OHISHI N. and YAGI K.: Assay for lipid peroxides in animal tissues by thiobarbituric acid reaction. *Anal. Biochem.*, 95: 351-358, 1976.
- 21- HABIG W.H., PABST M.J. and JAKOBY W.B.: Glutathione S-transferase: The first enzymatic step in mercapturic acid formation, *J. Biol. Chem.*, 249: 7130-7139, 1974.
- 22- AKINYEMI A.J., ADEDARA I.A., THOME G.R., MORSE V.M., ROVANI M.T., MUJICA L.K., et al.: Dietary supplementation of ginger and turmeric improves reproductive function in hypertensive male rats, *Toxicol. Rep.*, 2: 1357-66, 2015.
- 23- LOVATO F.L., ADEDARA I.A., BARBISAN F., MOREIRA K.L., DA ROCHA M.I. and DA CRUZ I.B.: Quercetin ameliorates polychlorinated biphenyls-induced testicular DNA damage in rats, *Andrologia.*, 48: 51-8, 2016.

- 24- BANCROFT J.D. and GAMBLE M.: Theory and Practice of Histology Techniques, 6th ed., Churchill Livingstone Elsevier, pp. 83-134, 2008.
- 25- DE VASCONCELOS F.S., FAHEEM M., CHAVEIRO A. and MOREIRA de SILVA F.: Effects of α -tocopherol and freezing rates on the quality and heterologous in vitro fertilization capacity of stallion sperm after cryopreservation. *Theriogenology*, 86 (4): 957-62, 2016.
- 26- SILVA E.C., CAJUERO J.F., SILVA S.V., SOARES P.C. and GUERRA M.M.: Effect of antioxidants resveratrol and quercetin on in vitro evaluation of frozen ram sperm. *Theriogenology*, 77 (8): 1722-6, 2012.
- 27- ZHONG R. and ZHOU D.: Oxidative stress and the role of natural plant derived antioxidants in animal reproduction. *J. Integr. Agr.*, 12: 1826-38, 2013.
- 28- WRIGHT C., MILNE S. and LEESON H.: Sperm DNA damage caused by oxidative stress: Modifiable clinical, lifestyle and nutritional factors in male infertility. *Reprod Biomed.*, 28 (6): 684-703, 2014.
- 29- LY C., YOCKELL-LELIEVRE J., FERRARO Z.M., ARNASON J.T., FERRIER Z.M. and GRUSLIN A.: The effects of dietary polyphenols on reproductive health and early development. *Hum. Reprod. Update*, 21 (2): 140-7, 2015.
- 30- MORETTI E., MAZZI L., BONECHI C., SALVATICI M.C., LACOPONI F., ROSSI C., et al.: Effect of Quercetin-loaded liposomes on induced oxidative stress in human spermatozoa. *Reprod. Toxicol.*, 60: 140-7, 2016.
- 31- AZU O.O.: Testicular morphology in spontaneously hypertensive rat model: Oxidant status and stereological implications, *Andrologia.*, 47: 123-137, 2015.
- 32- ZHAO H.S., XU Z., WANG Y., LI W., GUO C., LIN S., et al.: Repetitive exposures to low-dose X-rays attenuate testicular apoptotic cell death in streptozotocin-induced diabetes rats, *Toxicol. Lett.*, 192: 356-364, 2010.
- 33- KATO Y.: Neutrophil myeloperoxidase and its substrates: formation of specific markers and reactive compounds during inflammation, *J. Clin. Biochem. Nutr.*, 58: 99-104, 2016.
- 34- BANDAY M.N., LONE F.A., RASOOL F., RASHID M. and SHIKAR A.: Use of antioxidants reduce lipid peroxidation and improve quality of crossbred ram sperm during its cryopreservation. *Cryobiology*, 74: 25-30, 2017.
- 35- AL-OMAIR M.A., SEDKY A., ALI A. and ELSAWY H.: Ameliorative potentials of quercetin against lead-induced hematological and testicular alterations in albino rats. *Chinese Journal of Physiology*, 60 (1): 346-52, 2017.
- 36- CABRILLANA M.E., MONCLUS M.L., LANCELLOTTI T.E., BOARELLI P.V., VINCENTI A.E., FORNÉS M.M., et al.: Thiols of flagellar proteins are essential for progressive motility in human spermatozoa, *Reprod. Fert. Dev.*, 29 (7): 1435-46, 2016.
- 37- KIM S.W., CUONG T.D., HUNG T.M., RYOO S., LEE J.H., et al.: Arginase II inhibitory activity of flavonoid compounds from *Scutellaria indica*. *Arch. Pharm. Res.*, 36: 922-926, 2013.
- 38- OKTEM F., KIRBAS A., KUYBULU A.E., YILMAZ H.R., OZGUNER F. and UZ E.: Lisinopril attenuates renal oxidative injury in L-NAME-induced hypertensive rats, *Mol. Cell. Biochem.*, 352: 247-253, 2011.
- 39- LIN J., PENG Y., WANG S., LAI M., YOUNG T., SALTER D.M., et al.: Sympathetic nervous system control of carbon tetrachloride-induced oxidative stress in liver through α -adrenergic signaling, *Oxidative Medicine and Cellular Longevity*, (6, Part 1): 1-11, 2016.
- 40- LIU J., WU K.C., LU Y.F., EKUASE E. and KLAASSEN C.D.: NRF2 protection against liver injury produced by various hepatotoxicants, *Oxidative Medicine and Cellular Longevity*, 12: 1-8, 2013.

المكملات الغذائية من الكيرسيتين والوظائف الإنجابية فى إرتفاع ضغط الدم المستحدث بالأل نيم فى ذكور الجرذان

الخلفية/الهدف: يعتبر إرتفاع ضغط الدم من أكثر الأمراض الطبية شيوعاً ويؤثر على أكثر من ٢٥٪ من عامة السكان، مع زيادة أنتشاره مع التقدم فى السن. ويرتبط مع مجموعة واسعة من التحديات الصحية مثل السكتة الدماغية، وفشل القلب، والفشل الكلوى والإضطرابات التناسلية. الوقاية من الإضطرابات التناسلية الناجمة عن إرتفاع ضغط الدم لا تزال غير واضحة. وبالتالي كان الهدف من الدراسة هو دراسة التأثيرات الوقائية المحتملة للكيرسيتين على الوظائف التناسلية الذكورية فى الجرذان الناجم عن إرتفاع ضغط الدم المستحدث بالأل نيم.

المواد والطرق: تم تقسيم ٥٠ من ذكور الجرذان البيضاء إلى ٥ مجموعات كل ١٠. الأولى: المجموعة الضابطة وضعت على النظام الغذائى الأساسى (مع إعطائها محلول ملحي من نفس الحجم المستخدم فى حل الأل نيم والكيرسيتين عن طريق التزقيم لمدة أربعة أسابيع). المجموعة الثانية مجموعة الكيرسيتين وتم إعطائها الكيرسيتين ٥٠ ملغ/كغ وزن. عن طريق التزقيم لمدة أربعة أسابيع. المجموعة الثالثة: مجموعة الأل نيم قد تلقت ٤٠ ملجم من الأل نيم/كغ/يوم التزقيم لمدة أربعة أسابيع. المجموعة الرابعة: تم إعطائها الأل نيم بالإضافة للأتينولول ١٠مجم/كجم/يوم. المجموعة الخامسة: تم إعطائها الأل نيم ٤٠ ملغ/كغ/يوم بالإضافة للكيرسيتين ٥٠ ملغ/كغ وزن الجسم عن طريق التزقيم لمدة أربعة أسابيع.

النتائج: ألغى كيرسيتين الأرتفاع فى متوسط ضغط الدم الناجم عن الأل نيم وزاد الكيرسيتين من نشاط إنزيم مضادات لأكسدة والجلوتاثيوم، فى حين أنه قام بتقليل المؤشرات الحيوية للأكسدة ونشاط الأرجيناز. إستعاد الكيرسيتين بشكل كبير هرمون الأل أنش وهو من الأف أس أنش وهرمون التستوستيرون. كما حسن الكيرسيتين حركية الحيوانات المنوية. قد دعمت النتائج النسيجية نتائجننا، وفى الختام، يمكن اعتبار مكملات الكيرسيتين نهجاً مفيداً يستهدف حالات القصور التناسلى عند مرضى إرتفاع ضغط الدم لدى الرجال.