

Ultrasound-guided transversus abdominis plane block for postoperative analgesia after varicocelectomy operations

Wael Alham Mahmoud, Ahmed Hamody Hassan, Khaled abdefattah Mohamed, Ghada Abdel Gaber Rizk*

*Lecturer of anaesthesia and intensive care, Sohag University.

Abstract

To assess the efficacy of transversus abdominis plane (TAP) block as a postoperative analgesic effectiveness. Thirty-three consecutive male patients undergoing retroperitoneal varicocele repair (Palomo technique) were enrolled in this study. Patients were randomly allocated to undergo ultrasound-guided TAP block anesthesia (case group), or conventional spinal anesthesia (control group), rescue analgesia need, nausea, and satisfaction at different time-points (6, 12, and 24 h after surgery). The post-operative evaluation, patients enrolled in the case group expressed significantly less pain on VAS score at rest and on movement at 6 ($p = 0.001$ and $p = 0.001$) and at 12 h ($p = 0.004$ and $p = 0.01$). Moreover, the need of rescue analgesia resulted significantly higher in the control group ($p = 0.03$). This is the first study showing that TAP block could be employed as an effective and feasible anesthesia method for the retroperitoneal varicocelectomy. Moreover, our results demonstrate that this method is more effective than spinal anesthesia in the pain control after varicocele repair.

Introduction

Varicocelectomy is one of the most frequently performed surgical procedures. Several techniques have been used for the surgical ligation of varicocele, including retroperitoneal, inguinal, and scrotal open techniques, microsurgical inguinal, and subinguinal varicocele ligation, laparoscopic approaches, and radiographic embolization. The open retroperitoneal high ligation of the internal spermatic vein (Palomo technique) currently represents one of these validated surgery methods for the varicocele repair [1].

The transversus abdominis plane (TAP) block is a recently regional anesthesia technique that provides analgesia to the parietal peritoneum as well as to the skin and muscles of the anterior abdominal wall [2, 3, 4]. Despite a relatively low risk of complications and a high success rate using modern techniques, TAP blocks remain overwhelmingly underutilized [5].

The aim of this randomized and controlled study was to determine the feasibility and the efficacy of TAP block for post-operative analgesic effectiveness after varicocelectomy operations.

Methods

After local ethical committee approval and written informed consent signature, all consecutive adult male patients undergoing elective varicocelectomy repair were screened for the enrollment in our study between June 2016 and March 2017.

Exclusion criteria were: inability to consent to the study, age ≤ 18 years, BMI ≥ 40 kg m², contra-indication to local anesthetic (LA) agents.

Patients were randomly allocated by sealed envelopes to undergo ultrasound-guided TAP block anesthesia (case group), or conventional spinal anesthesia (control group).

All surgical procedures were performed using the Palomo technique

(open high retroperitoneal ligation of internal spermatic vein). All patients (cases and controls) were premedicated with midazolam (0.03 mg/kg) intravenously. All TAP blocks and spinal anaesthesia were performed before operation by the same anaesthetist, experienced in ultrasound-guided loco-regional anaesthesia.

In addition, before surgery, patients were instructed how to make use of a 10 mm Visual Analogue Scale (VAS) for pain graded from 0 (no pain) to 10 (most severe pain). The VAS score was recorded at the major three phases of the intervention (first: skin and subcutaneous incision; second: retraction of the muscle internal oblique and the peritoneum; third: vein identification and ligation).

At different time-points (6, 12, and 24 h) after the surgical intervention, each subject (cases and controls) was evaluated for pain on movement (elevation of the head and shoulders from the pillow, in the supine position), pain at rest, need of rescue analgesia, presence of nausea, and patient satisfaction (defined according to validated criteria).

The VAS scores were recorded at each time-point by an independent observer unaware of the patient allocation the case or to control arm.

For post-operative analgesia, both case and control subjects received paracetamol 1 g every 8 h. If rescue analgesia was needed (VAS score at rest >4), ketorolac (30 mg in single dose) was administered. In case of failure of the rescue analgesia with ketorolac, the use of opioids has been taken into consideration.

Results

Of the 47 subjects screened for the enrollment in this study, 14 patients were excluded because of the exclusion criteria. In particular, three were ≤ 18 years old, two showed a BMI $> 40 \text{ kg/m}^2$, seven denied their consent to the study, two referred contra-indication to LA agents.

Participants were asked to rate the severity of nausea on a four-point scale (none, mild, moderate, and severe) during the first 24 h after surgery.

TAP block (Case) group:

. After receiving the standard general anaesthesia they received a Single shot TAP block via a linear array transducer probe (6–13 MHz) in the multibeam mode, connected to a portable ultrasound unit levobupivacaine 0.5 % (1.5 mg/kg) was injected with intermittent aspiration and the correct placement of the needle was confirmed by expansion of the LA solution as a dark shadow between aponeurosis of the internal oblique (which moved anteriorly) and the transversus abdominis muscles pushing the muscle deeper.

Traditional spinal anaesthesia (control) group:

Subarachnoid puncture was performed with a 25-gauge Whitacre needle, with patients in the sitting position. A midline approach at the L2–3 or L3–4 interspace was used. Patients received 2.4 or 2.6 ml of 0.5 % hyperbaric bupivacaine depending on their height (2.4 ml for those $< 152 \text{ cm}$ and 2.6 ml for those $> 152 \text{ cm}$).

Statistical analysis

Statistical analysis was performed with SPSS 15.0. The Yates corrected Chi square test was used as a means of evaluating differences in categorical variables, and the independent *t* test was used for continuous variables. To adjust for co-variables and to make predictions, linear and logistic regression models were used. Statistical significance was accepted when the *p* value was < 0.05 .

Among the 33 consecutive patients enrolled in our study, 16 underwent varicocele repair under ultrasound-guided TAP block anesthesia (case group), and 17 under spinal anaesthesia (control group). Baseline clinical and demographic characteristics were similar between the two groups. Moreover, surgical results did not significantly differ between case and control patients (Table 1). The TAP block procedure added to the surgery 15.3 ± 4.2 min.

Table 1: Baseline demographic characteristics and outcome measurements

	Tap block	Spinal	p value
Age (years)	30.5 ± 6.3	30.4 ± 6.3	0.9
BMI (units)	24.8 ± 3.9	24.7 ± 4.0	0.9
Operative time (min)	17.3 ± 5.8	17.8 ± 5.8	0.8
Adequate anaesthesia (pts)	15 (91 %)	17 (100 %)	0.1
Rescue analgesia use (pts)	6 (27.2 %)	14 (77.2 %)	0.03
First time to require ketorolac(min)	277±33	138±47	0.02
Total ketorolac consumption(mg) /24 hrs	39±12.1	58 ±9.6	0.05

Postoperative VAS score at rest (rVAS) and VAS score on movement (mVAS) are reported in Fig. 1. In detail, patients enrolled in the TAP block group expressed significantly less pain on rVAS at 6 h ($p = 0.001$) and at 12 h ($p = 0.004$) as compared with control subjects. On the contrary, no significant differences were found between the two groups for rVAS scores 24 h after surgery ($p = 0.5$). Accordingly, as compared with controls, patients from TAP block group reported significantly less pain on mVAS at 6 h ($p = 0.001$) and 12 h ($p = 0.01$) whereas no significant differences were found between the two groups for mVAS scores at 24 h ($p = 0.5$) after surgery

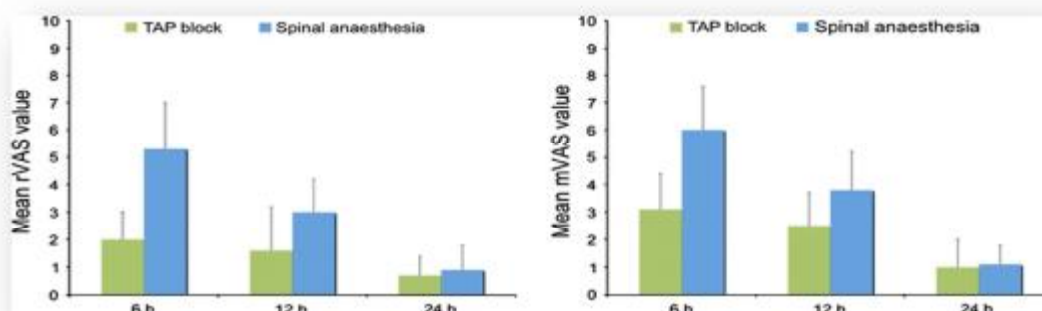


Fig. 1 Mean pain intensity scores at rest and on movement (mVAS) in case and control patients in the postoperative period.

During the first postoperative day, the need of rescue analgesia for abdominal pain resulted significantly higher in the control group as compared with the case group [13/17 (77.3 %) vs. 4/16 (27.3 %), $p = 0.03$]. In case of rescue analgesia use only a single dose of ketorolac (15 mg) was administered. After adjusting for the other variables (age, BMI, operative time), the TAP block anesthesia was found to predict

lower values of post-operative rVAS at 6 h ($\beta = -0.695$, $p < 0.001$) and at 12 h ($\beta = -0.468$, $p < 0.001$) as compared with spinal anesthesia.

Similar results was found for mVAS at 6 h ($\beta = -0.673$, $p < 0.001$) and at 12 h ($\beta = -0.390$, $p = 0.005$).

Accordingly, in a logistic regression analysis, the TAP block anesthesia was associated with a significantly reduced need of rescue post-operative analgesia (OR 0.141, 95 % CI 0.028–0.714, $p = 0.018$). None of the subjects (case and controls) needed drugs other than ketorolac (30 mg) for analgesia. On the contrary, no patients had analgesic requirement during the first week after surgery.

No surgical and anaesthetic complications were observed in all the procedures, although a trend towards less nausea ($p = 0.3$) was found in the case group as compared with the controls (Table 2). After all, as to the patients satisfaction rate after surgery, in this study, we achieved good results among our patients in either groups ($p = 0.7$) and no one referred bad this period (Table 2).

Table 2: Nausea and vomiting rates

	Tap block	Spinal	<i>p</i> value
Nausea (pts)			
Severe	0	0	0.3*
Moderate	3 (18.1 %)	4 (22.7 %)	
Mild	2 (9 %)	3 (18.1 %)	
None	11 (72.7 %)	10 (59 %)	

Discussion

This study aimed to know the efficacy and safety of the TAP block for postoperative analgesia after varicocelectomy operations.

The TAP is an intermuscular plane between the internal oblique and transversus abdominis muscles. The terminal branches of the lower thoracic and first lumbar nerves course through the lateral abdominal wall within this plane [6]. Injection of local anesthetic in the TAP may possibly provide unilateral analgesia of the anterior abdominal wall (skin, muscles, and parietal peritoneum) from the T7 to L1 dermatomes [7, 8].

The TAP block was first described as a landmark-guided technique involving needle insertion at the triangle of Petit and the elicitation of two tactile fascial “pops” to indicate entry into the transversus abdominis muscles [3]. More recently, ultrasounds has been used successfully to guide needle

insertion [10, 11, 12], and it may help prevent complications related to inadvertent visceral perforation [13]. The muscle layers and peritoneum are readily visualized using a linear transducer, even in moderately obese subjects [10].

Transversus abdominis plane block has been described as an effective component of multimodal postoperative analgesia for a wide variety of abdominal procedures including large bowel resection, open/laparoscopic appendectomy, cesarean section, total abdominal hysterectomy, laparoscopic cholecystectomy, open prostatectomy, renal transplant surgery, abdominoplasty with/without flank liposuction, and iliac crest bone graft [1]. Most reports demonstrate the effectiveness of TAP block by highlighting a reduced postoperative opioid related requirement, lower pain

scores, and/or reduction in opioid-related side effects [14]. Moreover, the efficacy of the TAP block in the induction of an effective analgesia during the first 24 h after surgery has been reported [15, 16, 17].

There are a few randomized controlled trials comparing TAP block and spinal analgesia for analgesia after varicocele operations. At present, TAP block is recommended in patients undergoing abdominal surgery when spinal or epidural blockade is contraindicated or not available.

TAP block is considered a good analgesic procedure for pain control after operations that involve the abdominal wall like varicocele and hernia repair operations. Our results demonstrate that this analgesia method is more effective than spinal anesthesia in the pain management after varicocele repair because patients who underwent TAP block anesthesia expressed significantly less pain on VAS score at rest and on movement, and a less analgesic requirements considering first time to require ketorolac and total dose of ketorolac consumption per 24 hours. As to the analgesic potential of TAP block, in a similar manner with all the other surgical procedures, also in the varicocele the relative small sample size make it unlikely to define conclusive results.

Further studies are needed to address the relevant issue of the TAP block use in the anesthetic and analgesic management of varicocele surgery.

References

- 1- Hsu GL, Ling PY, Hsieh CH et al (2005): Outpatient varicocele performed under local anesthesia. *Asian J Androl* 7(4):439–444.
- 2- Charlton S, Cyna AM, Middleton P et al (2010) : Perioperative transversus abdominis plane (TAP) blocks for analgesia after abdominal surgery. *Cochrane Database of Systematic Reviews*, vol 8, Article ID CD007705.
- 3- Rafi N (2001) Abdominal field block: a new approach via the lumbar triangle. *Anaesthesia* 56(10):1024–1026.
- 4- Kearns RJ, Young SJ (2011) : Transversus abdominis plane blocks; a national survey of techniques used by UK obstetric anaesthetists. *Int J Obstet Anesth* 20(1):103–104.
- 5- Rozen WM, Tran TM, Ashton MW et al (2008): Refining the course of the thoracolumbar nerves: a new understanding of the innervation of the anterior abdominal wall. *Clin Anat* 21(4):325–333.
- 6- McDonnell JG, O'Donnell BD, Farrell T et al (2007) Transversus abdominis plane block: a cadaveric and radiological evaluation. *Reg Anesth Pain Med* 32(5):399–404.
- 7- Tran TM, Ivanusic JJ, Hebbard P et al (2009): Determination of spread of injectate after ultrasound-guided transversus abdominis plane block: a cadaveric study. *Br J Anaesth* 102(1):123–127.
- 8- McDonnell JG, O'Donnell B, Curley G et al (2007): The analgesic efficacy of transversus abdominis plane block after abdominal surgery: a prospective randomized controlled trial. *Anesth Analg* 104:193–197.
- 9- Rafi AN (2001) Abdominal field block: a new approach via the lumbar triangle. *Anaesthesia* 56:1024–1026.
- 10- Hebbard P, Fujiwara Y, Shibata Y et al (2007) Ultrasound-guided transversus abdominis plane (TAP) block. *Anaesth Intensive Care* 35:616–617.
- 11- Suresh S, Chan VW (2009): Ultrasound guided transversus abdominis plane block in infants, children and adolescents: a simple

- procedural guidance for their performance. *Paediatr Anaesth* 19:296–299.
- 12-**Farooq M, Carey M (2008) A case of liver trauma with a blunt regional anesthesia needle while performing transversus abdominis plane block. *Reg Anesth Pain Med* 33:274–275.
- 13-**McDermott G, Korba E, Mata U et al (2012) :Should we stop doing blind transversus abdominis plane blocks? *Br J Anaesth* 108(3):499–502.
- 14-**O'Donnell BD, McDonnell JG, McShane AG (2006):The transversus abdominis plane (TAP) block in open retropubic prostatectomy. *Reg Anesth Pain Med* 31:91.
- 15-**Carney J, McDonnell JG, Ochana A, Bhinder R (2008): The transversus abdominis plane block provides effective postoperative analgesia in patients undergoing total abdominal hysterectomy. *Anesth Analg* 107(6):2056–2060.
- 16-**McDonnell JG, Curley G, Carney J et al (2008) :The analgesic efficacy of transversus abdominis plane block after cesarean delivery: a randomized controlled trial. *Anesth Analg* 106(1):186–191.
- 17-**McMorrow RC, Ni Mhuircheartaigh RJ, Ahmed KA et al (2011): Comparison of transversus abdominis plane block vs spinal morphine for pain relief after Caesarean section. *Br J Anaesth* 106(5):706–712.