

## Case Report:

# Syringocystadenoma Papilliferum in the Middle Ear

Wael A. Alzamil, M.D.

The Department of Otorhinolaryngology, Hearing and Speech Institute,  
General Organization for Teaching Hospitals and Institutes, Giza, Egypt

### Abstract

**Background:** Syringocystadenoma papilliferum is a rare adnexal tumor of controversial origin that often occurs as a solitary tumor derived from apocrine and eccrine glands. It is more common in children and adolescents and affects the head and neck regions, although occurrences on other anatomical locations have been described. Routine H & E-stained sections revealed cystic epidermal invaginations with papillary projections. The superficial portions of the cyst were lined by stratified keratinizing epithelium, whereas the deeper papillated portion exhibited a double layer of basal-like cells and luminal eosinophilic columnar cells with focal decapitation secretions.

**Patient and Method:** A female patient, aged 29 years, presented to us in the outpatient clinic suffering from left earache and hearing loss since the past 3 months, with gradual onset and a slowly progressive course. On examination, we found a left aural polyp, which was firm and grayish in color, but extremely tender on touch. Biopsy for histopathological examination was consistent with a diagnosis of syringocystadenoma papilliferum. The patient received regular follow-up and is doing well with regard to her earache with marked hearing improvement. To conclude, solitary lesions seen in unusual locations generate multiple differential diagnoses and should be confirmed by histopathology in order to exclude other pathologies and define the appropriate therapeutic approach.

**Conclusion:** Solitary lesions seen in unusual locations generate multiple differential diagnoses and they must be confirmed by histopathology

**Key Words:** Adnexal tumor of the middle ear – Middle-ear adenoma – Syringocystadenoma papilliferum in the middle ear.

### Introduction

**SYRINGOCYSTADENOMA** papilliferum is a rare adnexal tumor of controversial origin that often occurs as a solitary tumor derived from apocrine and eccrine glands. It is more common in children and adolescents, occurring in the head

and neck region, although occurrences in other anatomical locations have been described [1-5]. Routine H & E-stained sections revealed cystic epidermal invaginations with papillary projections. The superficial portions of the cyst were lined by stratified keratinizing epithelium, whereas the deeper papillated portion exhibited a double layer of basal-like cells and luminal eosinophilic columnar cells with focal decapitation secretion. Here we present an interesting case of a left aural polyp, which later proved to be syringocystadenoma papilliferum. The postoperative period was uneventful. The patient received regular follow-up and is doing well with marked hearing improvement.

### Case History

A female patient, aged 29 years, presented to us in the outpatient clinic suffering from left earache and hearing loss of 3 months' duration, with gradual onset and a slowly progressive course. On examination, we found a left aural polyp, which was firm and grayish in color, but extremely tender on touch. Tuning fork examination and pure tone audiometry revealed a left-only hearing ear with conductive gap of 15 db. She underwent therapy with antibiotics, systemic and topical corticosteroids, and pain killers, with no improvement and even progression of symptoms. Her computed tomography scan of the temporal bone and middle-ear cleft showed left soft-tissue opacity centered over facial recess and extending to the external canal Figs. (1,2). After obtaining written consent, an atraumatic punch biopsy was taken in the outpatient clinic. Histopathology of the adnexal tumor and persistence of symptoms mandated surgical excision after written consent for hearing loss and facial nerve affection was obtained. Lesions were surgically excised for definitive diagnosis and management, and tissue was sent for a histopatho-

Correspondence to: Dr. Wael A. Alzamil,  
E-Mail: [dr\\_waelzamil25@yahoo.com](mailto:dr_waelzamil25@yahoo.com)

logical examination. Intraoperatively, we found a grayish-white firm mammilated polyp in the posterior tympanomeatal sulcus with defect in the posterior half of the tympanic membrane. On dissection, the polyp was found to be centered over the facial recess, the incudostapedial joint (which was eroded), extending to the fossa incudis and mastoid antrum. Retrograde atticoantrostomy (in outward direction) was performed parallel to the tumor until it was completely removed as a single piece peeled away from its bed and ossicular chain. Incus shaping and interposition with tympanic membrane grafting was done. The postoperative period was uneventful. The patient received regular follow-up and is doing well with respect to her earache, with marked hearing improvement. Histopathological diagnosis Gross examination showed a grayish-white, soft-tissue piece. It measured 0.5 X 0.3 X 0.4cm in dimension. There were papillary projections on the outer surface. The cut section was homogenous. Microscopic examination showed an acanthotic and papillomatous epidermis with multiple cystic, papillary, and ductal invaginations that extended into the dermis Fig. (3). These invaginations were lined by double layers of cells, which consisted of an outer layer of cuboidal cells and a luminal layer of tall columnar cells. Decapitation secretions were seen in the luminal layer, which stained positive with Periodic acid Schiff stain.

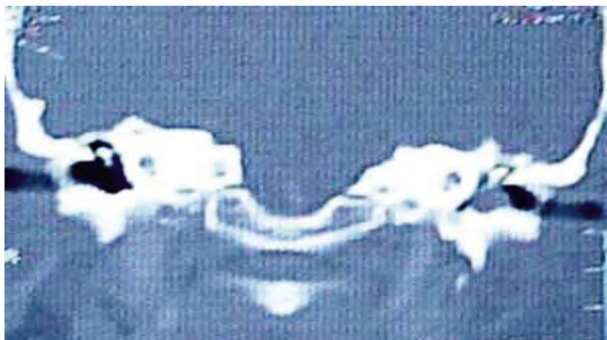


Fig. (1): Coronal Computed Tomography (CT) of the temporal bone.

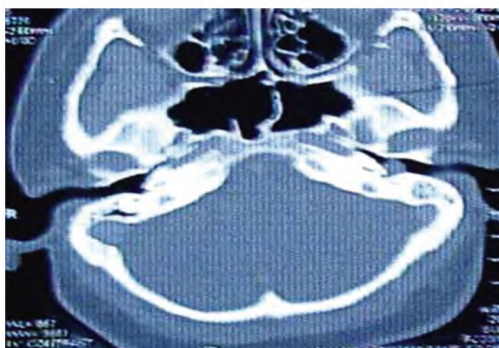


Fig. (2): Axial Computed Tomography (CT) of the temporal bone.

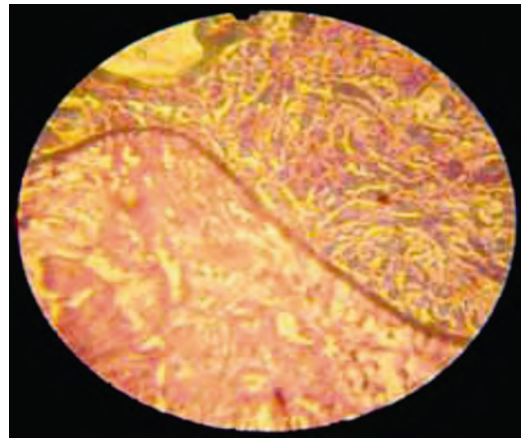


Fig. (3): Histopathological section. Syringocystadenoma papilliferum in the middle ear.

The connective tissue core was filled with plasma cells, a few lymphocytes, and dilated capillaries. The histological findings were consistent with a diagnosis of syringocystadenoma papilliferum.

### Discussion

Adenomas in the middle ear are benign glandular neoplasms confined to it and originating from its epithelium [6]. These adenomas were not recognized until 1976 [7]. The epithelium of the middle ear has a propensity for gland formation in otitis media, and adenomas would seem to represent a benign neoplastic transformation of this epithelium along the same lines [8]. In the study by Hyams and Michaels the patients with this lesion ranged in age from 14 to 80 years, three being in the second to the fourth decade. There was an equal sex distribution. Most patients complained of hearing loss, which was of conductive type. Pain, facial palsy, and ear discharge were usually absent. The tympanic membrane was mostly intact and the neoplasm was confined to the middle ear, sometimes extending to the mastoid spaces; in a few cases it did extend through a perforation into the ear canal. A rare example of penetration through an intact tympanic membrane has also been described [6,9]. Grossly, the neoplasm appears white, gray, or reddish brown at operation and, unlike paragangliomas, is not vascular. It seems to peel away from the walls of the surrounding middle ear with ease, although ossicles may sometimes be entrapped in the tumor mass and may even show destruction [10]. Microscopic examination of the adenoma shows closely apposed small glands with a 'back to back' appearance. In some places a solid or trabecular arrangement is present. Sheet-like, disorganized areas are seen in which the glandular

pattern appears to be lost. This may be artifactual and related to the effects of the trauma of the biopsy on the delicate structure of this neoplasm, but the appearance may lead one to suspect malignancy. The cells are regular, cuboidal, or columnar and may enclose luminal secretion. No myoepithelial layer is seen. Sometimes a papillary pattern is present. Mills and Fechner [11] found lysozymes in each of five adenomas stained for this enzyme by an immunochemical method. In another study, four adenomas were examined for lysozymes using the same antiserum as that reported by Mills and Fechner but with a sandwich technique for the further stages of the test. However, no lysozymes were found in any of the adenomas tested. Electron microscopy showed projecting microvilli [11]. Syringocystadenoma papilliferum is a hamartomatous adnexal tumor that arises from pluripotent cells. Derived from apocrine and eccrine glands, its histogenesis is still controversial [10,12]. It is accepted that differentiation is predominantly apocrine. It is a childhood or adolescence neoplasm, which is observed since birth in 50% of cases. Its clinical presentation in the skin is in the form of a papule, plaque, or a single or grouped nodule, with no hair. It may be asymptomatic, but could become exudative, with a linear arrangement. It has a tendency to increase in size during adolescence, becoming more verrucous and papillomatous. Its most frequent sites of occurrence are the scalp, neck, and face (75%) [13,14]. Some uncommon sites reported are eyelids, arms, buttocks, auricular pavilion, scrotum, vulva, back, and abdomen [15,16]. Association with other benign neoplasms of adnexal origin may occur, such as apocrine adenoma, hidradenoma papilliferum, trichoblastoma, eccrine poroma, sebaceous nevus of Jadassohn, and others [17,18]. Histopathologically, its presentation is a dermal endophytic tumor with irregular papillary projections of scaly epithelium, forming ductile structures that connect with the surface, aligned by glandular epithelium constituted by an external layer of cuboid cells, with round nuclei and scarce cytoplasm, and an internal layer of cylindrical cells with decapitation secretion and plasmocyte-rich inflammatory infiltrate [7]. Syringocystadenoma papilliferum can rarely affect the eyelid skin [19]. This lesion is frequently clinically misdiagnosed as basal cell carcinoma or cyst. Although syringocystadenoma papilliferum of the eyelid can be associated with other benign lesions, no malignant transformation or association with malignant neoplasms has been reported. Evidence suggests that this tumor should be managed with conservative complete excision. Tumor cells show a reaction of positive staining with carcinoembry-

onic antigen. It is rarely associated with malignant progression, but basal cell carcinoma development has been described in 10% of cases, mainly when associated with sebaceous nevus of Jadassohn [17,18]. Squamous cell carcinoma and syringocystadenocarcinoma papilliferum were also reported as a progression of syringocystadenoma papilliferum [20], but are extremely rare. The most common form of treatment is surgical excision, but there are cases in which removal was effective with CO<sub>2</sub> laser in locations unfavorable for surgery. In our study, we present the case of a 29-year-old female patient with a left aural polyp who had a complaint of left earache and hearing loss of 3 months' duration, with gradual onset and a slowly progressive course. The polyp was very tender on touch. The challenge we faced was that the affected left ear was the only hearing ear with a conductive gap of 15db. Persistence and deterioration of symptoms indicated surgical excision for definitive diagnosis and management after written consent regarding hearing loss and facial nerve affection had been obtained. Histopathological examination was consistent with the diagnosis of syringocystadenoma papilliferum. The postoperative period was uneventful. The patient received regular follow-up and is doing well with respect to her earache and had gained marked hearing improvement. The patient in the present case was a candidate for surgery, because excision is recommended to prevent infections, hemorrhages, exacerbated growth, and malignant degeneration, and, consequentially, greater hearing loss and facial nerve affection. Syringocystadenoma papilliferum is a rare benign adnexal neoplasm with few reports of uncommon location in the literature. We have presented an additional case of an atypical location of this rare disease, thus contributing to the differential diagnosis of middle ear lesions.

#### *Differential diagnosis:*

The important differential diagnosis of adenoma of the middle ear is adenocarcinoma [20,21]. In most cases of the latter the neoplasm is metastatic to the middle ear [8]. The distinction can usually be made easily by the benign cellular pattern of the adenoma and the lack of destructive features clinically and on radiographs. Salivary gland choristomas are rare developmental tumor-like anomalies. Choristomas resemble hamartomas, which are focal overgrowth in improper proportions of tissues, except that the tissues of which it is composed are not normally present in the part of the body where it is found. It consists, as a rule, of mixed mucous and serous elements like the normal submandibular or sublingual gland, but unlike the parotid gland [7].

**Summary :**

Syringocystadenoma papilliferum is a rare benign adnexal neoplasm which present few reports of uncommon location described in the literature. We illustrate an additional case of atypical location of this rare disease and contributes to the differential diagnosis of middle ear lesions. Solitary lesions seen in unusual locations generate multiple differential diagnoses and they must be confirmed by histopathology.

**References**

- 1- MALHOTRA P., SINGH A. and RAMESH V.: Syringocystadenoma papilliferum on the thigh: An unusual location. Indian. J. Dermatol. Venereol. Leprol., 75: 170-2, 2009.
- 2- SOOD A., KHAITAN B.K., KHANNA N., KUMAR R. and SINGH M.K.: Syringocystadenoma papilliferum at unusual sites. Indian. J. Dermatol. Venereol. Leprol., 66: 328-9, 2000.
- 3- YAP F.B., LEE B.R. and BABA R.: Syringocystadenoma papilliferum in an unusual location beyond the head and neck region: A case report and review of literature. Dermatol. Online J., 16: 4, 2010.
- 4- GHOSH S.K., BANDYOPADHYAY D., CHATTERJEE G. and BAR C.: Syringocystadenoma papilliferum: An unusual presentation. Pediatr. Dermatol., 26: 758-9, 2009.
- 5- PAHWA P., KAUSHAL S., GUPTA S., KHAITAN B.K., SHARMA V.K. and SETHURAMAN G.: Linear syringocystadenoma papilliferum: An unusual location. Pediatr. Dermatol., 28: 61-2, 2011.
- 6- HYAMS V.J. and MICHAELS L.: Benign adenomatous neoplasm (adenoma) of the middle ear. Clin. Otolaryngol. Allied. Sci., 1: 17-26, 1976.
- 7- QUARANTA A., MININNI F. and RESTA L.: Salivary gland choristoma of the middle ear: A case report. J. Laryngol. Otol., 95: 953-6, 1981.
- 8- DERLACKI E.L. and BARNEY P.L.: Adenomatous tumors of the middle ear and mastoid. Laryngoscope, 86: 1123-35, 1976.
- 9- JAHRDOERFER R.A., FECHNER R.E., SELMAN J.W., MOON CNJR and POWELL J.B.: Adenoma of the middle ear. Laryngoscope, 93: 1041-4, 1983.
- 10- DIAMANDOPOLOUS G.T.H. and MEISSNER V.A.: Neoplasia. In: Kissane J.H., editor. Andersen's pathology. 8th ed. St Louis: CV Mosby, AQ13, 1985.
- 11- MILLS S.E. and FECHNER R.E.: Middle ear adenoma. A cytologically uniform neoplasm displaying a variety of architectural patterns. Am. J. Surg. Pathol., 8: 677-85, 1984.
- 12- KAR M., KAR J.K. and MAITI S.: Giant linear syringocystadenoma papilliferum of the back. Indian. J. Dermatol. Venereol. Leprol., 78: 123, 2012.
- 13- YOSHII N., KANEKURA T., SETOYAMA M. and KANZAKI T.: Syringocystadenoma papilliferum: Report of the first case on the lower leg. J. Dermatol., 31: 939-42, 2004.
- 14- SANGMA M.M., DASIAH S.D. and BHAT V.R.: Syringocystadenoma papilliferum of the scalp in an adult male -a case report. J. Clin. Diagn. Res., 7: 742-3, 2013.
- 15- RAMMEH-ROMMANI S., FEZAA B., CHELBI E., KAMMOUN M.R., BEN JILANI S.B. and ZERMANI R.: Syringocystadenoma papilliferum: Report of 8 cases. Pathologica, 98: 178-80, 2006.
- 16- DUFRECHOU L., ACOSTA A., BELTRAMO P., POMIES V., CARUSO R., SALMENTON G.M. and ALVAREZ M.: Syringocystadenoma papilliferum arising on the scrotum. Pediatr. Dermatol., 30: e12-e13, 2013.
- 17- KIM M.S., LEE J.H., LEE W.M. and SON S.J.: A case of tubular apocrine adenoma with syringocystadenoma papilliferum that developed in a nevus sebaceous. Ann. Dermatol., 22: 319-22, 2010.
- 18- BRUNO C.B., CORDEIRO F.N., SOARES FDO E., TAKANO G.H. and MENDES L.S.: Dermoscopic aspects of syringocystadenoma papilliferum associated with nevus sebaceous. An. Bras. Dermatol., 86: 1213-6, 2011.
- 19- RAO V.A., KAMATH G.G. and KUMAR A.: An unusual case of syringocystadenoma papilliferum of the eyelid. Indian. J. Ophthalmol., 44: 168-9, 1996.
- 20- MICHAELS L. and WELLS M.: Squamous cell carcinoma of the middle ear. Clin. Otolaryngol. Allied. Sci., 5: 235-48, 1980.
- 21- HILL B.A. and KOHUT R.I.: Metastatic adenocarcinomas of the temporal bone. Arch. Otolaryngol., 102: 568-71, 1976.

## سرنج أدينوما بابليفييرام في الأذن الوسطى (تقرير حالة)

سرنج أدينوما بابليفييرام يعتبر من الأورام النادرة جداً والتي تصيب أنسجة الإكتودرم وتسمى الأورام الأذنيكية ويوجد في مجالات البحث حالات محدودة جداً والتي تصيب أجزاء مختلفة من الجسم مثل الأطراف والأعضاء التناسلية وجفن العين.

في هذا البحث يتم عرض حالة مصابة بورم أو نمو السرنج أدينوما بابليفييرام بالأذن الوسطى في سيدة بمنتهى العمر حيث تم إستئصال الورم بنجاح وبدون مضاعفات خلال جراحة دقيقة بالميكروسكوب الجراحي وتم عمل جراحة لعظيومات الأذن لتحسين السمع كما تم تحليل الورم في معملين مختلفين للتأكد من التشخيص. وهذا يؤكد حتمية تحليل أنسجة أي نمو يظهر في أماكن غير شائعة حيث أنه قد يحمل العديد من الاحتمالات التشخيصية.