



## A Comparative Study between the Combined Effect of Frankincense and Myrrh versus the Effect of Triamcinolone Acetonide on Healing of Induced Labial Mucosal Ulcer in Albino Rats

Abeer E. Wahba<sup>(1)</sup>, Mona H. M. Farid<sup>(2)</sup> and Heba A. Adawy<sup>(3)</sup>

Codex : 40/1710

dentaljournal.forgirls@yahoo.com

### ABSTRACT

**Aim:** The aim of the present study was to evaluate the combined effect of frankincense and myrrh versus the effect of triamcinolone acetonide (TA) on healing of induced labial mucosal ulcer in albino rats histologically and immunohistochemically. **Materials and Methods:** Seventy five adult male albino rats (weighting 200-250) were used in the study and exposed to induced ulcers in the labial mucosa. The rats were divided into four groups, positive control group, group I, and three experimental groups. Negative control group: group II: (received no treatment). Group III: ulcers were treated with triamcinolone acetonide three times daily. Group IV: ulcers were treated with combination of frankincense and myrrh three times daily. Histological, immunohistochemical examination (using cyclin D1) and statistical analysis were performed for all groups. The animals were sacrificed at day 1, 3 and day 7 postoperatively. **Results:** Frankincense and myrrh enhanced the healing of labial mucosal ulcer better than triamcinolone acetonide. **Conclusion:** This study showed that combination of frankincense and myrrh have superior healing properties on oral ulcer and enhancing cell proliferation compared to triamcinolone acetonide.

### INTRODUCTION

Oral ulcers are encountered frequently in our daily practice; it causes a lot of suffering and agony for the patients throughout their life. Most oral ulcers are caused due to local causes such as trauma,

### KEYWORDS

Wound healing, frankincense, myrrh, triamcinolone acetonide.

- Paper extracted from master thesis entitled “A Comparative Study between the Combined Effect of Frankincense and Myrrh versus the Effect of Triamcinolone Acetonide on Healing of Induced Labial Mucosal Ulcer in Albino Rats. (A Histological and Immunohistochemical Study)”.
1. Demonstrator of Oral and Dental Biology, Faculty of Dental Medicine for Girls, Al- Azhar University.
  2. Professor and Head of Oral and Dental Biology Department, the Former Dean of Faculty of Dental Medicine for Girls, Al-Azhar University.
  3. Assistant Professor of Oral and Dental Biology, Faculty of Dental Medicine for Girls, Al- Azhar University.

self-elicited injuries and burns. Some may result due to aphthae or malignant conditions and few may be due to underlying systemic diseases, skin disorders or autoimmune diseases <sup>(1)</sup>.

Healing process is a dynamic process consisting of four continuous, overlapping and precisely programmed phases. The events of each phase must happen in a precise and regulated manner. Interruptions, aberrancies, or prolongation in the process can lead to delayed wound healing or a non-healing chronic wound. In adult humans, optimal wound healing involves the following the events: (1) rapid hemostasis; (2) appropriate inflammation; (3) mesenchymal cell differentiation, proliferation, and migration to the wound site; (4) suitable angiogenesis; (5) prompt re-epithelialization (re-growth of epithelial tissue over the wound surface); and (6) proper synthesis, cross-linking, and alignment of collagen to provide strength to the healing tissue <sup>(2,3)</sup>.

Management of oral ulcers can be obtained through non-therapeutic and therapeutic treatment. Non-therapeutic treatment includes supportive measures with attention to maintain good oral hygiene, prevent trauma or avoid certain foods. Therapeutic treatment options comprise anti-inflammatory agents, antibiotics, immunomodulatory agents and others. It can be administered topically or systemically <sup>(4)</sup>.

Corticosteroids are widely used in the topical treatment of canker sores and traumatic ulcers. Although there are different types of topical corticosteroids (TCs) with different strengths, the clinician are familiar with a limited number of TCs<sup>(5)</sup>.

Triamcinolone acetonide (TA) is one of the most commonly used TCs. It is considered to be an average strength TCs<sup>(6)</sup>. Moreover, it is effective in treatment of dermatoses, asthma and allergic rhinitis and is used in the decreasing of the signs and symptoms of many oral inflammatory conditions. The small amount which may enter

systemic circulation is metabolized in liver. TA dental paste was used as adjunctive treatment and temporary relief of symptoms associated with oral inflammation, gingival disorders and oral ulcers <sup>(7)</sup>.

However, the long-term and/or repeated application of corticosteroids could cause adrenal suppression. For this reason the therapeutic use of medicinal plants is of importance to avoid these non-desired side effects of corticosteroid therapy <sup>(8)</sup>.

Frankincense and myrrh are without a doubt the world's two most important resins. Frankincense is known as "Kundur" in Persian language. It has been used for centuries in ceremonial, cosmetic, cultural and as a traditional medicine to treat a variety of ailments especially inflammatory diseases including arthritis, asthma, cerebral edema, chronic bowel diseases, cancer and memory disorders <sup>(9)</sup>.

Myrrh is known as "Morr" in Persian language. It is a yellow-brown aromatic oleo-gum resin. Myrrh is used in traditional Chinese medicine for the treatment of trauma, arthritis, fractures and diseases caused by blood stagnation. It has been demonstrated that myrrh has broad spectrum of biological properties including antimicrobial, anti-inflammatory and immunopotentiating properties<sup>(10)</sup>.

## MATERIALS AND METHODS

### 1. Preparation of herbal paste

Frankincense (1kg) and myrrh (1kg) were washed with water and dried in room temperature. Then, they were grounded separately to a fine powder passed through 40 mesh sieve and exhausted separately with ethanol (70%). The extracts were dried under vacuum. 221g of dried frankincense extract and 127g of myrrh extract were obtained. The paste was made containing 69.5% of hydrophilic base (gel 2% made with carbomer 940), 10% active ingredients (containing frankincense and myrrh, 1:1), 20% of glycerin, 0.26% of sodium metabisulfite, 0.20% of methylparaben and 0.05% of propylparaben. Then the paste, was preserved in refrigerator to ensure its action was not affected by storage <sup>(11)</sup>.

## 2. Triamcinolone acetone (TA)

Kenacort - A- Orabase Pomad dental paste were used, so that TA is an active ingredient by concentration 1mg/g. This dental paste contains carboxymethyl cellulose sodium, gelatin, and pectin in plastibase (plasticized hydrocarbon gel), a polyethylene and a mineral oil gel base. It was purchased as an ointment from Deva Holding A.S Company<sup>(12)</sup>.

## 3. Animals

75 adult male albino rats (weighting 200-250) were used in the study. The animals were obtained from Theodor Bilharz Institute (Giza, Egypt). The animals were housed in the animal facility of faculty of Pharmacy, Al-Azhar University, Cairo. They were fed with standard diet pellets (proteins, lipids, fibers, NaCl, lysine, methionine, vitamins, salts and wheat) obtained from El-Naser Company, Abou-Zaabal, Cairo, Egypt, and allowed free access to water. The rats were kept in standard cages, under standard conditions of temperature ( $21 \pm 0.5^\circ\text{C}$ ) and relative humidity ( $55 \pm 1$ ) with 12-light/12-dark cycle. They were acclimated for 7 days prior to use in the experiment.

## 4. Ulcer induction:

First, the rats were anesthetized generally by intraperitoneal injection of 0.1 ml of ketamine hydrochloride Combined with 0.05 ml of xylazine hydrochloride per 100 g body weight of the animal<sup>(13)</sup>. After anesthesia, the labial mucosa was antiseptically cleaned with 2% chlorhexidine. The ulcer was induced through wide opening the mouth

and retraction of tongue to the right side then, retraction of the left side upper lip. To control the depth of the induced ulcers, a rubber stopper was placed on the punch in order to produce ulcers with 1 mm of depth. Punch biopsy was held against the labial mucosa in a perpendicular manner, producing uniform circular cutting on labial mucosa, after that excess tissue was removed with a scalpel. Drying

the area by using a cotton pellet. The induced ulcer appeared immediately after application of a punch biopsy instrument. The operation technique was standardized for all the animals. The rats in the experimental groups were received the topical treatment immediately after ulcer induction. The animals were maintained in their standard cages and received standard food and water ad libitum<sup>(14,15)</sup>.

## 5. Specimens collection

The animals (both control and experimental groups) were anesthetized and sacrificed by cervical dislocation and their lips were excised immediately. Specimens were immediately cut perpendicularly to the anterior-posterior axis of the lip, which means the anterior-posterior axis of the wound surface (in the transverse axis<sup>(16)</sup>. The parts of lip containing the induced ulcers were cut with normal margins (2mm) from each side<sup>(17)</sup>.

## 6. Histomorphometric and Statistical analysis

For evaluation of the positive epithelial cells count, the immunoreactivity was measured by an image analysis system (Leica DM LB2 with QWIN plus image analyzer computer system, Germany). This analysis was carried out in the Faculty of Dentistry Al-Azhar University, Cairo. The data obtained from the histomorphometric analysis was statistically calculated and computed to compare the change in the count of positive cells for CD1 between the studied groups. Results were considered significant when probability P value (P) is  $\leq 0.05$  and highly significant when  $P \leq 0.01$ .

## RESULTS

### At day (3)

Group (2) showed disrupted basement membrane, less mitotic figures, few and small keratohyaline granules, thin keratin thread, inflammatory infiltrate, dilated blood vessels, edema and degenerated muscle fibers. Moreover, it showed few and condensed

CD1immunostaining reaction confined to basal and suprabasal cells. The lamina propria showed –ve reaction. While group (3) showed irregular basement membrane, homogenous eosinophilic material obscured the cell outlines, mitotic figures, few and small keratohyaline granules, thick and relatively disrupted keratin layer, inflammatory infiltrate, dilated blood vessels, edema and degenerated muscle fibers. Moreover, it showed deeply stained and condensed CD1immunostaining reaction in basal, suprabasal and some prickle cells. The lamina propria showed –ve reaction. Group (4) was covered with thick and relatively normal orthokeratinized stratified squamous epithelium. Moreover, it showed relatively intact basement membrane. The epithelium showed increased activity represented by numerous mitotic figures and keratohyaline granules appeared large in size, increase in number and densely stained. It is covered by thick and relatively continuous keratin layer. Inflammatory infiltrate, edema and degenerated muscle fibers. Moreover, it showed deeply stained and condensed CD1immunostaining reaction in basal, suprabasal and many prickle cells. The lamina propria showed –ve reaction (Fig.1 [A,B] ).

#### At day (7):

Group (2) the ulcer still opened, the basement membrane in the area away from the defect was observed with flattened epithelial cells, wide intercellular spaces and migrating laterally to coveunderling connective tissue. Less mitotic figures, few and small keratohyaline granules, thin keratin layer and more plump, less spindle and irregularly scattered fibroblasts. Moreover, it showed deeply stained and condensed CD1immunostaining reaction in basal and suprabasal cells. The lamina propria showed –ve reaction. While in group (3) the ulcer still opened, hyperplasia in basal and suprabasal cells with homogenous eosinophilic material still obscured the cell outline of prickle and granular cell layers. Furthermore, the basement membrane is formed with mitotic figures, few and small keratohyaline granules, thick and continuous keratin layer and immature granulation tissue. Moreover, it showed deeply stained and condensed CD1immunostaining reaction in basal, suprabasal and many prickle cells. The lamina propria showed –ve reaction. In group (4) the ulcer was completely closed and covered with typical pattern of orthokeratinized stratified squamous epithelium. Moreover, it showed regular

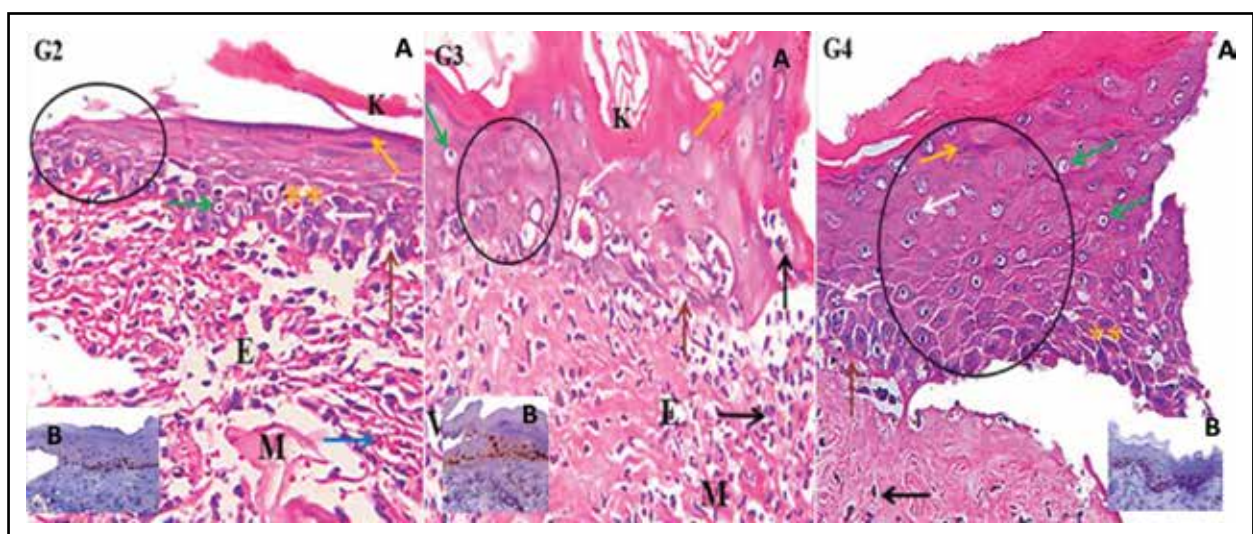


Fig. (1) A) Black arrow (inflammatory cells), white arrow (mitotic figures), green arrow (Clear cells), blue arrow (Area of hemorrhage), yellow arrow (keratohyaline granules), brown arrow (basement membrane), E (Areas of edema), stars (intercellular spaces) and M (degenerated muscle fibers). B) Different degree of stain ability of cells.

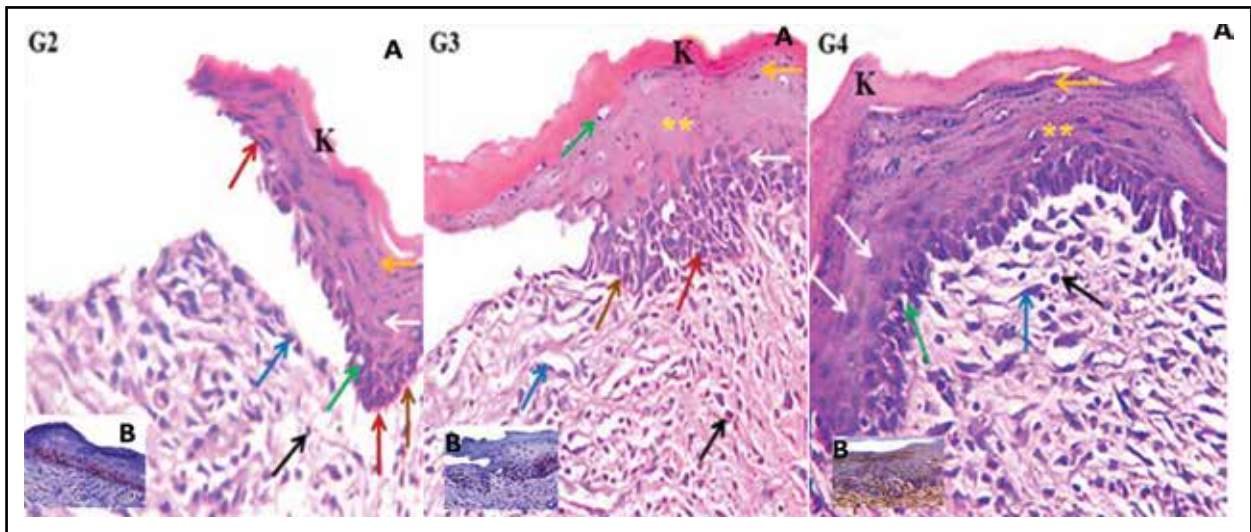


Fig. (2) A) Black arrow (inflammatory cells), white arrow (mitotic figures), green arrow (Clear cells), blue arrow (fibroblasts), brown arrow (basement membrane), red arrow (basal cells) and stars (prickle cells). B) Different degree of stain ability of cells.

and continuous basement membrane, abundant mitotic figures, abundant, large and strongly basophilic keratohyaline granules with thick and continuous keratin layer. The underlying connective tissue showed fibroblasts which appeared abundant, less plump, more spindle, and have more regular arrangement parallel to each other and to basement membrane. Moreover, it showed deeply stained and condensed CD1 immunostaining reaction in all layers of epithelium. The lamina propria showed strong +ve reaction. (Fig.2 [A,B] )

## DISCUSSION

The rationale for searching an alternative medicine to corticosteroid based on the fact that, regardless of the route of administration, corticosteroids can cause systemic adverse effects if absorbed into the circulation. Unfortunately, there is no absolute dose threshold at which adverse effects will not occur<sup>(18)</sup>.

In this study male rats were used weighted 200-250 g. They were ideal model for the study as they possess quite large labial mucosa to enable the ulcer induction. The choice of male rats also cancelled the effect of sex hormones on ulcer healing. Sex

hormones likely modulate oral mucosal wound healing. Studies in rats are of low cost and provide useful information that could be difficult to obtain in humans. In studies with humans, it is difficult to eliminate biases in relation to their behavioral variables, and standardize and maintain the same living conditions during the entire experiment. Thus, the use of rats in this work produced simple information but still capable of encouraging further researches in this area of knowledge<sup>(15)</sup>. The labial mucosa of rat is covered by thin orthokeratinized stratified squamous epithelium while in human it is covered by nonkeratinized stratified squamous epithelium<sup>(19)</sup>.

The general anesthesia was injected intraperitoneally (i.p.) using 0.1 ml of ketamine hydrochloride combined with 0.05 ml of xylazine hydrochloride, per 100 g body weight of the animal. It was good choice because it is an ultra- short acting barbiturate and provides anesthesia for rapid onset and suitable time for small operations. Moreover, when ether was used in pilot study, the recovery time was so rapid. Furthermore, to get anesthesia for longer time, the prolonged exposure time to ether, caused death of some rats<sup>(20)</sup>.



The ulcers were induced in the upper labial mucosa of all animals mechanically by means of a punch-biopsy instrument (2.5mm in diameter) because this method was very successful and useful for creating uniform ulcer diameters and minimal trauma to the surrounding tissues as compared to chemical induced ulcer. The upper lip was chosen as it was thicker than lower lip and easy of application of punch biopsy on it. The ulcers were done so that their depths would include the submucosa. The punch was applied so that the induced ulcer will be centralized and surrounded by an intact labial mucosa. This helped examining the ulcer, following its healing and comparing the lesion with the surrounding normal labial mucosal tissue<sup>(14,15)</sup>. It had been proved from the histological results of frankincense and myrrh group and TA group influenced ulcer treatment that was further confirmed through the immunohistochemical labeling for CD1.

Statistical analysis confirmed the histological and the immunohistochemical findings. The lowest mean area percent was in group (1) (+ve control group). In experimental groups, at day 1, 3 and 7, the greatest mean area percent was recorded in group (4), followed by group (3), with the lowest mean in group (2). Moreover, group (2) and group (3) revealed that the mean area percent gradually increased from day 1 to day 3 and day 7. However in group (4) the mean area percent gradually increased from day 1 to day 3, then decreased at day 7.

In the present study, it was noted that frankincense and myrrh enhanced the proliferation of the epithelial cells as immunoexpression of CD1 was greatly increased in group (4) in comparison to TA and control groups. The epithelial thickness and the rate of epithelialization are factors to be considered in the process of ulcer healing. A higher rate of cell proliferation associated with increased expression of growth factors and their receptors could facilitate recovery of the epithelium and thereby enhanced the healing process. Stimulation of re-epithelialization of the tissue represents an important step towards resolution of the lesion<sup>(21)</sup>.

This enhancement of ulcer healing caused by frankincense may be attributed to several chemical constituents that had different pharmacologic activities and could enhance the health and vitality of the cells as well as promote tissue repair. These constituents include  $\beta$ -BA, AKBA, limonene, esters e.g. duva-3, 9, 13-trien-1, 5a-diol-1- acetate, KBA, incensole, triterpene acids, tannins, terpenoids, sterols and flavonoids<sup>(22)</sup>.

Moreover, this enhancement of ulcer healing caused by myrrh may be attributed to several chemical constituents that had different pharmacologic activities and could enhance the wound healing. These constituents include flavonoids, T-cadinol, muscanone, alkaloid, coumarin, tannins, myrrhanol A, myrrhanone A, guggulsterone, mansumbinone, 3,4-seco-mansumbinoic acid and two octanodamarane triterpenes<sup>(23,24)</sup>.

The greatest enhancement of ulcer healing shown in combination of frankincense and myrrh compared to the other groups may be attributed to synergistic effects of the constituents present in both of them<sup>(25)</sup>.

## CONCLUSIONS

1. Combination of frankincense and myrrh enhanced the healing of induced ulcer in labial mucosa of rats compared to triamcinolone acetate and control groups.
2. Frankincense and myrrh have a controlled healing effect on labial ulcer with minimal side effects.
3. The use of frankincense and myrrh in clinical practice may provide a promising and effective therapeutic aid for enhancing healing of labial ulcer.

## REFERENCES

1. Muñoz-Corcuera, M., Esparza-Gómez, G., González-Moles, M. A., and Bascones-Martínez, A. Oral ulcers: clinical aspects. A tool for dermatologists. Part I. Acute ulcers. *Clin Exp Dermatol* 2009; (34): 289- 94.

2. Gosain A., and Dipietro LA. Aging and wound healing. *World J. Surg* 2004; (28): 321- 6.
3. Mathieu D, Linke J-C, Wattel F. Non-healing wounds. In: *Handbook on hyperbaric medicine*, Mathieu DE, editor. Netherlands: Springer 2006; pp.401- 27.
4. Rao, P. S. Recurrent aphthous stomatitis: a review. *J Orofac Sci* 2010; (2): 60-5.
5. González-Moles MA. The use of topical corticoids in oral pathology. *Med Oral Patol Oral Cir Bucal* 2010; (15): 827-31.
6. González-Moles MA, Scully C. Vesiculo-erosive oral mucosal disease – management with topical corticosteroids: (1) Fundamental principles and specific agents available. *J Dent Res* 2005; (84): 294- 301.
7. Rabiyyi M, Sahebamee M. Effect of aqueous triamcinolone acetate 0.2% suspension in treatment of oral lichen planus. *J Guilan University Med Sci* 2003; (12): 6 - 14.
8. Vena GA, Cassano N, Dargento V, Milani M. Clobetasol propionate 0.05% in a novel foam formulation is safe and effective in the short-term treatment of patients with delayed pressure urticaria: a randomized, double-blind, placebo- controlled trial. *Br J Dermatol* 2006; (154): 353- 6.
9. Rafie H, Soheila H, Mohsen H, Mina S, Hamidpour R. Chemistry, Pharmacology and Medicinal Property of Frankincense (*Boswellia* Species): From the Selection of Traditional Applications to the Novel Phytotherapy for the Prevention and Treatment of Serious Diseases. *Global Journals Inc* 2015; (15):15- 22.
10. Ashry KM, El-Sayed YS, Khamiss RM and El- Ashmawy IM. Oxidative stress and immunotoxic effects of lead and their amelioration with myrrh (*Commiphora molmol*) emulsion. *Food Chem Toxicol* 2010; (48): 236- 41.
11. Jahandideh M, Hajimehdipoor H, Mortazavi S.A, Dehpour A, Hassanzadeh G. A Wound Healing Formulation Based on Iranian Traditional Medicine and Its HPTLC. *Iranian J Pharm Res* 2016; (15): 149- 57.
12. Levin C, Maibach HI. Topical corticosteroid-induced adrenocortical insufficiency: clinical implications. *Am J Clin Dermatol* 2002; (3): 141- 7.
13. Moraes L, Trevilatto P, Gregio A, Machado M and Lima A. Quantitative analysis of immature collagen during oral wound healing in rats treated by Brazilian Propolis. *J Int Dent Med Res* 2011; (4):106- 10.
14. Sultana, J., Molla, M. R., Kamal, M., Shahidullah, M., Begum, F., et al. Histological differences in wound healing in maxillofacial region in patients with or without risk factors. *Bangladesh J Pathol* 2009; (24): 3- 8.
15. Ali, Z. H., & Dahmouh, H. M. Propolis versus Daktarin (R) in mucosal wound healing. *Life Sci J* 2012; (9): 624- 36.
16. Evrard L, Nammour S and Dourov N. Scanning electron microscopic and immunocytochemical studies of contraction during secondary CO2 laser wound healing in the tongue mucosa. *J Oral Patho Med* 1996; (25): 72- 7.
17. Slomiany B and Slomiany A. Biphasic role of Platelet Activating Factor in Oral Mucosal Ulcer Healing. *IUBMB Life* 2003; (55): 483- 90.
18. Martins M, Marques M, Bussadori S, Martins M, Pavesi V, et al. A Comparative Analysis between *Chamomilla recutita* and Corticosteroids on Wound Healing. An In Vitro and In Vivo Study. *Phytother Res* 2009; (23): 274 - 8. 124. Prabhu S.R, Squire C.A. and Johnson N.W: The effect of ultra – violet radiation and restricted diet on rat labial mucosa. *J Oral Pathol* 1978; (7):143 – 55.
19. Prabhu S.R, Squire C.A. and Johnson N.W: The effect of ultra – violet radiation and restricted diet on rat labial mucosa. *J Oral Pathol* 1978; (7):143 – 55.
20. Moraes L, Trevilatto P, Gregio A, Machado M and Lima A. Quantitative analysis of immature collagen during oral wound healing in rats treated by Brazilian Propolis. *J Int Dent Med Res* 2011; (4):106- 10.
21. Fukuda Y, Ito Y, Azumi H, Eid N, Li Z, et al. Cell death and proliferation in Nd- YAG laser electrocautery and scalpel wounds on mice skin. *J Dermatol Sci* 2002; (28):106- 18.
22. Mikhaeil, B.R., Maatooq, G. T., Badria, F. A., & Amer, M. Chemistry and immunomodulatory activity of frankincense oil. *Zeitschrift für Naturforschung C* 2003; (58): 230- 8.
23. El-Ashry, E.S.H., Rashed, N., Salama, O.M. et al. Components, therapeutic value and uses of myrrh. *Die Pharmazie* 2003; (58): 163- 8.
24. Meselhy, M.R. Inhibition of LPS-induced NO production by the oleo gum resin of *Commiphora wightii* and its constituents. *J Phytochem* 2003; (62): 213- 8.
25. De Rapper, S., Van Vuuren, S. F., Kamatou, G. P.P., Viljoen, A. M., & Dagne, E. The additive and synergistic antimicrobial effects of select frankincense and myrrh oils—a combination from the pharaonic pharmacopoeia. *J Lett Appl Microbiol*, 2012; (54): 352-358.