

Expression of Hypoxia Inducible Factor-1 α Correlates with Microvessel Density in Glioblastoma Multiforme

MOHAMED WAGIH, M.D.

The Department of Pathology, Faculty of Medicine, Beni-Suef University, Egypt

Abstract

Background: Glioblastoma multiforme (GBM) is the most aggressive brain tumour characterized by marked angiogenesis, invasiveness and poor outcome. Intratumoral hypoxia possibly plays a key role in GBM growth and angiogenesis. A key regulator of adaptive response to hypoxia is the hypoxia inducible factor 1-alpha (HIF-1 α) protein.

Aim of Study: The present study aimed to evaluate the expression of HIF-1 α in tumour cells of GBM and analyze its relation to tumour microvessel density.

Material and Methods: Fifty formalin fixed paraffin embedded tissue blocks of GBM were studied immunohistochemically for HIF-1 α expression using anti-HIF-1 α monoclonal antibody and for microvessel density using anti-CD34 monoclonal antibody.

Results: HIF-1 α expression was observed in 86% of the studied cases. The immunostaining scores were negative in 14%, weak positive in 20%, moderate positive in 28% and strong positive in 38% of cases. The mean microvessel counts were 14.3 ± 11.5 in the negative cases, 21.6 ± 15.8 in the weak positive cases, 27.2 ± 21.7 in the moderate positive cases and 32.8 ± 16.3 in the strong positive cases. A statistically significant relation was found between the expression of HIF-1 α protein and microvessel density in the studied GBM cases ($p=0.01$).

Conclusion: Our findings have shown that expression of HIF-1 α protein is correlated to the microvessel density in GBM, supporting evidence that different types of tumours can induce aberrant angiogenesis through HIF-1 α . Thus, an understanding of the relationship between HIF-1 α and tumour angiogenesis in GBM may provide further therapeutic opportunities for patients with this tumour.

Key Words: Glioblastoma Multiforme – Hypoxia Inducible Factor-1 α – Microvessel Density.

Introduction

GLIOBLASTOMA multiforme is the most frequent primary malignant brain tumour in adults [1]. Despite great advances in both diagnostic and treatment modalities, glioblastomas are associated with the poorest survival time, which is typically 1-2 years [2].

Correspondence to: Dr. Mohamed Wagih,
E.Mail: mohamwagih@hotmail.com.

Angiogenesis is the process leading to the formation of new blood vessels. It has been linked to tumour growth and metastatic potential in many tumours [3]. However, most malignant tumours contain areas of hypoxia, due to unrestrained tumour growth outpacing the rate of microvascular hyperplasia and to aberrant microcirculation influencing oxygen diffusion to tumour cells [4].

Several evidences have previously highlighted intratumoral hypoxia as a major factor inducing tumour angiogenesis [5,6,7]. Although the molecular events in this pathway are not fully clarified, hypoxia inducible factor (HIF)-1 has appeared as a chief transcriptional factor implicated in the cellular response to hypoxia [8]. HIF-1 consists of two subunits, HIF-1 α and HIF-1 β . The transcriptional activity of HIF-1 is dependent mainly on the quantity of HIF-1 α protein in the cell, while HIF-1 β is constitutively present irrespective of oxygen level [9,10].

Upon exposure to hypoxia, HIF-1 α evades proteasome mediated degradation and translocates in the nucleus where it dimerizes and creates an active complex with HIF-1 β that binds to hypoxia responsive elements (HRE) and prompts transcription of several genes implicated in tumour angiogenesis, invasion, cell survival and anaerobic metabolism [11]. As a result, HIF-1 α and its signaling pathway have become targets for cancer chemotherapy aiming to inhibit angiogenesis [12].

Given the long recognized prominence of vasculature in GBM, this study aimed to analyze the correlation between the immunohistochemical expression of HIF-1 α and microvessel density to investigate the potential role of HIF-1 α in the regulation of angiogenesis in a series of GBM affecting a group of Egyptian patients.

Patients and Methods

Samples:

The material of the present study consisted of fifty formalin fixed paraffin embedded tissue samples of glioblastoma multiforme received after surgical resection. All cases were collected retrospectively from diverse sources during the period from March 2018 to August 2018. The clinical data including age, sex and tumour location were recorded from the patients' files. Three sections were prepared from each block and stained with hematoxylin and eosin for routine histopathological evaluation, anti-HIF-1 α monoclonal antibody to assess the expression of HIF-1 α protein and anti-CD34 monoclonal antibody to evaluate the microvessel density in the studied cases.

Immunohistochemistry:

Sections prepared from the tumour tissue were examined using the avidin biotin peroxidase method. The primary antibodies used were the monoclonal mouse anti-HIF-1 α (clone MS213, DAKO, Glostrup, Denmark) diluted at 1: 50 and the monoclonal mouse anti-CD34 (clone SR806, DAKO, Glostrup, Denmark) diluted at 1: 60.

The sections were deparaffinized in xylene and rehydrated in graded alcohol series. Endogenous peroxidase activity was blocked by adding 3% hydrogen peroxide for 5 minutes. To enhance antigen retrieval, the sections were microwave treated in phosphate buffer saline (PBS) at 100°C for 15 minutes and were allowed to cool for 30 minutes then washed with PBS for 5 minutes. Then, a blocking serum was added for 20 minutes to suppress nonspecific binding of immunoglobulins. Next, the sections were incubated with the primary antibodies after reconstitution overnight at 4°C. Then, one to two drops of biotinylated secondary antibody were applied to cover the section entirely followed by incubation with performed avidin biotinylated peroxidase complex (DAKO). Through wash with phosphate buffer saline after each indicated step was done. The sections were treated with DAB (3,3 diaminobenzidine tetrahydrochloride) (DAKO) as a chromogen and incubated for 3 minutes. Finally, the slides were counterstained in hematoxylin then dehydrated and mounted. A section of HIF-1 α positive breast carcinoma was used as a positive control for HIF-1 α while the positive control employed for CD34 was a tissue section obtained from a hepatic angiosarcoma. The negative controls were prepared by omitting the primary antibody and instead phosphate buffer saline was used in this step.

HIF-1 α Immunostaining Interpretation:

In each case, the entire section was examined microscopically in ten high power fields (X400) for HIF-1 α immunoreactivity. Positive HIF-1 α immunostained cells showed brown nuclear deposition of chromogen at the antigen antibody binding site. The nuclear intensity of HIF-1 α immunoreactivity was scored as: (–): Negative (no staining), (+): Weak positive (less than 10% stained positive nuclei), (++) Moderate positive (10-30% stained positive nuclei) and (+++): Strong positive (more than 30% stained positive nuclei) [13].

MVD Evaluation:

For MVD evaluation, tumour areas with the highest density of microvessels highlighted by CD34 antibody were chosen at low power field (X100). Microvessel counting was performed on X200 magnification in five areas and the mean value was determined statistically [14].

Statistical Analysis:

SPSS version 16 was used for statistical analysis. The association between staining scores and the studied parameters was analyzed using the Chi square and Fisher's exact test. Statistical significance was considered with a *p*-value less than 0.05.

Results

The clinical features of the studied GBM cases are represented in Table (1). There were 33 (66%) male and 17 (34%) female cases, with ages ranging from 27 to 82 years and a mean age of 56.8 years. Out of the 50 cases, 14 (28%) cases were located in the temporal lobe, 11 (22%) in the frontal lobe, 8 (16%) in the parietal lobe, 4 (8%) in the occipital lobe, 5 (10%) in the temporo-parietal region, 4 (8%) in the fronto-temporal region, 3 (6%) in the parieto-occipital region and 1 (2%) in the fronto-parietal region.

Overall, HIF-1 α expression was found in 43 (86%) of the studied 50 patients. The results of HIF-1 α immunostaining were as follows: Negative in 7 (14%) cases, weak positive in 10 (20%) cases, moderate positive in 14 (28%) cases and strong positive in 19 (38%) cases (Table 2). There was a statistically significant relation between HIF-1 α expression and the microvessel density in the studied GMB cases. The mean microvessel counts were 14.3 ± 11.5 , 21.6 ± 15.8 , 27.2 ± 21.7 and 32.8 ± 16.3 in the negative, weak positive, moderate positive and strong positive cases respectively (*p*=0.01) (Table 3).

Table (1): Clinical features of studied GBM cases.

	N	%
<i>Age</i>		
<60 years	31	62
≥60 years	19	38
<i>Gender:</i>		
Males	33	66
Females	17	34
<i>Tumour Location:</i>		
Temporal	14	28
Frontal	11	22
Parietal	8	16
Occipital	4	8
Temporo-parietal	5	10
Fronto-temporal	4	8
Parieto-occipital	3	6
Fronto-parietal	1	2

Table (2): HIF-1 α expression in the studied GBM cases.

HIF-1 α Expression	N	%
Negative	7	14
Weak Positive	10	20
Moderate Positive	14	28
Strong Positive	19	38

Table (3): Relation between HIF-1 α expression and MVD in the studied GBM cases.

HIF-1 α Expression	MVD (Mean ± SD)	p-value
Negative	14.3±11.5	0.01
Weak Positive	21.6±15.8	
Moderate Positive	27.2±21.7	
Strong Positive	32.8±16.3	

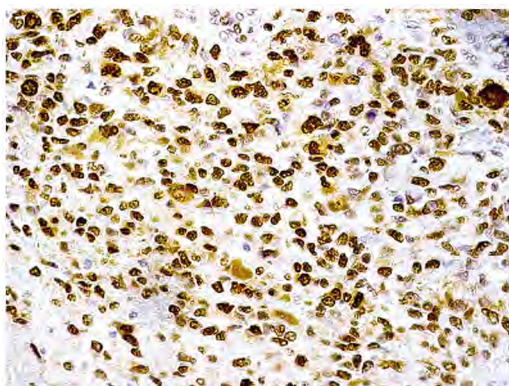


Fig. (1): GBM showing positive nuclear expression for HIF-1 α (IHC, X400).

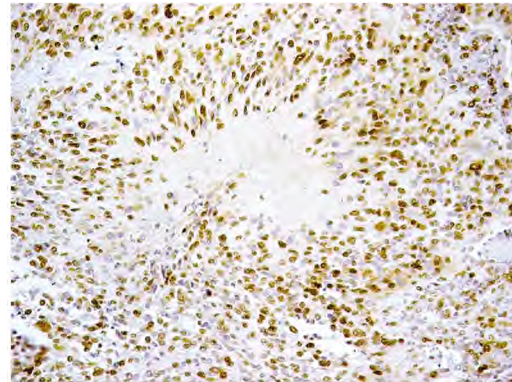


Fig. (2): GBM showing positive expression for HIF-1 α in palisading tumour cells surrounding a necrotic area (IHC, X200).

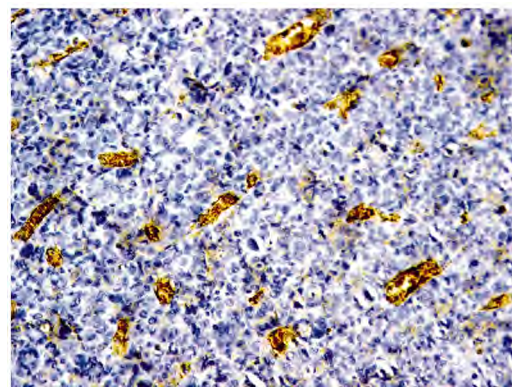


Fig. (3): GBM showing microvascular proliferation immunolabeled with CD34 (IHC, X200).

Discussion

GBM is the most common primary brain tumour characterized by prominent new blood vessel formation, which is an important indicator of poor prognosis [15].

One of the major triggers for tumoral angiogenesis is the physiological response to hypoxia. This is obvious in GBM, where the close relationship between vascular proliferation and necrosis can be attributed to an angiogenic response to low oxygen concentration in nearby necrotic areas [16]. Definitely, tumour cells palisading around necrotic areas show high expression of hypoxia inducible regulators of angiogenesis such as VEGF [17].

In several cancers, HIF-1 α is over expressed early during tumour development, with expression directly related to the microvessel density of the lesions. A similar phenomenon is observed in malignant gliomas, implying that HIF-1 activity contributes to the angiogenic switch through increased production of pro-angiogenic factors [18].

Previous evidence suggested that glioblastomas take advantage of hypoxia mediated HIF activation

by up-regulating two growth factors, PDGF-BB and VEGF. PDGF-BB sustains glioblastoma growth via autocrine and paracrine cell regulatory mechanisms [19], while VEGF supports glioblastoma growth via a paracrine influence on endothelial cells [18].

HIF-1 α is implicated in tumorigenesis via two major mechanisms: Hypoxia-dependent mechanisms, which are observed nearby to the necrotic zones, and hypoxia independent mechanisms, like activation of oncogenes and signaling pathways involving growth factors. The significance of HIF-1 α to tumour growth and progression is emphasized by several mechanisms controlled by HIF target genes, including angiogenesis, increased tissue oxygenation over glycolysis, pH regulation leading to energy production in response to low oxygen levels, cell proliferation and survival pathways [20]. Intratumoral hypoxia is directly related to the tumour's biological aggressiveness and clinical recurrence, while it inversely correlates with the post-operative survival of patients with gliomas [21,22].

As angiogenesis and cellular response to hypoxia are key steps in tumour progression, with HIF-1 α representing a fundamental factor in regulating cellular oxygen homeostasis, targeting HIF-1 may be valuable in treating aggressive brain tumours. Approaches proposed for targeting HIF-1 α include disrupting the normal coactivational response to hypoxia, using decoy oligonucleotides and a gene therapy dependent on HRE regulated gene expression which exploits the presence of hypoxia in tumours to induce therapeutic genes [23].

The current study revealed a statistically significant relationship between HIF-1 α expression and microvessel density in the studied GBM cases ($p=0.01$). In agreement with our findings, Musumeci et al., 2005 [24] verified that increased expression of angiogenic markers correlates with HIF-1 α expression in GBM supporting previous evidence that different types of tumours can induce aberrant angiogenesis through HIF-1 α . Furthermore, in vitro studies revealed that in tumours that over express HIF-1 α , the growth is enhanced due to decreased hypoxia induced apoptosis and increased stress induced proliferation. Alternatively, loss of HIF-1 α reduces the expression of VEGF, inhibiting tumoral angiogenesis and impairs vascular function, resulting in hypoxic microenvironments [25].

In conclusion, our findings suggest that hypoxia inducible factor-1 α could be implicated in GBM

angiogenesis, suggesting that it is a potential therapeutic target of this tumour. However, further studies about the role of HIF-1 α and its molecular regulators in GBM pathogenesis may improve therapeutic outcomes for this aggressive tumour.

References

- 1- ALEXIOU G., GOUSSIA A., VOULGARIS S., FOTOPOULOS A., FOTAKOPOULOS G., NTOULIA A., ZIKOU A., TSEKERIS P. and KYRITSIS A.: Prognostic significance of MRP5 immunohistochemical expression in glioblastoma. *Cancer Chemother. Pharmacol.*, 69 (5): 1387-91, 2012.
- 2- OKITA Y., NARITA Y., MIYAKITA Y., OHNO M., FUKUSHIMA S., KAYAMA T. and SHIBUI S.: Pathological findings and prognostic factors in recurrent glioblastomas. *Brain. Tumor. Pathol.*, 29 (4): 192-200, 2012.
- 3- ONGURU O., GAMISZKAN M., ULUTIN C. and GUNHAN O.: Cyclooxygenase-2 (Cox-2) expression and angiogenesis in glioblastoma. *Neuropathology*, 28: 29-34, 2008.
- 4- DANG C. and SMENZA G.: Oncogenic alterations of metabolism. *Trends. Biochem. Sci.*, 24: 68-72, 1999.
- 5- DOR Y. and KESHT E.: Oxygen and tumour angiogenesis. In *Angiogenesis in Health and Disease*. Ed. GM Rubanyi. New York: Marcel. Dekker. Inc., 245-60, 2000.
- 6- JURGENSEN J., ROSENBERGER C., WEISNER M., WARNECKE C., HORSTRUP J., GRAFE M., PHILIPP S., GRIETHE W., MAXWELL P., FREI U., BACHMANN S., WILLENBROCK R. and ECKARDT K.: Persistent induction of HIF-1 alpha and-2 alpha in cardiomyocytes and stromal cells of ischemic myocardium. *Faseb. J.*, 18: 1415-1417, 2004.
- 7- DERY M., MICHAUD M. and RICHARD D.: Hypoxia inducible factor 1: Regulation by hypoxic and non hypoxic activators. *Int. J. Biochem. Cell. Biol.*, 37: 535-540, 2005.
- 8- KAYNAR M., SANUS G., HNIMOGLU H., KARCIRA T., TANRIVERDI KEMERDERE R., ATUKEREN P., GUMUSTAS K., CANBAZ B. and TANRIERDI T.: Expression of hypoxia inducible factor-1 α in tumours of patients with glioblastoma multiforme and transitional meningioma. *Journal of Clinical Neuroscience*, 15: 1036-1042, 2008.
- 9- RAPISARDA A. URACHIMEG B., SCUDIERO D., et al.: Identification of small molecule inhibitors of hypoxia inducible factor-1 transcriptional activation pathway. *Cancer Res.*, 62: 4316-24, 2002.
- 10- CHUN Y., CHOI E., KIM T., et al.: A dominant negative isoform lacking exons 11 and 12 of the human hypoxia inducible factor-1 α gene. *Biochem. J.*, 362: 71-9, 2002.
- 11- CHAN D., SUTPHIN P., DENKO N., et al.: Role of prolyl hydroxylation in oncogenically stabilized hypoxia-inducible factor-1 α . *J. Biol. Chem.*, 277: 40112-7, 2002.
- 12- LAZARO-LOPEZ M.: Hypoxia inducible factor 1 as a possible target for cancer chemoprevention. *Cancer Epidemiol. Biomarkers Prev.*, 15: 12-5, 2006.
- 13- CLARA C., MARIE S., DE ALMEIDA J., WAKAMATSU A., SHINJO S., UNO M., NEVILLE M. and ROSEM-

- BERG S.: Angiogenesis and expression of PDGF-C, VEGF, CD105 and HIF-1 α in human glioblastoma. *Neuropathol.*, 34: 343-352, 2014.
- 14- WEIDNER N., SEMPLE J., WELCH W. and FOLKMAN J.: Tumour angiogenesis and metastasis-correlation in invasive breast carcinoma. *N. Engl. Med.*, 324 (1): 1-8, 1991.
- 15- SONDERGAARD K. HILTON D. PENNEY M., OLLE-RENSHAW M. and DEMAINE A.: Expression of hypoxia inducible factor 1- α in tumours of patients with glioblastoma. *Neuropathol. Appl. Neurobiol.*, 28: 210-217, 2002.
- 16- PLATE K., BREIER G., WEICH H. and RISAU: Vascular endothelial growth factor is a potential tumour angiogenesis factor in human gliomas in vivo. *Nature*, 359: 845-848, 1992.
- 17- SHWEIKI D., ITIN A., SOFFER D. and KESHET E.: Vascular endothelial growth factor induced by hypoxia may mediate hypoxia-initiate angiogenesis. *Nature*, 359: 843-845, 1992.
- 18- PLATE K. and RISAU W.: Angiogenesis in malignant gliomas. *Glia.*, 15: 339-47, 1995.
- 19- SMITS A. and FUNA K.: Platelet derived growth factor (PDGF) in primary brain tumours of neuroglial origin. *Histol. Histopathol.*, 13: 511-20, 1998.
- 20- BRAT D. and MAPSTONE T.: Malignant glioma physiology: Cellular response to hypoxia and its role in tumour progression. *Ann. Intern. Med.*, 138: 659-68, 2003.
- 21- ACKER T. and PLATE K.: Hypoxia and hypoxia inducible factors (HIF) as important regulators of tumour physiology. *Cancer Treat. Res.*, 117: 219-48, 2004.
- 22- FISCHER I., GAGNER J. and LAW M.: Angiogenesis in gliomas: Biology and molecular pathophysiology. *Brain. Pathol.*, 15: 297-310, 2005.
- 23- POWIS G. and KIRKPATRICK L.: Hypoxia inducible factor-1 α as a cancer drug target. *Mol. Cancer Ther.*, 3: 647-54, 2004.
- 24- MUSUMECI G., CASTORINA A., MAGRO G., CARDILE V., CASTORINA S. and RIBATTI P.: Enhanced expression of CD31/platelet endothelial cell adhesion molecule 1 (PECAM1) correlates with hypoxia inducible factor-1 alpha (HIF-1 α) in human glioblastoma multiforme. *Experimental. Cell. Research.*, 339 (2): 407-10, 2015.
- 25- CARNNELIET P., DOR Y., HERBERT J., FUKUMURA D., BRUSSELMANS K., DEWERCHIN M., NEEMAN M., BONO F. ABRAMOVITCH R., MAXWELL P., KOCH C., RATCLIFFE P., MOONS L., JAN R., COLLEN D. and KESHET E.: Role of HIF-1 alpha in hypoxia mediated apoptosis, cell proliferation and tumour angiogenesis. *Nature*, 394: 485-490, 1998.

تعبير العامل المسبب لنقص الأكسجين -1 ألفا يتناسب مع كثافة الأوعية الدموية في ورم الأرومة الدبقية بالمخ

يعتبر ورم الأرومة الدبقية من أكثر أورام المخ شيوعاً وشراسة، ويتميز هذا الورم بكثافة مرتفعة من الأوعية الدموية ذات علاقة مباشرة بشراسة الورم وانتشاره مما يؤدي إلى ضعف التكهن المستقبلي لهذا الورم. وتتميز خلايا هذا الورم الشرس بنقص في تركيز الأكسجين مما قد يكون له دوراً مهماً في نمو الورم وتكون الأوعية الدموية. ويعتبر العامل المسبب لنقص الأكسجين -1 ألفا المنظم المحوري لإستجابة الخلايا لنقص الأكسجين.

تستهدف هذه الدراسة تقييم التعبير المناعي الهستوكيميائي لبروتين العامل المسبب لنقص الأكسجين-1 ألفا في خلايا ورم الأرومة الدبقية بالمخ وتحليل العلاقة بينه وبين كثافة الأوعية الدموية بالورم. وقد أشتمل هذا البحث على 50 حالة لورم الأرومة الدبقية بالمخ وتم دراسة تعبير بروتين العامل المسبب لنقص الأكسجين -1 ألفا في الخلايا السرطانية بإستخدام الأجسام المضادة الأحادية لبروتين العامل المسبب لنقص الأكسجين -1 ألفا، كما تم دراسة كثافة الأوعية الدموية في الورم بإستخدام الأجسام المضادة الأحادية لاسي د 34. وقد وجد تعبير مناعي هستوكيميائي إيجابي لبروتين العامل المسبب لنقص الأكسجين -1 ألفا في 43 (٪86) حالة من الحالات المدروسة من بينها 10 (٪20) حالات بها تعبير إيجابي منخفض و14 (٪28) حالة بها تعبير إيجابي متوسط و19 (٪38) حالة بها تعبير إيجابي مرتفع بينما كانت سبعة حالات (14٪) ذات تعبير سلبي. وكان متوسط كثافة الأوعية الدموية 11.0 ± 14.3 في الحالات السلبية. 10.8 ± 21.6 في الحالات منخفضة التعبير، 21.7 ± 27.2 في الحالات متوسطة التعبير و 16.3 ± 22.8 في الحالات مرتفعة التعبير لبروتين العامل المسبب لنقص الأكسجين -1 ألفا. كما أظهرت نتائج هذه الدراسة وجود علاقة إحصائية ذات دلالة بين بروتين العامل المسبب لنقص الأكسجين -1 ألفا وكثافة الأوعية الدموية في ورم الأرومة الدبقية بالمخ مما يؤكد الأدلة السابقة في أورام مختلفة أن العامل المسبب لنقص الأكسجين -1 ألفا له دوراً مهماً في تكون الأوعية الدموية.

ونوصى في هذه البحث بإجراء المزيد من الدراسات لدراسة العلاقة بين العامل المسبب لنقص الأكسجين -1 ألفا وكثافة الأوعية الدموية في ورم الأرومة الدبقية بالمخ مما قد يفتح المجال لمزيد من وسائل العلاج المختلفة للمرضى المصابين بهذا الورم.