

## Osteo-Protective Effect of Curcumin, Fenugreek and their Combination on Ovariectomized Female Rats

Nesma M.E. Abo El- Nasr\*, Ezz Eddin El-Denshary\*\*, Sawsan S. Mahmoud\* and Salwa M. Nofal\*

\*Department of Pharmacology, Medical Division, National Research Centre, Cairo, Egypt and\*\* Department of Pharmacology and Toxicology, Faculty of Pharmacy, Cairo University, Cairo, Egypt.

**T**HE MOST common type of osteoporosis is the bone loss associated with ovarian hormonal deficiency at menopause. It is characterized by an imbalance between bone resorption and formation, resulting in a decrease of bone mass and a deterioration of bone microarchitecture. Purified curcumin, Fenugreek extract and their combination were evaluated for improvement of bone loss on ovariectomized rats as a model of postmenopausal osteoporosis. 60, female Wistar rats weighing 130150-g were ovariectomized (OVX) except sham-operated (SH) group. Rats fed a soya bean deficient diet and randomly divided into 5 groups. After 3 months of ovariectomy, SH group and OVX control group was received 1 % DMSO (1 ml/kg P.O.), while, other OVX groups were received curcumin (100mg/kg p.o.), alcoholic fenugreek extract (200mg/kg p.o.) and their combination (Received the same doses of drugs). Fumer, tibia and total bone mineral density showed significant decrease in OVX control vs. sham control, while the combination of curcumin and fenugreek showed significant increase compared with OVX control group. Data obtained showed that curcumin, significantly, decreased the bone loss. In addition, curcumin combined with alcoholic fenugreek extract showed a synergistic effect that consequently improved both bone turnover and bone strength.

**Keywords:** Curcumin- fenugreek- rats- osteoporosis- menopause- hormonal deficiency

### Introduction

Menopause, is the permanent cessation of menstruation due to loss of the ovarian function [1], combined with a decrease in the levels of estrogens affecting many organs in the body and producing a variety of signs and symptoms [2, 3]. Postmenopausal osteoporosis- a major public health problem that occurs due to estrogen loss-associated with reduction in bone mineral content with disarrangement in bone microarchitecture, resulting in skeletal fragility with a consequent increased fracture risk [4].

Bone cells contain both estrogen and androgen hormone receptors [5]. Estrogen exhibits both skeletal and extra-skeletal activities that in case of their deficiency contribute to the pathogenesis of osteoporosis. Skeletal activities are divided into direct and indirect ones. Direct skeletal activities are based upon estrogen receptors on osteoblasts and osteoclasts [6, 7].

On other hand, indirect activities of estrogens are mediated by estrogen receptors on stromal cells preventing RANKL/M-CSF binding, in addition to up regulating of osteoclastogenesis-inhibitory factor called osteoprotegerin (OPG) upon estrogen exposure, which acts as a decoy receptor for preventing RANKL/RANK binding [8]. Besides that estrogen inhibits RANK/RANKL by regulating the synthesis of numerous cytokines and growth factors such as (IL)-1- and IL-61, TNF $\alpha$ , PGE2 and M-CSF [9-12]. Subsequently inhibits osteoclastogenesis, osteoclast activity and bone resorption [13, 14].

On the other hand, estrogen deficiency results in increased production of IL-7, leading to T cell activation. This is accompanied by an increased production of IFN- $\gamma$  and TNF- $\alpha$  by T cells [15-17]. One major action of IFN- $\gamma$  is the up-regulation of major histocompatibility complex (MHC) class II molecules on antigen presenting cells, such as

bone marrow macrophages and dendritic cells. This leads to a further activation of T cells, which produces more RANKL and TNF- $\alpha$  [18].

Effects of extra-skeletal estrogen deficiency are mainly based upon increased renal calcium excretion and decreased intestinal calcium absorption [19]. Estrogen plays an important role in calcium absorption in the gut [20] and its reabsorption in the kidney [21]. The presence of estrogen receptors in the intestine has been reported and has been shown to increase intestinal calcium absorption in both rats [22, 23] and humans [24].

Curcumin (Diferuloylmethane, 1, 7- bis (4-Hydroxy-3-methoxyphenyl)-1,6-heptadiene-3, 5 - dione) [25] is the active polyphenolic compound extracted from the rhizomes of turmeric (*Curcuma longa L.*, *Zingiberaceae*) a member of the ginger family, grown in tropical Southeast Asia [26]. Some studies demonstrated the efficacy of turmeric extracts in the prevention of bone loss in animal models of rheumatoid arthritis and postmenopausal osteoporosis [27-29]. In vitro investigations have identified that the anti-inflammatory effects of curcumin able to prevent osteoclast differentiation [30, 31]. Thus, curcumin produces beneficial changes in bone turnover and increase in bone strength using the ovariectomized mature rat model of postmenopausal osteoporosis [32, 33].

Fenugreek (*Trigonella Foenum-Graecum*, *Leguminosae*) is one of the oldest medicinal plants, originating in Southern Europe, Northern Africa and India [34, 35]. Numerous studies have been carried out to reveal the therapeutic potential of fenugreek in various pathological conditions such as diabetes mellitus [36-38], cancer [39, 40], gastric disorders, gastric ulcers [41] and obesity [42]. Finally, Diosgenin in fenugreek suppresses osteoclastogenesis, which subsequently leads to bone loss [43].

The aim of this study was to evaluate the effects of curcumin, alcoholic fenugreek extract and their combination in the improvement of bone loss on ovariectomized rats as a model for postmenopausal osteoporosis.

## **Material and Methods**

Sixty of female Wister rats weighing 130-150 were obtained from the animal house colony

of the National Research Centre (Giza, Egypt). Animals were kept under suitable environmental conditions throughout the period of investigation, in an ambient temperature ( $25 \pm 2^\circ\text{C}$ ), humidity ( $60 \pm 10\%$ ), and alternating 12 h light-dark cycle. Standard rats' chow pellets and water were supplied ad libitum.

All animals' procedures were performed in accordance to the guidelines for animal experiments set by the ethical committee of the National Research Centre.

### *Experimental design*

In the present study, postmenopausal syndrome model induced by bilateral ovariectomy, rats were ovariectomized and left for 3 months on soya bean deprived diet and then treated with  $17\beta$  estradiol, curcumin, alcoholic fenugreek extract and their combination daily for 2 months. Animals had free access to distilled water and diet during the experiment. Ovariectomized (OVX) rats were randomly divided into 5 groups except group I (Sham) Sham-operated rats. Each group consisted of 10 rats. Group I (Sham): Sham-operated rats, received 1% DMSO (1ml/250g, P.O.), served as normal control. Group II: served as +ve control, contained ovariectomized (OVX) rats received 1 % DMSO (1ml/250g, P.O.). Group III: treated with  $17\beta$  estradiol standard (30 $\mu\text{g}/\text{kg}$ , S.C.). Group IV: treated with curcumin from *Curcuma longa* (Turmeric) (100mg/kg, P.O.), Group V: treated with alcoholic fenugreek extract (200mg/kg, P.O.) and Group VI: administrated combination of curcumin (100mg/kg P.O.) and alcoholic fenugreek extract (200mg/kg P.O.).

At the end of the experimental period, blood samples were collected and then, the rats were sacrificed.

### *Experimental procedures*

#### *Preparation of Fenugreek*

Fenugreek extract prepared according to the method of Sauvaire [44] with a yield of 20%. While curcumin was obtained from *Curcuma longa* (Turmeric) obtained from Sigma Aldrich.

#### *Bilateral ovariectomy*

All rats anesthetized with intra-peritoneal injection of ketamine hydrochloride (100mg/kg) body weight [45]. Ovariectomy was performed according to method described by Turner [46] , Komori [47].

### Collection of blood samples

Blood samples were withdrawn from the retro-orbital vein of each animal, under light anesthesia by diethyl ether at the end of treatment period, according to the method of [48]. Coagulated blood samples were centrifuged at 3000 rpm for 15 minutes. The serum was separated for estimation the drug effects on alkaline phosphatase, calcium and phosphorous.

### Dual energy X-ray absorptiometry (DEXA) measurement

Animals were anesthetized by intra-peritoneal injection of ketamine hydrochloride (100 mg/kg) body weight [45]. Bone mineral density was measured at femur, the lumbar spine (L 2-4) and total bone mineral density at zero time and after 2 months of treatment, by dual-energy X-ray absorptiometry (DXA, Hologic QDR-2000, Bedford, MA, USA).

### Statistical analysis

All results were expressed as percentage of ovariectomized control group and data were analyzed by using one-way ANOVA, followed by least significant difference (LSD) test using GraphPad Prism (version 6, GraphPad, San Diego, California, USA). A probability level of less than 0.05 was accepted as statistically significant.

### Results and Discussion

Results of groups III, IV, V and VI (table, 1) showed a significant decrease in serum alkaline phosphatase activity by 31%, 34%, 31% and 41% respectively. Moreover, a significant decrease in serum calcium level by 15%, 14%, 17% and 16% respectively. Regarding the serum inorganic phosphate levels, results exhibited a significant elevation by 9%, 24%, 27% and 17% respectively. All the results compared to un-treated OVX control group at (P<0.05). Table 1.

Results of groups III, IV, V and VI in Figures 1, 2, 3 and 4 reveal a significant elevation of the spinal bone mineral density by 36%, 22%, 15% and 25% respectively (P<0.05). Moreover, different treatments in the same groups were efficient to cause a significant increase in the femur bone mineral density by 25%, 16%, 13% and 24% respectively at P<0.05, compared to un-treated OVX control group.

Upon treatment of OVX-rats with  $17\beta$  estradiol daily for 2 months, the tibia bone mineral density was significantly elevated by 32% at (P<0.05) as compared to un-treated OVX control group.

Treatment of OVX-rats with combination of curcumin and alcoholic fenugreek extract for 2 months, had significantly elevated the tibia bone

**TABLE 1. Effects of ovariectomy,  $17\beta$  estradiol, alcoholic fenugreek extract, curcumin and alcoholic fenugreek extract-curcumin combination on serum levels of alkaline phosphatase activity, calcium and inorganic phosphate of female rats**

Groups	Serum levels		
	Alkaline phosphatase activity (U/L)	Calcium (mg/dl)	inorganic phosphate (mg/dl)
Sham "control"	73.07±5.75 @	6.88±0.13@	4.35±0.07@#
OVX "Control"	125.65±5.39*#	7.56±0.29*#	3.59±0.14*#
OVX+ $17\beta$ Estradiol	86.88±4.70@	6.40±0.17@	3.93±0.09@
OVX+ Curcumin	83.48±5.58@	6.47±0.21@	4.45±0.11@#
OVX+ Alcoh. fenugreek extract	87.31±6.05@	6.26±0.17@	4.58±0.13@#
OVX + Alcoh. fenugreek extract + Curcumin	74.13±3.51@	6.34±0.16@	4.21±0.13@

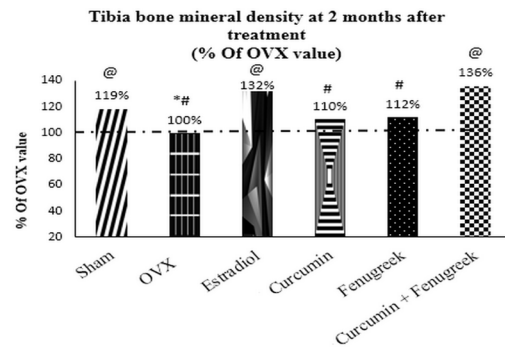
Results expressed as Mean ± S.E. (N=7). \* (p<0.05) vs. Sham-operated control group. @ (p<0.05) vs. un-treated OVX control group. # (p<0.05) vs.  $17\beta$  estradiol treated group.

mineral density at ( $P < 0.05$ ) of about 36% against un-treated OVX control group. Hence capable of manifesting a remarkable improvement than each drug administered alone.

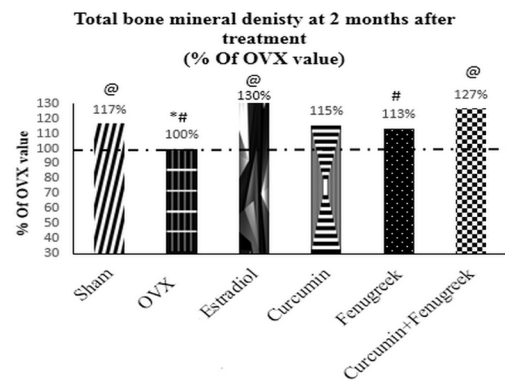
The OVX-rats received  $17\beta$  estradiol and administrated the combination daily for 2 months, the total bone mineral density was significantly improved by 30% and 27% respectively at ( $P < 0.05$ ) as compared to un-treated OVX control group.

Further, treatment of OVX-rats with alcoholic fenugreek extract daily for 2 months at ( $P < 0.05$ ) showed significant decrement in total bone mineral density as compared to OVX-rats.

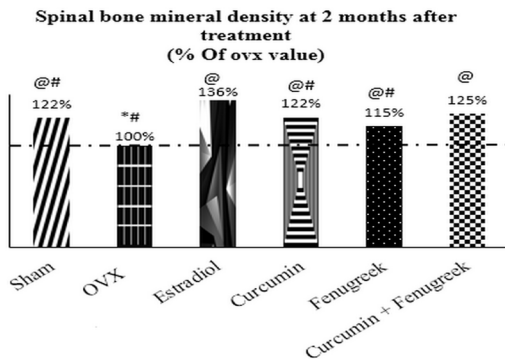
In one word, treatment with combination of curcumin and alcoholic fenugreek extract daily for 2 months is superior in elevation of BMD than treatment with curcumin or alcoholic fenugreek extract alone at ( $P < 0.05$ ) as compared to  $17\beta$  estradiol treated group especially in spinal and tibia bone mineral densities. Figs (1, 2, 3 and 4)



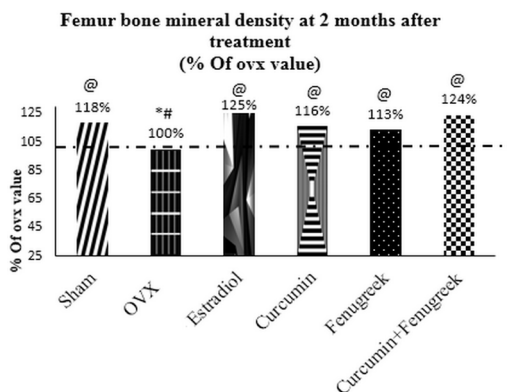
**Fig. 3**



**Fig. 4**



**Fig. 1**



**Fig. 2**

Results expressed as % of normal value (a) and % of OVX control value (b) (N=6).

\* ( $p < 0.05$ ) vs. Sham-operated control group. @ ( $p < 0.05$ ) vs. un-treated OVX1 control group. # ( $p < 0.05$ ) vs.  $17\beta$  estradiol treated group

Effects of ovariectomy,  $17\beta$  estradiol, alcoholic fenugreek extract, curcumin and alcoholic fenugreek extract-curcumin combination on cortical thickness, trabecular thickness, trabecular bone volume and osteoid area (unmineralized bone area) of female rats after 2 months of treatment.

The histomorphometrical measurements of female rat's femur bones which are illustrated in table (2) indicated that: Treatment with  $17\beta$  estradiol standard, Curcumin, alcoholic fenugreek extract and the combination daily for 2 months to OVX-rats were able to exert a significant increase on the cortical thickness by 82%, 78%, 42% and 83% respectively, as compared to un-treated OVX control group respectively. Further, treatment of OVX-rats with alcoholic fenugreek extract daily for 2 months at ( $P < 0.05$ ) showed significant decrement in cortical thickness as compared to OVX-rats received  $17\beta$  estradiol at the same time.

**TABLE 2. The histomorphometrical measurements of the femur bones of female rats at 2 months after treatment:**

Group	Parametrer	Cortical thickness	Trabecular thickness	Trabecular bone volume	Osteoid area
Sham "control"		2675.21±178.88 <sup>@</sup>	519.23±33.85 <sup>@</sup>	42.50±1.60 <sup>@</sup>	2.13±0.39 <sup>@</sup>
OVX "Control"		1412.87±20.10 <sup>*#</sup>	215.76±27.77 <sup>*#</sup>	28.89±2.60 <sup>*#</sup>	39.11±3.42 <sup>*#</sup>
OVX+17 $\beta$ Estradiol		2577.80±117.89 <sup>@</sup>	498.69±20.28 <sup>@</sup>	40.58±2.29 <sup>@</sup>	5.02±0.75 <sup>@</sup>
OVX+ Curcumin		2513.67±145.68 <sup>@</sup>	479.14±23.31 <sup>@</sup>	43.81±3.71 <sup>@</sup>	6.62±0.79 <sup>@</sup>
OVX+ Alcoholic fenugreek extract		2011.83±143.17 <sup>@#</sup>	336.92±27.85 <sup>@</sup>	36.37±2.35 <sup>@</sup>	7.10±0.75 <sup>@</sup>
OVX+ Alcoh. fenugreek extract + Curcumin		2580.40±58.49 <sup>@</sup>	540.96±29.86 <sup>@</sup>	43.88±1.22 <sup>@</sup>	5.99±0.85 <sup>@</sup>

Values represent the Mean  $\pm$  S.E. (N=6).

\* (p<0.05) vs. Sham-operated control group. @ (p<0.05) vs. un-treated OVX1 control group. # (p<0.05) vs. 17- $\beta$  Estradiol treated group.

In addition, administration of daily 17 $\beta$  estradiol standard, curcumin and alcoholic fenugreek extract for 2 months to OVX-rats, shown a significant increase on trabecular thickness at (P<0.05) by 98%, 90% and 74% respectively as compared to un- treated OVX control group. Meanwhile, co-administration of curcumin and alcoholic fenugreek extract to OVX-rats daily for 2 months, exerted significant improvement from each drug alone by 115% as compared to un-treated OVX control group.

Trabecular bone volume showed a significant increase after treatment with 17 $\beta$  estradiol, curcumin and the combination daily for 2 months to OVX-rats by 36%, 47% and 47% respectively as compared to un-treated OVX control group at the same time interval.

Results of ovariectomized rats in groups III, IV, V and VI, (Table, 2) revealed a significant decrease in osteoid area as compared to un-treated OVX control group (P<0.05) by 87%, 83%, 82% and 85% respectively.

#### Histomorphology examination

Effects of ovariectomy, 17 $\beta$  estradiol, alcoholic fenugreek extract, curcumin and alcoholic fenugreek extract-curcumin combination on bone mineral density (BMD) of female rats measured by dual-energy X-ray absorptiometry (DEXA).

A: Cancellous bone of normal control rat (sham-operated) consisting of a network of thick bony trabeculae with entrapped osteocytes and rimming osteoblasts. Trabeculae separated by interconnecting spaces containing bone

marrow. (B) Thin bone trabeculae of un-treated ovariectomized control rat (OVX) with multiple osteoporotic cavities (white arrows), showed dilatation of bone marrow spaces (arrows) (H&E, original magnification x 200). (C) Normal Cancellous bone of 17- $\beta$  estradiol treated rat consisting of a network of bony trabeculae separated by interconnecting spaces containing bone marrow (H&E, original magnification x 100). (D) curcumin treated rat showing a normal trabeculae and cortical thickness, (H&E original magnification 100). (E) Nearly normal architecture of cancellous bone trabeculae of alcoholic extract of fenugreek treated rat with apparent increase in the intertrabecular distance that led to marked widening of the interconnected bone marrow spaces compared with control rats, (H&E original magnification x 100). (F) Curcumin-fenugreek combination treated rat showing bony trabeculae with non-homogenous dark and pale areas of matrix marked widening of the interconnected bone marrow spaces compared with control rats, (H&E original magnification x100).

(A) Compact bone trabeculae of normal control rat (sham-operated) showing normal periosteum, endosteum (arrow), blood vessels and osteocytes inside their lacunae (white arrow). (H&E, original magnification x 100). (B) Irregular periosteum and endosteum of femur compact bone of un-treated ovariectomized control rat (OVX) (white arrow) and multiple osteoporotic cavities and cracks of thin bone trabeculae (arrows) (H&E, original magnification x 100). (C) Normal thick and regular periosteum and endosteum in the compact bone of 17- $\beta$  estradiol treated rat (H&E original magnification x100). (D) Treated rat with

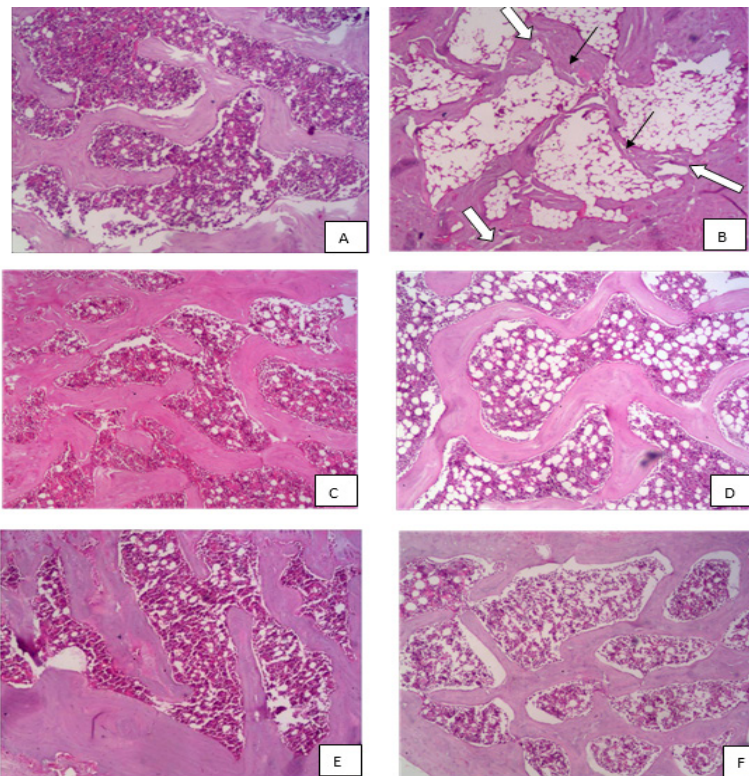
curcumin showing nearly normal histochemical reaction with normal compact bone trabeculae, (H&E, original magnification x100). (E) Normal thick Femur compact bone of alcoholic extract of fenugreek treated rat, (H&E original magnification 100). (F) Nearly normal compact bone trabeculae of curcumin–fenugreek combination treated rat with cement line. (H&E original magnification x100).

(A) Normal control rat (sham-operated) Spongiosa layer showing normal distribution of collagen fibers (unmineralized osteoid bone) (Blue stain). (Masson Trichome, original magnification x 100). (B) Femur compact bone of un-treated ovariectomized control rat (OVX) showing increase density of trichrome reaction showing increase in collagenous fibers in bone trabecula matrix, localization of the decalcified osteoid tissue of trabeculae and osteoporotic cavities (arrows), (Masson Trichome, original magnification x 200). (C) Nearly normal histochemical reaction indicated normal distribution of collagen fibers in bone trabecula, of 17- $\beta$  estradiol treated rat (Masson Trichome x 200). (D) Treated rat with curcumin showed normal distribution of collagen -positive reaction, (Masson Trichome, original magnification x 200). (E) Moderate trichrome staining reaction showing decrease

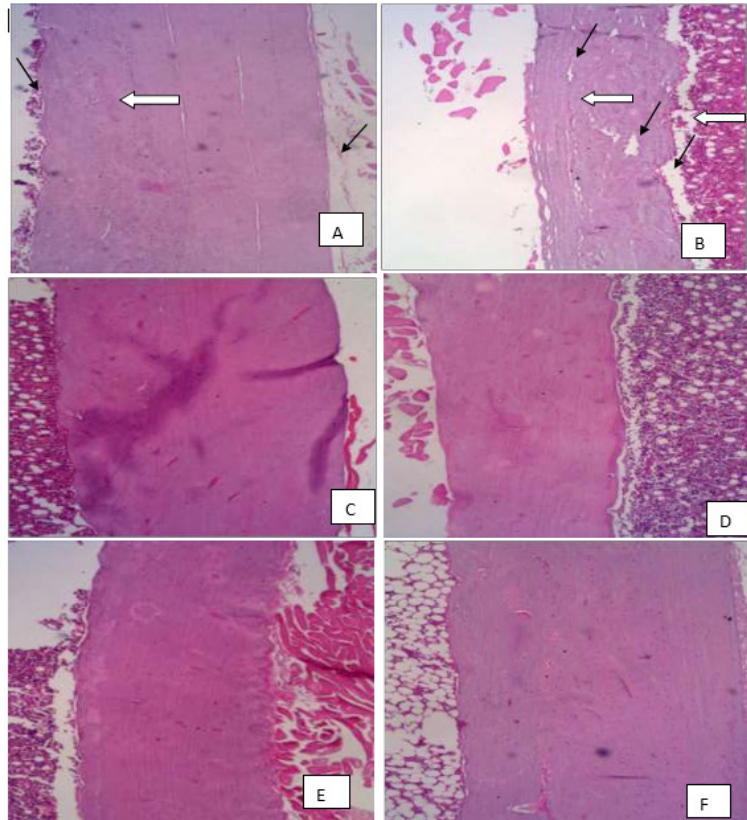
in collagenous fibers in bone trabecula matrix of alcoholic extract of fenugreek treated rat, (Masson Trichome, original magnification x 200). (F) Normal distribution of collagenous fibers in bone trabecula matrix of curcumin–fenugreek combination treated rat, (Masson Trichome, original magnification x200).

In clinical practice, postmenopausal women suffered from increased bone turnover associated with elevated serum calcium, serum alkaline phosphatase (ALP) activity and decreased serum phosphorous. Surgical animal model of bilateral ovariectomy for 3 months of female mimic postmenopausal syndrome in women with physiological, structural, functional and biochemical changes [49-51].

The current study indicated that serum ALP was increased as a serum biomarker for detection of bone loss in OVX-rats as compared to sham-operated rats, whereas, treatment with 17 $\beta$  estradiol, Curcumin, alcoholic fenugreek extract and combination of curcumin and alcoholic fenugreek extract normalized serum calcium, phosphorous and ALP. These results are in harmony with previous experimental studies regarding curcumin [52, 53].



**Fig. 1. (A:F) Photomicrograph of a section in femur spongiosa of rats showing cancellous bone.**



**Fig. 2. (A:F) Photomicrograph of a section in femur bone of rat showing compact bone trabeculae.**

The research study demonstrated that administration of  $17\beta$  estradiol, curcumin, alcoholic fenugreek extract and the combination to OVX-rats produced increased spinal and femur bone mineral density, in addition to the amelioration of cortical thickness, trabecular (both thickness and volume) and decreased Osteoid area as compared to the un-treated OVX-rats. The current result of dual-energy X-ray absorptiometry (DEXA) further supports the osteoprotective effect of curcumin, fenugreek and their combination on ovariectomized rats. These results are in agreement with those of other investigations [32, 54-58].

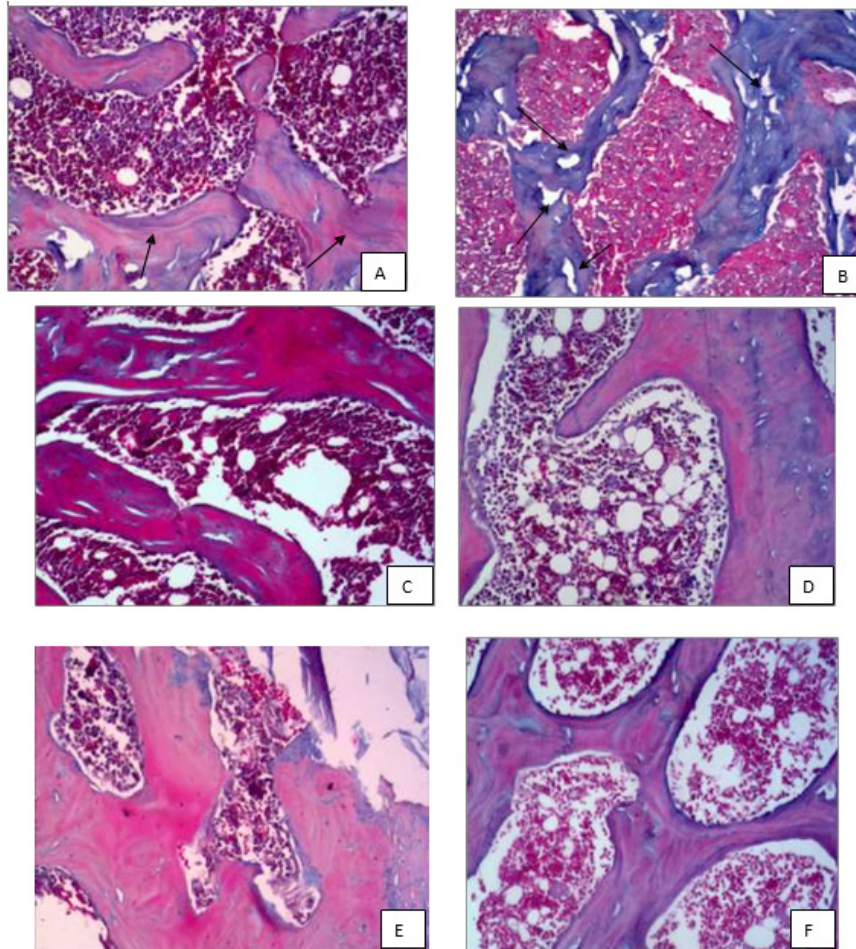
Estrogen plays an important role in calcium reabsorption in the kidney and gastrointestinal absorption [20, 21]. It has been reported that presence of estrogen receptors in the intestine confirmed that estrogen might increase intestinal calcium absorption both in rats [22, 23] and humans [24].

The estrogenic protective effect of  $17\beta$  estradiol on bone might be involved in suppression of inflammatory cytokines such as interleukin-1 (IL-1) and tumor necrosis factor-alpha (TNF- $\alpha$ ), which

activates inducible nitric oxide synthase (iNOS) and derived nitric oxide (NO), and hence consequently potentiates cytokine and inflammatory-induced bone loss [59,60]. Estrogen itself also stimulates osteoprotegerin (OPG) production in osteoblasts with a subsequent suppression of RANKL binding to receptor activator of nuclear factor-kappa B (RANK) in osteoclast precursors and thus exerts anti-resorptive effects on bone [8, 61, 62].

In parallel, curcumin, fenugreek and their combination possess an estrogenic activity and potent anti-inflammatory activity with free radical scavenging activity, and osteoprotective [63-65] that contracts the oxidative stress as consequences of osteoporosis.

Finally, it's has concluded that curcumin and/ or fenugreek extracts have an anti- osteoporotic activity that can be recommended as natural replacement therapy in women with postmenopausal osteoporosis. On the other hand, treatment with a combination of curcumin and alcoholic fenugreek extract has a synergistic effect in improvement of bone turnover and bone strength than used alone. Further clinical trials are required.



**Fig. 3. (A:F) Photomicrograph of a section in femur bone of rat showing compact bone trabeculae.**

### References

- Lombardi, I. Jr., Oliveira, L.M., Mayer, A.F., Jardim, J.R., Natour, J., Evaluation of pulmonary function and quality of life in women with osteoporosis. *Osteoporos Int.* **16** (10), 1247-1253 (2005).
- Al-Azzawi, F. and Palacios, S., Hormonal changes during menopause. *Maturitas*, **63** (2), 135-137 (2009).
- Stachenfeld, N.S., Hormonal changes during menopause and the impact on fluid regulation. *Reprod. Sci.*, **21** (5), 555-561 (2014).
- Heilmeyer, U., Youm J. , Torabi S. and Link T. M., Osteoporosis Imaging in the Geriatric Patient. *Curr. Radiol. Rep.*, **4** (4), doi:10.1007/s40134-016-0144-1 (2016).
- Kronenberg, H. and Williams, R.H. Williams textbook of endocrinology. 11th ed., Philadelphia: Saunders/Elsevier. xix, 1911 p. (2008).
- Sipos, W., Pietschmann, P., Rauner, M., Kerschanschindl, K., Patsch, J., Pathophysiology of osteoporosis. *Wien Med Wochenschr.* **159** (9-10), 230-234 (2009).
- Mirza, F. and E. Canalis, Management of endocrine disease: Secondary osteoporosis: pathophysiology and management. *Eur. J. Endocrinol.*, **173** (3), R131-51 (2015).
- Saika, M., Inoue, D., Kido, S., Matsumoto, T., 17beta-estradiol stimulates expression of osteoprotegerin by a mouse stromal cell line, ST-2, via estrogen receptor-alpha. *Endocrinology*, **142** (6), 2205-2212 (2001).
- Quinn, J.M., Whitty, G.A., Byrne, R.J., Gillespie, M.T., Hamilton, J.A., The generation of highly enriched osteoclast-lineage cell populations. *Bone*, **30**(1), 164-70 (2002).
- Maurer, T., Zimmermann G. , Maurer S. , Stegmaier S. , Wagner C. , and Hänsch G. M., Inhibition of osteoclast generation: a novel function of the bone morphogenetic protein 7/osteogenic protein 1. *Mediators Inflamm*, 171-209 (2012).



11. Fitzpatrick, L.A., Estrogen therapy for postmenopausal osteoporosis. *Arq Bras Endocrinol Metabol.*, **50** (4), 705-19 (2006).
12. Hikiji, H., Takato, T., Shimizu, T., Iishi, S. The roles of prostanoids, leukotrienes, and platelet-activating factor in bone metabolism and disease. *Prog. Lipid. Res.*, **47** (2), 107-126 (2008).
13. Khosla, S. Minireview: the OPG/RANKL/RANK system. *Endocrinology.*, **142** (12), 5050-5055 (2001).
14. Xu, F., Dong Y., Huang X., Chen P., Guo F., Chen A., Huang S. Pioglitazone affects the OPG/RANKL/RANK system and increase osteoclastogenesis. *Mol. Med. Rep.*, **14** (3), 2289-96 (2016).
15. Robbie-Ryan, M., Pacifici, R. and Weitzmann, M.N., IL-7 drives T cell-mediated bone loss following ovariectomy. *Ann. N. Y. Acad. Sci.*, **1068**, 348-351 (2006).
16. Ghodasra, J.H., Ghodasra J. H., Nickoli M.S., Hashmi S.Z., Nelson J.T., Mendoza M., Nicolas J. D., Bellary S.S., Sonn K., Ashtekar A., Park C.J., Babu J., Yun C., Ghosh A., Kannan A., Stock S.R., Hsu W.K., Hsu E.L., Ovariectomy-Induced Osteoporosis Does Not Impact Fusion Rates in a Recombinant Human Bone Morphogenetic Protein-2-Dependent Rat Posterolateral Arthrodesis, *Model. Global Spine J.*, **6** (1), 60-68 (2016).
17. Chen, H.L., Tung, Y.T., Chuang, C.H., Tu, M. Y., Tsai, T.C., Chang, S.Y. and Chen, C.M., Kefir improves bone mass and microarchitecture in an ovariectomized rat model of postmenopausal osteoporosis. *Osteoporos Int.*, **26** (2), 589-99 (2015).
18. Gao, Y., Grassi F., Ryan M.R., Terauchi M., Page K., Yang X., Weitzmann M.N., and Pacifici R., IFN-gamma stimulates osteoclast formation and bone loss in vivo via antigen-driven T cell activation. *J. Clin. Invest.*, **117** (1), 122-132 (2007).
19. Khosla, S., Atkinson E. J., Melton L. J. III, Riggs B.L., Effects of age and estrogen status on serum parathyroid hormone levels and biochemical markers of bone turnover in women: a population-based study. *J. Clin. Endocrinol. Metab.*, **82** (5), p. 1522-1527 (1997).
20. Gennari, C., Agnusde D., Nard P., Civitelli R., Estrogen preserves a normal intestinal responsiveness to 1,25-dihydroxyvitamin D3 in oophorectomized women. *J Clin Endocrinol Metab*, **71** (5), 1288-1293 (1990).
21. McKane, W.R., Khosla, S., Burritt, M.F., Kao, P.C., Wilson, D.M., Ory, S.J., and Riggs B.L., Mechanism of renal calcium conservation with estrogen replacement therapy in women in early postmenopause--a clinical research center study. *J. Clin. Endocrinol. Metab*, **80** (12), 3458-3464 (1995).
22. Arjmandi, B.H., Salih M. A., Herbert D.C., Sims S.H., Kalu D.N., Evidence for estrogen receptor-linked calcium transport in the intestine. *Bone Miner*; **21** (1), 63-74 (1993).
23. Arjmandi, B.H., Hollis, B.W. and Kalu, D.N., In vivo effect of 17 beta-estradiol on intestinal calcium absorption in rats. *Bone Miner*; **26** (2), 181-9 (1994).
24. Riggs, B.L., Khosla, S. and Melton, L.J., A unitary model for involutional osteoporosis: estrogen deficiency causes both type I and type II osteoporosis in postmenopausal women and contributes to bone loss in aging men. *J. Bone Miner. Res.*, **13** (5), 763-773 (1998).
25. Jagetia, G.C. and B.B. Aggarwal "Spicing up" of the immune system by curcumin. *J. Clin. Immunol.*, **27** (1), 19-35 (2007).
26. Padhye, S., Chavan, D., Pandey, S., Deshpande, J., Swamy, K.V., Sarkar, F.H. Perspectives on chemopreventive and therapeutic potential of curcumin analogs in medicinal chemistry. *Mini. Rev. Med. Chem.*, **10** (5), 372-387 (2010).
27. Wright, L.E., Frye J.B., Timmermann B. N. and Funk J.L., Protection of trabecular bone in ovariectomized rats by turmeric (*Curcuma longa* L.) is dependent on extract composition. *J. Agric. Food Chem.*, **58** (17), 9498-504 (2010).
28. Funk, J.L., Funk, J.L., Frye, J.B., Oyarzo, J.N., Kuscuoglu, N., Wilson, J., McCaffrey G., Stafford G., Chen G., Clark Lantz R., Jolad S.D., Solyom A.M., Kiela P.R. and Timmermann B.N., Efficacy and mechanism of action of turmeric supplements in the treatment of experimental arthritis. *Arthritis Rheum*, **54** (11), 3452-64 (2006).
29. Funk, J.L., Oyarzo J.N., Frye J.B., Chen G., Clark Lantz R., Jolad S. D., Solyom A.M., and Timmermann B.N., Turmeric extracts containing curcuminoids prevent experimental rheumatoid arthritis. *J. Nat. Prod.*, **69** (3), 351-5 (2006).
30. Bharti, A.C., Takada, Y. and B.B. Aggarwal, Curcumin (diferuloylmethane) inhibits receptor activator of NF-kappa B ligand-induced NF-kappa B activation in osteoclast precursors and suppresses osteoclastogenesis. *J. Immunol.*, **172** (10) 5940-7 (2004).

31. von Metzler, I., Krebbel H., Ulrike Kuckelkorn, Heider U., Jakob C., Kaiser M., Fleissner C., Terpos E., Seze O., Curcumin diminishes human osteoclastogenesis by inhibition of the signalosome-associated I kappaB kinase. *J. Cancer Res. Clin. Oncol.*, **135** (2), 173-9 (2009).
32. French, D.L., J.M. Muir, and C.E. Webber, The ovariectomized, mature rat model of postmenopausal osteoporosis: an assessment of the bone sparing effects of curcumin. *Phytomedicine*, **15** (12), 1069-78 (2008).
33. Hou, M., Song Y., Li Z., Luo C., Ou J.-S., Yu H., Yan J., Lu L., Curcumin attenuates osteogenic differentiation and calcification of rat vascular smooth muscle cells. *Mol. Cell Biochem.*, **420** (1-2), 151-60 (2016).
34. Sauvaire, Y., Ribes G., Baccou J.-C., Loubatieres-Mariani M.-M., Implication of steroid saponins and saponinins in the hypocholesterolemic effect of fenugreek. *Lipids*, **26** (3), 191-7(1991).
35. Basch, E., Ulbricht, C., Kuo, G., Szapary, P. and Smith, M. Therapeutic applications of fenugreek. *Altern. Med. Rev.*, **8** (1), 20-7 (2003).
36. Gong, J., Fang K., Dong H., Wang D., Hu M., Lu F., Effect of Fenugreek on Hyperglycaemia and Hyperlipidemia in Diabetes and Prediabetes: a Meta-analysis. *J. Ethnopharmacol.*, **194**, 260-268 (2016).
37. Gaddam, A., Galla C., Thummiseti S., Marikanty R. K., Palanisamy U.D. and Rao P.V., Role of Fenugreek in the prevention of type 2 diabetes mellitus in prediabetes. *J. Diabetes Metab. Disord.*, **14**, 74-84 (2015).
38. Koupy, D., H. Kotolova, and J. Ruda Kucerova, [Effectiveness of phytotherapy in supportive treatment of type 2 diabetes mellitus II. Fenugreek (*Trigonella foenum-graecum*)]. *Ceska Slov Farm*, **64** (3), 67-71 (2015).
39. Amin, A., Alkaabi A., Al-Falasi S., Daoud S.A., Chemopreventive activities of *Trigonella foenum graecum* (Fenugreek) against breast cancer. *Cell Biol. Int.*, **29** (8) 687-94 (2005).
40. Rahmati-Yamchi, M., Ghareghomi S., Haddadchi G., Milani M., Aghazadeh M., Daroushnejad H., Fenugreek extract diosgenin and pure diosgenin inhibit the hTERT gene expression in A549 lung cancer cell line. *Mol. Biol. Rep.*, **41** (9) 6247-52(2014).
41. Pandian, R.S., C.V. Anuradha, and P. Viswanathan, Gastroprotective effect of fenugreek seeds (*Trigonella foenum graecum*) on experimental gastric ulcer in rats. *J. Ethnopharmacol.*, **81** (3), 393-7 (2002).
42. Mathern, J.R., Raatz S. K., Thomas W., Slavin J.L., Effect of fenugreek fiber on satiety, blood glucose and insulin response and energy intake in obese subjects. *Phytother Res.*, **23** (11) 1543-8(2009).
43. Shishodia, S. and B.B. Aggarwal, Diosgenin inhibits osteoclastogenesis, invasion, and proliferation through the downregulation of Akt, I kappa B kinase activation and NF-kappa B-regulated gene expression. *Oncogene*, **25** (10) 1463-73(2006).
44. Sauvaire, Y., Baissac Y., Leconte O., Petit P., Ribes G., Steroid saponins from fenugreek and some of their biological properties. *Adv. Exp. Med. Biol.*, **405**, 37-46 (1996).
45. Arjmandi, B.H., Alekel L., Hollis B.W., Amin D., Stacewicz-Sapuntzakis M., Guo P., Kukreja S.C., Dietary soybean protein prevents bone loss in an ovariectomized rat model of osteoporosis. *J. Nutr.*, **126** (1), 161-7 (1996).
46. Turner, A.S., Animal models of osteoporosis--necessity and limitations. *Eur. Cell Mater.*, **1**, 66-81 (2001).
47. Komori, T., Animal models for osteoporosis. *Eur J Pharmacol*, **759**, 287-94 (2015).
48. Cocchetto, D.M. and T.D. Bjornsson, Methods for vascular access and collection of body fluids from the laboratory rat. *J. Pharm. Sci.*, **72** (5), 465-92 (1983).
49. Liu, M.L., Xu X., Qing Rang Wei., Li Y.-J. and Son, H.-P., Influence of ovariectomy and 17beta-estradiol treatment on insulin sensitivity, lipid metabolism and post-ischemic cardiac function. *Int. J. Cardiol.*, **97** (3), 485-93 (2004).
50. Bitto, A., Altavilla D., Bonaiuto A., Polito F., Minutoli L., Di Stefano V., Giuliani., Guarini S., Arcoraci V. and Squadrito F., Effects of aglycone genistein in a rat experimental model of postmenopausal metabolic syndrome. *J. Endocrinol.*, **200** (3), 367-76 (2009).
51. Hussan, F., Ibraheem N.G., Kamarudin T.A., Shuid A.N., Soelaiman I.N. and Othman F., Curcumin Protects against Ovariectomy-Induced Bone Changes in Rat Model. *Evid Based Complement Alternat Med*, p. 174916 (2012)
52. Yamamoto, M., Fisher J. E., Gentile M. J., Seedor G., Tai Leu C., Rodan S. B., Rodan G. A., *The integrin ligand echistatin prevents bone loss in ovariectomized mice and rats.* *Endocrinology*, **139**(3) 1411-9 (1998).
53. Ikeuchi, M., Yamaguchi Kohji, Koyama T., Sono Yoshikatsu, and Yazawa Kazunaga, *Effects of fenugreek seeds (Trigonella foenum graecum) extract on endurance capacity in mice.* *J Nutr Sci Vitaminol (Tokyo)*, **52** (4) 287-92 (2006).

54. Seeman, E., *Pathogenesis of bone fragility in women and men*. Lancet, **359** (9320) 1841-50 (2002).
55. Seeman, E., *Estrogen, androgen, and the pathogenesis of bone fragility in women and men*. Curr. Osteoporos Rep., **2** (3) 90-6 (2004).
56. El Khassawna, T., El Khassawna T., Böcker W., Govindarajan P., Schlieffe N., Hürter B., Kampschulte M., Schlewitz G., Alt V., Lips K. S., Faulenbach M., Möllmann H., Zahner D., Dürselen L. et al, *Effects of multi-deficiencies-diet on bone parameters of peripheral bone in ovariectomized mature rat*. PLoS One, **8** (8) e71665 (2013)
57. Taty Anna, K., Elvy Suhana M.R., Das S., Faizah O., Hamzaini A.H., *Anti-inflammatory effect of Curcuma longa (turmeric) on collagen-induced arthritis: an anatomico-radiological study*. Clin Ter., **162** (3) 201-7 (2011).
58. Cho, D.C., Kim K.-T., Jeon Y., Sung J.-K., *A synergistic bone sparing effect of curcumin and alendronate in ovariectomized rat*. Acta Neurochir (Wien), **154** (12), p. 2215-23 (2012).
59. van't Hof, R.J. and S.H. Ralston, *Nitric oxide and bone*. Immunology, **103** (3): p. 255-61 (2001).
60. Das, U.N., *Nitric oxide as the mediator of the antiosteoporotic actions of estrogen, statins, and essential fatty acids*. Exp Biol Med (Maywood), **227** (2), 88-93 (2002)
61. Bord, S., Ireland D.C., Beavan S.R., Compston J.E., *The effects of estrogen on osteoprotegerin, RANKL, and estrogen receptor expression in human osteoblasts*. Bone, **32** (2), 136-41 (2003)
62. Di Carlo, C., Tommaselli G.A., Gargano V., Sammartino A., Bifulco G., Tauchmanova L., Colao A, Nappi C., *Effects of estrogen-progestin therapy on serum levels of RANKL, osteoprotegerin, osteocalcin, leptin, and ghrelin in postmenopausal women*. Menopause, **14** (1), 38-44 (2007).
63. Ak, T. and I. Gulcin, *Antioxidant and radical scavenging properties of curcumin*. Chem Biol Interact, **174** (1), 27-37 (2008).
64. Tvrda, E., Tušimová E., Kováčik A., Paál D., Greifová H., Abdramanov A., Lukáč N., *Curcumin has protective and antioxidant properties on bull spermatozoa subjected to induced oxidative stress*. Anim. Reprod. Sci., (2016).
65. Tizabi, Y., Hurley L. L., Qualls Z. and Akinfiresoye L., *Relevance of the anti-inflammatory properties of curcumin in neurodegenerative diseases and depression*. Molecules, **19** (12), 20864-79 (2014).

(Received 14/12/ 2017,  
accepted 18/02/ 2018)

### التأثير الواقي من هشاشة العظام لكل من الكركم أو الحلبة أو الاثنتين معا على إناث الجرذان مستأصله المبايض

نسمه محمد عصمت أبو النصر\* ، عز الدين الدنشارى\*\* ، سوسن صلاح محمود\* و سلوى محمد نوفل\*  
\*قسم الفارماكولوجى - الشعبة الطبية - المركز القومى للبحوث - القاهرة - مصر و \*\* قسم الأدوية و السموم -  
كلية الصيدلة - جامعه القاهرة - القاهرة - مصر.

يعتبر النوع الأكثر شيوعاً من هشاشة العظام هو فقدان العظام المرتبطة نقص هرمون المبيض في سن اليأس. ويتميز بعدم التوازن بين ارتشاف العظام وتشكيلها، مما يؤدي إلى انخفاض كتلة العظام وتدهور بنيتها العظام. تم تقييم الكركمين النقي، مستخلص الحلبة ومزيجها لتحسين فقدان العظام على الجرذان مستأصله المبايض كنموذج لهشاشة العظام بعد سن اليأس. تم استخدام 50 من إناث الجرذان يتراوح وزنها بين 130-150g. تم استئصال المبايض باستئناء المجموعة الضابطة السلبية. تم تغذية الجرذان على الغذاء بدون فول الصويا ثم تم تقسيم الجرذان عشوائياً إلى 5 مجموعات. بعد 3 أشهر من استئصال المبايض، تم تلقي المجموعة الضابطة السلبية والضابطة الايجابية مستأصله المبايض (1% DMSO مل / كجم)، في حين تم تلقي المجموعات الأخرى المستأصله المبايض (الكركمين 100mg/كجم) و(مستخلص الحلبة 200mg/ كجم) المزيج بينهما (تلقى نفس الجرعات). أظهرت الكثافة العظام للساق والكثافة الكلية للعظم انخفاضاً مؤثراً في المجموعة الضابطة الايجابية مقابل المجموعة الضابطة السلبية، في حين أن مزيج من الكركمين والحلبة أظهرت زيادة كبيرة مقارنة مع مجموعة الضابطة مستأصله المبايض. أظهرت البيانات التي تم الحصول عليها أن الكركمين يقلل من فقدان العظام بشكل ملحوظ. بالإضافة إلى أنه تم الحصول على تأثير مضاعف عندما تم الجمع بين الكركمين مع مستخلص الحلبة و بالتالي تحسين كل من هيئه العظام وقوتها.

الكلمات الدالة: الكركم - الحلبة - الجرذان - هشاشة العظام - انقطاع الطمث - نقص الهرمونات.