

Evaluation of Results of Calcaneo-Stop Procedure in Treatment of Pediatric Flexible Flatfoot

ALY M. FAYED, M.Sc.; AHMED M. SAMY, M.D.; MUHAMMAD A. QUOLQUELA, M.D. and MAHMOUD A. EL-ROSASY, M.D.

The Department of Orthopaedic Surgery, Faculty of Medicine, Tanta University

Abstract

Background: Flexible flatfoot is a common finding in pediatrics. It is usually amenable to conservative treatment but in less frequent occasions, some cases are not optimally responsive to conservative measures. Calcaneo-stop procedure is minimally invasive and safe resort for this cases after failure of conservative measures.

Objective: Evaluate the results of treatment of pediatric flexible flatfoot by Calcaneo-stop procedure only after exhaustion of six months of supervised conservative management.

Study Design and Setting: A prospective randomized clinical trial in a tertiary care center.

Patients and Methods: 20 cases of pediatric flexible flatfoot (ten patients) were operated on after failure of six months of conservative treatment. All patients were evaluated pre-operative and post-operative via Kite's angle, Meary's angle and according to American college of Foot and Ankle Society score (ACFAS). A *p*-value of less than 0.001 was considered statistically significant.

Results: There was statistically significant improvement in Meary's, Kite's angle. While ACFAS score measurement was better than preoperative score in all cases but not statistically significant.

Conclusion: Calcaneo-stop is safe, minimally invasive and effective in treatment of pediatric flexible flatfoot also it doesn't burn bridges for other adjuvant procedures later on.

Key Words: Calcaneo-stop – Flatfoot – Subtalar arthroereisis.

Introduction

FLATFOOT is defined as a deformity where the medial arch of the foot is lower than normal and the entire sole of the foot comes into near-complete or complete contact with the ground. Whether or not flat foot represents a true deformity is questionable. For example, some authors regarded flat feet as “usual in infants, common in children, and within the normal range in adults” in assessing and

documenting the spontaneous development of the longitudinal arch. Others have concurred with these observations [1]. Despite the fact that conservative measures are successful in many cases, in some cases it doesn't work well as insoles and shoes inserts will never reconstructs or develop a compromised longitudinal arch. Jane MacKenzie et al., [2] concluded that there is no evidence that orthopedic shoes immediately improves the radiographic parameters in pediatric flexible flatfoot [2]. Conservative treatment in the form of rehabilitative exercises is favored over passive methodological proof [3,4]. Also, the relatively hot humid atmosphere in Egypt and the relative high costs of insoles and supervised physiotherapy makes Calcaneo-stop procedure a suitable solution as its simple, reliable, safe and with low costs. The operative treatment flexible flatfoot could be categorized into: Soft tissue procedures (e.g. Achilles tendon lengthening or gastrocnemius recession, plication of talo-navicular joint capsule) usually these soft tissue procedures are used as adjuvant procedures. Bony procedures (e.g. Lateral column lengthening, medial displacement calcaneal osteotomy) and subtalar arthroereisis group which aims at limiting the movement of the subtalar joint in eversion or pronation.

Patients and Methods

A prospective study was conducted in Orthopaedic Surgery Department, Tanta University Hospital from first of May 2015 till the first of May 2017. 20 cases with mean age of 12.2 years (9-16, SD 2.4) were operated; all cases were followed-up for at one year. Study protocol was approved by institutional ethical committee. All the patients had signed informed written consent to participate in the study and surgical procedures.

Correspondence to: Dr. Aly M. Fayed, The Department of Orthopaedic Surgery, Faculty of Medicine, Tanta University

All patients included in the study were complaining mainly from ankle and foot pain especially on prolonged standing due to flexible flatfoot and all were resistant to conservative treatment for six months. Conservative measures were delivered for all patients under direct supervision of staff members of Physical therapy department of Tanta University Hospital.

Inclusion criteria: Patients with idiopathic flexible flatfoot who have exhausted all means of supervised conservative measure for a period not less than six months in the age group of 8 to 18 years old.

Exclusion criteria: Patients outside the age group, neurological or neuromuscular disorders, congenital or post-traumatic and cases with other deformities of limb alignment e.g. genu valgum.

Operative technique: All patients were operated in the supine position, under general anaesthesia and without tourniquet. After optimum prepping,

draping the lower limb, incision of skin and subcutaneous tissue is gently done exactly over the sinus tarsi about 2cm just below the lateral malleolus and for about 1.5cm long (Fig. 1). Blunt dissection of soft tissue is done. Then the foot is manipulated in the corrected position. Using the 3.5mm drill pit to drill the path of the arthroereisis screw after confirming the entry site, which is located at the junction between anterior 1/3 and posterior 2/3 of sinus tarsi under image intensifier. Then a 6.5mm cancellous screw is advanced under image control while the subtalar joint is inverted. After confirming correction (eversion block of the subtalar joint, and maintained arch) irrigation of the wound, layered closure is done and postoperative wrapping in a bandage.

Methods of evaluation:

ACFAS score of hind foot was used for evaluation of all cases. Radiological assessment was performed on loaded Antero-posterior and lateral view to assess Kite's angle and Meary's angle respectively.

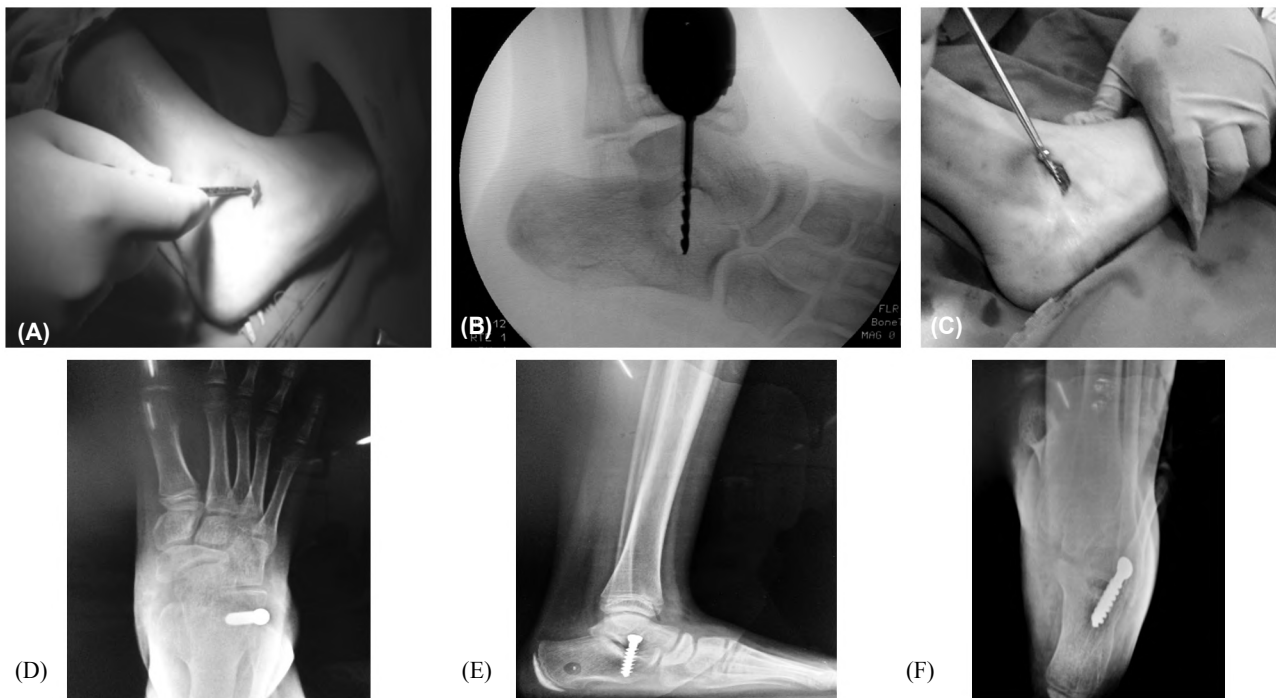


Fig. (1): (A) Skin incision and blunt dissection, (B) Pre-drilling of the screw trajectory, (C) Screw insertion and advancement, (D,E,F) Postoperative radiographs.

Results

1- **Meary's angle:** There is significant improvement in Meary's angle (p -value <0.001) the mean preoperative angle $24.75^{\circ} \pm 9.39$ is while the mean postoperative angle is $3.7^{\circ} \pm 0.58$ and it was also $3.7^{\circ} \pm 0.58$ at final follow-up. With a 9.7° as a mean of reduction in the angle measurement.

2- **Kite's angle:** There was also significant improvement (p -value <0.001) in this angle measurement with a mean of 8.75° reduction in angle measurement, as it had a mean of $30^{\circ} \pm 5$ preoperative, a mean of $21.3^{\circ} \pm 3.2$ postoperative and the same results in the final follow-up.

3- **Patient satisfaction according to ACFAS score:** 16 satisfactory results and only 4 unsatisfactory

results (the mean score was 87 with a standard deviation of 6.6, the minimum score was 70 and the maximum score was 92).

Complications: No reported complications.

Table (1): Results according to Meary's angle.

	Meary's angle		Paired <i>t</i> -test	
	Range	Mean±SD	<i>t</i>	<i>p</i> -value
Pre-operative	5°-32°	24.75°±9.39		
Immediate postoperative	3.1°-4.9°	3.7°±0.58	10.1	<0.001
Final Follow-up	3.1°-4.9°	3.7°±0.58	10.1	<0.001

Table (2): Results according to Kite's angle.

	Kite's angle (Talo-calcaneal angle) (AP view)		Paired <i>t</i> -test	
	Range	Mean±SD	<i>t</i>	<i>p</i> -value
Pre-operative	22°-36°	30°±5		
Immediate postoperative	16°-28°	21.3°±3.2	-6.9	<0.001
Final Follow-up	16°-28°	21.3°±3.2	-6.9	<0.001

Discussion

Pediatric flexible flatfoot remains a poorly defined pathology with little agreement regarding approaching it for proper management and till now no single method or operative technique is considered standard of care for this patients [5,6,7].

The most popular method for treatment of pediatric flexible flatfoot is the conservative way in the form of stretching exercises of Achilles tendon and insoles. Despite the fact that conservative measures are successful in many cases, in some cases it doesn't work well as insoles and shoes inserts will never reconstructs or develop a compromised longitudinal arch [2].

Jane MacKenzie et al., [2] concluded that there is no evidence that orthopedic shoes immediately improves the radiographic parameters in pediatric flexible flatfoot [2]. Conservative treatment in the form of rehabilitative exercises is favored over passive measures in some studies but also this studies were of poor methodological proof [3,4].

While the precise mechanism by which arthroereisis improves foot alignment remains to be elucidated, several studies [8-10] have demonstrated significant improvements in key radiographic pa-

rameters in the form of increased arch height and improved joint congruency following arthroereisis.

Arthroereisis represents a minimally invasive procedure capable of correcting flexible flatfoot through a combination of static, dynamic and proprioceptive mechanisms. As a treatment option it continues to polarize opinion. A focus on internal joint congruency rather than simple anthropometric measures may sharpen our understanding [11,12]. There is a growing body of evidence linking abnormalities in joint malalignment to the development of osteoarthritis with more recent observational studies have demonstrated a greater incidence of osteoarthritis in flat feet compared with controls [13].

In this study, We have a satisfaction rate of 80% which is closely matched to Koning et al., [14] and Viladot et al., [15]. Also we have closely matched results to Usuelli et al., [10] and Richard M. et al., [9] who reported satisfaction rate of 89% of total of 34 operated feet. The difference may be attributed to the variation in methods of evaluation as they depend on subjective data while our satisfaction rate was determined according to results of ACFAS score which is comprehensive score including both subjective and objective parameters.

J. Jerosch et al., [16], reported two patients out of eighteen patients (11%) unsatisfied with the procedure but there was no objective reason for that.

Giannini et al., [17], reported unsatisfactory results in only 5% cases out of a total of 49 cases through a four year follow-up. The high satisfaction rate may be attributed to the large number of patients and the long follow-up in this study compared to our study in which we have a mean follow-up period of twelve months.

In this study, there were marked improvement in radiological parameters in both AP and lateral views. Meary's angle (talo-1st metatarsal angle on lateral view) was significantly improved (*p*-value <0.001) as the mean preoperative angle was 24.75°±9.39 while the mean postoperative angle was 3.7°±0.58 and it was also 3.7°±0.58 at final follow-up. With a 9.7° as a mean of reduction in the angle measurement. S. Calvo et al., [18] reported less correction of the angle with mean pre-operative of 16.5° and mean postoperative of 11.92°. Sakti P. Das et al., [19] reported less correction than our results using the 6.5mm cancellous screw with a mean pre-operative of 32.7° and mean postoperative of 18°.

Also Kite's angle (Talo-calcaneal angle on AP view) which reflects hindfoot alignment was significantly improved (p -value <0.001) with a mean of 8.75° reduction in angle measurement, as it had a mean of $30^\circ \pm 5$ preoperative, a mean of $21.3^\circ \pm 3.2$ postoperative and the same results in the final follow-up Which is closely matched to the reported results by Pablo Fernandez et al., [20] as their pre-operative mean was 32.2° and postoperative mean was 19 . V. Pavon et al., [21] in their study using a cancellous screw in similar fashion as ours reported less correction of the angle with mean pre-operative of $31^\circ \pm 0.8$ and mean post-operative angle of $24.9^\circ \pm 1.8$.

Giannini et al., [22] used an expandable endo-orthesis and Castaman et al., [22] used a talar screw similar to our method both have managed to achieve a better correction than ours regarding Meary's angle with a mean of pre-operative 10.3° and mean postoperative 3° in the former study and mean pre-operative of 11.2° and mean postoperative 2° while we have better correction regarding kite angle as their results was as follows mean pre-operative of 39° and postoperative of 27° mean pre-operative of 41° and postoperative of 31° respectively. Despit we have a higher mean preoperative Meary's angle correction compared to the previous studies we have reached nearly equal mean postoperative angle with greater mean of reduction in angle measurement.

Sakti P. Das et al., [19], reported less correction of Kite's angle from a mean pre-operative of 30.92° to a postoperative mean of 23.07° .

Our significant radiological improvement was not only evident by comparison to other studies of subtalar arthroereisis but it was also closely matched to many studies that have used more invasive techniques to correct flexible flatfoot. H. Sodre, A et al., [23] used the medial sliding calcaneal osteotomy to achieve results which was closely matched to ours with a mean pre-operative Meary's angle of 18.8° and mean postoperative 1.9° angle of. Mean pre-operative Kite's angle of 31.6° and mean postoperative angle of 20.8° . Hazem El-Tayeby et al., [24] used combined Evans calcaneal lengthening osteotomy, arthrodesis of naviculocuneiform joint, lengthening of Achilles and rerouting of tibialis anterior tendon to plantar aspect of foot to correct severe cases of flatfoot, their results was as follows mean pre-operative Meary's angle was 30.11° and mean postoperative was 8.53° , they have achieved a great degree of correction but their mean preoperative value was higher than ours and this may explain the need for this

extensive interventions to correct these severe cases.

J. Mark Bruyn et al., [25], has used arthroereisis as adjunctive treatment with Evans calcaneal lengthening osteotomy for severe cases with improvement of Kite's angle from mean preoperative 24.8° of to a mean postoperative of 2.8° . This also proves that arthroereisis could be combined with other procedures for treatment of flatfoot and it wouldn't hinder other interventions.

The implant that we have used was 6.5mm cancellous screw which is relatively cheap and of material that is used safely in many orthopedic interventions. Other variable specifically designed calcaneostop screws which made of silicone is more expensive and there is recorded severe synovitis related to the implant which necessitates removal of the screw [26].

Viladot et al., [15] had used silicone implants with satisfaction rate of 79%, Koning et al., [27] had used implants seated within the calcaneus with satisfaction rate of 81.5%, While Giannini et al., [16] had used bioabsorbable free floating device with satisfaction rate of 95% comparing this results to ours, we found that our satisfaction rate of 80% is closely matched to Viladot et al., [15] and Koning et al., [27] but less than Giannini et al., [16] which may be due to the nature of the bioabsorbable implants used in his study or the self-locking wedge by which his implant acts.

There are some limitations in the study as the sample size which was relatively small and the relatively short follow-up time which if increased would significantly lighten some complications e.g. loosening of screws and effects on the surrounding joints of foot and ankle, Also longer follow up time may answer the major debate about the implant removal and fate of correction after implant removal, unfortunately this study can't answer this question due to the short follow-up time and there were no cases that we had to remove the screws. Lack of control group also was a limitation of this study.

The whole dependence on radiologic correction may have a wide range of inter and intra-observer discrepancies, so in this study we have used the comprehensive ACFAS score as it combines both subjective variables fulfilled by the patient, objective variables e.g. physical examination findings, footprint analysis and radiological assessment.

Superficial and deep infection at sinus tarsi didn't occur in this study as there is no cases which

had suffered this infections while Black, PR et al., [28], reported mean of 2.2% of superficial infection and mean of 0.6% of deep infection in their study using silicone implant. This may suggest that stainless screws are advantageous over silicon Another advantage in our study that there is no reported peroneal spasm in any of our cases while on the other hand Forg P, et al., [29], reported a mean of 0.6% of peroneal spasm in their study and there is no clear explanation for this spasm.

Granberry et al., [30], reported on a single case of avascular necrosis of the talus in one foot ten years following bilateral arthroereisis using a polyethylene device.

Through literature, there is some reported complications regarding overcorrection and forefoot varus but there is no if any reasonable explanation to this in literature and this study also doesn't provide an explanation for that, Although some reports suggest that pre-operative severity of valgus deformity may be a clue for this possible postoperative complications [18].

One of main causes of failure of the procedure is the inability to address the pre-operative equinus deformity of the ankle which acts as a deforming force, in this study we were careful in pre-operative assessment to the equinus deformity by careful clinical examination.

Arthroereisis has the potential for "reversibility" [31]. Compared to alternative operative procedures, the operative insult is small and recovery more speedy when performed in isolation [31]. Where arthroereisis fails, the majority of patients recover to their preoperative state following implant removal. The technical simplicity of arthroereisis does not imply lack of corrective power, nor longevity of correction. Where complications do arise, removal of the implant appears to usually lead to uncomplicated recovery without the irreversible consequences sequelae seen with more aggressive interventions.

Conclusion: Calcaneo-stop procedure is a simple, reliable and minimally invasive procedure for treatment of pediatric flexible flatfoot allowing the alignment of the talus and calcaneus and restoring the medial longitudinal arch of the foot. Proper patient selection, and addressing equinus deformity is important to get the best results. The use of intra-operative fluoroscopy helps to choose the proper size, length of the screw and the optimum direction. Using this minimally invasive technique could achieve correction that is comparable to

other more extensive procedures e.g. Evans calcaneal lengthening osteotomy with less complication. Also, this procedure holds the unique criteria of being friendly to other procedures to be done in the same foot while in the same setting or in the future We recommend using the cancellous screw as its relatively cheaper than silicone implants and with limited side effects e.g. synovitis.

Conflicts of interest:

No conflicts of interest declared.

Authors' contributions:

All authors had equal role in design, work, statistical analysis and manuscript writing.

References

- 1- TOMPKINS M.H., NIGRO J.S. and MENDICINO S.: The Smith STA-peg: A 7-year retrospective study. *J. Foot Ankle. Surg.*, 32 (1): 27-33, 1993.
- 2- JANE MACKENZIE A., ROME K. and EVANS A.M.: The Efficacy of Nonsurgical Interventions for Pediatric Flexible Flat Foot. *J. Pediatr. Orthop.*, 32 (8): 830-4, 2012.
- 3- RICCIO I., GIMIGLIANO F., GIMIGLIANO R., PORPORA G. and IOLASCON G.: Rehabilitative treatment in flexible flatfoot: A perspective cohort study. *Chir. Organi. Mov.*, 93 (3): 101-7, 2009.
- 4- CAPASSO G.: Dynamic varus heel cup: A new orthosis for treating pes planovalgus. *Ital. J. Orthop. Traumatol.*, 19 (1): 113-23, 1993.
- 5- ILAHI O.A. and KOHL^{3rd} H.W.: Lower extremity morphology and alignment and risk of overuse injury. *Clin. J. Sport Med.*, 8 (1): 38-42, 1998.
- 6- KAUFMAN K.R., BRODINE S.K., SHAFFER R.A., JOHNSON C.W. and CULLISON T.R.: The effect of foot structure and range of motion on musculoskeletal overuse injuries. *Am. J. Sports. Med.*, 27 (5): 585-93, 1999.
- 7- STAHELI L.T.: Philosophy of care. *Pediatr. Clin. North. Am.* [Internet], 33 (6): 1269-75m 1986.
- 8- RICHTER M. and ZECH S.: Foot and Ankle Surgery Arthrorisis with calcaneostop screw in children corrects Talo-1st.
- 9- JAY R.M. and DIN N.: A Retrospective Study, 6 (2): 101-7, 2012.
- 10- USUELLI F.G. and MONTRASIO U.A.: The Calcaneo-Stop Procedure. *Foot Ankl. Clin.*, 17 (2): 183-9, 2012.
- 11- PAGENSTERT G.I., HINTERMANN B., BARG A., LEUMANN A. and VALDERRABANO V.: Realignment surgery as alternative treatment of varus and valgus ankle osteoarthritis. *Clin. Orthop. Relat. Res.*, 462 (462): 156-68, 2007.
- 12- ANNE REILLY K., LOUISE BARKER K., SHAMLEY D. and SANDALL S.: Influence of foot characteristics on the site of lower limb osteoarthritis. *Foot. ankle. Int.* [Internet], 27 (3): 206-11, 2006.

- 13- MENZ H.B., MUNTEANU S.E., ZAMMIT G.V. and LANDORF K.B.: Foot structure and function in older people with radiographic osteoarthritis of the medial midfoot. *Osteoarthr. Cartil.*, 18 (3): 317-22, 2010.
- 14- METCALFE S.A., BOWLING F.L. and REEVES N.D.: Subtalar Joint Arthroereisis in the Management of Pediatric Flexible Flatfoot: A Critical Review of the Literature. *Foot Ankle. Int.*, 32 (12): 1127-39, 2011.
- 15- VILADOT A.: Surgical treatment of the child's flatfoot. *Clin. Orthop. Relat. Res.*, (283): 34-8, 1992.
- 16- JEROSCH J., SCHUNCK J. and ABDEL-AZIZ H.: The stop screw technique-A simple and reliable method in treating flexible flatfoot in children. *Foot Ankle. Surg.*, 15 (4): 174-8.
- 17- GIANNINI B.S., CECCARELLI F., BENEDETTI M.G., CATANI F. and FALDINI C.: Surgical treatment of flexible flatfoot in children a four-year follow-up study. *J. Bone. Joint. Surg., Am.*, 73-9, 2001.
- 18- VI R. and REVISTA ESPAÑOLA de CIRUGÍA ORTOPÉDICA Y.: Traumatología More than 10 years of follow-up of the stop screw technique, 60 (1): 75-80, 2016.
- 19- DAS S.P., DAS P.B., GANESH S. and SAHU M.C.: Effectiveness of surgically treated symptomatic planovalgus deformity by the calcaneo stop procedure according to radiological, functional and gait parameters. *J. Taibah. Univ. Med. Sci.*, 12 (2): 102-9, 2016.
- 20- FERNÁNDEZ de RETANA P., ÁLVAREZ F. VILADOT R.: Subtalar Arthroereisis in Pediatric Flatfoot Reconstruction. *Foot Ankle. Clin.*, 15 (2): 323-35, 2010.
- 21- PAVONE V., COSTARELLA L., TESTA G., CONTE G., RICCIOLI M. and SESSA G.: Calcaneo-stop procedure in the treatment of the juvenile symptomatic flatfoot. *J. Foot Ankle. Surg.*, 52 (4): 444-7, 2013.
- 22- ZATTI G., TELI M., MOALLI S. and MONTOLI C.: Arthroereisis in flexible flatfoot treatment: Comparative follow-up of two methods. *Foot Ankle. Surg.*, 4 (4): 219-26, 1998.
- 23- de SOUZA NERY C.A., SODRE H., MAGALHAES AAC., MIZUSAKI J.M. and BRUSCHINI S.: Postural flaccid flat foot treatment through calcaneum slipping osteotomy. *Foot*, 1 (3): 151-5, 1991.
- 24- EL-TAYEBY HM.: The severe flexible flatfoot: A combined reconstructive procedure with rerouting of the tibialis anterior tendon. *J. Foot Ankle. Surg.*, 38 (1): 41-9, 1999.
- 25- BRUYN J.M., CERNIGLIA M.W. and CHANEY D.M.: Combination of Evans calcaneal osteotomy and STA-Peg arthroereisis for correction of the severe pes valgo planus deformity. *J. Foot Ankle. Surg.*, 38 (5): 339-46, 1999.
- 26- SCHER D.M., BANSAL M. and HANDLER-MATASAR S.: Extensive Implant Reaction in Failed Subtalar Joint Arthroereisis: Report of Two Cases., 177-81, 2007.
- 27- KONING P.M., HEESTERBEEK P.J.C. and DE VISSER E.: Subtalar arthroereisis for pediatric flexible pes planovalgus: Fifteen years experience with the cone-shaped implant. *J. Am. Podiatr. Med. Assoc.*, 99 (5): 447-53, 2009.
- 28- BLACK P.R.M., BETTS R.P., DUCKWORTH T. and SMITH T.W.D.: The Viladot Implant in Flatfooted Children. *Foot Ankle. Int.* 21 (6): 478-81, 2000.
- 29- FORG P., FELDMAN K., FLAKE E. and GREEN D.R.: Flake-Austin modification of the STA-Peg arthroereisis: A retrospective study. *J. Am. Podiatr. Med. Assoc.*, 91 (8): 394-405, 2001.
- 30- SIFF T.E. and GRANBERRY W.M.: Avascular Necrosis of the Talus Following Subtalar Arthroereisis with a Polyethylene Endoprosthesis: A Case Report. *Foot Ankle. Int.*, 21 (3): 247-9. 2000.
- 31- LANGFORD J.H., BOZOF H. and HOROWITZ B.D.: Subtalar arthroereisis. Valente procedure. *Clin. Podiatr. Med. Surg.* [Internet], 4 (1): 153-61. 9, 1987.
- 32- ZARET D.I. and MYERSON M.S.: Arthroereisis of the subtalar joint. *Foot Ankle. Clin.*, 8 (3): 605-17, 2003.

تقييم نتائج علاج القدم المفلطحة المرنة فى الأطفال بواسطة السمكرة الجزئية لمفصل تحت الثالث

القدم المفلطحة هى حالة طبية تعرف بتشوه القوس الداخلى للقدم بحيث يصبح أكثر تسطحا من المعتاد وينتج عن ذلك تلامس كامل أو شبه كامل للقدم مع الأرض وعلى الرغم من عد وجود إحصاءات دقيقة عن مدى إنتشار هذا التشوه إلا التشوه إلا أنه ممكا لا شك فيه أنها من أكثر التشوهات التى تواجه جراحى العظام المختصين بالأطفال ولتشخيص القدم المسطحة من المهم أن نراجع التاريخ الطبى للمريض ونقوم بفحص إكلينيكى شامل ودقيق للمريض وأحيانا نحتاج لبعض الفحوصات المساعدة مثل الأشعة السينية وطبعة القدم.

حتى الآن يوجد جدل فى اعتبار هذه الحالة الطبية تشوه مرضى أو مجرد ظاهرة طبيعية فى النطاق الطبيعى ويصاحب هذا جدل آخر حول الطريقة المثلى للعلاج فهناك علاج تحفظى مثل التمارين العلاجية وارتداء الأحذية التصحيحية والتحفيز الكهربائى للعضلات وعلى الصعيد الأخر هناك العلاج الجراحى.

هناك مشاكل قد تواجه العلاج التأهيلي من حيث صعوبة شراء بعض المرضى للحذاء التصحيحى وصعوبة ارتدائها معظم اليوم فى الطقس الحار الرطب وكما أن بعض المرضى قد يجدوا صعوبة فى المحافظة على جلسات العلاج الطبيعى مما يجعل العلاج الجراحى وسيلة ناجحة لهؤلاء المرضى خاصة إن تم من خلال عملية بسيطة آمنة ذات تدخل جراحى محدود ومتبوعة بفترة قصيرة من العلاج الطبيعى.

إشتمل البحث على عشرين حالة تعانى من القدم المفلطحة المرنة تراوحت أعمارهم بين ٩ إلى ١٦ سنة جميع الحالات خضعت بالفعل لفترة من العلاج التحفظى وأجريت الجراحة لهم بعد فشل العلاج التحفظى المنتظم لمدة ستة أشهر. تمت المتابعة والجراحة لجميع الحالات فى مستشفيات جامعة طنطا خلال الفترة من مايو ٢٠١٥ إلى مايو ٢٠١٧ وجميع الحالات أتمت فترة متابعة لمدة عام بعد الجراحة.

تم تقييم نتائج هذا البحث بواسطة عدة معايير متمثلة فى استبيان مجتمع العظام الأمريكى لجراحى القدم والكاحل والذى اشتمل على العديد من المتغيرات من أجل تقييم كلى للحالات سواء من خلال أعراض المريض، الفحص الإكلينيكى أو الأشعة. وتحسنت جميع المقاييس المعمول بها لتقييم القدم المفلطحة بعد العملة عن نظيرتها قبل العملية. وقد تمت مناقشة هذه النتائج ومقارنتها بتلك المذكورة فى المراجع والأبحاث والمجلات العلمية من وقائع النتائج السابقة يمكننا استنتاج الآتى :

- أن السمكرة الجزئية لمفصل تحت الثالث هى عملية آمنة لها نسبة نجاح مرتفعة فى علاج القدم المفلطحة المرنة لدى الأطفال بعد فشل طرق العلاج التحفظى.
- لا تعيق هذه العملية أى تدخلات جراحية أخرى للقدم المصابة.
- ننصح بإستخدام المسامير لمعدنية بدلا من نظيرتها المصنعة من السليكون حيث أنها لا تؤدى إلى حدوث إلتهابات حولها.