

## **THE POSSIBLE PROTECTIVE EFFECT OF PROPOLIS (BEE GLUE) ON CYPERMETHRIN-INDUCED HEPATOTOXICITY IN ADULT ALBINO RATS**

*BY*

**Mie Sameer Gomaa, Maha Amin Abd Alla\* and Maha Mohamad Sameer\*\***

*Departments of Forensic Medicine and Clinical Toxicology, Histology\* Faculty of Medicine, Zagazig University  
and Animal Health Research Institute, \*\* Zagazig*

### **ABSTRACT**

*Pyrethroid pesticides were used preferably over organochlorines and organophosphates due to their high effectiveness, low toxicity to non-target organisms and easy biodegradability. It has widespread applications in agriculture through the world resulting in increased human exposure to this compound. The aim of present study was to evaluate the possible protective effect of propolis on hepatotoxic effect caused by cypermethrin in adult male Albino rats. Fifty adult male albino rats were included in the current study and classified into 4 groups. Group I (control) subdivided into (a): negative control received 2ml saline orally daily and (b): positive control received orally daily 2 ml corn oil. Group II: received orally daily (cypermethrin 14.5 mg/kg) dissolved in corn oil. Group III: received orally daily (propolis 200 mg/kg) dissolved in saline. Group IV: received orally daily (cypermethrin 14.5 mg/kg dissolved in corn oil + propolis 200 mg/kg dissolved in saline). After 4 weeks of treatment, blood samples were collected for estimation of the levels of liver enzymes [ alanine aminotransferase (ALT), aspartate aminotransferase (AST), alkaline phosphatase (ALP)], total proteins, albumin, total cholesterol, triglyceride, very low density lipoprotein-cholesterol (VLDL-c), then rats were sacrificed, the liver was excised, and subjected to estimation of levels of malondialdehyde (MDA), antioxidant enzymes [catalase (CAT), superoxide dismutase (SOD), glutathion peroxidase (GPx)], and histopathological examination. Cypermethrin induced a significant increase in the levels of liver enzymes, total cholesterol, and MDA. While total protein, albumin, triglyceride, VLDL-c and antioxidant enzymes were decreased when compared to control rats. Histopathological examination of the liver revealed congestion of central and portal veins with hydropic degeneration of hepatocytes. Propolis administration with cypermethrin induced a significant decrease in levels of liver enzymes, total cholesterol and MDA and a significant increase in the levels of antioxidant enzymes, total protein, triglyceride and VLDL-c. Histopathological examination of the liver revealed apparent improvement of lesions induced by cypermethrin. It was concluded that propolis has a beneficial influences in reducing the hepatotoxic effects of cypermethrin in male Albino rats.*

### **INTRODUCTION**

Pesticides are used widely in agricul-

ture for control of insects all over the world with more than 10,000 commercial formulations of approximately 450 pesti-

dal compounds currently in use (Cengiz et al., 2001). Synthetic pyrethroids represent one quarter of the insecticides used in the agriculture all over the world. Synthetic pyrethroids such as cypermethrin, permethrin and delta-methrin are among the most commonly used pesticides/insecticides in developing countries including Egypt. These agents are used preferentially in place of other pesticides because of their high insecticidal activity and considerably low toxicity to mammals and birds (Yousef et al., 2006).

In 1997 cypermethrin, was allowed for turn over as a very active insecticide, effective in control of many pest species in agriculture animal breeding and the household (Luty., et al 2000). After household treatment cypermethrin, persists in the air, on walls and furniture for about three months (Cox, 1996). In spite of low toxicity of synthetic pyrethroids persistence of these compounds in mammalian tissue, may be dangerous (Shakoori. et al., 1992).

Due to their lipophilicity, pyrethroid insecticides favor absorption through the gastrointestinal and respiratory tracts and also confer preferential distribution into lipid-rich internal tissues, including body fat, skin, liver, kidney, ovaries and the central and peripheral nervous systems (Soderlund et al., 2002). Liver is the major site of pesticides metabolism. This soft tis-

sue accumulates a greatest concentration of its metabolites (Kurutas et al., 2009). Several reports have shown that cypermethrin is a hepatotoxic pesticide. During cypermethrin metabolism, reactive oxygen species (ROS) were generated and caused oxidative stress in intoxicated animals (El-Demerdash et al., 2003 and 2004). Many studies were carried out to evaluate the potential role of antioxidant for the protection of cells against oxidative damage due to pesticides toxicity (Pregiosi et al., 1998).

Nature produces an array of antioxidants to prevent free radical formation or to limit their damaging effects in the cell. Propolis (bee glue), a natural product collected by honey bees, is composed of mainly polyphenols and flavonoids that exhibit a variety of pharmacological actions (Claus et al., 2000). Propolis has been used in folk medicine since ancient times and is known for its antimicrobial, antiparasitic, antiviral, anti-inflammatory, antitumoral and antioxidant properties (Yousef et al., 2003 and Paulino et al., 2008).

Furthermore, Shukla et al. (2005) and Bhadauria et al. (2007) have reported profound curative hepatoprotective activity of extract of propolis against carbon tetrachloride intoxication. Also Nirala et al. (2008) reported that propolis extract has potential to reverse acetaminophen induced hepatorenal dysfunction.

Based on these findings, the objective of the current study was to evaluate the protective effect of propolis against cypermethrin induced hepatotoxicity using biochemical approaches including assessment of liver function tests, antioxidant enzymes activities, MDA, as well as hepatic histopathology.

### **MATERIAL AND METHODS**

**Chemicals:** Cypermethrin was obtained from Kima Chemicals Company, Egypt and propolis was purchased from Sigma/IBE.

#### **Experimental Design:**

Fifty adult male rats, weighing 230-290 gm, were purchased from the animal breeding house of Faculty of Veterinary Medicine, Zagazig University. The animals were housed in stainless steel cages and provided with commercial laboratory animal food and water ad libitum. The animals were classified into 4 groups:

**Group I (control, 20 rats):** subdivided into (Ia) negative control received 2ml saline orally daily and (Ib) positive control that received 2 ml corn oil orally daily.

**Group II (10 rats):** received orally, daily 14.5 mg/kg body weight cypermethrin (1/10 of LD50 of cypermethrin (Gabbianelli et al., 2004) dissolved in corn oil.

**Group III (10 rats):** received orally, dai-

ly (propolis 200 mg/kg body weight) dissolved in saline (Bhadauria, et al., 2007).

**Group IV (10 rats):** received orally, daily (200 mg/kg propolis dissolved in saline +14.5 mg/kg body cypermethrin dissolved in corn oil) by oral gavage.

The experiment extended for 4 weeks. Twenty four hours after the last treatment, the rats were fasted overnight then anaesthetized by diethyl ether, blood samples were taken from the retro-orbital plexus to sterile tubes. Blood samples were centrifuged and serum was separated and used for the estimation of biochemical parameters. Then, rats were sacrificed; livers were dissected out, washed with saline. Some liver samples were minced and homogenized (10% w/v) in an appropriate buffer (pH 7.4) and centrifuged. The resulting supernatants were used for antioxidant enzymes activities, MDA assays. The other liver samples were immediately fixed in 10% formalin solution for histopathological studies.

### **METHODS**

#### **I- Biochemical evaluation:**

##### **a- Liver function tests**

Total protein, albumin, alkaline phosphatase (ALP), aspartate aminotransferase (AST), alanine aminotransferase (ALT), total cholesterol, triglyceride and very low density lipoprotein- cholesterol (VLDL- c)

were measured spectrophotometrically in serum using Roche commercial kits by autoanalyzer (Roche Hitachi 912).

#### **b- Measurement of MDA levels**

MDA content was estimated, according to the method of Ohkawa et al. (1979). The MDA values were calculated using 1,1,3,3-tetraethoxypropane as the standard and expressed as nmoles of MDA/g liver.

#### **c- Determination of antioxidant enzymes levels:**

The catalase (CAT) level was determined according to the method of Aebi (1974). The rate of H<sub>2</sub>O<sub>2</sub> decomposition was followed by monitoring absorption at 240 nm. One unit of CAT activity is defined as the amount of enzymes required to decompose 1 mmol of hydrogen peroxide in 1 min. The enzyme activity was expressed as mmol H<sub>2</sub>O<sub>2</sub> consumed/min/mg protein.

Superoxide dismutase (SOD) level was assayed by the method of Marklund and Marklund (1974). One unit (U) corresponds to the enzyme activity required to inhibit half of the oxidation of pyrogallol and the SOD activity was expressed as U/mg of protein.

Glutathion peroxidase (GPx) level was measured by modified method of Flohe and Gunzler (1984). The absorbance of the reaction product was recorded at 412 nm

and the enzyme activity was calculated as U/mg protein.

#### **II. Histopathological examination:**

Liver samples were fixed in 10% formalin in phosphate buffer. Tissue was embedded in paraffin, and 5µm thick sections were stained with hematoxylin and eosin stain according to the method of Bancroft and Gamble (2002).

#### **III- Statistical analysis**

The data were analyzed by one-way ANOVA and the significant differences between the controls and the treated groups were evaluated by Student's t-test. P value of 0.05 was considered significant.

### **RESULTS**

There was no mortality in any groups at any time of the study. There was a non statistically significant difference between the two control groups in the level of liver function tests. Light microscopic evaluation of both groups showed regular morphology of the liver (Fig. 2).

In cypermethrin -treated group, it was found that cypermethrin induced a significant increase in the mean values of AST, ALT and ALP levels and a significant decrease in the mean values of total protein and albumin levels as compared with control group (P<0.05) (Table 1). Cypermethrin also induced a significant increase in

total cholesterol level and a significant decrease in triglyceride and VLDL-c level as compared with control group ( $P < 0.05$ ) (Fig. 1). Cypermethrin also induced a significant increase in the mean value of MDA and a significant decrease in the mean values of antioxidant enzyme activities (CAT, SOD and GPx) in rats' liver as compared with control group ( $P < 0.05$ ) (Table 2).

Light microscope examination of the liver of cypermethrin treated group revealed congestion of central and portal veins with hydropic degeneration of hepatocytes and a few cases of degenerative changes of hepatocytes and marked leukocytic infiltration (Fig. 2).

Propolis co-administration with cypermethrin induced a significant decrease in AST, ALT and ALP levels and a significant increase in total protein and albumin levels when compared with cypermethrin-treated group ( $P < 0.05$ ) (Table 1). It also induced a significant decrease in the total cholesterol level and a significant increase in triglyceride and VLDL-c level as compared with cypermethrin-treated group ( $P < 0.05$ ) (Fig. 1).

Propolis co-administration with cypermethrin also induced a significant decrease in the mean value of MDA and a significant increase in the mean values of antioxidant enzyme activities (CAT, SOD

and GPx) as compared with cypermethrin treated group ( $P < 0.05$ ) (Fig. 2).

The normal hepatocytes were observed in most areas when propolis was co-administered with cypermethrin, however, mild sinusoidal dilation with inflammatory cell infiltration was also present (Fig. 2).

Treatment with propolis alone did not cause any significant change in biochemical parameters such as AST, ALT, ALP, total protein, triglyceride, total cholesterol, MDA and antioxidant enzymes in rats as compared with control group (Table 1 and 2). Also the normal histological pattern of liver tissue was observed in propolis treated group (Fig. 2).

## DISCUSSION

Pyrethroids account for around 30% of the worldwide insecticide market. Pyrethroids have a reputation of being safe so the careless and indiscriminate use of pyrethroids insecticides such as cypermethrin has been reported to cause acute as well as chronic toxicity in non target species including humans (Cantalamesa, 1993). Most toxic chemicals are metabolized in liver and these processes may cause liver injuries.

The estimations of various enzyme levels like ALT and AST were carried out be-

cause they represent the functional status of liver.

In the present study, cypermethrin induced a significant increase in the mean values of ALT and AST, ALP activities as compared with control group. Yanpallewar et al. (2003) stated that high serum concentrations of ALT, AST, and LDH indicated cellular leakage due to disintegration of cell membrane in liver.

The increase in transaminase activities is probably due to the cypermethrin-induced pathological changes in liver and is an indication of liver damage. (Choudhary et al., 2003 and Yousef et al., 2003).

In addition, cypermethrin induced a significant increase in total cholesterol level and a significant decrease in triglyceride and VLDL-c level as compared with control group which may be attributed to the effect of pesticides on the permeability of liver cell membrane (Adham et al., 1997). or, to the blockage of liver bile ducts causing reduction or cessation of its secretion to the duodenum (Zaahkouk et al., 2000).

In the current study, the significant decrease in the antioxidant enzyme activities (CAT, SOD and GPx) and increased level of MDA in liver tissues suggested that cypermethrin induced oxidative stress. This result is in agreement with Atessahin et al.

(2005) who reported that administration of cypermethrin has been shown to produce oxidative stress by generating reactive oxygen species and reducing the antioxidant defense systems. Furthermore Manna et al., (2004) reported that cypermethrin undergoes metabolism in the liver via esoteric and oxidative pathways by the cytochrome P450 microsomal enzyme system which results in oxidative stress by producing the depletion of the activity of free radical scavengers and increased level of MDA causing hepatic necrosis leading to pathological changes on liver and other tissues

Microscopically, the histopathological changes in the liver of rats exposed to cypermethrin agree with those published by El-Toukhy and Girgis (1993) who reported that a single dose of 62.5 mg/kg of cypermethrin administered orally to adult Albino rats produced necrotic areas in hepatocytes and cell swelling and that with oral doses of 31.5 mg/kg of cypermethrin over 3 weeks, cytoplasmic hypertrophy and intracytoplasmic vacuoles were seen. Also Grewal et al. (2010) reported that cypermethrin administration at 14.5 mg/kg for 30 consecutive days produced congestion, marked degenerative changes of hepatocytes, these histopathological changes in the liver may be explained by the fact that cypermethrin induced oxidative stress may account for the degenerative changes in various organs such as liver,

lung, heart and kidneys (Manna et al., 2006).

Recently much attention has been focused on protective role and mechanism of action of naturally occurring compounds in biological system. Propolis, a mixture of phenolic acids, flavonoids and other bioactive compounds, is known to have antioxidative effects (Fadillioglu et al., 2004).

After treatment of rats with cypermethrin plus propolis the activities of AST, ALT and ALP were normalized to their control values. This result is in agreement with the findings that propolis induced reduction of the increased activity of AST and ALT in plasma of rats treated with alcohol (Kolankaya et al., 2002) or galactoseamine (Nirala et al., 2008). Newairy et al. (2009) reported that propolis tended to prevent hepatic damage and suppressed the leakage of enzymes through cellular membranes. Propolis treatment decreased the levels of AST, ALT, and ALP towards the respective control value that was an indication of stabilization of plasma membrane as well as repairment of hepatic tissue damage that can be considered as an expression of the functional improvement of the hepatocytes (Nirala and Bhadauria, 2008)

The current study showed that co-administration of propolis with cyper-

methrin decreased total cholesterol and increased triglyceride, total protein levels compared to the rats treated with cypermethrin alone. Similar results were reported by Kolankaya et al. (2002) who demonstrated that propolis caused a decrease in cholesterol level of rats treated with alcohol and Fuliang et al. (2004) who found that oral administration of propolis significantly lowered total cholesterol and VLDL-c in serum of rats; and to increased serum levels of HDL-c, triglycerides. Some studies suggested that propolis can act in several ways to lower plasma VLDL-bound cholesterol, first, uptake of cholesterol in the gastrointestinal tract could be inhibited; second, VLDL-c could be eliminated from the blood via LDL receptor; and finally, the activity of cholesterol-degrading enzymes, namely cholesterol-7-hydroxylase could be increased. It has been suggested that propolis decreased total cholesterol and VLDL-c, while increased HDL-c due to absorption, degradation or elimination of cholesterol (Kolankaya et al., 2002 and Fuliang et al., 2004).

In the present study, co-administration of propolis with cypermethrin induced a significant decrease in the mean value of MDA and a significant increase in the mean values of antioxidant enzyme activities (CAT, SOD and GPx) as compared with cypermethrin treated group. This result is in accordance with the findings of

Newairy et al. (2009) who reported that after treatment of rats with AlCl<sub>3</sub> plus propolis the activities of antioxidant enzymes were normalized to their control values. Also Kanbura et al. (2009) reported a significant decrease in the plasma and tissue (liver, kidney and brain) MDA levels, and increase in the antioxidant enzymes parameters (SOD, CAT, and GSH-Px) of animals that were administered propolis in association with propetamphos, in comparison to the group that was administered propetamphos alone.

The antioxidant activities of propolis are related to its ability to scavenge singlet oxygen, superoxide anions, proxy radicals, hydroxyl radicals and peroxy nitrite (Ferrali et al., 1997). The primary mechanism of the effect of propolis may involve the scavenging of free radicals that cause lipid peroxidation. The other mechanism may comprise the inhibition of xanthine oxidase, which is known to cause free rad-

icals to be generated (Kanbura et al., 2009).

The present study showed that administration of propolis alone did not cause any significant alteration on the biochemical and histological indices of the liver. These findings are similar to the data reported by Sforcin et al. (1995) and Mani et al. (2006) who demonstrated that treatment with propolis did not cause any significant change in biochemical parameters such as AST, ALT, total protein, glucose, triglyceride and total cholesterol in rats.

### **CONCLUSION**

In conclusion, our results demonstrated that administration of propolis to rats treated with cypermethrin exerted significant protective role against the oxidative stress in liver. This study recommended further investigations on human exposed to cypermethrin and modulates its residential usage.

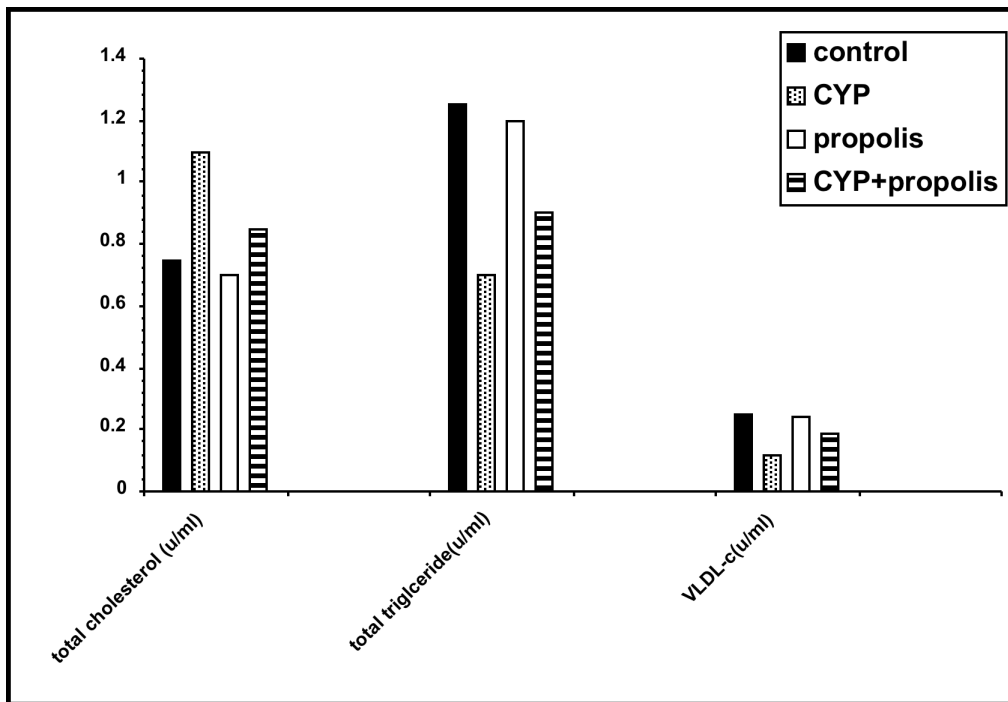


**Table (1):** Effect of Cypermethrin (Cyp.), propolis and their combination on hepatic function (ALT, AST, ALP, total protein and albumin) in male Albino rats.

Parameters	Group I (Control)	Group II (Cyp.)	Group III (Propolis)	Group IV (Cyp.+propolis)	P
	Mean ± S.D	Mean ± S.D	Mean ± S.D	Mean ± S.D	
<b>AST (unit/l)</b>	<b>32.3±0.30</b>	<b>54.2±0.27(a)</b>	<b>32.4±0.3</b>	<b>47.8±0.2(b)</b>	<b>&lt;0.05</b>
<b>ALT (unit/l)</b>	<b>76.1±0.24</b>	<b>99.14±0.28(a)</b>	<b>74.3±0.19</b>	<b>79.3±0.27(b)</b>	<b>&lt;0.05</b>
<b>ALP (unit/l)</b>	<b>110.9±0.20</b>	<b>155.5±0.31(a)</b>	<b>119.1±0.23</b>	<b>126.1±0.23(b)</b>	<b>&lt;0.05</b>
<b>Total proteins(g/dl)</b>	<b>9.73±0.31</b>	<b>5.5±0.20(a)</b>	<b>9.56±0.28</b>	<b>7.8±0.23(b)</b>	<b>&lt;0.05</b>
<b>Albumin(g/dl)</b>	<b>4.7±0.29</b>	<b>2.7±0.26(a)</b>	<b>4.9±0.27</b>	<b>4.1±0.24(b)</b>	<b>&lt;0.05</b>

(a): Significantly different from control group (P < 0.05).

(b): Significantly different from cypermethrin treated group (P < 0.05).



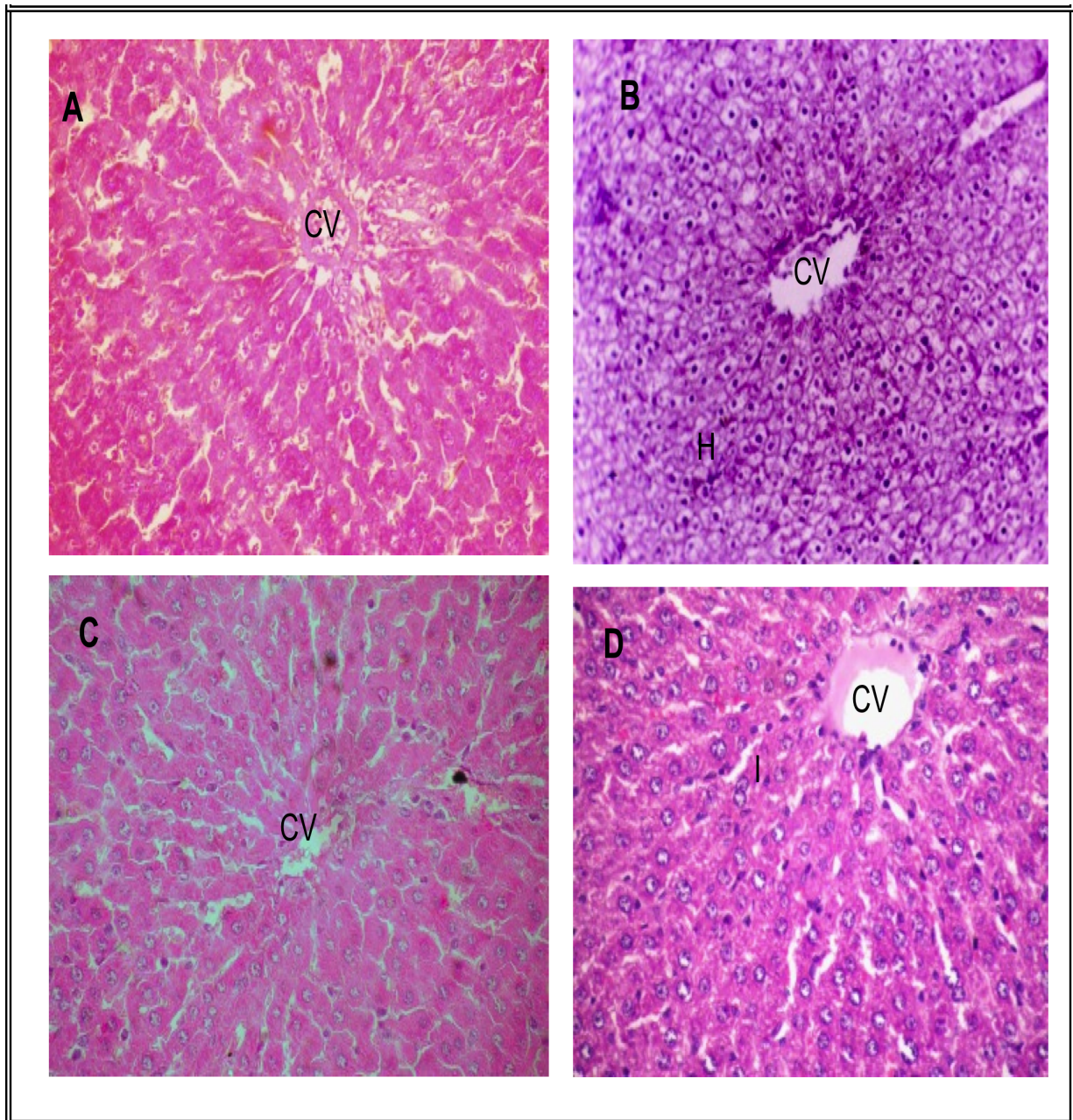
**Figure (1):** Effect of Cypermethrin (Cyp.), propolis and their combination on serum total cholesterol, triglyceride, VLDL-cholesterol profile in adult Albino rats.

**Table (2):** Effect of Cypermethrin (Cyp.), propolis and their combination on antioxidant enzyme activities (CAT, SOD and GPx) and MDA in rats' livers.

Groups	Group I (Control)	Group II (Cyp.)	Group III (Propolis)	Group IV (Cyp.+propolis)	P
	Mean ± S.D	Mean ± S.D	Mean ± S.D	Mean ± S.D	
<b>Catalase</b> (mmoles /min/mg protein).	<b>24.9±1.05</b>	<b>18.6±1.16(a)</b>	<b>25.2±1.32</b>	<b>21.9±0.55(b)</b>	<b>&lt;0.05</b>
<b>Superoxide dismutase</b> (units/mg protein)	<b>14.2±2.33</b>	<b>10.8±1.29(a)</b>	<b>14.4±13.7</b>	<b>11.7±1.15(b)</b>	<b>&lt;0.05</b>
<b>Gluthathione peroxidase</b> (units/mg protein.)	<b>74.7±1.28</b>	<b>64.39±1.20(a)</b>	<b>74.5±74.8</b>	<b>70.03±1.21(b)</b>	<b>&lt;0.05</b>
<b>Malondialdehyde</b> (units/mg protein.)	<b>11.5±0.9</b>	<b>15.4±1.1(a)</b>	<b>11.0±1.2</b>	<b>12.5±0.8(b)</b>	<b>&lt;0.05</b>

(a): Significantly different from control group (P < 0.05).

(b): Significantly different from cypermethrin treated group (P < 0.05).



**Figure (2):** Photomicrograph of liver section of [A] control liver showing well arranged hepatocytes with obvious sinusoids around the central vein [B] Cyp. treated rats showing dilatation of central vein (CV) and hydropic degeneration (H). [C] Propolis treated rats showing normal histological pattern [D] Cyp.+propolis treated rats showing normal hepatocyte, mild central vein dilation with mild inflammatory cell infiltration(I) ( Hx &E stain, X140).

## REFERENCES

- Aebi, H. (1974):** Catalase. In: Methods in Enzymatic Analysis. Bergmeyer, H.V. (Ed), Vol 2, Academic Press, New York, p.p. 673-678.
- Adham, K. G.; Khairalla, A.; Abu-Shabana, M.; Addel-Mguis, N. and Abd El-Mmoneim, A. (1997) :** "Environmental stress in Lake Maryut and physiological response of Tilapia zilli Gerv". J. Environ. Sci. Health A., 32: 2585-2598.
- Atessahin, A.; Yilmaz, S.; Karahan, I. and Tasmadir, P. B. (2005) :** "The effects of vitamin E and selenium on cypermethrin induced oxidative stress in rats". Turk. J. Vet. Anim. Sci., 29: 385-91.
- Bancroft, J. and Gamble, A. (2002) :** Theory and Practice of Histological Techniques. 5th ed, Churchill, Livingstone, New York, London. p.p.: 165-180.
- Bhadoria, M.; Nirala, S. K. and Shukla, S. (2007) :** "Duration-dependent hepatoprotective effects of propolis extract against carbon tetrachloride-induced acute liver damage in rats". Advances In Natural Therapy, 24(5): 1220-1226.
- Bhadoria, M.; Nirala, S. K. and Shukla, S. (2008) :** "Multiple treatment of propolis extract ameliorates carbon tetrachloride induced liver injury in rats". Food and Chemical Toxicology, (46) : 2703-2712.
- Cantalamesa, F. (1993) :** "Acute toxicity of two pyrethroids, permethrin and cypermethrin in neonatal & adult rats". Arch. Toxicol., (67): 510-513.
- Cengiz, E. I.; Unlu, E. and Balci, K. (2001) :** "The histopathological effects of thiodan on liver and gut of mosquito fish, gambusia affinis". J. Environ. Sci. Health B., 36 (1): 75-85.
- Choudhary, N.; Sharma, M.; Verma, P. and Joshi, S. C. (2003) :** "Hepato and nephrotoxicity in rat exposed to endosulfan". J. Environ. Biol., 24: 305-308.
- Claus, R.; Kinscherf, R.; Gehrke, C.; Bonaterra, G.; Basnet, P.; Metz, J. and Deigner, H. P. (2000) :** "Antiapoptotic effect of propolis extract and propolis on human macrophages exposed to minimally modified low density lipoprotein". Arzneimittelforschung., 50 (4): 373-379.
- Cox, C. (1996) :** "Insecticide factsheet, cypermethrin". J. Pesticide Refor ., 16 : 15-20 .
- El-Demerdash, F. M.; Yousef, M. I. and Al-Salhen, K. S. (2003) :** "Protective effects of isoflavone on some biochemical parameters affected by cypermethrin in male rabbits". J. Environ. Sci. Health B., 38: 365-378.

**El-Demerdash, F. M.; Yousef, M. I.; Kedwany, F. S. and Baghdadi, H. H. (2004):** "Role of alphanatocopherol and beta-carotene in ameliorating the fenvalerate-induced changes in oxidative stress, hemato-biochemical parameters, and semen quality of male rats". *J. Environ. Sci. Health B.*, (39): 443-459.

**El-Toukhy, M. A. and Girgis, R. S., (1993) :** "In vivo and in vitro studies on the effect of Larvin and cypermethrin on adenosine triphosphatase activity of male rats". *J. Environ. Sci. Health B.*, 28 (5): 599-619.

**Fadillioglu, E.; Ortas, E.; Erdogen, H.; Yagmurca, M.; Sogut, S.; Ucar, M. and Irmak, M. K. (2004) :** "Protective effect of caffeic acid phenethyl ester on doxorubicin-induced cardio toxicity in rats". *J. Appl. Toxicol.*, (24): 47-52.

**Ferrali, M.; Signorini, C. and Caciotti, B. (1997) :** "Protection against oxidative damage of erythrocytes membrane by the flavinoid quercetin and its relation to iron chelating activity". *FEBS Lett.*, (416):123-129.

**Flohe, L. and Gunzler, W. A. (1984) :** "Assays of glutathione peroxidase". *Methods Enzymol.*, (105): 114-121.

**Fuliang, H. U.; Hepburn, H. R.; Xuan, H.; Chen, M.; Daya, S. and Radloff, S. E.**

**(2004):** "Effects of propolis on blood glucose, blood lipid and free radicals in rats with diabetes mellitus". *Pharmacol. Res.*, (104): 147-152.

**Gabbianelli, R.; Nasuti, C.; Falcioni, G. and Cantalamessa, F. (2004) :** "Lymphocyte DNA damage in rats exposed to pyrethroids: Effect of supplementation with vitamins E and C". *Toxicology*,15, 203 (1-3): 17-26.

**Grewal, K. K.; Sandhu, G. S.; Kaur, R.; Brar, R. S. and Sandhu, H. S. (2010) :** "Toxic impacts of cypermethrin on behavior and histology of certain tissues of albino rats". *Toxicol. Int.*, (17): 94-8.

**Kanbura, M.; Eraslan, G. and Silici, S. (2009) :** "Antioxidant effect of propolis against exposure to propetamphos in rats". *Ecotoxicol. Environ. Safety*, (72): 909-915.

**Kolankaya, D.; Selmanoglu, G.; Sor-kun, K. and Salih, B. (2002) :** "Protective effects of Turkish propolis on alcohol induced serum lipid changes and liver injury in male rats". *Food Chem.*, 78: 213-217.

**Kurutas, E. B.; Sahan, A. and Altun, T. (2009) :** "Oxidative stress biomarkers in liver and gill tissues of spotted barb (*Capoeta barroisi* Lortet, 1894) living in the river Ceyhan, Adana, Turkey". *Turk. J. Biol.*, 33: 275-282.

**Luty, S.; Latuszynska, J.; Tokarska, M and Haratym-Maj, A. (2000) :** "Subacute toxicity of orally applied alpha-cypermethrin in swiss mice". *Ann. Agric. Environ. Med.*, 7: 33-41.

**Manna, S.; Bhattacharyya, D.; Mandal, T. K. and Das, S. (2004) :** "Repeated dose toxicity of alfa- cypermethrin in rats". *J. Vet. Sci.*, 5 (3): 241-245.

**Manna, S.; Bhattacharyya, D.; Mandal, T. K. and Das, S. (2006) :** "Sub-chronic toxicity study of alfa-cypermethrin in rats". *Iranian Journal of pharmacology & therapeutics*, 5:163-166.

**Mani, F.; Damasceno, H. C.; Novelli, E. L.; Martins, E. A. and Sforcin, J. M. (2006) :** " Propolis: Effect of different concentrations, extracts and intake period on seric biochemical variables". *J. Ethnopharmacol.*, 105: 95-98.

**Marklund, S. and Marklund, G. (1974):** "Involvement of the superoxide anion radical in the autoxidation of pyrogallol and a convenient assay for superoxide dismutase". *Eur. J. Biochem.*, 47: 469-74.

**Newairy, A. S.; Salama, A. F.; Hussien, H. M. and Yousef, M. (2009) :** "Propolis alleviates aluminium-induced lipid peroxidation and biochemical parameters in male rats". *Food Chem. Toxicol.*, 47: 1093-1098.

**Nirala, S. and Bhadauria, M. (2008) :** "Propolis reverses acetaminophen induced acute hepatorenal alterations: A biochemical and histopathological approach". *Arch. Pharm. Res.*, 31 (4): 451-461.

**Nirala, S. K.; Bhadauria, M.; Shukla, S.; Agrawal, O. P.; Mathur, A.; Li, P. Q. and Mathur, R. (2008) :** "Pharmacological intervention of tiferron and propolis to alleviate beryllium-induced hepatorenal toxicity". *Fundam. Clin. Pharmacol.*, 22: 403-415.

**Ohkawa, H.; Ohishi, N. and Yagi, K. (1979) :** "Assay for lipid peroxides in animal tissues by thiobarbituric acid reaction". *Anal. Biochem.*, 95: 351-358.

**Paulino, N.; Abreu, S. R.; Uto, Y.; Koyama, D.; Nagasawa, H.; Hori, H.; Dirsch, V. M.; Vollmar, A. M.; Scremin, A. and Bretz, W. A. (2008) :** "Anti-inflammatory effects of a bioavailable compound, Artepillin C, in Brazilian propolis". *Eur. J. Pharmacol.*, 587:296-301.

**Pregiosi, P.; Galan, P.; Hebeth, B.; Valeix, P.; Roussel, A. M.; Malvy, D.; Favier, A. and Hercberg, S. (1998) :** "Effect of supplementation with a combination of antioxidant vitamins and trace elements, at nutritional doses, on biochemical indicators and markers of the antioxidant system in adult subjects". *J. Am. Coll. Nutr.*, 17 (3): 244 -/249.

**Shakoori, A. R.; Aslam, M.; Sabir, M. and Ali, S. S. (1992) :** "Effect of prolonged administration of insecticide (cyhalothrin/karate) on the blood and liver of rabbits". *Folia. Biol. Krakw.*, 40 : 91-99.

**Sforcin, J. M.; Funari, S. R. and Novelli, E. L. (1995) :** "Serum biochemical determinations of propolis treated rats". *J. Venom. Anim. Toxins.*, 1: 31-37.

**Shukla, S.; Bhadauria, M. and Jadon, A. (2005) :** "Evaluation of hepatoprotective potential of propolis extract in carbon tetrachloride induced liver injury in rats". *Indian J. Biochem. Biophys.*, 42: 321-325.

**Soderlund, D. M.; Clark, J. M.; Sheets, L. P.; Mullin, L. S.; Piccirillo, V. J. and Sargent, D. (2002) :** "Mechanisms of pyrethroid neurotoxicity: Implications for cumulative risk assessment". *Toxicology*, 171: 53-59.

**Yanpallewar, S. U.; Sen, S.; Tapas, S.; Kumar, M.; Raju, S. S. and Acharya, S. B. (2003) :** "Effect of *Azadirachta indica* on paracetamol induced hepatic damage in albino rats". *Phytomed.*, 10: 391- 396.

**Yousef, M. I.; El-Demerdash, F. M.; Kamel, K. I. and Al-Salhen, K. S. (2003) :** "Changes in some hematological and biochemical indices of rabbits induced by isoflavones and cypermethrin". *Toxicology*, 189: 223-234.

**Youssef, M. I.; Awad, T. I. and Mohamed, E. H. (2006):** "Deltamethrin-induced oxidative damage and biochemical alterations in rat and its attenuation by Vitamin E". *Toxicology*, 227: 240-247.

**Zaahkouk, S. A.; Helal, E. G.; Abd-Rabo, T. E. and Rashed, S. Z. (2000) :** "Carbamate toxicity and protective effect of Vit. A and Vit.E on some biochemical aspects of male albino rats". *Egypt J. Hosp. Med.*, 1: 60-77.

## الدور الوقائي المحتمل للبروبوليز (صمغ النحل) على التأثيرات السمية للسيبرميثرين على الكبد في الجرذان البيضاء البالغة

المشتركون في البحث

د. هس سمير جمعه      د. مها أمين عبد الله\*  
د. مها محمد سمير\*\*

من أقسام الطب الشرعى والسموم الإكلينيكية والهستولوجيا\*

كلية الطب - جامعة الزقازيق ومعهد بحوث صحة الحيوان بالزقازيق\*\*

يعد مركب السيبرميثرين وهو أحد مركبات البيروثرويد المخلقة من أكثر المبيدات الحشرية استخداما وفعالية. فقد أجريت هذه الدراسة لبيان التأثيرات الوقائية المحتملة للبروبوليز ضد الأثر السمي لمركب السيبرميثرين على الكبد في الجرذان البيضاء. أجريت الدراسة على أربع مجموعات من الجرذان. المجموعة الأولى: مجموعة ضابطة سلبية، و أخرى ضابطة إيجابية أعطيت ٢سم<sup>٣</sup> من زيت الذرة عن طريق الفم. المجموعة الثانية: أعطيت يوميا ٥, ١٤ مجم/كجم من وزن الجسم سيبرميثرين مذاب في ٢سم<sup>٣</sup> من زيت الذرة عن طريق الفم. المجموعة الثالثة: أعطيت بروبوليز (٢٠٠مجم / كجم) جرعة واحدة يوميا عن طريق الفم. المجموعة الرابعة: أعطيت يوميا سيبرميثرين (٥, ١٤مجم/كجم من وزن الجسم سيبرميثرين مذاب في ٢سم<sup>٣</sup> من زيت الذرة) + بروبوليز (٢٠٠مجم / كجم) جرعة واحدة يوميا عن طريق الفم. وقد استمرت هذه الدراسة لمدة ٤ اسابيع وعند نهاية مدة الدراسة تم تجميع عينات الدم لقياس مستوى انزيمات الكبد ونسبه الدهون والكوليسترول ثم تم ذبح الجرذان لاستخراج الكبد، و فحصه بالميكروسكوب كما تم قياس مستوى الأنزيمات المضاده للأكسدة (الكتاليز والجلوتاثيون بيرواكسيداز والسوبر أكسيد ديسميوتيز) و المألونديهيد في الكبد.

وقد أظهرت نتائج هذه الدراسة ان استخدام البروبوليز مع السيبرميثرين أدى إلى زيادة ذات دلالة إحصائية في مستوى الأنزيمات المضاده للأكسدة في الكبد وانخفاض في مستوى انزيمات الكبد ونسبه الكوليسترول والمألونديهيد ، مع تحسن ملحوظ في التغييرات الباثولوجية في الكبد مقارنة بالمجموعه التي أعطيت السيبرميثرين. مما تقدم يتضح ان البروبوليز له تأثير وقائي على الآثار السمية التي يحدثها السيبرميثرين في الكبد. لذا ينصح الاشخاص المعرضين للسيبرميثرين باستخدام البروبوليز لتقليل آثار السيبرميثرين السمية في الكبد كما ينصح بعمل دراسات أخرى لتقييم الدور الوقائي للبروبوليز ضد الآثار السمية التي تحدثها المبيدات الحشرية الأخرى.