

## Case Report:

# Trans-Vaginal Excision of Anterior Rectal Duplication Cyst in an Adult

DAFER M. AL-SHEHRI, M.D., S.B.-SURG.\*; HALA F. ALI, M.S., M.R.Cs. and  
WALID M. ABD EL-MAKSOUH, M.D., Ph.D., M.R.Cs.\*\*

*The Department of General Surgery, Aseer Central Hospital\* and Faculty of Medicine, King Khalid University\*\*,  
Abha, Saudi Arabia*

### Abstract

**Case Report:** We present an extremely rare case of anterior rectal duplication cyst in a 36-year old female patient. The patient presented with deep perineal pain, constipation, and severe dyspareunia. Pelvic examination showed a mass in the rectovaginal space. The condition has been diagnosed by MRI. The cyst was completely excised through transvaginal approach due to its lower anterior location. The transvaginal approach was safe, easy and was followed by well-preserved anal functions. Post-operative histopathological examination confirmed the diagnosis of rectal duplication cyst. The patient was followed for one year and she reported complete disappearance of her pre-operative symptoms.

**Conclusions:** Although anterior rectal duplication is an extremely rare condition, it should be put into consideration in managing patients with pararectal cysts. MRI is an efficient radiological investigation that accurately describes the cyst and its relation to surrounding structures. Transvaginal approach is a safe and easy approach to excise these lesions, especially when they have a low anterior location.

**Key Words:** Rectal duplication cyst – Trans-vaginal approach – MRI – Dyspareunia.

### Introduction

**ALIMENTARY** tract duplication is a rare anomaly, which was first described by Ladd and Gross in 1937 [1]. Duplication occurs in 1 in 10,000 live-births, and may occur anywhere along the alimentary tract [2]. The most common site of duplication is the ileum accounting for nearly 22% of cases. Rectal duplications are among the rarest locations and occur in 1-8% of cases [2-4]. Most rectal duplication cysts are diagnosed during childhood [2-7]. However, few cases are presented and diagnosed during the adult age [8-11].

**Correspondence to:** Dr. Dafer M. Al-Shehri, The Department of General Surgery, Aseer Central Hospital, Abha, Saudi Arabia

We report a rare case of an anterior rectal duplication cyst that presented in an adult Saudi female, which was operated transvaginally.

### Case Report

In November, 2016, a 36-year old Saudi female patient presented to the outpatient clinic of the Surgery Department in Aseer Central Hospital, with a history of deep perineal pain, chronic constipation and severe dyspareunia. The patient is a mother of 3 children, all born through normal spontaneous vaginal delivery. There was no fever, no perianal or vaginal discharge, and no bleeding per rectum.

General physical and abdominal examination revealed no abnormality. Perineal examination revealed normal perineal body and no perineal descent. Digital rectal examination revealed a mass anterior to the rectum, but no rectocele with normal rectal mucosa. Per-vaginal examination revealed a tender mass located retrovaginally, to the left side up to the fornix with normal overlying vaginal mucosa. Flexible sigmoidoscopy up to the splenic flexure was normal.

The plain radiograph of the abdomen revealed no significant bony or soft tissue abnormality. CT-scan showed a cystic lesion in the rectovaginal space Fig. (1). For more details, MRI of the pelvis was performed and showed “an elongated cystic structure in the recto-vaginal space slightly to the left side that is hypointense on T1W and hyperintense on T2W images Fig. (2). The cyst starts 2 cm above the anal verge with focal attachment to the external anal sphincter and extends along the

anterior left lateral wall of the rectum for almost 8.5cm. The cyst contained a single non enhancing septum. There was a fat plane between the cyst and the posterior vaginal wall. The cyst displaced the left vaginal vessels anteriorly, the left puborectalis muscle laterally and passed to the lower pelvis through the rectal hiatus. No obvious communication with rectum was noted” the impression was of an anterior rectal duplication cyst but due to the unusual anterior location, the less likely diagnosis of congenital Mullerian duct cyst was kept in consideration. No other anatomical anomalies were observed.

Surgical excision through a trans-vaginal approach was decided due to the lower retrovaginal

location of the cyst Fig. (3). The cyst was carefully dissected from the surrounding structures specially puborectalis. Dissection posteriorly from the rectum was not difficult because of absence of communication between them.

Histopathology of the resected cyst showed presence of ciliated columnar epithelial lining with well-developed muscularis propria, thereby confirming the diagnosis of rectal duplications.

The post-operative period was uneventful. The patient was discharged on the 3<sup>rd</sup> post-operative day with preserved anorectal functions. She was followed-up for one year and reported complete disappearance of all her pre-operative symptoms.

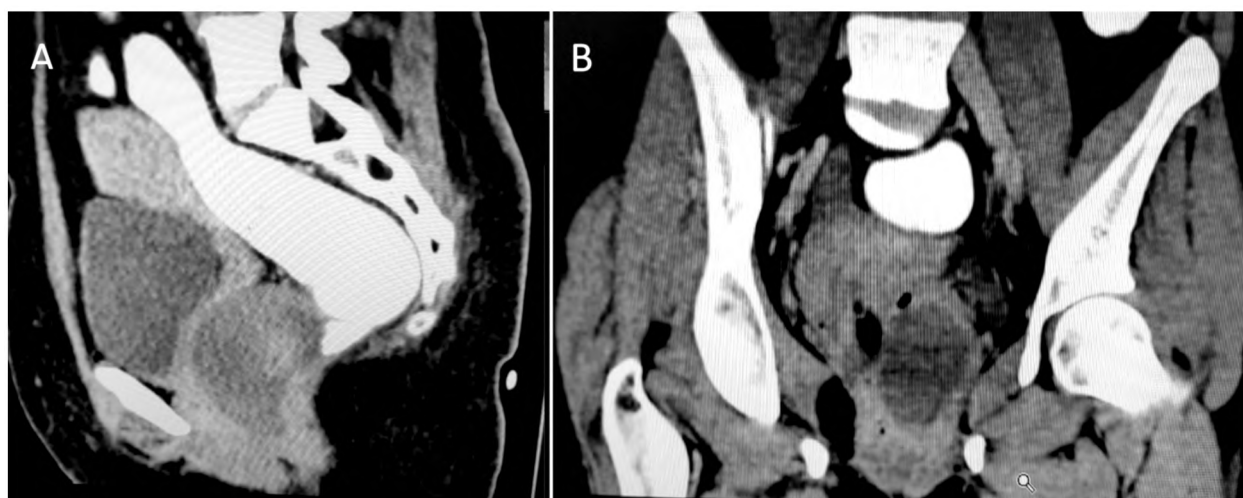


Fig. (1): CT saggital (A) and coronal (B) Planes showing a cystic lesion located between the vagina antriorly and the rectum posteriorly.

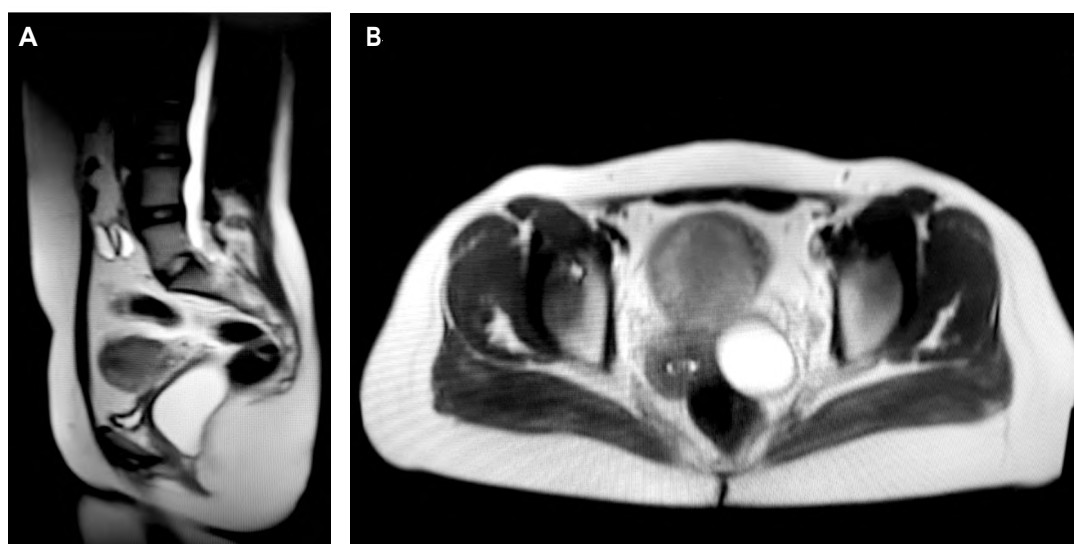


Fig. (2): MRI saggital (A) and axial (B) Planes showing an elongated cystic structure in the recto-vaginal space slightly to the left side.

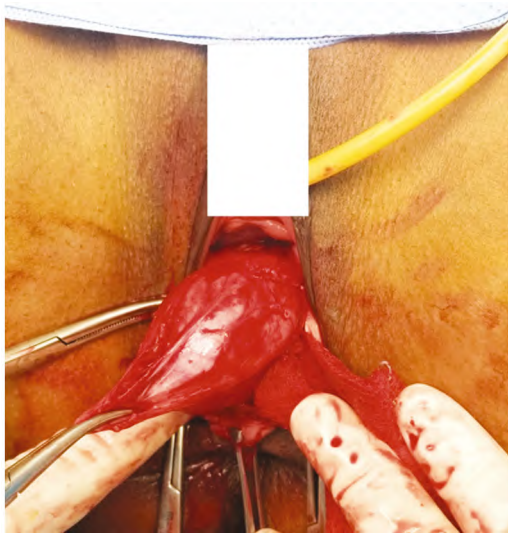


Fig. (3): Intraoperative transvaginal excision of the anterior rectal duplication cyst.

### Discussion

Rectal duplications are rare developmental anomalies. They are generally cystic and only 20%-45% of rectal duplications have fistulous communication with the perineum or anus [5,12]. Differential diagnosis of such lesions in this location includes tail gut cyst, liomyoma, teratoma, hydrocolpos, hydrometrocolpos, and hydrosalpinx [9]. However, three anatomic criteria should be fulfilled in accordance with the definition suggested by Gross and colleagues [13]; the cyst must be attached to the alimentary tract, it must be lined by mucous membranes similar to that part of the alimentary tract, and it must possess a smooth-muscle coat. The last criteria on is important to differentiate between duplication cyst and tail gut cyst [14].

The cyst in our case was fulfilling the three criteria. Embryological theories for enteric duplications include partial caudal twinning, recanalization defects, incomplete separation of the notochord from the endodermal tube, and persistent epithelial buds [5].

The rectal duplication cyst in our patient is located anteriorly which is an extreme rare location. It also presented in adulthood which is uncommon. Most rectal duplications are located in the retro-rectal or posterior rectal region and usually present in childhood [2,4,7]. On the other hand, Flint et al., [11] reported that rectal duplication cyst can present at any age. They also reported that they occur most commonly in females.

Being a rare entity, clinical presentations are usually variable. Our patient presented at the age

of 36 years by deep perineal pain, constipation and severe dyspareunia. Many factors may be responsible for the variability of symptoms; i.e., the size of the duplication, its site, the presence of infection, the presence of ectopic gastric mucosa, and whether it has internal or external communications [6].

The small size and absence of pressure effect during early life of our patient may be the cause of her late presentation. Moreover, the unusual low anterior location of the cyst may be the cause of dyspareunia described by our patient, that was not mentioned before in other case reports. Our opinion is supported by Flint et al., [11], who stated that those cysts that were not discovered in infancy usually remain asymptomatic until complicated. Progressive increase in size usually leads to later presentations.

In our patient, CT was performed and revealed the existence of a cystic lesion located between the rectum posteriorly and the vagina anteriorly. However, MRI revealed the relation between the cyst and the surrounding structures. Magnetic resonance imaging MRI is considered the superior radiological modality for diagnosing rectal duplications and differentiates from them an anterior myelomeningocele, sacrococcygeal teratoma, or other masses [2].

Complete surgical excision through transvaginal approach was the plan of treatment in our patient. Surgical excision is the treatment of choice for rectal duplication cyst to eliminate the pressure effect and also to prevent malignant transformation that has been reported in adults [5,8]. Percutaneous needle biopsy should be avoided because the perineal mass may be a meningocele or a malignancy [11].

The surgical approach was dictated by the position of the cyst and the presence of any vertebral or sacral anomalies. The usual method of excision was through a perineal approach, although abdominal, posterior sagittal, and transrectal approaches have been performed [2,9-11].

Up to the best of our knowledge, transvaginal approach was not reported before for rectal duplication cyst excision. This may be attributed to the extreme rare location of the lesion in our patient being anterior and very low encroaching upon the puborectalis muscle that required extreme intraoperative care during dissection of the cyst to avoid unnecessary injury to anal sphincter. Feasible intraoperative dissection of the cyst with preserved anal functions post-operatively makes transvaginal

approach one of the safe options for excision of such lesions.

#### Conclusions:

Although anterior rectal duplication is an extremely rare condition, it should be put into consideration in managing patients with pararectal cysts. MRI is an efficient radiological investigation that accurately describes the cyst and its relation to surrounding structures. Transvaginal approach is a safe and easy approach to excise these lesions specially when they have a low anterior location.

#### References

- 1- LADD W.E. and GROSS R.E.: Duplications of the Alimentary Tract. Southern Medical Journal; 30: 9, 1937.
- 2- HART IN C.W., LAU S.T., ESCOBAR M.A. and GLICK P.L.: Laparoscopic excision of a newborn rectal duplication cyst. Journal of Pediatric Surgery; 43 (8): 1572-4, 2008.
- 3- JASON KNUDTSON R.J. and HARSH GREWAL: Rectal Duplication. Journal of Pediatric Surgery; 38 (7): 2, 2003.
- 4- MBOYO A., MONEK O., MASSICOT R., MARTIN L., DESTUYNDER O., LEMOUEL A., et al.: Cystic rectal duplication: A rare cause of neonatal intestinal obstruction. Pediatric Surgery International; 12 (5): 452-4, 1997.
- 5- KARAMAN I., KARAMAN A., ARDA N. and CAKMAK O.: External cystic rectal duplication: An unusual presentation of rectal duplication cyst. Singapore Medical Journal; 48 (11): e287-8, 2007.
- 6- RAJAH S., RAMANUJAM T., ANAS S., JAYARAM G., BASKARAN P., GANESAN J., et al.: Duplication of the rectum: Report of four cases and review of the literature. Pediatric Surgery International; 13 (5): 373-6, 1998.
- 7- TAORI K., GOUR P., PATWA D., RATHOD J., DISAWAL A., HATGAONKAR A., et al.: Anterior Rectal Duplication Cyst: A Rare Case Report. Open Access Library Journal; 2 (04): 1, 2015.
- 8- ALAVANJA G., KADERABEK D.J. and HABEGGER E.D.: Rectal duplication in an adult. The American Surgeon; 61 (11): 997-1000, 1995.
- 9- AMJADI K., POENARU D., SOBOLESKI D., HURLBUT D. and KAMAL I.: Anterior rectal duplication: A diagnostic challenge. Journal of Pediatric Surgery; 35 (4): 613-4, 2000.
- 10- CERIOTTI M., SACCOMANI G., LACELLI F. and SACCOMANI G.E.: Wide rectal duplication cyst in an adult resected by anterior approach: Efficacy and recurrence. Journal of Surgical Case Reports; 2017 (6), 2017.
- 11- FLINT R., STRANG J., BISSETT I., CLARK M., NEILL M. and PARRY B.: Rectal duplication cyst presenting as perianal sepsis: Report of two cases and review of the literature. Diseases of the Colon & Rectum; 47 (12): 2208-10, 2004.
- 12- LA QUAGLIA M.P. F.N., ERAKLIS A. and HENDREN W.H.: Rectal duplications. J. Pediatr. Surg.; 25: 5, 1990.
- 13- GROSS R.E., HOLCOMB G.W. and FARBER S.: Duplications of the alimentary tract. Pediatrics; 9 (4): 449-68, 1952.
- 14- ANIL LUTHER N.S.S., AMIT MAHAJAN and KAMAL NABH RAI NEGI: Tailgut Cyst-An unusual Retrovesical Prerectal Location: A Case Report and Review of Literature. J.I.M.S.A.; 27 (4): 2, 2014.

## تقرير حالة: إستئصال كيسة مضاعفة أمامية بالمستقيم من خلال شق الجدار المهبل الخلفي

عرض الحالة: نحن نقدم حالة نادرة جدا لإمرأة عمرها ٣٦ عاما وتعاني من كيسة مضاعفة أمامية بالمستقيم. المريضة كانت تشكو من ألم عميق بالعجان وإمساك وآلام شديدة أثناء الجماع. وبالكشف على الحوض تبين وجود كتلة في الجيبة المستقيمة الرحيمية. فتم عمل أشعة رنين مغناطيسي والتي شخصت الحالة. وتم إستئصال الكيسة بالكامل من خلال شق الجدار المهبل الخلفي نظرا لوجود الكيسة في موضع سفلى أمام المستقيم. أن إستخدام طريقة الإستئصال من خلال شق الجدار المهبل الخلفي كانت آمنة وسهلة ولم تتبعها أية مشاكل لوظيفة معصرة الشرج. وأكد تحليل الأنسجة بعد العملية تشخيص كيسة مضاعفة بالمستقيم. وقد تمت متابعة المريضة لمدة عام بعد إجراء الجراحة، والتي أكدت إختفاء جميع الأعراض التي كانت تشتكى المريضة منها قبل إجرائها.

الإستنتاجات: على الرغم من أن إزدواجية المستقيم الأمامي نادر الحدوث، إلا أنه ينبغي أن يوضع في الإعتبار عند علاج المرضى الذين يعانون من خراجات مجاورة للمستقيم. إن التصوير بالرنين المغناطيسي هو أحد الفحوصات الإشعاعية الفعالة حيث يصف بدقة الكيس وعلاقته مع الأجزاء المحيطة بها، كما أن إجراء الجراحة عبر المهبل نهج آمن وسهل لإستئصال مثل تلك الإصابات المرضية، خاصة عندما تكون ذات موقع أمامي منخفض.