

Vitamin E Improves Doxorubicin Induced Nephrotoxicity; Possible Underlying Mechanisms

HEBA S. SHOUKRY, M.D.¹; RADWA T. HASSANIEN, M.D.²; RABAB A. RASHEED, M.D.³; MOATAZ M. KAMEL, M.D.²; EHAB R. IBRAHIM, M.D.⁴ and HALA S. IBRAHIM, M.Sc.⁵

The Departments of Physiology¹ and Medical Biochemistry², Faculty of Medicine, Cairo University, The Department of Histology, Faculty of Medicine, of October³ and Cairo⁴ Universities and The Department of Clinical Pharmacy, Faculty of Pharmacy, Princess Nora University, KSA⁵

Abstract

Background: Doxorubicin (Dox) nowadays is a widely used chemotherapy, however using it has a lot of side effects on different body organs. Unfortunately Nephrotoxicity is one of its common side effects.

Aim of Work: In this article we tried to seek for the effect of Vitamin E (Vit E) as a commonly used vitamin to reduce Dox induced nephrotoxicity.

Material and Methods: 40 albino rats were involved, they were divided into 4 groups: Control group, Dox group in which Dox was given in a dose of 2.5mg/kg, 3 times/week, Vit E group in this group rats were given Vitamin E alone for 250mg/kg/day daily via intramuscular injection, Dox + Vit E rats in this group received both medications in the previously mentioned doses. At the end of the experimental period blood samples were collected for biochemical analysis of serum Urea, Creatinin and 8-Hydroxy-2'-deoxyguanosine (OHdG). Renal tissues were collected for analysis of tissue OHdG, histological examination (H & E) and immunohistochemical analysis of renal tissue caspase 3 levels.

Results: Our results showed deterioration of all parameters and increased immunohistochemical expression of caspase 3 in Dox treated group. On the other hand administration of Dox with Vit E significantly improved all measured parameters and lowers the expression caspase 3 levels.

Conclusion: Combined treatment of Dox with Vitamin E decreases risk of Dox induced nephrotoxicity. Protective effects of Vitamin E can be due its antioxidant and its antiapoptotic actions.

Key Words: Doxorubicin – Vitamin E – 8-Hydroxy-2'-deoxyguanosine – Caspase 3.

Introduction

NEPHROTOXICITY is one of the important side effects of Doxorubicin therapy. It is well known that Doxorubicin (Dox) which comes under anthra-

cycline group of antibiotics is used for treatment of cancers. In spite of its effective antitumor action, its use is limited due to its side effects on organs as the heart, kidney and testicles [1]. Doxorubicin toxicity can be due to imbalance between production of free oxygen radicals and antioxidants, this disturbance is likely to be seen as lipid peroxidation and protein oxidation leading to renal tissue injury [2]. Doxorubicin induced histological changes in renal tissue seen as increased glomerular capillary permeability and tubular atrophy [3]. To our knowledge it is known that Dox increased production of Reactive Oxygen Species (ROS) and mitochondrial DNA damage leads to outer mitochondrial membrane permeability and translocation of cytochrome c to cytoplasm, that activates a cascade of events finally leads to activation of caspase 3 and induction of apoptosis [4,5]. The most well-known oxidative DNA by product is 8-Hydroxy-2'-deoxyguanosine (8-OHdG), which is formed from a hydroxyl radical attack at the C-8 position of a deoxyguanosine residue in DNA. Measurement of levels of 8-OHdG is frequently used in the evaluation of DNA damage by oxidative radicals and considered as good biomarker for risk assessment of various cancers and degenerative diseases [6].

Increasingly, Doxorubicin was reported to induce inflammation, as doxorubicin-killed cells are considered as a chemotactic agent for aggregation neutrophils and monocytes [7]. Vitamin E is an effective antioxidant agent. Alpha-tocopherol is considered the most active form in human. In Diabetic nephropathy using oral high-dose of Vitamin E for 12 weeks improved renal inflammation, and oxidative stress [8]. Vitamin E used in renal ischemia reperfusion leads to amelioration of renal oxidative stress injury [9]. Moreover, in gentamicin

Correspondence to: Dr. Heba S. Shoukry, The Department of Physiology, Faculty of Medicine, Cairo University

toxicity, Vitamin E improved renal injury [10]. From the previous data we sought in our study to find the protective effect of Vitamin E in a model of doxorubicin induced nephrotoxicity and detect the possible underlying mechanisms.

Material and Methods

Animals:

Forty adults albino rats weighing (130-160 gms) were purchased from Animal House Faculty of Medicine, Cairo University June 2016. All animals were kept in the animal care facility of the Laboratory Animal House Unit of Faculty of Medicine, Cairo University and were provided ordinary rat chow and water ad libitum with a 12 hours' light-dark cycles. The experimental protocol and procedures were approved by the Institutional Animal Care and Use Committee of Cairo University. Animals were kept for 10 days prior to the start of study to allow proper acclimatization.

Animal grouping animals were divided into the following groups: Control group, Doxorubicin treated group (Dox), Vitamin E-treated group (Vit. E) Doxorubicin and Vitamin E treated group (Dox + Vit. E).

Medications: Doxorubicin (Adricine, EIMC United Pharmaceuticals) was given in a dose of 2.5mg/kg/day, daily via intraperitoneal injections in both Dox-treated groups, while Vitamin E (Pharmaco Pharmaceuticals) was given in a dose of 250mg/kg/day daily via intramuscular injection, throughout the experimental period (14 days).

Assessment of body weight: Body weight were assessed at the beginning and at the end of the study.

Biochemical analysis:

A- Estimation of urea & creatinine: Urea & creatinine were measured spectrophotometrically following manufacture manual using commercial kits (randox).

B- Estimation of *8hydroxydeoxyguanosine (8-OHdG) in serum of albino rats by ELISA: Blood samples were taken from rats, left for 20 minutes at room temperature to be clotted, then centrifuged at 4000rpm for 10 minutes, the supernatant serum was used for the determination of 8-OHdG by ELISA Kit (8-OHdG, Glory Science Co., Ltd. USA), detection level: 10-300ng/L.

C- Estimation of *8hydroxydeoxyguanosine levels in kidney of albino rats by ELISA: The kidney was rapidly excised then the samples were frozen

in liquid nitrogen and kept at 80°C until analyzed.

On the day of assay, small parts of the samples were homogenized in 500 μ l phosphate buffer, the homogenates were centrifuged for 20 minutes. The supernatant was taken & used for estimation of 8-OHdG by ELISA kit (8-OHdG, Glory Science Co., Ltd. USA).

Histopathological examination:

After scarification, kidneys were removed and cleared of fat. Kidneys were fixed in 10% buffered formalin solution, dehydrated in ascending ethanol and embedded in paraffin. Serial sections of 5 μ m thickness were obtained and stained with hematoxylin and eosin for routine histopathological assessment.

Immunohistochemical examination:

Tissue sections were also processed for immunohistochemical identification. For immune detection, sections were incubated at room temperature for 1h with ready-to-use primary antibodies against caspase 3.

Results

A- Assessment of body weight: Our results displayed significant decrease in body weight ($p < 0.05$) in doxorubicin treated group with mean value of (131.6667gms \pm 10.65) in comparison to normal control group with mean value of (168.3gms \pm 4.71). On the other hand, administration of Doxorubicin in combination with Vitamin E increased the body weight with mean value of (185gms \pm 15) in comparison to Dox treated group and normal untreated group with mean values of (131.6667gms \pm 10.65 and 168.3gms \pm 4.71 respectively). Administration of Vitamin E alone significantly increased the body weight with mean value of (180gms \pm 10) in comparison to normal control group with mean value of (168.3gms \pm 4.71) Fig. (1).

B- Biochemical analysis:

- Assessment of Kidney functions:

In the present study, Dox treated group showed significant elevation ($p < 0.05$) in the levels of urea and creatinine with mean values of (145.3mg/dl \pm 13.3 and 1.63mg/dl \pm 0.07 respectively) in comparison to normal group with mean values of (43.8 mg/dl \pm 2.13 and 0.46mg/dl \pm 0.01 respectively). In combination of Dox with Vitamin E, our results displayed significant improvement of kidney functions as it was shown via significant decrease in the levels of urea and creatinine with mean values of (58.3mg/dl \pm 14.9488 and 0.64mg/dl \pm 0.18 respec-

tively) in comparison to Dox alone treated group, while there was significant elevation in the combination (Dox and Vitamin E) group in comparison to Vitamin E alone treated group with mean values of (43.5mg/dl±1.51 and 0.47mg/dl±0.04 respectively). Fig. (2A,B).

- Assessment of oxidative stress:

Our results displayed significant increase in the oxidative stress in Dox-treated group detected through significant elevation in serum and tissue 8-hydroxydeoxyguanosine with mean value of (810.8ng/ml±25.3 and 908.3ng/L±73.5 respectively) in comparison to normal control with mean values of 620±27.5ng/ml and 616.6ng/L±25.8). On combination of Dox and Vitamin E there was significant improvement of oxidative stress as it was noticed through significant decrease in the level of serum and tissue 8-OH Gd with mean values of (697.5ng/ml±8.8 and 685.8±25.7ng/L respectively) in comparison to Dox treated group but still these values are significantly elevated in comparison to control group with mean value of (620±27.5ng/ml and 616.6ng/L±25.8 respectively) and Vitamin E treated group with mean values of (623.3ng/ml±17.5119 and 513.3ng/L±29.4 respectively). Fig. (3A,B).

C- Histopathological results:

- Haematoxylin and Eosin:

Histological examination of control group showed normal histological renal structure Fig. (4A). On the other hand, examination of Dox group showed enlarged glomeruli almost filling the renal corpuscles obliterating Bowman's space with markedly congested glomerular capillaries. Some glomeruli showed sloughing and focal necrosis. Renal tubules were distorted with obliterated lumina. The tubular epithelium showed areas of shedding and marked cytoplasmic vacuolization. Renal interstitial tissue showed congested capillaries, focal haemorrhages and focal mononuclear inflammatory cellular infiltrates Fig. (4B-D). However, examination of Dox + Vit. E group revealed that renal glomeruli showed mild focal and segmental congestion. Renal tubular epithelium showed mild focal cytoplasmic vacuolization. Renal interstitial tissue showed mild scattered congested capillaries with mild focal mononuclear inflammatory cellular infiltrates Fig. (4E,F).

- Immunohistopathological detection of caspase 3:

Immunohistochemical analysis of Dox group using caspase 3 active antibodies showed positive cytoplasmic staining in glomerular endothelial and

epithelial cells as well as positive staining in degenerated tubular epithelium Fig. (5B,C). On the other hand, immunohistochemical analysis of Dox + Vit E revealed very few positive cytoplasmic granules in glomerular endothelial and epithelial cells and mild positivity in cytoplasm of tubular epithelium Fig. (5D).

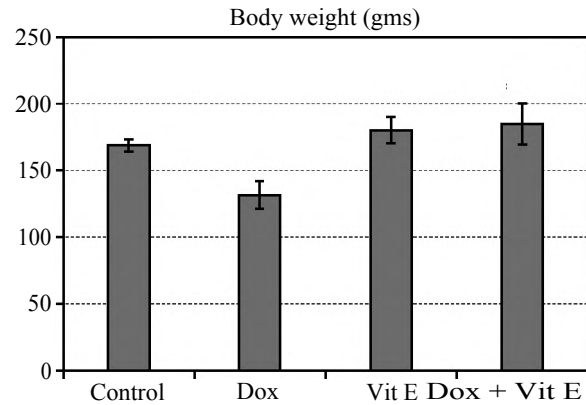


Fig (1): Comparison between the mean values ± SD of body weights in all experimental groups.

* : Significant (p<0.05) in comparison to control.
 @: Significant (p<0.05) in comparison to Dox-treated group.

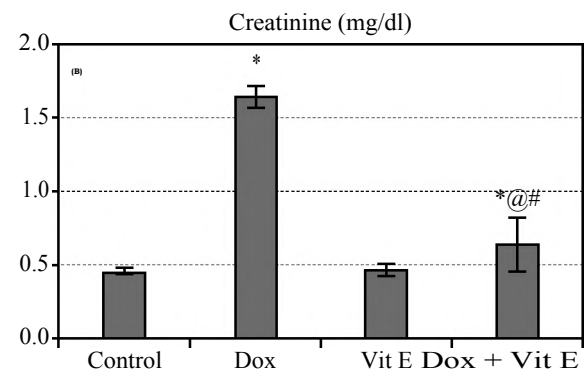
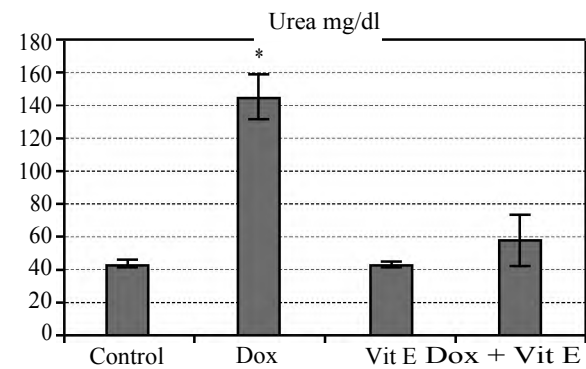


Fig. (2): A- Comparison between the mean values ± SD of urea in all experimental groups. B- Comparison between the mean values ± SD of creatinine in all experimental groups.

* : Significant (p<0.05) in comparison to control.
 @: Significant (p<0.05) in comparison to Dox-treated group.
 #: Significant (p<0.05) in comparison to Vit. E-treated group.

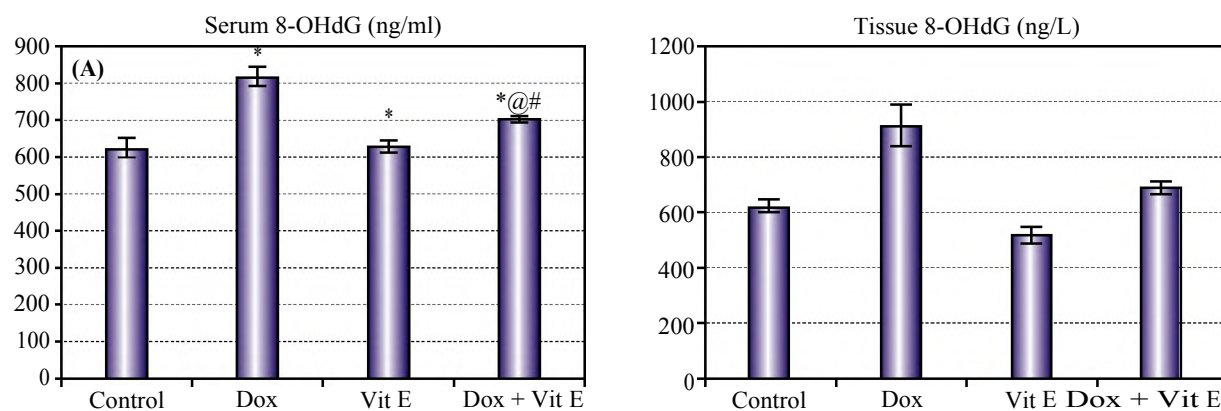


Fig. (3): A- Comparison between the mean values \pm SD of serum level of 8-OHdG in all experimental groups. B- Comparison between the mean values \pm SD of tissue level of 8-OHdG in all experimental groups.

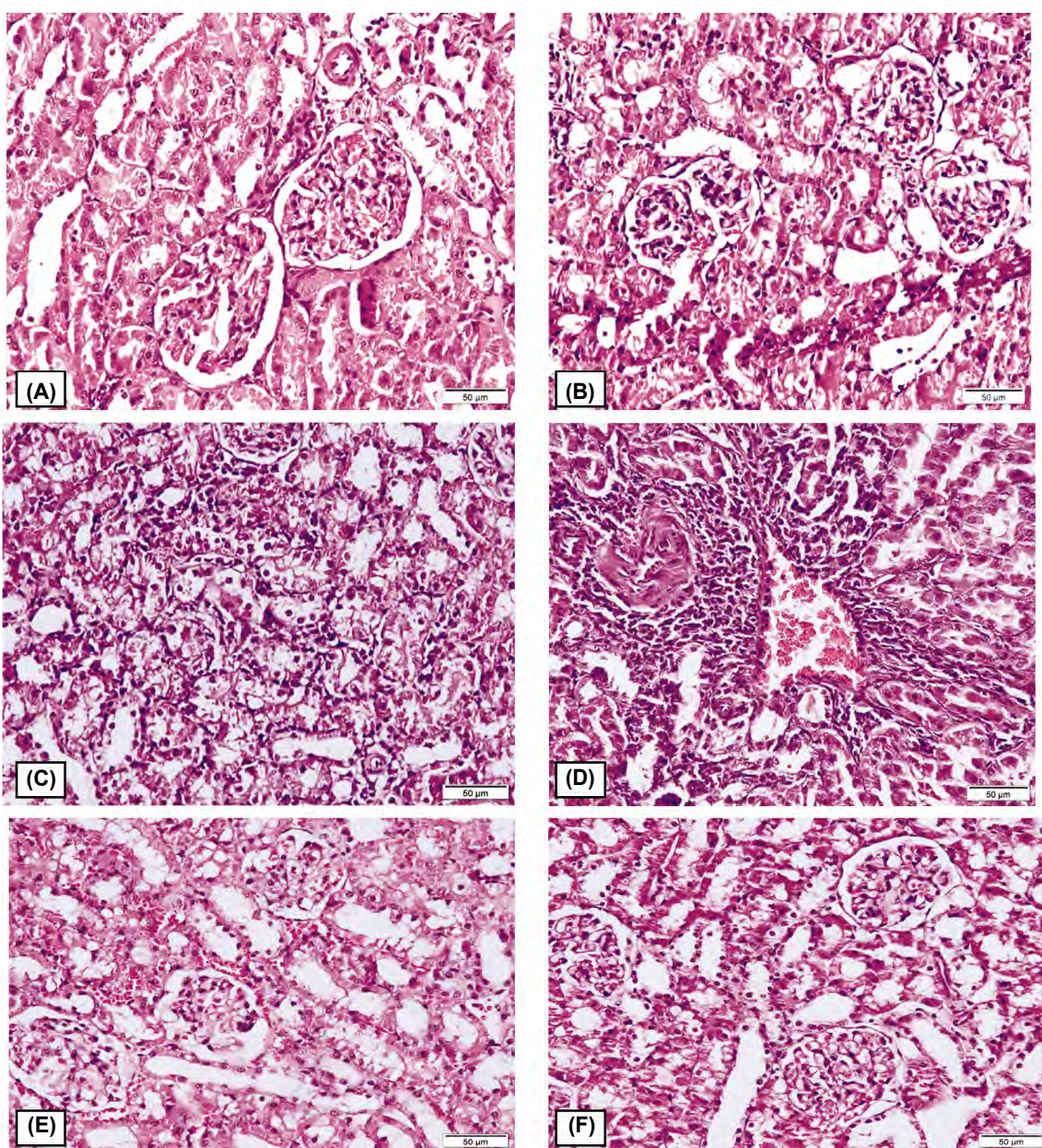


Fig. (4): Photomicrograph plate of H & E results in all studied groups: A- Control group (H & E X200). B,C,D: Dox group (H & E X200). E,F: Dox + Vit E group (H & E X200).

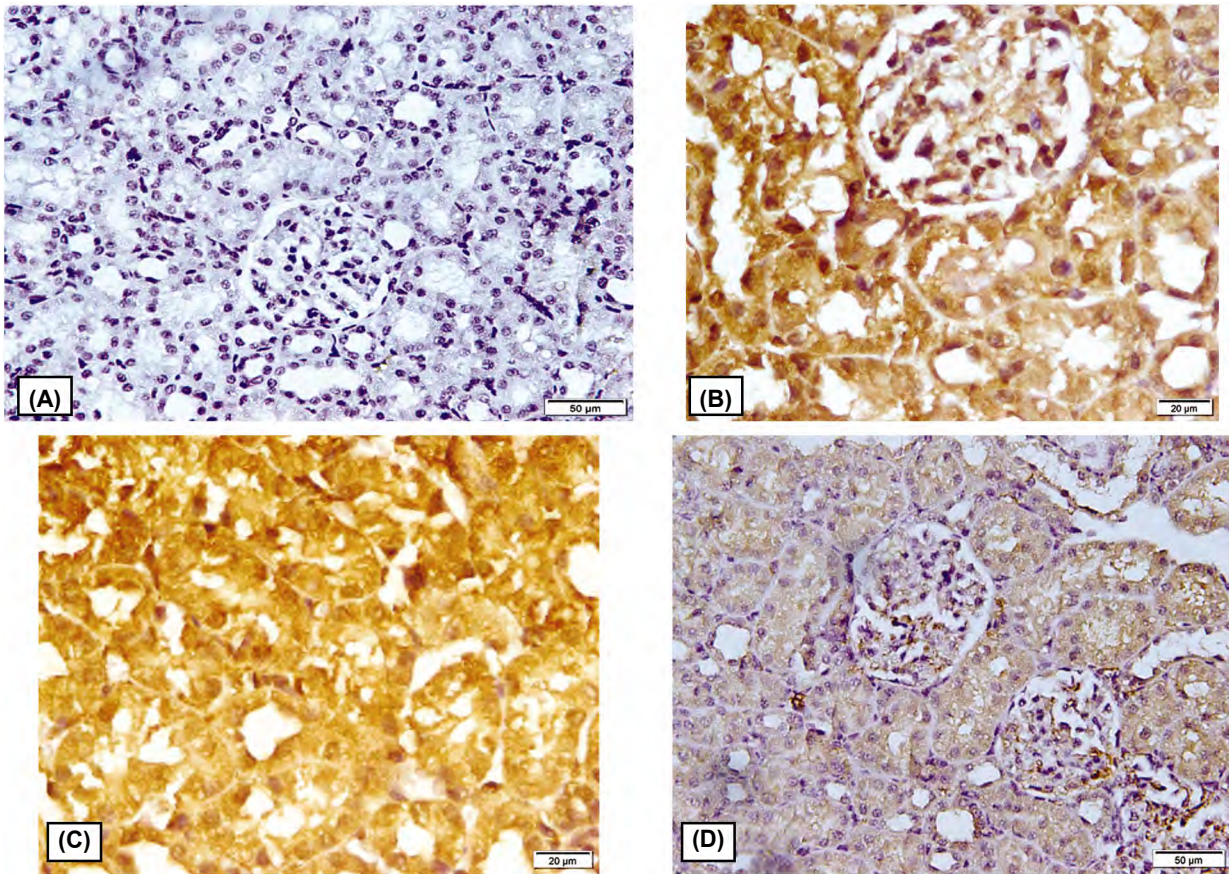


Fig. (5): Photomicrograph plate of immunohistopathological results of caspase 3 in all studied groups: A- Control group X200. B,C- Dox group X400. D- Dox + Vit E group X200.

Discussion

Doxorubicin is used nowadays in treatment of many cancers, however its side effects limited its usage. It well Known that Doxorubicin has a toxic effect on the kidney [11]. This was evident in our study via increased serum levels of urea and creatinine. Our results are in agree with [12] as they mentioned elevated kidney function tests on administration of Dox injected intraperitoneal. The exact mechanism of nephrotoxicity is not well fully understood. Several studies attributed the Nephrotoxic action of Doxorubicin was due to drug-induced free radical generation [13] and this was evident in our study via the significant increase in the serum and renal tissue levels 8-OHGd levels which is a sign of increased DNA damage resulted from oxidative damage. Our results are in accordance to [11] study that showed significant increase in cardiac mitochondrial 8-OHGd levels on Doxorubicin administration. Also our histological findings showed deterioration of the renal tissue on administration of Dox as mentioned before by [14] as they observed glomerular sclerosis seen 10 days after Dox injection in rats. Also, it was shown that there was thickening of capillary basement mem-

brane in the Dox group. Urinary spaces and capillaries were dilated, and the flat epithelial cells of the parietal layer of Bowman's membrane could be discerned mostly as cuboidal or round in shape. In the proximal tubules, vacuolization was observed in the endothelial cell cytoplasm, for the most part, degenerated, and microvillus is lost. Our histological findings found also vacuoles in the cytoplasm between the nuclei and cellular membranes of the tubules. We seek in our study to find out the another mechanism by which Dox can induce nephrotoxicity, so we immunohistological measured the level of caspase 3 expression level which is one of the key regulators of apoptosis and can play a role in the production of reactive oxygen species which leads to Dox induced nephrotoxicity and to find out if Dox has a direct effect on caspase 3 and increased its expression. Our immunohistological results found increased expression of caspase 3 in Dox group. Our findings agreed with [12] as they attributed Dox induced nephrotoxicity is via renal tissue inflammation and apoptosis as they observed increased expression levels of caspase 3 and inflammatory proteins in Dox treated group. Vitamin E is a well known antioxidant drug as it was noticed in our study causing significant decrease the serum

and tissue 8-hydroxyGuanosine in Vitamin E treated group in comparison to normal control group and the significant decrease when combined with Dox in comparison to Dox treated group. To our knowledge Vitamin E is strong antioxidant with low toxicity, rare side-effects, and low cost so it is considered as a new therapy against acute kidney injury [15]. In our study we seek to find out if Vit E has antiapoptotic protective role if it is combined with Dox, interestingly we observed decreased immunohistological expression of caspase 3 on administration of Vitamin E. Our observation was agreed by [16] as they found that Vit E has antiapoptotic effect against formaldehyde induced nephrotoxicity. Moreover, [17] observed decreased caspase 3 activity when Vit. E used for protection against renal ischemia reperfusion injury.

In Conclusion:

Vitamin E has a protective role in doxorubicin induced nephrotoxicity and the mechanism of protection can be via the antioxidant effect of Vit E or through its antiapoptotic effect.

References

- 1- SINGAL P.K., DEALLY C.M.R. and WEINBERG L.E.: Subcellular effects of: Adriamycin in the heart a concise review," *Journal of Molecular and Cellular Cardiology*, Vol. 19, No. 8, pp. 817-28, 1987.
- 2- KARAMAN A., FADILLIOGLU E., TURKMEN E., TAS E., and YILMAZ Z.: Protective effects of leflunomide against ischemia-reperfusion injury of the rat liver," *Pediatric Surgery International*, Vol. 22, No. 5, pp. 428-34, 2006.
- 3- WAPSTRA F.H., VAN GOOR H., De JONG P.E., NAVIS G., and ZEEUW D. De: Dose of doxorubicin determines severity of renal damage and responsiveness to ACE-inhibition in experimental nephrosis," *Journal of Pharmacological and Toxicological Methods*, Vol. 41, No. 2-3, pp. 69-73, 1999.
- 4- MONTAIGNE D., MARECHAL X., PREAU S., BACCOUCH R., MODINE T., FAYAD G., LANCEL S. and NEVIERE R.: Doxorubicin induces mitochondrial permeability transition and contractile dysfunction in the human myocardium. *Mitochondrion*, 11: 22-6, 2011.
- 5- SUSIN S.A., LORENZO H.K., ZAMZAMI N., MARZO I., SNOW B.E., BROTHERS G.M., MANGION J., JACOTOT E., COSTANTINI P., LOEFFLER M., LAROCLETTE N., GOODLETT D.R., AEBERSOLD R., SIDEROVSKI D.P., PENNINGER J.M. and KROEMER G.: Molecular characterization of mitochondrial apoptosis-inducing factor. *Nature*, 397: 441-6, 1999.
- 6- VIEIRA G., LOSSIE A., Jr. D., RADCLIFFE J., and GARNER J.: "Preventing, treating, and predicting barbering: A fundamental role for biomarkers of oxidative stress in a mouse model of Trichotillomania" *PLoS One*, 12 (4): e0175222, 2017.
- 7- BALKWILL F.: Tumour necrosis factor and cancer *Nat. Rev. Cancer*, 9 (5): 361-71, 2009.
- 8- KHATAMI P.G., SOLEIMANI A., SHARIFI N., AGHADAVOD E. and ASEMI Z.: The effects of high-dose Vitamin E supplementation on biomarkers of kidney injury, inflammation, and oxidative stress in patients with diabetic nephropathy: A randomized, double-blind, placebo-controlled trial *J. Clin. Lipidol.* Jul.-Aug., 10 (4): 922-9, 2016.
- 9- ZHANG W., WANG Y.L., WANG H.J., MIAO Z.H. and XIA X.H.: The effect of vitamin E on renal ischemia/reperfusion injury in young and aged rats. *Zhongguo Ying Yong Sheng Li Xue Za Zhi.* May, 26 (2): 159-63, 2010.
- 10- ABDEL-NAIM A.B., ABDEL-WAHAB M.H. and ATTIA F.F.: Protective effects of vitamin e and probucol against gentamicin-induced nephrotoxicity in rats. *Pharmacol. Res.* Aug., 40 (2): 183-7, 1999.
- 11- SERRANO J., PALMEIRA C.M., KUEHL D.W. and WALLACE K.B.: Cardioselective and cumulative oxidation of mitochondrial DNA following subchronic doxorubicin administration. *Biochim. Biophys. Acta.* Apr. 21; 1411 (1): 201-5, 1999.
- 12- SU Z., YE J., QIN Z. and DING X.: Protective effects of madecassoside against Doxorubicin induced nephrotoxicity in vivo and in vitro *Scientific Reports*, 5: 18314, 2015.
- 13- DEMAN A., CEYSSENS B., PAUWELS M., J. ZHANG, HOUTE K.V., VERBEELEN D. and BRANDEN C.V.: "Altered antioxidant defence in a mouse adriamycin model of glomerulosclerosis," *Nephrology Dialysis Transplantation*, Vol. 16, No. 1, pp. 147-50, 2001.
- 14- YAGMURCA M., ERDOGAN H., IRAZ M., SONGUR A., UCAR M. and FADILLIOGLU E.: Caffeic acid phenethyl ester as a protective agent against doxorubicin nephrotoxicity in rats. *Clinica Chimica Acta.*, 348 (1-2): 27-34, 2004.
- 15- LIU P., FENG Y., WANG Y., ZHOU Y. and ZHAO L.: Protective effect of vitamin E against acute kidney injury. *Biomed. Mater. Eng.*, 26 (Suppl 1): S2133-44, 2015.
- 16- BAKAR E., ULUCAM E. and CERKEZKAYABEKIR A.: Protective effects of proanthocyanidin and Vitamin E against toxic effects of formaldehyde in kidney tissue. *Biotechnic & Histochemistry*, 90: 1, 2015.
- 17- KOGA H., HAGIWARA S., MEI H., HIRAOKA N., KUSAKA J., GOTO K., KASHIMA K. and NOGUCHI T.: The vitamin E derivative, ESeroS-GS, attenuates renal ischemia-reperfusion injury in rats. *J. Surg. Res.* Jul., 176 (1): 220-5, 2012.

فيتامين "هـ" يعمل على تحسين التسمم الكلوى الناتج عن عقار الدوكسوروبيسين: الآليات المختلفة

يعتبر عقار الدوكسوروبيسين من أكثر الأدوية إستخداما فى علاج الأورام السرطانية. وجد أن إستخدام الدوكسوروبيسين له العديد من الأضرار على معظم أجهزة الجسم. لذلك قمنا فى هذا البحث بدراسة تأثير عقار الدوكسوروبيسين على الكليتين ومعرفة الطريقة التى يؤدى بها هذا العقار إلى هذا التأثير. من أجل التغلب على الأضرار الناتجة من إستخدام هذا العقار قمنا بإستخدام واحدا من أكثر الفيتامينات شيوعا وهو فيتامين "هـ" ودراسة هل بإمكان هذا الفيتامين إيقاف الضرر الذى يسببه عقار الدوكسوروبيسين على الكليتين. توصلنا فى هذه الدراسة إلى أن إستخدام عقار الدوكسوروبيسين يؤدى إلى قصور فى وظائف الكلى ويمكن التغلب على هذا الأضرار بإستخدام فيتامين "هـ".