

MR Arthrography with Radial Planes in Diagnosis of Acetabular Labral Tear and Articular Cartilage Lesion of the Hip

MUHAMMAD AZMY EL-KAMEL, M.Sc.*; OSAMA H. ABDEL LATIF, M.D.*; HATEM G. SAID, M.D.** and EHAB M. MOHAMMAD, M.D.*

The Departments of Radio-Diagnosis* and Orthopedics**, Faculty of Medicine, Assiut University, Egypt

Abstract

Background: The target of this study was to compare between MR arthrography with parallel planes and MR arthrography with radial planes in the diagnosis of acetabular labral tear and chondral lesion of the hip joint.

Patients and Methods: 28 hips of 27 patients with suspected labral tear and/or FAI were enrolled in this prospective study. All hips were examined by direct MR arthrography. The acetabular labrum and articular cartilage were assessed at parallel planes (axial and coronal) and compared to radial planes.

Results: Parallel planes detected 14 labral tear and 13 chondral lesion of the 28 examined hips while radial planes detected 22 labral tear and 22 chondral lesion.

Conclusion: Radial planes have higher sensitivity than parallel planes in diagnosis of acetabular labral tear and chondral lesion of the hip.

Key Words: Radial MRI – Arthrography – FAI – Hip joint – Labrum.

Introduction

DIRECT MR arthrography is the method of choice in diagnosing lesions of the acetabular labrum and articular cartilage of the hip [1]. Due to complex three-dimensional orientation of the acetabular opening as it looks downwards, laterally and anteriorly, MR arthrography with parallel planes will display anterior, superior and posterior labrum in true cut section but anterosuperior, posterosuperior and posteroinferior labrum will be distorted due to volume average artifact [2].

MR arthrography with radial planes has been advised for better detection of lesions of the labrum as it reduces volume average artifact and the labrum

will be displayed as triangular shaped structure in all images along the whole acetabulum [2,3].

Patients and Methods

28 hips of 27 patients were enrolled in this prospective study in radio-diagnosis department, Assiut university hospital between May 14, 2011, and March 7, 2016. There were 21 male and 6 female (age range, 17 to 66 years; mean, 32.5 years). There were 16 right and 12 left hips. Patients referred from orthopedic department, Assiut university hospital. All had hip pain with one or more of the following criteria:

- 1- Hip pain (groin >trochanter >buttocks) exacerbated often by sitting.
- 2- Hip pain associated with hip locking, catching, instability, giving way, and/or stiffness.
- 3- Hip pain associated with positive impingement test (pain increase in flexion, adduction and internal rotation).
- 4- Hip pain with positive plain X-ray for FAI (Proximal femur: Pistol grip deformity and/or alpha angle >52 degrees; Acetabulum: Coxa profunda, C-E angle >39 degrees, Tonnis roof angle <5 degrees, crossover sign, posterior wall sign and/or ischial spine sign) [4]. (Figs. 1-4). Informed consent was obtained for all cases of the study before it began. The privacy rights of human subjects were always observed.

Technique:

A- Hip injection (Arthrography): (No specific patient preparation needed).

Abbreviations:

MRI = Magnetic resonance imaging.
MR = Arthrography magnetic resonance arthrography.
FAI = Femoroacetabular impingement.
C-E angle = Centre edge angle.

Correspondence to: Dr. Muhammad Azmy El-Kamel,
The Department of Radio-Diagnosis, Faculty of Medicine,
Assiut University, Egypt

Direct injection (arthrography) was performed to all patients guided by fluoroscopy. The patients were positioned supine on the fluoroscopy table with both feet internally rotated. A 22g spinal needle was introduced anteriorly directly to the hip joint. A 5ml of urographin was injected to prove intra-articular needle position. Then, a gadopentetate dimeglumine (0.2mmol/L) was injected. To obtain this dilution, 0.1mL of gadopentetate dimeglumine was diluted in 20mL of normal saline solution. Lidocaine was also injected at this time.

B- MRI examination protocol:

MRI examination was done within 30 minutes of injection. MRI scan using Gyroscan NT 1.5 Tesla MRI machine. The patients were placed supine and the both feet were fixed with 20-degree internal rotation to decrease motion during examination and to provoke proper position of the pelvis. A flexible wrap-around surface coil was used. The standardized MR imaging protocol included:

(Figs 5-8):

- Radial T1 weighted turbo spin echo sequence with spectral fat saturation (500/6.5 [TR msec/TE time msec], 4-mm section thickness, 0.4-mm intersection gap and field of view 20cm) orthogonal to acetabular rim of the examined hip with center of rotation is the center of the acetabular opening with angle of rotation 22.5 degree.
- Parallel coronal (parallel to axis of the proximal femur) of the examined hip T1 weighted turbo spin echo sequence with spectral fat saturation.
- Parallel axial (parallel to axis of the proximal femur) of the examined hip T1 weighted turbo spin echo sequence with spectral fat saturation.

Images interpretation:

Acetabular labrum was assessed using Czerny et al., [5] classification and articular cartilage was

assessed using Beck et al., [6] classification at parallel planes (coronal oblique and axial oblique planes) and results compared with the radial planes. (Figs. 5-8).

Results

There were 14 hips had labral tears when using MR arthrography with parallel planes alone. And 22 hips had labral tears when using MR arthrography with radial planes (Table 1). The radial planes demonstrated 2 hips stage I and 6 hips stage III labral tears that were not seen on the parallel planes. There was not any labral tear found in parallel planes and not found on the radial planes.

Arthroscopic correlation on 15 hips demonstrated labral tears in 12 hips. Parallel planes diagnosed labral tears in 7 hips denoting 58.33% sensitivity while radial planes diagnosed 11 of the 12 hips denoting 91.67% sensitivity. (Fig. 9).

Using MR arthrography with parallel planes alone, chondral lesions were found in 13 of 28 hips while MR arthrography with radial planes alone, chondral lesions were found in 22 of 28 hips (Table 2). The radial planes demonstrated 2 hips pitting malacia and 7 hips debonding that were not visible on the parallel planes. The parallel planes did not show any chondral lesion that was not identified on the radial planes.

Arthroscopic correlation on 15 hips demonstrated chondral lesions in 9 hips. Parallel planes demonstrated chondral lesions in 5 hips denoting 55.6% sensitivity, while radial planes demonstrated chondral lesions in 7 of the 9 hips denoting 77.8% sensitivity. (Fig. 10).

Table (1): Comparison between MR arthrography with parallel planes and MR arthrography with radial planes in diagnosis and staging of acetabular labral lesions.

	MR arthrography Radial: Normal	MR arthrography Radial: Stage I	MR arthrography Radial: Stage II	MR arthrography Radial: Stage III	Total
MR arthrography parallel: Normal	6 (100%)	2 (66.6%)	6 (42.8%)	0 (0.0%)	14 (50%)
MR arthrography parallel: Stage I	0 (0.0%)	1 (33.3%)	1 (0.07%)	0 (0.0%)	2 (7.1%)
MR arthrography parallel: Stage II	0 (0.0%)	0 (0.0%)	7 (50%)	2 (40%)	9 (32.1%)
MR arthrography parallel: Stage III	0 (0.0%)	0 (0.0%)	0 (0.0%)	3 (60%)	3 (10.7%)
Total	6 (100%)	3 (100%)	14 (100%)	5 (100%)	28 (100%)

Table (2): Comparison between MR arthrography with parallel planes and MR arthrography with radial planes in diagnosing and staging of chondral lesion.

	MRA Radial: Normal	MRA Radial: Pitting malacia	MRA Radial: Debonding	MRA Radial: Cleavage	MRA Radial: Defect	Total
MRA parallel: Normal	6 (100%)	2 (66.7%)	7 (46.7%)	0 (0.0%)	0 (0.0%)	15 (53.6%)
MRA parallel: Pitting malacia	0 (0.0%)	1 (33.3%)	0 (0.0%)	0 (0.0%)	0 (0.0%)	1 (3.6%)
MRA parallel: Debonding	0 (0.0%)	0 (0.0%)	8 (53.3%)	1 (33.3%)	0 (0.0%)	9 (32.1%)
MRA parallel: Cleavage	0 (0.0%)	0 (0.0%)	0 (0.0%)	2 (66.7%)	0 (0.0%)	2 (7.1%)
MRA parallel: Defect	0 (0.0%)	0 (0.0%)	0 (0.0%)	0 (0.0%)	1 (100%)	1 (3.6%)
Total	6 (100%)	3 (100%)	15 (100%)	3 (100%)	1 (100%)	28 (100%)

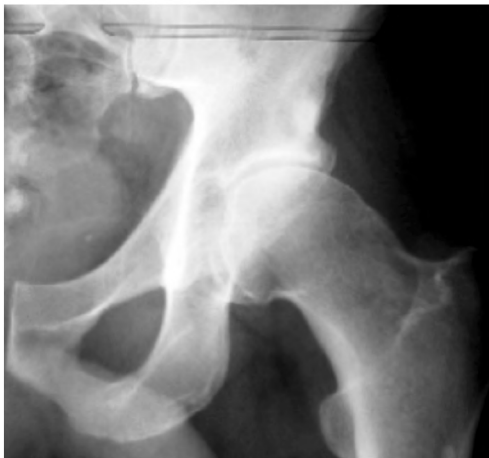

Fig. (1): Plain radiography AP view of the left hip shows pistol grip deformity of proximal femur in patient with cam type (FAI).

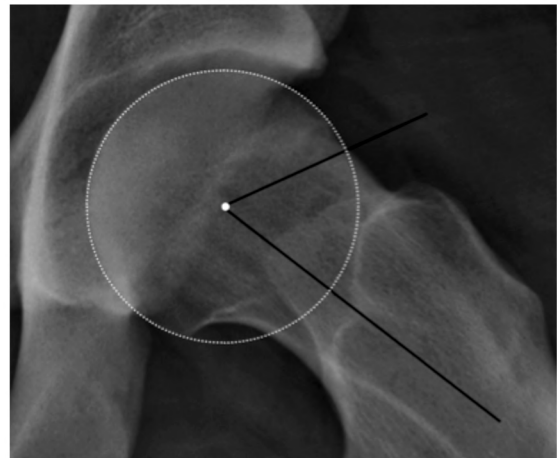

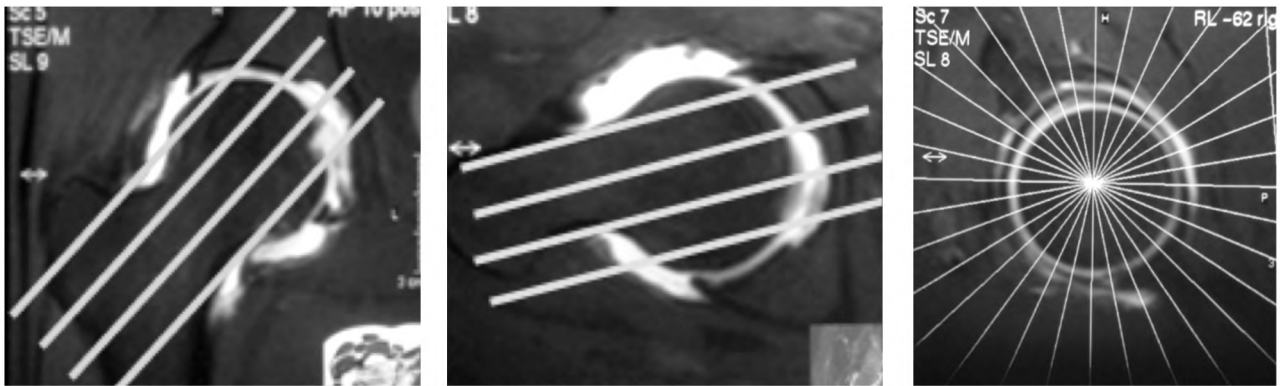
Fig. (2): Plain radiography frog view of the left hip shows aspherical head in patient with cam type (FAI) with alpha angle=62 degree (normal <52 degree).

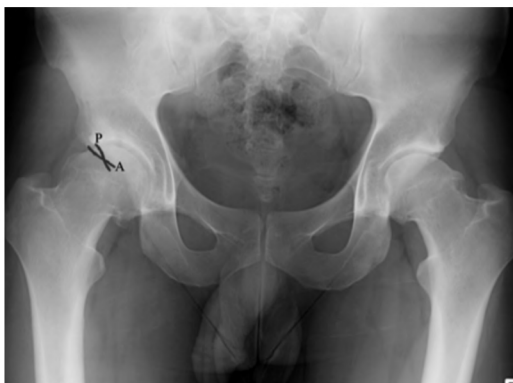

Fig. (3): Plain X-ray AP of the pelvis shows the cross over sign in patient with pincer type (FAI).

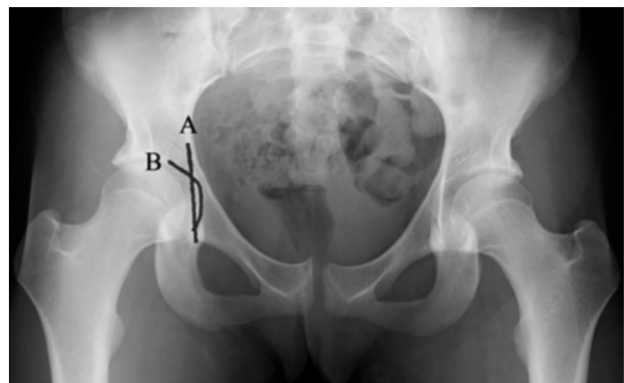

Fig. (4): Plain X-ray AP view of the pelvis shows coxa profunda where the acetabular fossa (B) is overlying the ilio-ischial line (A).



(A)

(B)

(C)

Fig. (5): (A,B) Represent the planning for parallel axial and coronal cuts respectively. (C) Represent the planning for radial cuts.

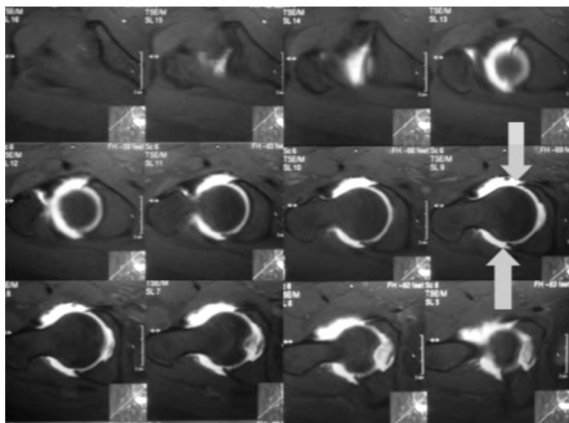


Fig. (6): MR arthrography of the right hip joint with parallel axial planes depicts only anterior and posterior labrum in normal triangular shape (arrow).

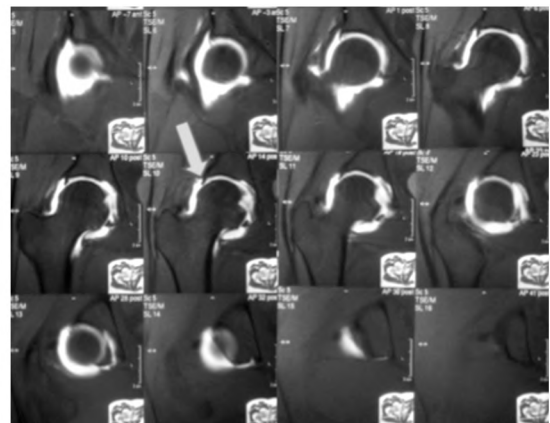


Fig. (7): MR arthrography with parallel coronal planes of the same patient depicts only superior labrum in triangular shape (arrow)

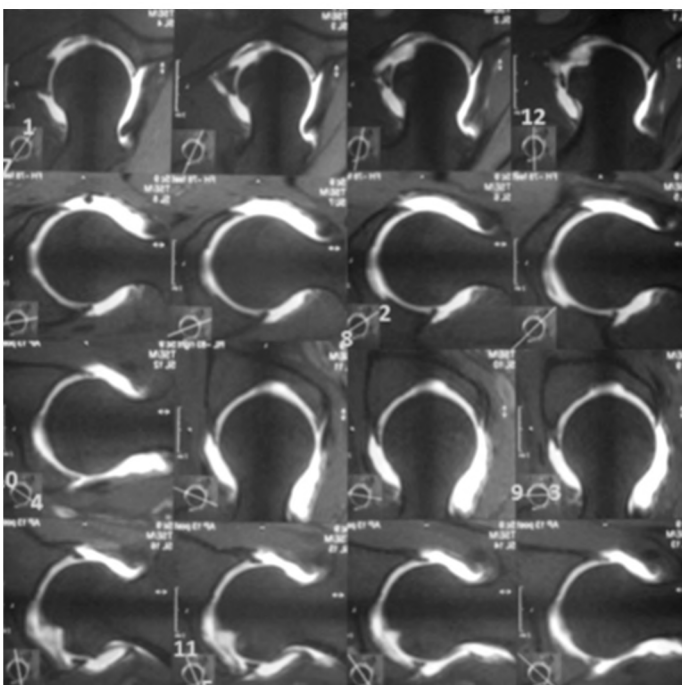


Fig. (8): MR arthrography with radial planes of the same patient shows normal triangular shaped acetabular labrum and articular cartilage around the entire acetabulum

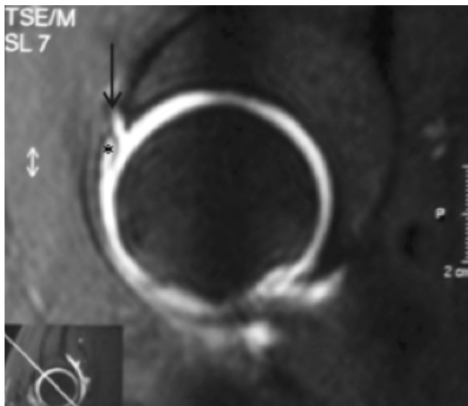


Fig. (9A): MR arthrography T1 SPIR radial plane images anterosuperiorly at 2 o'clock position shows stage III labral tear (arrow) with preserved perilabral recess (*).

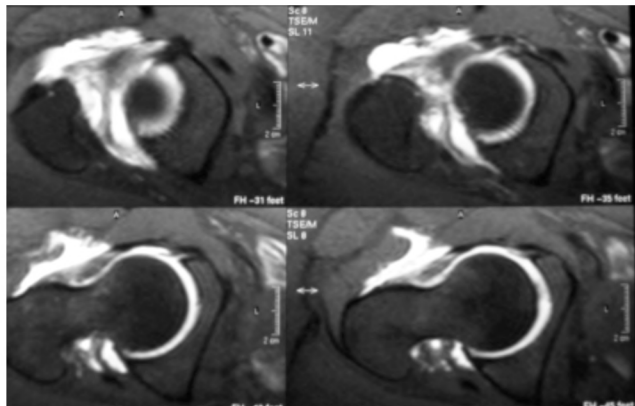


Fig. (9B): MR arthrography parallel axial planes superior cuts of the same patient show normal labrum.

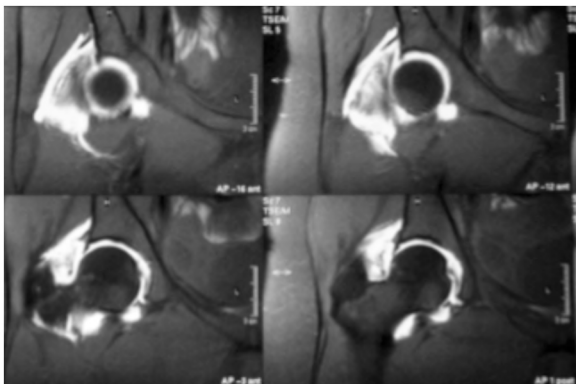


Fig. (9C): MR arthrography parallel coronal planes anterior cuts of the same patient show normal labrum

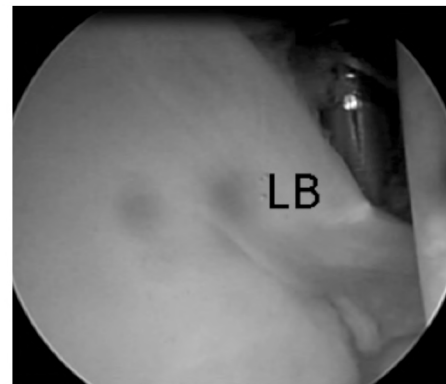


Fig. (9D): Arthroscopic view of the same patient probing of the labrum (LB) revealed completely avulsed labrum from its acetabular attachment.

Fig. (9): Labral tear stage III diagnosed at radial planes (A) and missed at parallel planes (B&C) and tear was confirmed at arthroscopy (D).

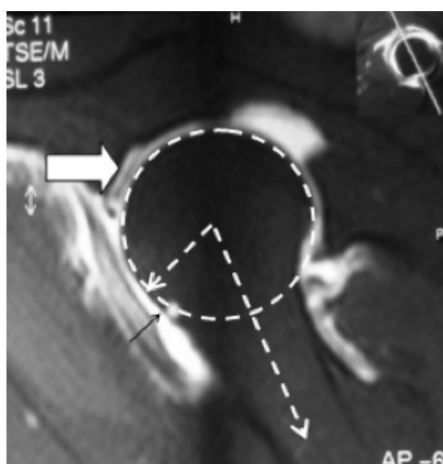


Fig. (10A): MR arthrography T1 fat suppression radial image anterosuperiorly at 1 o'clock position shows cam deformity (alpha angle=60), acetabular cartilage cleavage (white arrow) and noted small cyst herniation pits (small black arrow).

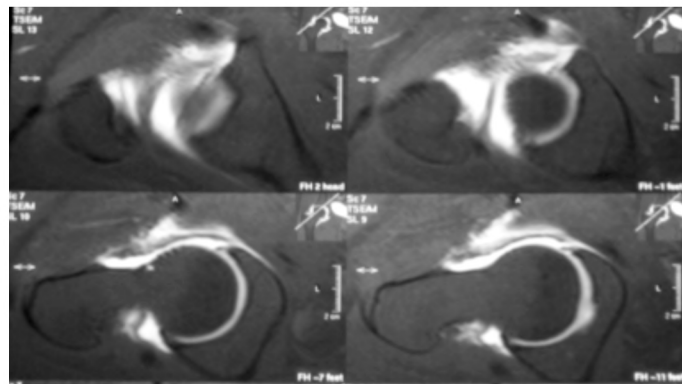


Fig. (10B): MR arthrography parallel axial planes superior cuts of the same patient show normal articular cartilage.

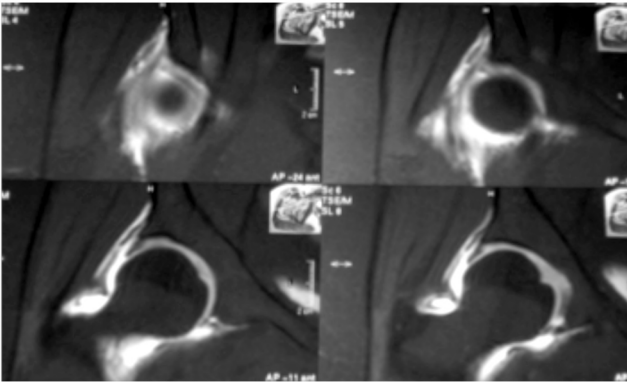


Fig. (10C): MR arthrography parallel coronal planes anterior cuts of the same patient show normal articular cartilage.

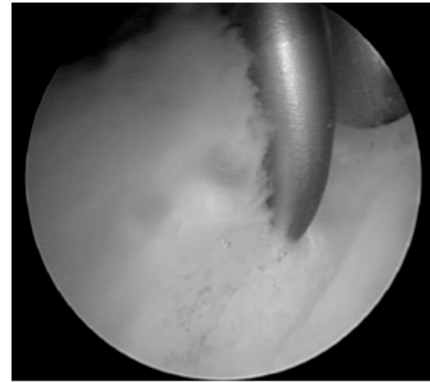


Fig. (10D): Arthroscopic view central compartment of the same patient shows cartilage cleavage denoted by probing of the cartilage.

Fig. (10): Chondral lesion (cleavage) diagnosed at radial planes (A) and missed at parallel planes (B&C) and was confirmed at arthroscopy (D).

Discussion

Holder et al., [7] used MR arthrography with parallel coronal planes only and found 54%-67% sensitivity, 25%-68% specificity and 53%-58% accuracy for labral tear. Leunig et al., [8] used MR arthrography with parallel coronal, parallel axial and parallel sagittal planes and found 63% sensitivity for labral tear. Czerny et al., [9] used MR arthrography with parallel coronal and parallel sagittal planes and reported 90% sensitivity and 91% accuracy for labral tear.

Plötz et al., [2] compared between parallel and radial planes in 20 examined hips obtained from cadaver retrospectively and they found an improved detection of labral tear by using radial planes over parallel ones. The sensitivity, specificity and accuracy of parallel planes were 60%, 100%, and 70% and of radial planes were 80%, 100%, and 85%, respectively.

While Luke et al., [10] found that radial planes did not show improved sensitivity over parallel planes in diagnosis of labral tear and concluded that there is no need for the radial planes in diagnosis of lesions of the labrum.

In our study parallel planes detected labral tears in 14 of 28 hips, while radial planes detected labral tears in 22 hips. The radial planes demonstrated tears in 8 hips that were not detected on parallel planes. There was not any labral tear found in parallel planes and not found on the radial planes. Arthroscopic correlation on 15 hips demonstrated labral tears in 12 hips. The MR arthrography with parallel planes demonstrated labral tears in 7 hips (58.33% sensitivity), while MR arthrography with

radial planes demonstrated labral tears in 11 of the 12 hips (91.67% sensitivity).

In our study there was higher sensitivity, specificity and overall accuracy regarding the lesions detected in radial imaging, this could be explained on basis of, higher number of examined hips, the combination of radial and parallel images with arthroscopic examination as well as the relative higher resolution and image quality, development of recent fat saturation technique as well as established technique of MR arthrography.

To our knowledge, no previous study compared MR arthrography with parallel oblique planes (axial and coronal) to radial planes in diagnosis of chondral lesion of the hip.

In our study parallel planes detected chondral lesions in 13 of 28 hips, while radial planes detected chondral lesions in 22 hips. The radial planes demonstrated 9 hips with chondral lesions that were not visible on parallel planes. The parallel planes did not show any chondral lesion that was not identified on the radial planes. Arthroscopic correlation on 15 hips demonstrated chondral lesions in 9 hips. The MR arthrography with parallel planes demonstrated chondral lesions in 5 hips (55.6% sensitivity), while with radial planes demonstrated chondral lesions in 7 of the 9 hips (77.8% sensitivity).

Conclusion:

MR arthrography with radial planes is more sensitive in the diagnosis of acetabular labral tear and articular cartilage lesion than parallel planes and should be considered in the MR arthrography examination of the hip joint.

References

- 1- BERNARD MENGIARDI CHRISTIAN W.A. and PFIRRMANN JUERG HODLER: MR imaging appearance of common causes, Eur. Radiol., Hip. pain in adults, 17: 1746-1762 DOI 10.1007/s00330-006-0491-z, 2007.
- 2- G.M.J. PLÖTZ, J. BROSSMANN, M. VON KNOCH, C. MUHLE, M. HELLER and J. HASSENPFUG: Magnetic resonance arthrography of the acetabular labrum: Value of radial reconstructions. Arch. Orthop. Trauma. Surg., 121: 450-457, 2001.
- 3- KUBO T., HORII M., HARADA Y., NOGUCHI Y., YUTANI Y., OHASHI H., HACHIYA H., MIYAOKA H., NARUSE S. and HIRASAWA Y.: Radial sequence magnetic resonance imaging in evaluation of acetabular labrum. J. Orthop. Sci., 4: 328-332, 1999.
- 4- John C. Clohisy, John C. Carlisle, Paul E. Beaulé, Young-Jo Kim, Robert T. Trousdale, Rafael J. Sierra, Michael Leunig, Perry L. Schoeneker, and Michael B. Millis: A Systematic Approach to the Plain Radiographic Evaluation of the Young Adult Hip, J. Bone Joint. Surg. Am. Nov., 1, 90 (Suppl 4): 47-66, 2008.
- 5- CZERNY C., HOFMANN S., URBAN M., TSCHAUNER C., NEUHOLD A., PRETTERKLIEBER M., RECHT M. and KRAMER J.: MR arthrography of the adult acetabular capsular-labral complex: Correlation with surgery and anatomy. AJR, 173: 345-349, 1999.
- 6- BECK M., LEUNIG M., PARVIZI J., BOUTIER V., WYSS .D and GANZ R.: Anterior femoroacetabular impingement: Part II. Midterm results of surgical treatment, Clin. Orthop. Relat. Res., 418: 67-73, 2004.
- 7- HODLER J., YU JS., GODDWIN D., HAGHIGHI P., TRUDELL D. and RESNICK D.: MR arthrography of the hip: Improved imaging of the acetabular labrum with histologic correlation in cadavers. AJR, 165: 887-891, 1995.
- 8- LEUNIG M., WERLEN S., UNGERSBÖCK A., ITO K. and GANZ R.: Evaluation of the acetabular labrum by MR arthrography. J. Bone. Joint. Surg. Br., 79: 230-234, 1997.
- 9- CZERNY C., HOFMANN S., NEUHOLD A., et al.: Lesions of the acetabular labrum: accuracy of MR imaging and MR arthrography in detection and staging, Radiology, 200: 225-30, 1996.
- 10- LUKE S.Y., WILLIAM E.P. and ARA K.: Evaluation of radial-sequence imaging in detecting acetabular labral tears at hip MR arthrography, Skeletal Radiol., 36: 1029-1033 DOI 10.1007/s00256-007-0363-x, 2007.

المقاطع المشعة للرنين المغناطيسي باستخدام وسيط التباين لمفصل الفخذ وتشخيص تمزق الشفة الحقية واعتلالات الغضروف

يهدف هذا البحث الى المقارنة بين فحص الرنين المغناطيسي باستخدام وسيط التباين لمفصل الفخذ عن طريق المقاطع العادية المتوازية ومقارنتها بالمقاطع المشعة في تشخيص تمزق الشفة الحقية واعتلالات الغضروف لمفصل الفخذ حيث تم فحص ٢٨ مفصل حوض يشته في اصابتهم بتمزق الشفة الحقية او يعانون من انحشار في مفصل الفخذ عن طريق الحقن المباشر للصبغة داخل المفصل ثم الفحص باستخدام الرنين المغناطيسي وتم تقييم الشفة الحقية وغضروف المفصل في المقاطع المتوازية ومقارنتها بالمقاطع المشعة ووجدنا ان المقاطع المشعة ذات دقة حساسية اعلى من المقاطع المتوازية في تشخيص تمزق الشفة الحقية واعتلالات الغضروف لمفصل الفخذ.