

Simple-type Caroli disease with diffuse involvement of the liver: A case report

Mohammad Elmoghazy, Khaled Farid, Fathiya El-Raey, Nasser Mousa



Summary

Caroli's disease is a congenital disorder characterized by a segmental and saccular dilatation of intrahepatic biliary ducts. The diagnosis of Caroli's disease depends on demonstrating that the cystic lesions are in continuity with the biliary tree which can be shown by ultrasonography, computerized tomography, endoscopic retrograde cholangiopancreatography or magnetic resonance cholangiopancreatography which is considered as the gold standard diagnostic tool. Treatment of Caroli's disease relies on the location of the biliary abnormalities, while the localized forms can be treated with surgery; liver transplantation is the only effective modality for diffuse forms as in our current case which reported in our Gastroenterology and Hepatology department at Damietta cardiology and gastroenterology center for 27 years old male presented with right upper quadrant pain, jaundice with repeated vomiting.

Keywords: Caroli's disease, biliary ducts and magnetic resonance cholangiopancreatography

Medical Journal of Viral Hepatitis

(MJVH) 2018; 3 (1) - pp. 1-4

Received: 3/5/2018

Revised: 12/9/2018

Accepted: 2/10/2018

Published Online: 20/11/2018

(Mohammad Elmoghazy) Gastroenterology and Hepatology dept., Damietta Cardiology and Gastroenterology center, Egypt

(Khaled Farid & Nasser Mousa) Tropical Medicine dept, Faculty of Medicine, Mansoura Univ., Egypt.

(Fathiya El-Raey) Tropical Medicine dept, Faculty of Medicine, Al-Azhar Univ., Damietta Egypt.

* CA: Mohammad Elmoghazy

dr_mhamed2008@yahoo.com

Introduction

In 1958, Caroli was the first to illustrate congenital dilatation of the intrahepatic bile ducts (IHDs), which leads to bile stasis and stone formation¹. This disorder can involve all IHDs or may be limited to some part of the liver, usually the left lobe or a segment of the left lobe^{2,3}. Its incidence is extremely low (1 in 1,000,000 of the population)² and it comprises two entities: the pure form (type 1), or Caroli disease (CD), and (type 2) associated with periportal fibrosis, also known as the Caroli syndrome⁴. The disease is the consequence of the arrest or derangement of the normal embryologic remodeling of bile ducts, and results in varying degrees of destructive inflammation and segmental dilatation⁵. Congenital hepatic fibrosis, CD, and Caroli syndrome are generally considered a disease continuum at different stages of severity associated with ductal plate malformation⁶. CD is the result of the involvement of large IHDs, while abnormal development of the small interlobular bile ducts results in

congenital hepatic fibrosis. If all levels of the biliary tree are affected, features of both congenital hepatic fibrosis and CD are expressed as the Caroli syndrome⁵. The main clinical manifestations are intermittent abdominal pain, hepatomegaly, recurrent cholangitis, and stone formation. Bacterial cholangitis occurs often and may be complicated by development liver abscess⁷. We report a case of simple-type CD with diffuse liver involvement, which was diagnosed in adulthood.

Case Report

A 27-year-old Egyptian man was admitted with a one-month history of intermittent fever and right upper quadrant abdominal pain, vomiting. He had no known underlying disease or significant family history, and denied alcohol and tobacco consumption. One year prior to admission, he returned from travelling abroad to Jordan, he visited an outpatient clinic because of epigastric and right upper quadrant abdominal

pain with occasional vomiting, investigated at that time by abdominal ultrasound which revealed multiple hepatic cysts with no other organ cysts, diagnosed as simple liver cysts versus hydrated disease, hydatid serology was -ve but the patient received a 3 months treatment course of albendazole for hydatid with no improvement. Other outpatient clinic visit by another physician with more investigations as the patient began to develop tinge of jaundice, Total bilirubin 2 mg% mainly direct, ALT 219 u/l, Albumin 3.8 gm%, high alkaline phosphatase (ALP) and gamma glutamyl transferase (GGT) more than 1000, +ve ASMA 1/20 high serum polyclonal immunoglobulins, -ve ANA, -ve LKMA1, -ve virological markers, diagnosed as autoimmune hepatitis and the patient started corticosteroid for 6 months with minimal clinical and laboratory improvement. On admission to our hospital, vital sign measurements were as follows: blood pressure, 100/80 mm Hg; body temperature, 38.0°C; pulse rate, 100 beats/minute; and respiratory rate, 20 breaths/minute. The physical examination showed right upper quadrant tenderness and laboratory test results were as follows: white blood cell count, 12,9/mL; aspartate transaminase, 59 IU/L; alanine transaminase, 120 IU/L; ALP, 882 IU/L; GGT, 1250 IU/L; total bilirubin, 4.1 mg/dL; and cancer antigen 19-9, 34.3 U/mL. Other laboratory indicators of portal hypertension, such as platelet count, serum albumin, or prothrombin time were all within normal range. Upper gastroduodenoscopy was done revealed small hiatus hernia and diffuse gastritis and duodenitis with no overt esophageal varices. Abdominal ultrasound again showed multiple hepatic cysts, slightly coarse echo pattern with no dilated intrahepatic biliary radicles and no CBD dilatation no GB disease, otherwise normal ultrasound. After reviewing the case we suspected a diffuse biliary disease. Differential diagnosis at that time was choledochal cysts, hydatid cysts, simple liver cysts, Iry sclerosing cholangitis, overlap syndrome, refractory auto-immune hepatitis. MRI abdomen and MRCP were requested to solve this dilemma of differential diagnosis. MRCP examination showed a cystic dilatation (ectasia) of IHBRs, normal caliber of

both CHD and CBD, no pancreatic masses; average sized liver with homogenous parenchymal texture, and gave diagnosis of diffuse type Caroli disease. Finally, we referred the patient for assessment for liver transplantation.

Discussion

Caroli disease is a rare congenital disorder characterized by communicating cavernous ectasia or segmental cystic dilatation of the IHD. Although duct abnormalities are generally present at birth, patients are often asymptomatic until adolescence or adulthood³, as in our case. Mode of inheritance is unclear, but in most cases, CD is transmitted in an autosomal recessive fashion⁴. Two forms of CD have been described. The simple or isolated type is characterized by cystic dilatation of the IHD, while the most common complex variant—also known as Caroli syndrome—is associated with congenital hepatic fibrosis, portal hypertension, and polycystic kidney disease^{8,9}. Simple-type CD is often limited to one lobe (usually the left), whereas Caroli syndrome usually involves the entire liver¹⁰. Our case was diagnosed as simple-type CD with diffuse liver involvement, which is uncommon, because there was no evidence of portal hypertension or polycystic kidney disease. Febrile episodes caused by cholangitis are the most common symptoms in CD; however, this may not be accompanied by jaundice or abdominal pain. Hepatomegaly is usually present, and laboratory tests typically show an elevated level of ALP and GGT. Intrahepatic ductal dilatation induces bile stasis, which may predispose individuals to stone formation and frequent infections, such as cholangitis, abscess formation, or even septicemia. Patients with CD are also at risk for intrahepatic cholangiocarcinoma¹¹. It is reported that about 7% of patients eventually develop malignancy¹², and the risk is known to be as high as 100-fold greater in patients with CD than in the general population^{13,14}. The diagnosis of CD relies on demonstrating the cystic dilatation of IHD in continuity with the biliary tree by imaging studies¹⁵. MRCP and ERCP are valuable in identifying direct communication of the intrahepatic saccular dilatation with the biliary tree¹⁶. However, because of its invasiveness, ERCP is recommended for therapeutic purposes but not

for the diagnosis of CD. In this case, ERCP was performed for treatment of choledocholithiasis, and direct communication of an intrahepatic cyst with the bile duct was confirmed. Clinicians should also be aware of the differential diagnosis of CD, such as the von Meyenburg complex, a rare condition that is usually asymptomatic and does not cause liver function abnormalities. It is generally diagnosed incidentally by MRCP, showing multiple small-sized cystic nodules (<1.5 cm) that do not communicate with the biliary tree¹⁷. Other differential diagnosis of CD includes primary sclerosing cholangitis, recurrent pyogenic cholangitis, polycystic liver disease, and biliary papillomatosis⁵. Treatment of CD depends on the clinical symptoms and location of the biliary abnormalities. In most patients, UDCA is used in an attempt to reduce the formation of intra-hepatic stones¹⁸. In our case, CBD stones removed during ERCP were pigment stones; therefore, it is reasonable to assume that IHD stones are also pigment stones, so that a successful result is less expected with UDCA. Therapeutic ERCP with dilatation of strictures and extraction of stones is also helpful in some cases. Potential curative treatment of CD is surgical resection, such as segmentectomy, lobectomy, or hepaticojejunostomy, determined by the range of distribution¹⁹. In localized diseases, lobectomy can not only cure but also reduce the risk of subsequent occurrence of cholangiocarcinoma. 10 Patients with end-stage liver disease or diffuse-type CD, as in our case, should be considered for eventual liver transplantation^{10,20}. In conclusion, this patient had a sporadic form of simple-type CD with diffuse involvement of the liver, and was diagnosed in adulthood following incidental discovery of liver function test abnormalities.

References

- 1- Caroli J, Couinaud C, Soupault R, Porcher P, Eteve J. A new disease, undoubtedly congenital, of the bile ducts: Unilobar cystic dilation of the hepatic ducts. **Sem Hop** 1958; 34: 496-502/SP.
- 2- Giovanardi R. Monolobar Caroli's disease in an adult. Case report. **Hepatogastroenterology** 2003; 50: 2185-2187.
- 3- Pezzilli R, Carini G, Cennamo V. Education and imaging. Hepatobiliary and pancreatic: Caroli's disease. **J. Gastroenterol Hepatol** 2008; 23: 1621.
- 4- Gupta A, Gupta A, Bhardwaj V, Chansoria M. Caroli's disease. **Indian J. Pediatr** 2006; 73: 233-235.
- 5- Levy A, Rohrmann C., Murakata L, Lonergan G. Caroli's disease: Radiologic spectrum with pathologic correlation. **Am J. Roentgenol** 2002; 179: 1053-1057.
- 6- Desmet V. Ludwig symposium on biliary disorders- Part I. Pathogenesis of ductal plate abnormalities. **Mayo Clin Proc** 1998; 73: 80-89.
- 7- Zhang D, Ji Z, Shen X, Liu H, Pan B, Dong L. Caroli's disease: A report of 14 patients and review of the literature. **J. Dig Dis.** 2012; 13: 491-495
- 8- Yonem O, Bayraktar Y. Clinical characteristics of Caroli's disease. **World J. Gastroenterol** 2007; 13: 1930-1933.
- 9- Wang ZX, Li YG, Wang RL, Li Z, Wang L, Yang H, et al. Clinical classification of Caroli's disease: an analysis of 30 patients. **HPB (Oxford)** 2015; 17: 278-283.
- 10- Bockhorn M, Malagó M, Lang H, Nadalin S, Paul A, Saner F, Frilling A, Broelsch CE. The role of surgery in Caroli's disease. **J. Am Coll Surg** 2006; 202: 928-932.
- 11- Chapman R. Risk factors for biliary tract carcinogenesis. **Ann Oncol** 1999; 10 Suppl 1 4: 308-311.
- 12- Dayton M, Longmire W, Tompkins R. Caroli's disease: A premalignant condition? **Am J. Surg** 1983; 145: 41-48.
- 13- Totkas S, Hohenberger P. Cholangiocellular carcinoma associated with segmental Caroli's disease. **Eur J. Surg Oncol** 2000; 26: 520-521.
- 14- Shimonishi T, Sasaki M, Nakanuma Y. Precancerous lesions of intrahepatic cholangiocarcinoma. **J. Hepatobiliary Pancreat Surg** 2000; 7: 542-550.
- 15- Lall N, Hogan M. Caroli disease and the central dot sign. **Pediatr Radiol** 2009; 39: 754.
- 16- Chung E, Conran R, Schroeder J, Rohena-Quinquilla I, Rooks V. From the radiologic pathology archives: Pediatric polycystic kidney disease and other ciliopathies: Radiologic-pathologic correlation. **Radiographics** 2014; 34: 155-178.

- 17- Sinakos E, Papalavrentios L, Chourmouzi D, Dimopoulou D, Drevelegas A, Akriviadis E. The clinical presentation of von Meyenburg complexes. **Hippokratia** 2011; 15: 170-173.
- 18- Ros E, Navarro S, Bru C, Gilabert R, Bianchi L, Bruguera M. Ursodeoxycholic acid treatment of primary hepatolithiasis in Caroli's syndrome. **Lancet** 1993; 342: 404-406.
- 19- Gu DH, Park MS, Jung CH, et al. Caroli's disease misdiagnosed as intraductal papillary neoplasm of the bile duct. **Clin Mol Hepatol** 2015; 21: 175-179.
- 20- Ulrich F, Steinmüller T, Settmacher U, et al. Therapy of Caroli's disease by orthotopic liver transplantation. **Transplant Proc** 2002; 34: 2279-2280.

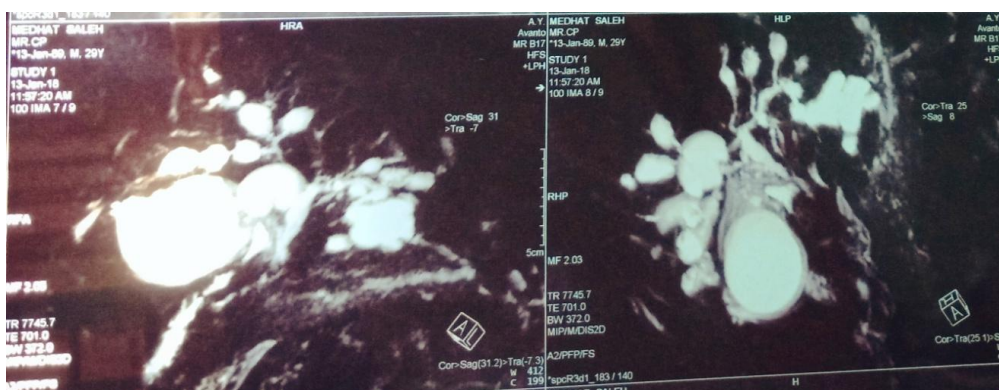


Figure (1) MRCP shows cystic dilatation (Ectasia) of intrhepatic biliary radicals.