

The Beneficial Effects of Silymarin in Treatment of Experimentally Induced Non-Alcoholic Fatty Liver Disease in Rats

HEBAT ALLAH M. MAHMOUD, M.Sc.*; FATMA A. MAHMOUD, M.D.*; GHADA HASHEM, M.D.*; HANAN H. AHMED, M.D.** and HESHAM M. MAHMOUD, M.D.*

The Departments of Medical Pharmacology* and Biochemistry**, Faculty of Medicine, Cairo University

Abstract

Background: Non alcoholic fatty liver disease (NAFLD) is one of the most common diseases worldwide, which is commonly associated with diabetes hyperlipidemia and insulin resistance with oxidative stress and inflammatory reaction. Silymarin offers good protection in various toxic models of experimental liver diseases in laboratory animals. It acts by antioxidative, anti-lipid peroxidative, antifibrotic, anti-inflammatory, membrane stabilizing, immunomodulatory and liver regenerating mechanisms

Aim of the Study: The present work was designed to study the beneficial effects of silymarin on a dietary model of NAFLD.

Material and Methods: 30 male albino rats were allocated in 3 groups. Group I represents the normal control, Group II represents the HFD induced NAFLD model, the effects of silymarin, was assessed in groups III. Body weight and blood pressure were recorded and blood samples were tested for total cholesterol, triglycerides and liver transaminases. Livers were removed and weighed, parts were used for GSH, MDA, TGF-B and other parts were kept for histopathological examination. Aortae were removed for in vitro vascular reactivity studies.

Results: Induction of NAFLD model by HFD for 20 weeks resulted in significant increase in body weight, blood pressure, liver index and epididymal weight, serum and liver different biochemical parameters with significant improvement of these indices in silymarin treated group. HFD model groups showed notable steatosis, lobular inflammation and fibrosis which was improved with silymarin use. Also NAFLD rats developed endothelial dysfunction which was significantly ameliorated in silymarin treated group.

Conclusion: The results of the present work showed that silymarin have the potential to favorably influence the course of NAFLD process and its complications. silymarin has many beneficial effects including scavenging of free radicals, or by enhancing the activity of antioxidant effects.

Correspondence to: Dr. Hebat Allah M. Mahmoud, The Department of Medical Pharmacology, Faculty of Medicine, Cairo University

Key Words: Non alcoholic fatty liver disease – HFD – Silymarin.

Introduction

THE term NAFLD encompasses a wide spectrum of conditions, from simple accumulation of fat ('fatty liver' or steatosis) to non-alcoholic steatohepatitis (NASH), fibrosis and cirrhosis with its clinical consequences. Despite the high prevalence of NAFLD in the general population, the vast majority of patients have simple steatosis [1].

The pathogenesis of nonalcoholic fatty liver disease has not been fully elucidated. A growing body of evidence shows that the primary abnormality in NAFLD is a metabolic disturbance. Insulin resistance is at the center of this metabolic abnormality and may cause NAFLD. Then, a fatty liver may cause hepatocyte injury and inflammation by oxidative stress and may progress to NASH and cirrhosis [2]. Therefore, improvement of these medical conditions may be beneficial to ameliorate NAFLD.

Treatment of NAFLD includes sustained weight loss which seems to improve insulin resistance associated with NAFLD. Several pharmacological agent have been studied including insulin sensitizing agents, lipid lowering agents, antioxidants, probiotics and cytoprotectives.

Silymarin is a flavonolignan that has been introduced fairly as a natural treatment for upper gastrointestinal and digestive disorder, and biliary diseases. It is the most well-known compound of the flavonoids, thanks to its well defined therapeutic properties. It is extracted from the seeds and fruit of *Silybum marianum* (Compositae) and in reality is a mixture of three structural components: Silibinin, silydianine and silychristine [3].

Studies have showed that silymarin is able to neutralize the hepatotoxicity of several agents, including *Amanita phalloides*, ethanol, paracetamol (acetaminophen) and carbon tetrachloride in animal models. Silymarin protects against their toxic principle [4,5].

The most important hepatoprotective mechanism of silymarin is its free radical scavenging effect therefore the present study was designed to study the effects of silymarin in treatment of NAFLD in rats.

Patients and Methods

The study was conducted in the Pharmacology Department, Faculty of Medicine, Cairo University in a duration of 5 months started from March 2016 to the end of July 2016.

Drugs and chemicals used:

Silymarin as powder (SEDICO-Egypt):

Silymarin was supplied as yellow powder and was dissolved in distilled water. It was given to rats by means of oral gavage in a dose of 100mg/kg/day in a total volume of 1ml [6].

High fat diet (HFD):

Consists of the standard crushed rat chow diet plus 10% animal fat and 2% cholesterol (Sigma-Aldrich-Egypt), [7].

Phenylephrine (Sigma-Aldrich-Egypt):

The drug was supplied in powder form and were freshly prepared in distilled water.

Krebs solution: For use in the in-vitro experiments on isolated aortic ring preparation. It has the following composition per liter distilled water.

NaCl 5.5g/l - KCl 0.35g/l - CaCl₂ 0.28g/l - MgSO₄ 0.14g/l - KH₂PO₄ 0.16g/l - NaHCO₃ 2.g/l - Glucose 2g/l.

Kits :

- Serum Cholesterol & Triglyceride assessment Kit, SIGMA-Aldrich- Egypt.
- Alanine Aminotransferase (ALT)& Aspartate Aminotransferase (AST) Activity Assay Kit SIGMA-Aldrich- Egypt.
- Serum insulin ELISA Kit (Ray Bio®- Rat Insulin, USA).
- Glucose Assay Kit (Sigma-Aldrich-Egypt).
- Malondialdehyde (MDA) (Ray Bio®- Rat MDA, USA).

- Tissue reduced glutathione GSH ELISA kit (Ray Bio®- Rat GSH, USA).

- Tissue Transforming Growth Factor-B (TGF-B) ELISA kit (RayBio® Rat TGF-B, USA).

Animals used:

This study included 30 adult male albino rats with an average weight of 180-200g. The animals were kept on a 12-h light/dark cycle (lights on from 08:00 am) at a constant ambient temperature (24±1°C), The animals were handled according to the guide lines of local ethical committee which comply with the international laws for use and care of laboratory animals. The animals were divided into 5 groups (12 rats each).

Group I (Negative control group):

Rats were fed with the standard rat chow for 16 weeks and 1ml/kg/day of distilled water were administered orally to these animals for additional 4 weeks which served as a negative control.

Group II (Animal model of high fat diet (HFD) induced non- alcoholic fatty liver disease (positive control):

Rats had free access to modified HFD in pellet form for 20 weeks with oral distilled water (1ml/kg/day) in the last 4 weeks [7].

Group III:

Rats received the HFD for 20 weeks with administration of silymarin in a dose of 100 mg/kg/day by means of oral gavage together with (HFD) daily for the last 4 weeks [6].

The HFD was prepared by mixing 2g cholesterol and 10g animal fat with 88g normal crushed pellet chow. The HFD was composed of the following energy sources: 52% was provided by carbohydrates, 30% by fat, and 18% by protein (overall calories: 4.8kcal/g). The negative control rats were fed normal rat pellet chow, which contains 67% carbohydrates, 10% fat, and 23% protein as the energy sources (overall calorie: 3.6kcal/g) [7,8].

Outcome measures:

a- In vivo measures:

- Body weight recordings were done to rats of all groups at the beginning and at the end of the study.
- Blood pressure was monitored; at the beginning of the study and at the end using the non-invasive rat tail cuff blood pressure measuring system (Harvard Apparatus Ltd, Edenbridge, Kent, Eng-

land). In the tail-cuff technique, animals were warmed for 30min at 28°C in a thermostatically controlled heating cabinet (UgoBasille, Italy) for detection of tail artery pulse, the tail was passed through a miniaturized cuff and a tail-cuff sensor that was connected to an amplifier (ML 125 NIBP, AD Instruments, Australia) Mean arterial pressure (MAP) was calculated using the equation: $MAP = \text{diastolic blood pressure} + 1/3 (\text{systolic blood pressure} - \text{diastolic blood pressure})$ [9].

b- Collection of blood samples for biochemical analysis:

Venous blood samples were obtained from all animals at the end of the experiment.

Procedure:

The animals were lightly anaesthetized then venous samples were collected by means of capillary glass tubing from the retro-orbital plexus. Serum samples were analyzed for the measurement of:

- Serum total cholesterol (TC) & Serum triglyceride (TG).
- Serum alanine aminotransferase (ALT) & serum aspartate aminotransferase (AST) serum insulin level & fasting blood glucose.

c- Determination of liver index, oxidant, antioxidant parameters, level of TGF-B:

Liver was quickly removed and weighed for calculation of liver index (LI, it is calculated as liver weight/bodyweight x100%) [10]. Part of the liver tissues was snap frozen in liquid nitrogen for analysis of:

- Hepatic levels of malondialdehyde (MDA).
- Hepatic levels of reduced glutathione (GSH).
- Hepatic levels of transforming growth factor B (TGF-B).

d- Determination of visceral obesity:

The epididymal fat was removed and measured, and used as an indicator for visceral adipose tissue [8].

e- Pathological examination:

A small piece of liver was immediately fixed in 10% neutral-buffered formalin then embedded in paraffin wax. For light microscopic analysis of liver histology, the paraffin-embedded liver tissues were cut into 4µm sections, and standard hematoxylin-eosin (H&E) staining was performed. Hepatic fibrosis was assessed by Masson trichrome stain.

The liver sections were scored according to the NAFLD Activity Score (NAS), which includes the features of active liver injury. The score is defined as the sum of the scores for steatosis (0-3) hepatic steatosis: Score 0, no fat; score 1, steatosis occupying less than 33% of the hepatic parenchyma; score 2, 34-66% of the hepatic parenchyma; score 3, more than 66% of the hepatic parenchyma, lobular inflammation (0-3) inflammatory cell infiltration: Score 0: None; score 1, 1-2 foci/field; score 2, 3-4 foci/field; score 3, more than 4 foci/field, and hepatocellular ballooning (0-2); is evaluated for zonal location, and the estimate of its severity is based on the numbers of hepatocytes showing this abnormality (score 1=few ballooned cells, score 2= marked ballooning) thus ranging from 0 to 8 [11].

Hepatic fibrosis was investigated by Masson staining as:

- Stage 1: Perisinusoidal/pericellular fibrosis; focally or extensively present (lesion in the central vein area).
- Stage 2: Zone 3 perisinusoidal/pericellular fibrosis with focal or extensive periportal fibrosis (lesion in the central vein area and expansion to the surrounding area).
- Stage 3: Portal fibrosis with focal or extensive bridging fibrosis.
- Stage 4: Cirrhosis. Table (4) [11,12].

f- In vitro study:

Vascular reactivity studies of isolated rat aorta to examine endothelial dysfunction induced by HFD.

Rats were anesthetized with intraperitoneal sodium pentobarbital (35mg/kg) then sacrificed. The thoracic aorta was quickly removed, cleaned of adhering fat and connective tissue. Ring segments (3-5mm) were mounted between two stainless steel wires in 10-ml organ baths filled with modified Krebs solution, under passive tension of 1 g for 45min. The rings were maintained at 37°C and gassed with a 95% O₂ and 5% CO₂ mixture (pH=7.4). The contractile response (isometric tension, in g) was measured by a force transducer coupled to data acquisition system and analysis software (powerlab) AD Instruments. Organ bath 4/30, ML221 (Australia) transducer (TR 1201Pan lab, Spain).

After 45 minutes of equilibration; aortic rings were challenged with phenylephrine to assure the good contractile condition of the preparation [13].

A dose response curve of the preparation from different groups was done to Phenylephrine induced contractile response.

Statistical analysis:

The data was coded and entered using the statistical package SPSS version 15. The data was presented as: Mean and standard deviation, for quantitative variables and number and percentage for qualitative values. Statistical differences between groups were tested using Chi Square test for qualitative variables, independent sample *t*-test and ANOVA (analysis of variance) test with post Hoc Bonferroni test for quantitative variables.

p-value <0.05 was considered statistically significant.

Results

The body weight (BW) changes and the mean arterial pressure were measured to all rats of the study groups at the beginning and the end of the study.

Feeding rats with high fat diet (HFD) for 20 weeks in group II resulted in significant increase in the mean body weight and the mean arterial pressure (MAP) at the end of the 20th week compared to that of the control group. administration of silymarin for 4 weeks resulted in insignificant reduction of the mean BW and e of the mean (MAP) (Tables 1,2).

Feeding rats with HFD resulted in increase in visceral adiposity as indicated with significant increase in epididymal fat weight and liver index compared to that of control group. Treatment with silymarin resulted in significant reduction of epididymal fat weight and liver index compared to HFD fed non treated group (Table 3).

Regarding the different biochemical parameters, feeding rats with HFD for 20 weeks (group II) resulted in significant elevation of fasting blood glucose level with significant rise of serum insulin level as well as significant elevation of serum cholesterol and triglycerides, there was also significant elevation of serum liver enzymes ALT, AST compared to that of the normally fed control rats.

Giving silymarin orally for 4 weeks resulted in insignificant reduction of fasting blood glucose and serum insulin levels.

Giving silymarin resulted significant reduction of serum cholesterol, triglycerides and AST, ALT compared to HFD fed non treated group.

Regarding the oxidant antioxidant parameters measured in liver tissue there was significant elevation of hepatic MDA levels and significant reduction of reduced glutathione levels (GSH) in liver tissue of rats of HFD fed non treated group compared to the normal control with significant reduction of MDA levels and significant elevation of GSH levels with treatment with silymarin.

Feeding rats with HFD for 20 weeks resulted in significant elevation of hepatic TGF-B evels compared to normally fed control group, with significant reduction of its values with treatment with silymarin compared to HFD fed non treated group (Table 4).

Table (1): Effect of treatment with silymarin (100 mg/kg/ day) together with high fat diet HFD for 4 week preceded by 16 weeks of HFD only on the mean body weight of albino rats.

Groups	The mean body weight (g) ±SD	
	At the beginning	At the end of 20th week
Group I (control)	191±8.43	371±9.5
Group II (HFD)	193.3±8.5	438.3±12.3*
Group III (silymarin treated)	193.5±8.24	432.1±11.4

Data are represented as mean ± SD.

n=10.

*=Significant change compared to group I (*p*-value <0.05).

Table (2): Effect of treatment with silymarin (100 mg/kg/ day) together with high fat diet HFD for 4 week preceded by 16 weeks of HFD only on the mean arterial pressure (MAP) of albino rats.

Groups	The mean value of the mean arterial pressure (MAP) (mm hg) ±SD	
	At the beginning	At the end of 20th week
Group I (control)	86.08± 1.49	87.91±1.44
Group II (HFD)	86.25± 1.92	143.55±5.28*
Group III (silymarin treated)	86.5±1.8	133.66±5.86

Data are represented as mean ± SD.

n=10.

*=Significant change compared to group I (*p*-value <0.05).

Table (3): Effect of treatment with silymarin (100 mg/kg/ day) together with high fat diet HFD for 4 week preceded by 16 weeks of HFD only on epididymal fat weight and liver index of albino rats.

Groups	Epididymal fat weight (g)	Liver index %
Group I (control)	7.71 ±0.74	3.00±0.25
Group II (HFD)	11.68±0.51*	4.79±0.470*
Group III (silymarin treated)	9.83±0.505#	3.99±0.260#

Data are represented as mean ± SD.

n=10.

* = Significant change compared to group I (*p*-value <0.05).

= Significant change compared to group II (*p*-value <0.05).

Table (4): The effect of treatment with silymarin (100mg/kg/day) together with high fat diet HFD for 4 week preceded by 16 weeks of HFD only on serum and tissue biochemical parameters in albino rats.

	Normal control	HFD non treated	Silymarin treated
Fasting blood glucose mg/dl	85.67±4.65	285.85±15.0*	279.12±14.39
Serum insulin Pg/ml	759.11±44.42	1949±74.46*	1520.75±77.05#
Total cholesterol mg/dl	73.55±6.47	266.38±7.26*	208.71±11.36 #
Triglycerides mg/dl	71.42±9.66	142.11±7.53*	105.61±10.08#
ALT U/ml	39.08±5.7	143.94±9.77*	106.9±9.37#
AST U/ml	26.61±3.97	164.99 ±9.08*	119.69±8.10#
Hepatic MDA nmol/g tissue	247.78±17.04	504.4±43.56*	331.82±31.33#
Hepatic GSH U/g Tissue	494.46±14.40	277.51±17.75*	372.18±16.66#
TGF-B ng/g tissue	5.76 ±0.79	40.54±4.02*	22.38±2.45#

Data are represented as mean ± SD. n=10. * = Significant change compared to group I (p-value <0.05). # = Significant change compared to group II (p-value <0.05).

Table (5): Effect of treatment with silymarin (100 mg/kg/day) together with high fat diet HFD for 4 week preceded by 16 weeks of HFD only on total histopathological score in albino rats.

	Normal control	HFD non treated	Silymarin treated
Total histopathological NAS score	1.8±0.79	7.6±0.52*	6.0±0.82#

Data are represented as mean ± SD. n=10. * = Significant change compared to group I (p-value <0.05). # = Significant change compared to group II (p-value <0.05).

Table (6): Effect of treatment with silymarin (100 mg/kg/day) together with high fat diet HFD for 4 week preceded by 16 weeks of HFD only on fibrosis score in albino rats.

	Normal control	HFD non treated	Silymarin treated
Stage 0	100%	0.0%	0.0%
Stage 1	0.0%	0.0%	50.0%
Stage 2	0.0%	60%	40%
Stage 3	0.0%	40%	10%
Stage 4	0.0%	0.0%	0.0%

Table (7): Effect of treatment with silymarin (100 mg/kg/day), with high fat diet HFD for 4 weeks preceded by 16 weeks of HFD only on phenylephrine (PE) induced contractions of aortic rings isolated from rats of different studied groups.

Phenyl ephrin concentration ug/ml	Normal control	HFD non treated	Silymarin treated
2	0.21±0.01	0.56±0.08*	0.48±0.06#
4	0.29±0.04	0.98±0.06*	0.77±0.06#
8	0.35±0.02	1.7±0.1*	1.15±0.03#
16	0.45±0.03	1.97±0.04*	1.5±0.06#

Data are represented as mean ± SD. n=10. * = Significant change compared to group I (p-value <0.05). # = Significant change compared to group II (p-value <0.05).

For the histopathological studies Liver sections from rats fed with the regular dry rat chow (normal control group I) had normal morphological appearance with normal structure and architecture with mean total NAS score 1.8±0.79 with no evidence of fibrotic changes with 100% of animals having (score 0). In case of feeding rats with high fat high cholesterol diet for 20 weeks (Group II) all rats developed hepatic changes consistent with severe steatosis. All liver samples showed moderate to severe lobular inflammation with focal necrosis and hepatocellular ballooning. Hepatic inflammation was present as demonstrated by infiltration with polymorphs and mononuclear cells, with necrotic foci were frequently observed with mean total NAS score was significantly increased compared to that of normal group (group I). Liver sections stained with Masson stain showed extensive periportal and portal fibrosis. administration of silymarine orally for 4 weeks resulted in significant reduction of pathological changes induced by high fat diet feeding and improvement of histopathological scores with liver samples showing mild to moderate steatosis and less inflammation and ballooning with significant reduction of total NAS and fibrosis scores compared to non treated group II (Tables 5,6) (Figs. 1,2a,b,3a,b).

Regarding to the in vitro vascular reactivity studies, the aortic ring contraction responses to phenylephrine (PE) in different groups were obtained in grams.

Induction of NAFLD with high fat high cholesterol diet for 20 weeks (group II) resulted in significant increase of the mean aortic ring contractile response to different concentrations of PE compared to normally fed rats of group I. administration of silymarin for 4 weeks resulted in significant reduction in PE induced contractions compared to HFD non treated group II (Table 7).

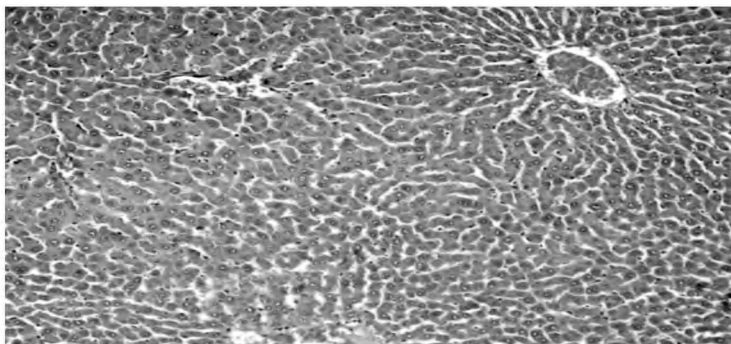


Fig. (1): Liver section of control group I showing normal structure and architecture (Haematoxylin & Eosin x 100).

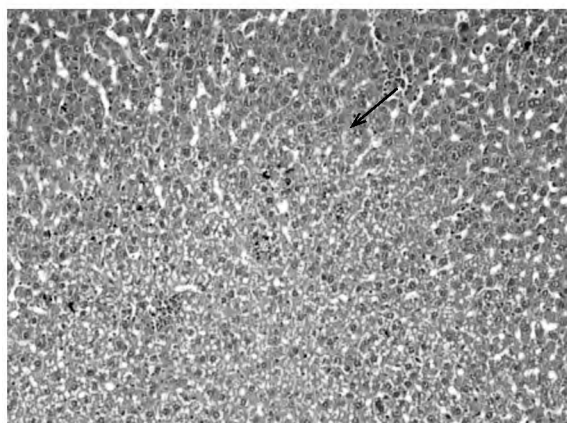
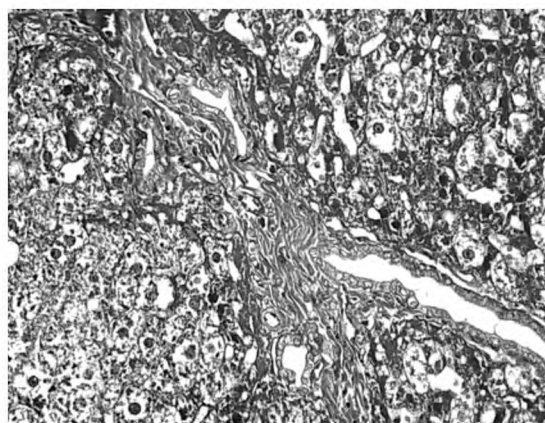


Fig. (2A): Liver section of HFD fed group II showing severe degree of micro and macrovesicular steatosis and severe hepatocellular ballooning with frequent foci of inflammatory cells (black arrow) (Haematoxylin & Eosin x 200).



(Fig. 2B): Liver section of HFD fed group II showing marked portal fibrosis (yellow arrow) (masson trichom stain x 100)

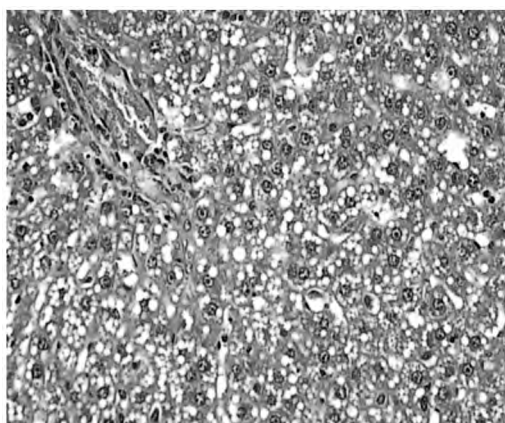


Fig. (3A): Liver sections of rats treated with silymarin (group III) showing improved inflammation and moderate steatosis (H & E x 100).

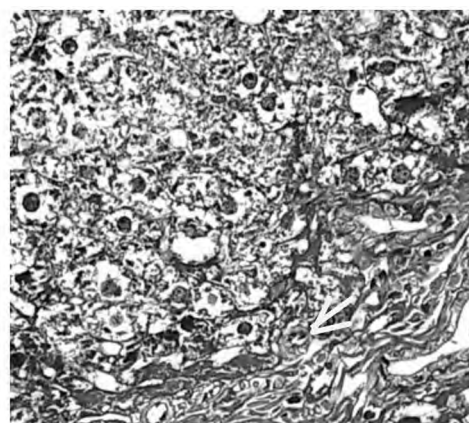


Fig. (3B): Liver sections of rats treated with silymarin showing mild perisinusoidal fibrosis (yellow arrow) (masson stain x 100).

Discussion

Non alcoholic fatty liver disease (NAFLD) consists of a spectrum of conditions ranging from a simple fatty infiltration to steatohepatitis, fibrosis and cirrhosis. Obesity, type 2 diabetes mellitus and hyperlipidemia are often associated with NAFLD. These aspects may coexist with insulin resistance. In turn, insulin resistance may lead to endothelial dysfunction and systemic hypertension and may induce an abnormal lipid profile [14]. Silymarin (a

mixture of at least 4 closely related flavonolignans, demonstrated antioxidant properties, through stimulation of polymerase and RNA transcription, by protecting the cell membrane from radical-induced damage and blocking the uptake of toxins [15]. In the present study the effect of silymarin, was tested on different features of rat model of non-alcoholic fatty liver disease (NAFLD) induced by high fat diet (HFD) feeding for 20 weeks.

HFD feeding of rats for 20 weeks resulted in development of rat steatohepatitis as documented from the histopathological and biochemical tests.

In the present study, rats received oral Silymarin for 4 weeks with HFD after 16 weeks of HFD only resulted in insignificant reduction of the mean body weight compared to that of the corresponding HFD fed non-treated groups however significant reduction of epididymal fat weight and liver index (LI) was noticed with Silymarin administration compared to that of the corresponding HFD fed non treated groups.

NAFLD/NASH is now considered one of the hepatic manifestations of metabolic Syndrome [16] which was reflected in the animal model of NAFLD used. The results of the present work was in accordance to other studies where Buettner, Schölm-erich and Bollheimer observed that prolonged offer of a lipid-rich diet induces weight gain in susceptible rats compared to control. According to these authors, the induction of obesity is more effective when the high-fat diet is started at a young age and is continued for several weeks [17]. HFD feeding precipitates the characterization of obesity development that causes increase in body weight with expanded adipose mass and may lead to altered function of adipocytes which induces lipid accumulation in the liver and can also precipitate obesity and associated metabolic disorders [18].

The results of the present study were in accordance with [19] who reported significant improvement in the liver weight in case of pretreatment with the silymarin in hepatotoxicity rat model.

In the present work, treatment with silymarin, resulted in significant reduction of serum levels of total cholesterol compared to high fat fed non treated groups. Regarding triglycerides serum level there was significant reduction also compared to the corresponding HFD fed non treated group. Significant reduction of transaminases ALT and AST levels was reported in silymarin treated group compared to the corresponding HFD fed non-treated group.

These results were in accordance with Hajaghamohammadi et al., [20] studies which reported that silymarin extract caused an improvement in serum alanine aminotransferase (ALT) levels in non alcoholic fatty liver disease patients.

Also Federico et al., [21] reported that a new silybin vitamin E complex improves insulin resistance and liver damage in patients with NAFLD.

More recently, Hasjiani et al., [22] found that in two patient groups receiving silymarin and Vitamin E, respectively, the AST and ALT serum levels significantly decreased.

Regarding the effects of silymarin on glycemic control and insulin resistance, the results of the present work showed in insignificant reduction of fasting glucose levels, while for serum insulin levels, significant reduction was observed with silymarin treatment compared to non treated groups. In NAFLD, type 2 diabetes, or metabolic syndrome, insulin resistance develops because of a defect in insulin signal transduction mechanism [23]. So, circulating insulin concentration fails to induce glucose uptake into the cells and the hyperglycemia develops. To compensate for the hyperglycemia, pancreas secretes more insulin leading to hyperinsulinemia [24].

Multiple biochemical, metabolic and signal transduction pathways contribute to insulin resistance. It was found that protein glycation may play role in insulin resistance by a variety of mechanisms, including generation of tumor necrosis factor- α , direct modification of the insulin molecule leading to its impaired action, generation of oxidative stress and impairment of mitochondrial function [25]. So that the beneficial effect of silymarin is mostly due improvement of insulin resistance. These results were in accordance with a previous report, in which silymarin treatment was associated with a reduction of insulin resistance and a significant decrease in fasting insulin levels, suggesting an improvement of the activity of endogenous and exogenous insulin [26], also Federico et al., [21] showed that a new silybin vitamin E complex improves insulin resistance and liver damage in patients with NAFLD. In Cacciapuoti, et al., study, [26], NAFLD was associated with insulin resistance (HOMA-IR) which was improved with silymarin treatment.

In the present study administration of silymarin restored hepatic reduced GSH with significant increase in its levels compared to that of the corresponding HFD fed non treated group. For MDA levels, use of silymarin resulted in significant increase compared to non treated groups Silymarin has demonstrated antioxidant properties, through stimulation of polymerase and RNA transcription, by protecting the cell membrane from radical-induced damage and blocking the uptake of toxins. Studies performed in patients with liver disease have shown that silymarin increased superoxide dismutase activity of lymphocytes and erythrocytes. In addition, it has been shown to increase patient

serum levels of glutathione and glutathione peroxidase [27]. The most important hepatoprotective mechanism of silymarin is its free radical scavenging effect. It raises the cellular content of glutathione that lead to the lipid peroxidation inhibition, increase membrane stability, steroid-like effect via adjustment of nuclear expression and reducing the deposition of collagen fibers as silymarin inhibits the conversion of stellate hepatocytes into myofibroblasts, which mediate the deposition of collagen fibers, leading to cirrhosis [28].

In the present study administration of Silymarin resulted in significant antifibrotic effects with significant reduction of hepatic TGF- β levels compared to the corresponding HFD fed non-treated group which was in accordance with Abdel-Moneim et al., study [29] which reported the free Radical-Scavenging, Anti-Inflammatory/Anti-Fibrotic and Hepatoprotective Actions of Taurine and Silymarin against CCl₄ Induced Rat Liver Damage.

Regarding the histopathological studies, the tested drug resulted in significant improvement of hepatic steatosis, inflammation, ballooning and fibrosis together with significant reduction of total NAS score compared to the corresponding HFD fed non-treated group.

Silymarin has an anti-inflammatory effect by acting through different mechanisms as its antioxidant action, membrane stabilizing effect and inhibition of production or release of inflammatory mediators.

That was in agreement with Zhang et al., who revealed that steatosis was much less severe in silymarin treated groups so that silymarin could improve the degree of hepatic steatosis and inflammation in liver tissues [30].

The effect of silymarin on blood pressure and endothelial dysfunction is contradictory. In the present study there was insignificant reduction of the mean value of the mean arterial pressure (MAP) with silymarin treatment however significant improvement of arterial stiffness was observed.

Insulin resistance may lead to endothelial dysfunction and systemic hypertension and may induce an abnormal lipid profile. All these changes may promote the development of atherosclerotic vascular disease.

The eNOS-NO system is thought to be responsible for endothelial dysfunction in NAFLD [31]. Endothelial dysfunction is a predictor for cardio-

vascular events in patients with NAFLD. Freitag et al., reported that treatment with silymarin decreased NO production, suggesting antiinflammatory and anti-free radicals properties of this drug [19]. Also Cacciapuoti et al., reported The effects of silybum marianum and vitamin E on some biochemical indices of atherosclerotic progression [26].

Conclusion:

In conclusion, the results obtained indicate that silymarin seems to be effective in reducing the biochemical and histopathological changes induced by high fat diet model of NAFLD so that we recommend the use of silymarin for reduction of NAFLD progression and complication due to silymarin's beneficial effects including scavenging of free radicals, or by enhancing the activity of antioxidant effects.

References

- 1- BUZZETTI E., PINZANI M. and TSOCHATZIS E.A.: The multiple-hit pathogenesis of non-alcoholic fatty liver disease (NAFLD). *Metabolism*, 65 (8): 1038-1048, 2016.
- 2- BAŞ ARANOĞLU M. and ÖRMECI N.: Nonalcoholic fatty liver disease: Diagnosis, pathogenesis, and management. *Turk. J. Gastroenterol.*, 25: 127-132, 2014.
- 3- VALENZUELA A. and GARRIDO A.: Biochemical bases of the pharmacological action of the flavonoid silymarin and of its structural isomer silibinin. *Biological Research*, 27 (2): 105-112, 1993.
- 4- SHAKER E., MAHMOUD H. and MNAA S.: Silymarin, the antioxidant component and Silybum marianum extracts prevent liver damage. *Food and Chemical Toxicology*, 48 (3): 803-806, 2010.
- 5- DAS S.K. and MUKHERJEE S.: Biochemical and immunological basis of silymarin effect, a milk thistle (Silybum marianum) against ethanolinduced oxidative damage. *Toxicology Mechanisms and Methods*, 22 (5): 409-413, 2012.
- 6- HUANG B., BAN X., HE J., TONG J., TIAN J. and WANG Y.: Hepatoprotective and antioxidant activity of ethanolic extracts of edible lotus (*Nelumbo nucifera* Gaertn.) leaves. *Food Chemistry*, 120 (3): 873- 878, 2010.
- 7- WANG W., ZHAO C., ZHOU J., ZHEN Z., WANG Y. and SHEN C.: Simvastatin ameliorates liver fibrosis via mediating nitric oxide synthase in rats with non-alcoholic steatohepatitis-related liver fibrosis. *PLoS. S. One.*, 8 (10): e76538, 2013.
- 8- XU Z.J., FAN J.G., DING X.D., QIAO L. and WANG G.L.: Characterization of high-fat, diet-induced, non-alcoholic steatohepatitis with fibrosis in rats. *Digestive Diseases and Sciences*, 55 (4): 931-940, 2010.
- 9- ROGERS G. and OOSTHUYSE T.: A comparison of the indirect estimate of mean arterial pressure calculated by the conventional equation and calculated to compensate for a change in heart rate. *Int. J. Sports Med.*, 21 (2): 90-95, 2000.

- 10- EL-LAKKANY N.M., SALAH EL-DIN S.H., SABRA A.N.A.A., HAMMAM O.A. and EBEID F.A.L.: Co-administration of metformin and Nacetylcysteinewith dietary control improves the biochemical and histological manifestations in rats with non-alcoholic fatty liver. *Research in Pharmaceutical Sciences*, 11 (5): 374, 2016.
- 11- KLEINER D.E., BRUNT E.M., VAN NATTA M., BEHLING C., CONTOS M.J., CUMMINGS O.W. and YEH M.: Design and validation of a histological scoring system for nonalcoholic fatty liver disease. *Hepatology*, 41 (6): 1313-1321, 2005.
- 12- BRUNT E.M., JANNEY C.G., DI BISCEGLIE A.M., NEUSCHWANDER-TETRI B.A. and BACON B.R.: Nonalcoholic steatohepatitis: A proposal for grading and staging the histological lesions. *The American Journal of Gastroenterology*, 94 (9): 2467-2474, 1999.
- 13- DAMIANI C.E.N., ROSSONI L.V. and VASSALLO D.V.: Vasorelaxant effects of eugenol on rat thoracic aorta. *Vascular Pharmacology*, 40 (1): 59-66, 2003.
- 14- Cacciapuoti F.: Visceral adiposity as a cause of some cardiovascular disorders. Old and new adipocytokines. *Obesity and Metabolism*, 6: 39-45, 2010.
- 15- WELLINGTON K. and JARVIS B.: Silymarin: A review of its clinical properties in the management of hepatic disorders. *Bio. Drugs.*, 15 (7): 465-489.
- 16- FAN J.G. and FARRELL G.C.: VAT fat is bad for the liver, SAT fat is not!. *Journal of Gastroenterology and Hepatology*, 23 (6): 829-832, 2008.
- 17- BUETTNER R., SCHÖLMERICH J. and BOLLHEIMER L.C.: High-fat diets: Modeling the metabolic disorders of human obesity in rodents. *Obesity*, 15 (4): 798-808, 2007.
- 18- SASIDHARAN S.R., JOSEPH J.A., ANANDAKUMAR S., VENKATESAN V., ARIYATTU MADHAVAN C.N. and AGARWAL A.: Ameliorative potential of *Tamarindus indica* on high fat diet induced nonalcoholic fatty liver disease in rats. *The Scientific World Journal*, 2014.
- 19- FREITAG A.F., CARDIA G.F.E., da ROCHA B.A., AGUIAR R.P., SILVA-COMAR F.M.D.S., SPIRONELLO R.A. and CUMAN R.K.N.: Hepatoprotective effect of silymarin (*Silybum marianum*) on hepatotoxicity induced by acetaminophen in spontaneously hypertensive rats. *Evidence-Based Complementary and Alternative Medicine*, 2015.
- 20- HAJAGHAMOHAMMADI A.A., ZIAEE A. and RAFLEI R.: The efficacy of silymarin in decreasing transaminase activities in nonalcoholic fatty liver disease. A randomized controlled clinical trial. *Hepat. Mon.*, 8: 191-195. [Pub. Med.], 2008.
- 21- FEDERICO A., TRAPPOLIERE M., TUCCILLO C., DE SIO I., DI LEVA A., DEL VECCHIO BLANCO C. and LOGUERCIO C.: A new silybin-vitamin E-phospholipid complex improves insulin resistance and liver damage in patients with non-alcoholic fatty liver disease: Preliminary observations. *Gut*. 55: 901-902. [PMC free article] [Pub. Med.], 2006.
- 22- HASJIANI E. and HASAHEMI S.J.: Comparison of therapeutic effects of Silymarin and Vitamin E in non-alcoholic fatty liver disease: Results of an open-label, prospective, randomized study. *J.J.N.P.P.*, 4: 8-14, 2009.
- 23- DAVIS L.M., PEI Z., TRUSH M.A., CHESKIN L.J., CONTOREGGI C., MCCULLOUGH K., et al.: Bromocriptine reduces steatosis in obese rodent models. *J. Hepatol.*, 45: 439-44, 2006.
- 24- NADE V.S., KAWALE L.S., TODMAL U. and TAJAN-PURE B.A.: Study of bromocriptine effect on cardiovascular complications associated with metabolic syndrome in fructose fed rats. *Indian. J. Pharmacol. Nov-Dec.*, 44 (6): 688-69, 2012.
- 25- SONG F. and SCHMIDT A.M.: Glycation and Insulin Resistance. Arteriosclerosis, thrombosis, and vascular biology, 32 (8): 1760-1765, 2012.
- 26- CACCIAPUOTI F., SCOGNAMIGLIO A., PALUMBO R., FORTE R. and CACCIAPUOTI F.: Silymarin in non alcoholic fatty liver disease. *World Journal of Hepatology*, 5 (3): P. 109, 2013.
- 27- WELLINGTON K. and JARVIS B. SILYMARIN: A review of its clinical properties in the management of hepatic disorders. *Bio. Drugs*, 15: 465-489. [Pub. Med.], 2001.
- 28- POLYAK S.J., MORISHIMA C., LOHMANN V., PAL S., LEE D.Y., LIU Y., GRAF T.N. and OBERLIES N.H.: Identification of hepatoprotective flavonolignans from silymarin. *Proceedings of the National Academy of Sciences*, 107 (13): Pp. 5995-5999, 2010.
- 29- ABDEL-MONEIM A.M., AL-KAHTANI M.A., EL-KERSH M.A. and AL-OMAIR M.A.: Free radical-scavenging, anti-inflammatory/anti-fibrotic and hepatoprotective actions of taurine and silymarin against CCl4 induced rat liver damage. *PLoS. One.*, 10 (12): P. e0144509, 2015.
- 30- ZHANG W., HONG R. and TIAN T.: Silymarin's protective effects and possible mechanisms on alcoholic fatty liver for rats. *Biomol. Ther.*, 21 (4): 264-269, 2013.
- 31- WU Y., XUE L., DU W., HUANG B., TANG C., LIU C. and JIANG Q.: Polydatin restores endothelium-dependent relaxation in rat aorta rings impaired by high glucose: A Novel insight into the PPAR β -NO signaling pathway. *Plo. S. One.*, 10 (5): e0126249, 2015.

الاثار المفيدة للسليمارين في علاج امراض الكبد الدهنى الغير كحولى المستحدثة فى الجرذان

مرض الكبد الدهنى غير الكحولى يعتبر حاليا احد اهم اسباب اضطرابات الكبد المزمنة فى العالم ويرتبط بشدة بمتلازمة اختلال الايض.

السليمارين مستخلص عشبى تبنت فاعليته فى كثير من الامراض نتيجة خواصه المضاده للالتهابات والممانعة للاكسدة. مما استدعى دراسة تأثيره على مرض الكبد الدهنى غير الكحولى ولذلك صممت هذه الدراسة لتقييم الاثار المفيدة للسليمارين فى علاج امراض الكبد الدهنى الغير الكحولى المستحدث باستخدام نظام غذائى عالى الدهون فى الجرذان.

تم استخدام عدد ٣٠ جرذا متقاربين فى الوزن والسن موزعين على ٣ مجموعات كل مجموعة تشمل ١٠ جرذا كما يلى :

١- مجموعة ضابطة سلبية.

٢- مجموعة ضابطة تغذت على غذاء عالى الدهون.

٣- مجموعة معالجة بدواء السليمارين.

نتائج هذه الدراسة وضحت وجود زيادة ذات دلالة احصائية فى وزن وضغط الدم للجرذان التى تغذت على الغذاء عالى الدهون كذلك لارتفاع فى انزيمات الكبد والكلوليسترول والدهون الثلاثية ودلالات الالتهاب وللأكسدة.

بينما نجح الاستخدام العلاجى بالسليمارين فى خفض الوزن بصورة ذات دلالة احصائية وتحسن فى نتائج التحاليل والصورة الباثولوجية للكبد.

ويمكن استخلاص ان دواء السليمارين له العديد من الاثار الايجابية للكبد الدهنى من حيث قدرته كمضاد للاكسدة ومانع للالتهاب ومعزز لقدرة الكبد على التعافى من التليف كما ظهر من النتائج للبحث.