

## **REVIEW ARTICLE: PERCUTANEOUS PATELLAR OSTEOSYNTHESIS**

By

**Mohammad Salah Abdel Hafeez, Mohammad Abd Almoneim Negm  
and Tamer Mohammad Abdel Azim**

Department of Orthopaedic Surgery, Faculty of medicine, AlAzhar University

### **ABSTRACT**

**Background:** Open reduction of patella fracture is the currently acceptable method for treating these fractures. In this study describe some minimally invasive techniques have been proposed as possible alternative methods with percutaneous reduction and fixation of patella fractures.

**The purpose of this article** was to review percutaneous surgical techniques that preserve the vascular supply of patellar fragments, which may improve fracture consolidation, and decrease post operative complications as infection, delayed wound healing, broken wires, irritation, immigration of Kirschner wires, and fixation failure.

**Conclusion:** Percutaneous surgical techniques of fixation of patellar fracture offering better functional outcome, short operative time, provide stable fixation, minimal postoperative pain, excellent cosmesis and lower incidence of complications.

### **INTRODUCTION**

Open repair of displaced patellar fractures are still the most widely used technique and can offer satisfactory results (**Wright et al., 2009**). However, complications associated with open reduction such as infection, delayed wound healing, broken wires, irritation, immigration of Kirschner wires, fixation failure, and revision were reported with different frequencies between 7% and 43% (**Lebrun et al., 2012**). These complications are related to open approach, fixation device, or both. Displaced transverse patellar fractures are easier for anatomic reduction by closed manipulation and potential candidates for percutaneous osteosynthesis. Less invasive technique with percutaneous fixation may reduce

postoperative wound complications and the possibility of delayed operation. However, there is a paucity of research in this field. There were few articles describing techniques using closed methods for patellar fractures (**Luna-Pizarro et al., 2006**).

Percutaneous surgical techniques preserve the vascular supply of patellar fragments, which may improve fracture consolidation. However, this treatment is technically demanding and not applicable to all fracture patterns. This technique combines the advantages of minimal invasive surgery and rigid internal fixation thereby permitting early rehabilitation and good functional outcome (**Tian et al., 2011**). The patella is the largest sesamoid bone in the human body, and has a major role in extension of the knee. Patella

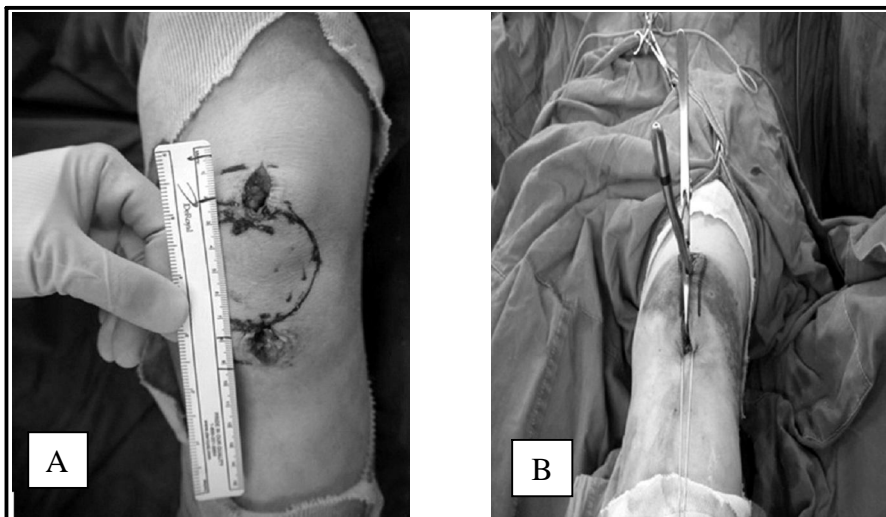
fractures occur through excessive tension or by a direct external force, both disrupting knee extension. Surgical treatment is necessary for displaced fractures to restore extension and reduce the risk of potential patello femoral (PF) osteoarthritis (OA) (Melvin and Mehta, 2011).

### Surgical Techniques:

**Percutaneous Cannulated Screws with Tension Band Wiring Technique:** This study describes a percutaneous 2 cannulated screws and modified tension band wiring technique to treat transverse patellar fracture.

**Surgical Technique:** Under either general anesthesia or spinal or epidural analgesia, the patients were placed in a supine position on a standard radiolucent operating table with the knee in full extension. Pneumatic tourniquet was applied to the upper thigh and inflated to control.

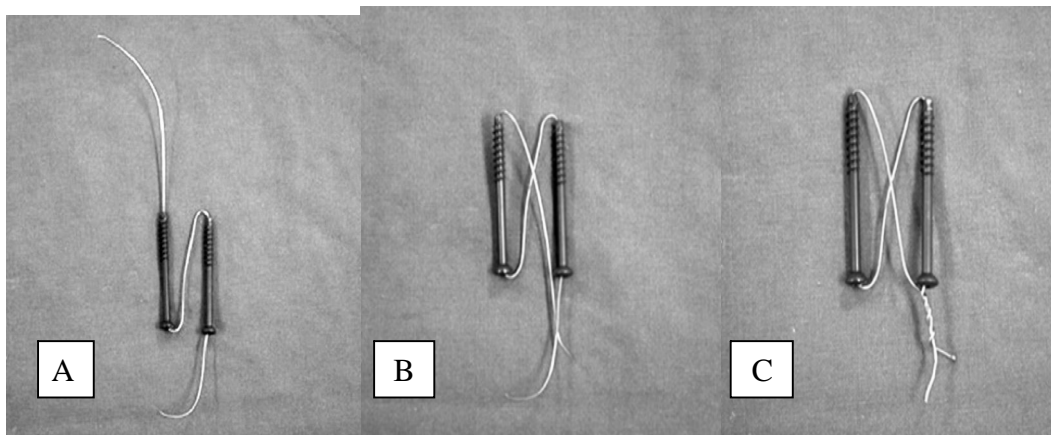
At first, 2 minimal 15-20 mm skin incisions were made on patellar upper and lower pole area (Fig.1-A). Through two skin incision, entrapped soft tissue or hematoma were removed with curette. Under C-arm image intensifier control, the upper pole of the proximal fragment and the lower pole of the distal fragment were identified by palpation and then confirmed with fluoroscopy and then the fracture was anatomically reduced by manipulation and maintained by a patellar reduction clamp applied through skin incisions percutaneously. Thereafter, two Kirschner wires (K-wires) were drilled longitudinally perpendicular to the fracture line from lower pole to upper pole of patella (Fig.1-B). And then adequate sized two half threaded 4.0 mm cannulated screws inserted through the K-wire. Next step is modified tension band wiring through screw's cannals (Cho, 2013).



**Figure (1-A):** Photograph showed 2 minimal 15 mm skin incisions were made on patellar upper and lower pole area on left knee. **(1-B):** Fracture was reduced by manipulation and maintained by a patellar reduction clamp applied through skin incisions percutaneously. Thereafter, two Kirschner wires were drilled longitudinally perpendicular to the fracture line from lower pole to upper pole of patella on left knee (Cho, 2013)

At first, 0.97 mm (18G, No7) rolled wire was inserted into lateral cannulated screw from head side to tail side and then pulled out percutaneously toward medial screw head side. At second, this wire tip inserted into medial screw from head to tail side (Fig.2-A) and then pulled out percutaneously toward lateral screw head side (Fig.2-B). Finally, wire's tips were twisted between both screw's head sides.

A wire was then placed in a “figure of butterfly” configuration shape with cannulated screws (Fig.2-C). Stability of reduction and fixation was checked with image intensifier by flexing and extending the knee. After routine suture of subcutaneous tissue and skin, cylinder splint applied with extended knee position fully (Cho, 2013).



**Figure (2-A):** Schematic photograph showed rolled wire was inserted into lateral cannulated screw from head side to tail side and then pulled out percutaneously toward medial screw head side. At second, this wire tip inserted into medial screw from head to tail side. **(2-B):** Pulled out percutaneously toward lateral screw head side. **(2-C):** Wire's tips were twisted between both screw's head sides in a “figure of butterfly” configuration (Cho, 2013).

### **Percutaneous patellar osteosynthesis system (PPOS Surgical Technique):**

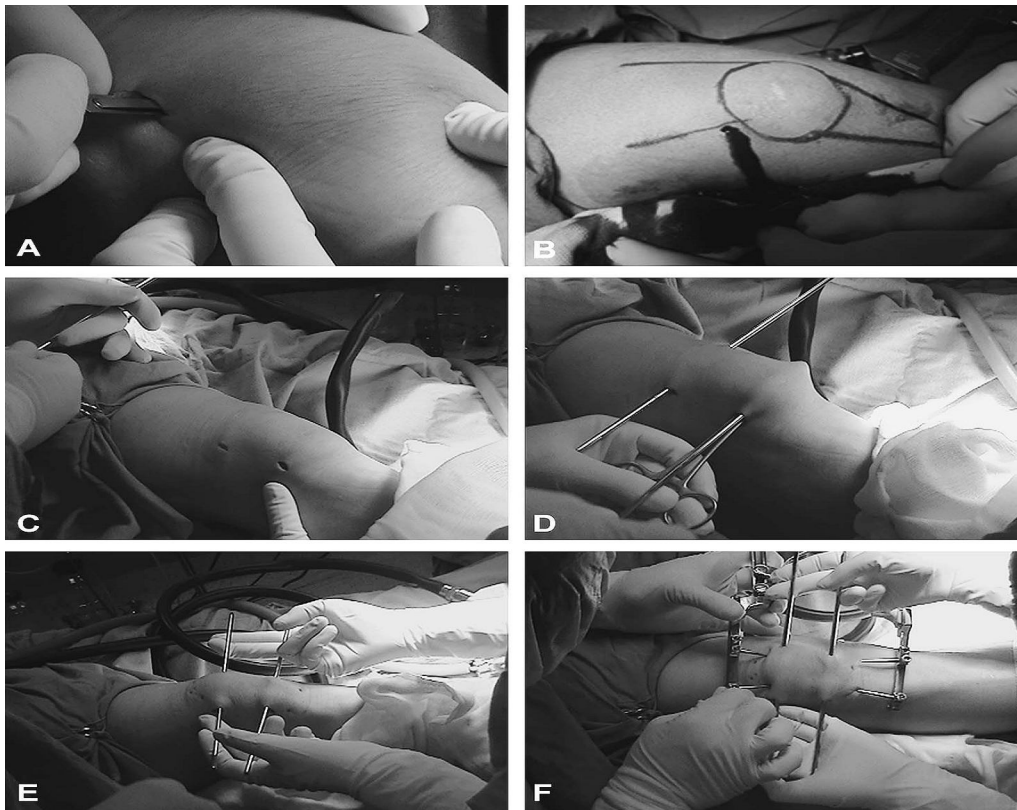
All surgical interventions in the PPOS group were performed by the same two surgeons. The patient was placed in the supine position under spinal anesthesia. After preparation and draping, a non-sterilized pneumatic tourniquet was inflated to  $250 \pm 30$  mm Hg. An incision of  $5 \pm 2$  mm was then made at the superior-lateral border of the patella to reach the intra capsular region through a

superior-lateral portal (Fig.3-A), using that incision initially to drain the intra-articular hematoma (Fig.3-B).

A similar incision was performed at the level of the lateral patellar border and the lower pole, which constituted the inferior-lateral portal (Fig.3-C). Two guided 4.0-mm Steinman pins were introduced through the quadriceps and patellar tendons with the medial skin exit site constituting the superior-medial and inferior-medial portals (Fig3-D). The

limb was then placed in extension, and reduction of the fragments was accomplished by manipulating the pins (Fig.3-E). When the fragments were reduced, the PPOS was placed by means

of its four fixation points through the lateral and medial portals and under the Steinman pins (Fig.3-F) (Luna-Pizarro *et al.*, 2006).



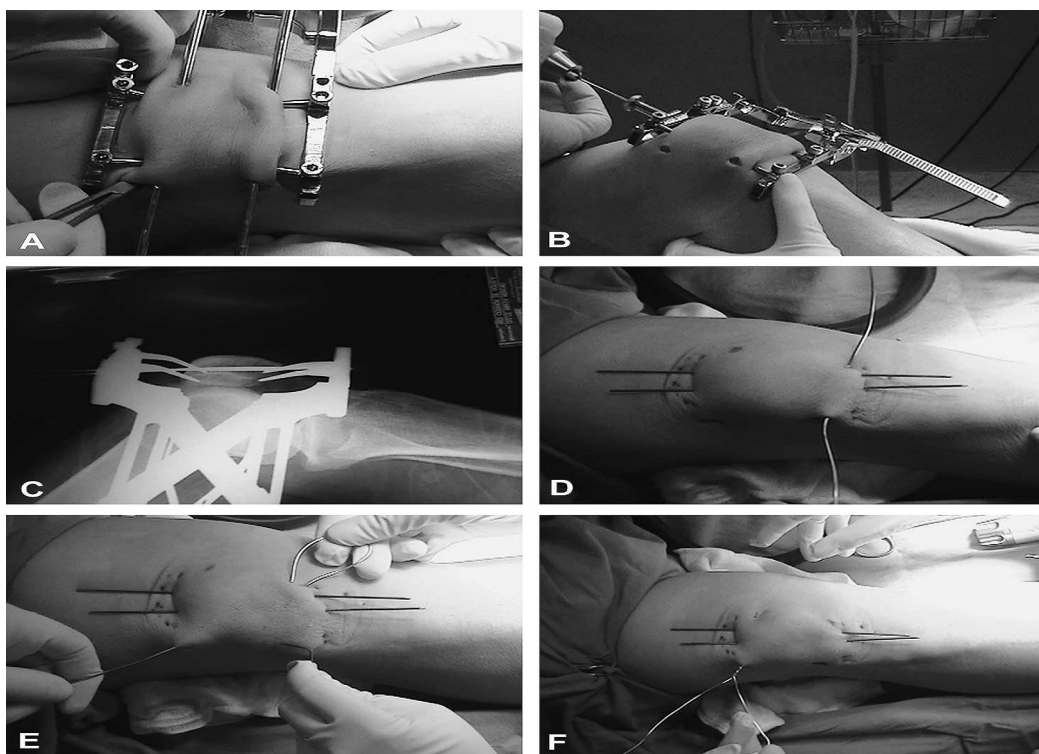
**Figure (3-A):** A superior–lateralportal was created through an incisionof 2 mm. **(3-B):** Drainage of the intra-articular hematoma. **(3-C):** The inferior–lateral portal was created on the lateral patellar border and the lower pole. **(3-D):** Steinman pins were placed through the quadriceps and patellar tendons using the superior–lateral and inferior– lateral portals as starting points. **(3-E):** Fragments were reduced by manipulation of the pins. **(3-F):** The percutaneous patellar osteosynthesis system was placed under the Steinman pins (Luna-Pizarro *et al.*, 2006).

The system was closed by manual compression to maintain the stability of the fragments A hemostat clamp was then introduced through the superior–lateral portal to verify surface articular congruence (Fig.4-A). When articular congruence was considered satisfactory, the Steinman pins were removed and the knee was placed in 30 or40 degrees of

flexion. Two vertically oriented parallel 1.5-mmK-wires were then placed p.c through the sliding guides of the system through the patellar fracture and the fragments from proximal to distal (Fig.4-B). K-wire placements and articular congruence were then verified by plain x-rays (Fig.4-C), and the PPOS was removed. A wire was then placed in a

“figure of-eight” configuration by introducing a 1.2 wire through the inferior–lateral portal toward the inferior–medial portal under the K-wires (Fig.4-D) The knee was then placed in extension, and the wire was reintroduced through the inferior–medial portal toward the superior–lateral portal (Fig.4-E). The knee was again extended, and the wire was reintroduced through the inferior–

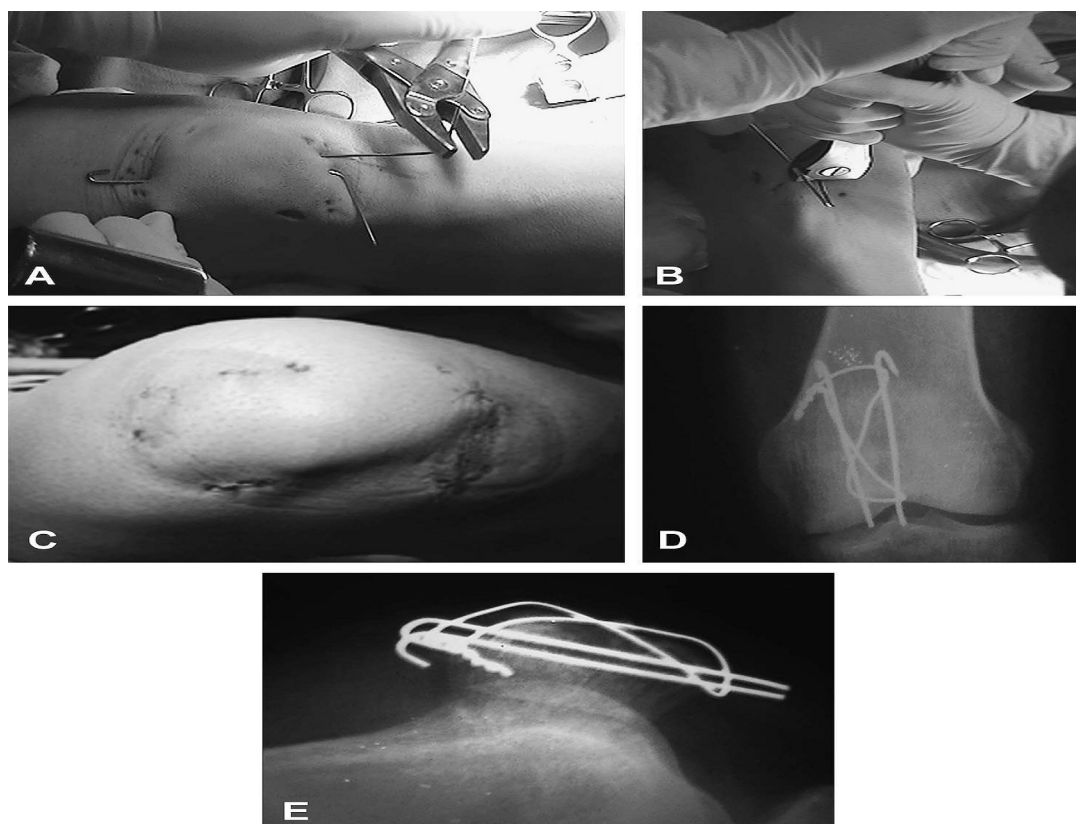
lateral portal toward the superior–medial portal under the skin and over the patella. The knee was again placed in flexion, and the wire was reintroduced through the superior–medial portal toward the superior–lateral portal under the K-wires, closing with a sac. Twist-tight knot touching the bone surface (Fig.4-F) (Luna-Pizarro et al., 2006).



**Figure (4):** The percutaneous patellar osteosynthesis system (PPOS) was closed by manual compression. (4-A) Haemostatic clamp was introduced to verify articular surface congruence. (4-B) Kirschner wires (K-wires) were placed percutaneously through the sliding guides of the PPOS from proximal to distal. (4-C) Articular congruence was verified by radiography. (4-D) A 1.2 wire was introduced through the inferior–lateral portal toward the inferior–medial portal. (4-E) The wire was reintroduced through the inferior–medial portal toward the superior–lateral portal. (4-F) The “figure-of-eight” configuration was completed by reintroducing the wire through the inferior–lateral portal toward the superior–medial portal under the skin and over the patella, then the wire was reintroduced through the superior–medial portal toward the superior–lateral portal under the K-wires and closed with a subcutaneous (s.c.) twist-tight knot (Luna-Pizarro et al., 2006)

K-wires were bent proximally to form a hook and interiorized subcutaneous (s.c.) by distal traction until the hooks touched the bone surface (Fig.5-A). The K-wires were then cut at the distal end, with the knee in maximal flexion (Fig.5-B). The four portals were closed with non

absorbable suture (Fig.5-C). Placement of the K-wires and the tension-band placement were verified by anteroposterior (AP) (Fig.5-D) and lateral (Fig.5-E) x-ray view. A Jones dressing was left in place (Luna-Pizarro *et al.*, 2006).



**Figure (5-A):** Kirschner wires (Kwires ) were bent proximally to forma hook and interiorized subcutaneous (sac) by distal traction. **(5-B):** The Kwires were cut at the distal end. **(5-C):** The four portals were closed with no absorbable suture. **(5-D):** Anteroposterior (AP) x-ray view of the tension band. **(5-E):** Lateral x-ray view of the tension band (Luna-Pizarro *et al.*, 2006).

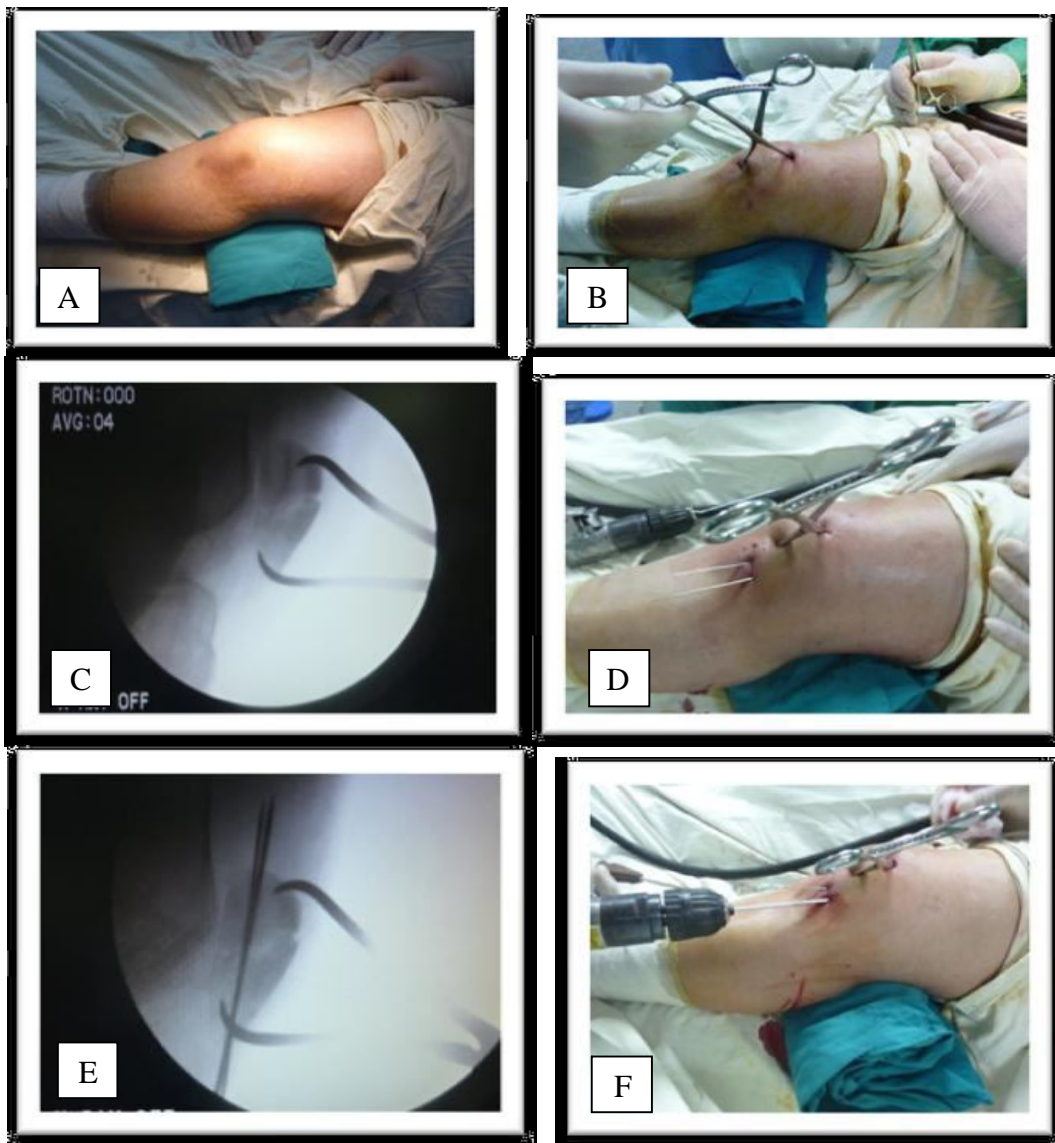
#### **Closed reduction and percutaneous cannulated screw fixation:**

All surgical interventions were performed by the same surgeons following the same steps of the procedure; patient is lying supine under anesthesia 12 patients under spinal and 2 under general anesthesia, after preparation and regular

draping, inflation of non sterile pneumatic tourniquet  $250 \pm 30$ Hg, flexion of the affected knee about 150 using folded towel under the knee to aid in reduction and use of image intensifier, a wide bore needle was inserted at the Parapatellar gutter to aspirate the knee from hemarthrosis which may be an obstacle for reduction (Elghaffar *et al.*, 2012).

Closed reduction was made using patellar clamp with its upper blade at the superior patellar border and inferior blade at the inferior pole and the reduction was checked by fluoroscopy both antero-posterior and lateral views. 6 patellae needed more reduction and manipulation, a transverse K-wire 2mm is inserted in the

larger patellar fragment transversally to use it as a joystick to aid in the manipulation of the fracture. Once reduction was achieved both patellar fragments were compressed by patellar clamp and reduction is checked again (Fig 6.) (Elghaffar et al., 2012).



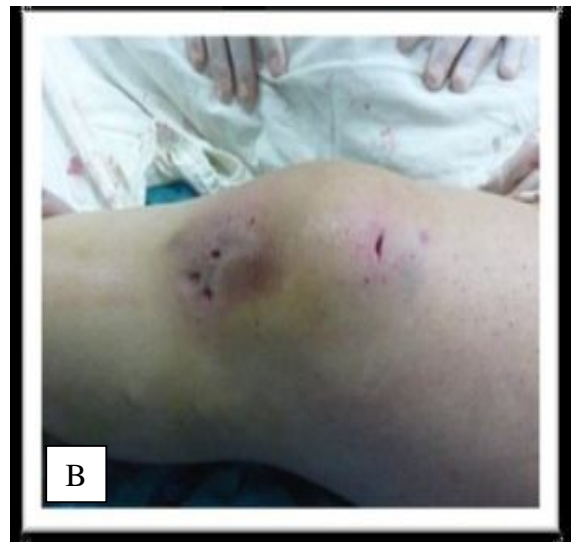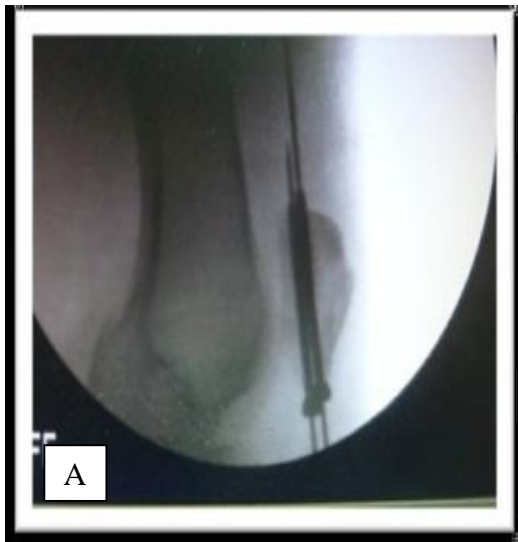**Figure (6-A):** Patient position, **(6-B):** reduction by patellar clamp under fluoroscopy control, **(6-C):** Articular congruence was verified by radiography, **(6-D):** insertion of 2 guide wire from inferior portals, **(6-E):** radiograph after guide wires insertion, and **(6-F):** 2.7mm cannulated drill bit over guide wire (Elghaffar et al., 2012).



Two incisions  $5\pm 2\text{mm}$  were made at the superior border of the patella  $2\text{ cm}\pm 5\text{mm}$  apart from each other as guide wires portals. A guide wire  $0.9\text{mm}$  was inserted from upper pole of the patella into the proximal fragment directed distally as much closer to articular surface of the patella and its position checked by fluoroscopy (**Elghaffar et al., 2012**).

Second K-wire was inserted from upper pole also closer to the other patellar superior pole and  $2\text{cm}\pm 5\text{mm}$  apart from the first guide wire according to size of the patella. Finally both wires positions were checked by fluoroscopy. Only in the first two cases guide wires were inserted from distal patellar fragments to proximal

one and this maneuver was replaced by the mentioned maneuver being safer for patellar ligament and easier in insertion of guide wires. Then a cannulated drill bit  $2.7\text{mm}$  was inserted over guide wires taking care to not to cross the far cortex of the patella, depth gauge is then inserted to determine the screws length, and finally 2 cannulated  $4\text{mm}$  partially threaded self-tapping screws are inserted over the guide wires using cannulated screw driver. Placement and final position was verified by anteroposterior (AP) and lateral (LAT) radiograph in both knee flexion and extension with the incision are then closed by suture (**fig.7-Elghaffar et al., 2012**).



**Figure (7-A):** LAT view x-ray after screws insertion, **(7-B):** skin wounds (**Elghaffar et al., 2012**).

In conclusion closed percutaneous screws fixation in patellar fracture carry many advantage regarding less operative time, postoperative Pain, preservation of blood supply and better cosmesis but patient selection is of paramount importance because open repair of

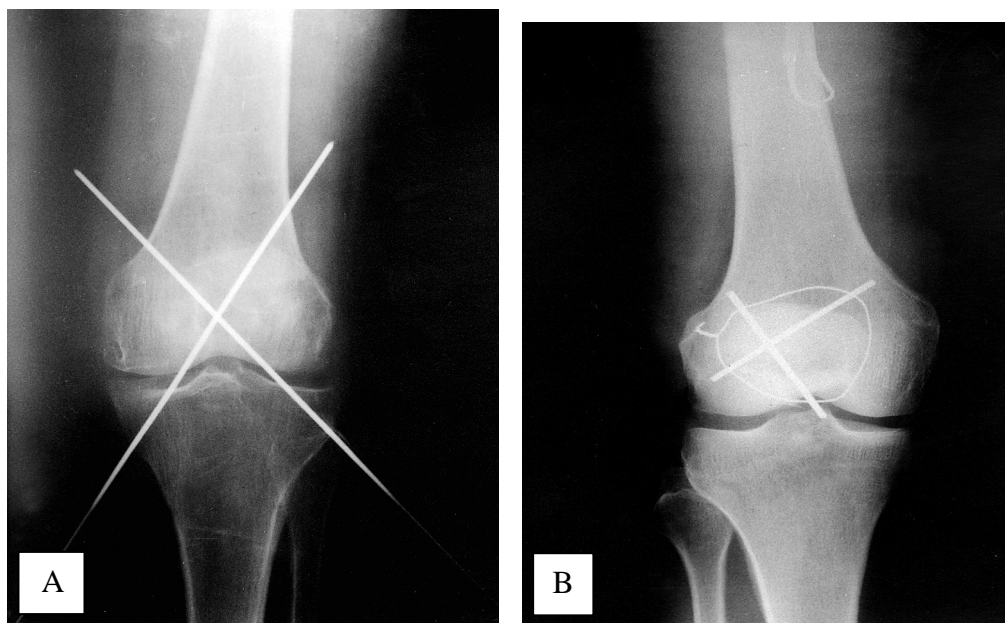
extensor mechanism may be necessary in patient with major fracture separation and addition of tension band through screws holes percutaneously may be added in osteopenic patient with weak screw purchase (**Elghaffar et al., 2012**).



**Arthroscopic-Assisted Percutaneous Stabilization of Patellar Fractures:**

The patients were placed in the supine position on the operating table with the leg prepared in full extension. A standard inferolateral arthroscopic portal was made and hemarthrosis and clots were evacuated from the joint until the fracture was visualized. The fracture then was reduced by manipulation and by towel clips that were applied percutaneously. Reduction was checked by arthroscopy and by c-arm fluoroscopy. Three stab incisions were made at the superolateral, superomedial, and inferomedial corners of the patella and two Kirschner (K) wires were driven from superolateral to inferomedial, and from superomedial to inferolateral incisions (Fig 8-A-**El-Sayed and Ragab, 2009**).

A cerclage wire then was inserted from the superolateral incision, with the aid of a straight needle, and advanced medially and taken out of the skin from the superomedial incision. The needle was reinserted from the superomedial incision and taken out from the inferomedial incision. The procedure was repeated by placing the wire circumferentially around the patella until the end of the wire was taken out from the superolateral incision. The cerclage wire was tightened circumferentially around the patella. After checking the reduction by arthroscopy and fluoroscopy, both ends of the wire were twisted several times and the remaining ends of the wire and the K wires were resected and the stump of the cerclage wire was buried in the subcutaneous tissue (Fig 8-B-**El-Sayed and Ragab, 2009**).



**Figure (8-A):** Radiograph showing placement of the K wires, **(8-B):** Stabilization maintained by a circumferential wire loop is shown. The ends of the K wires were removed (**El-Sayed and Ragab, 2009**).

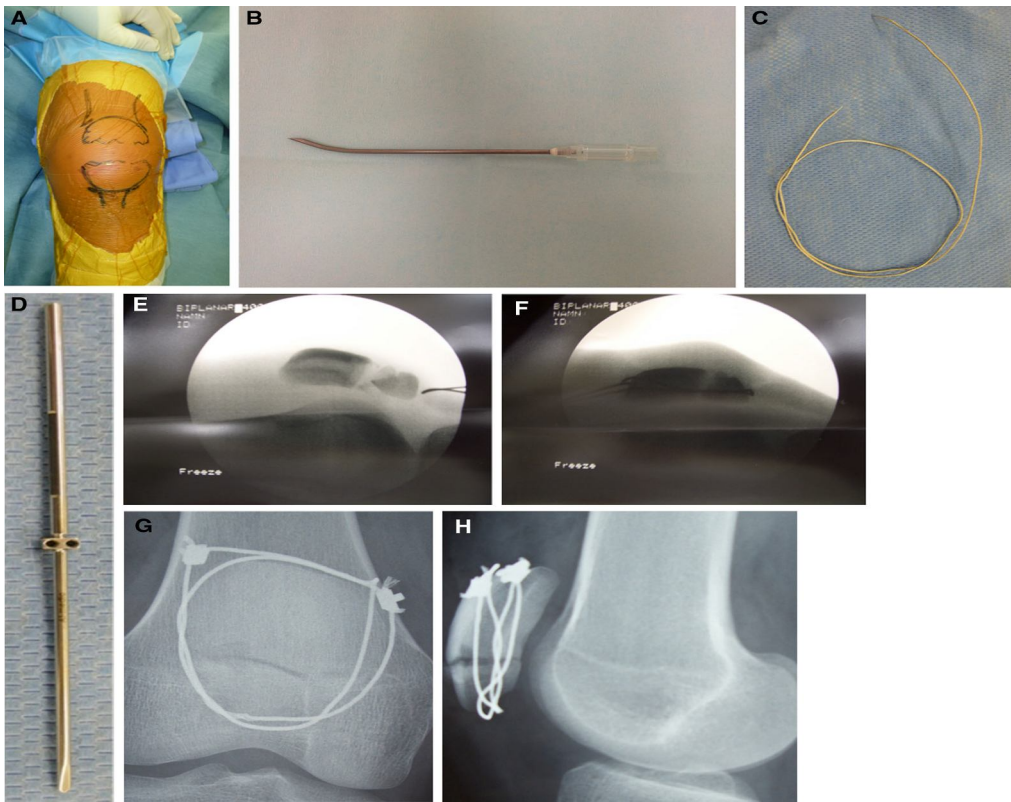
When the inferior portion of the patella was comminuted, the towel clips were not used and the arthroscope was advanced to the suprapatellar pouch under the patella. Reduction was achieved and maintained by the arthroscope throughout the procedure. In fractures of the inferior pole, a transpatellar arthroscopic portal was used rather than the standard inferolateral arthroscopic portal. If the comminution was distal to the articular surface of the patella, then no attempt was made for reduction. Bony fragments were kept together without damage to the soft tissue envelope (El-Sayed and Ragab, 2009).

#### **Percutaneous cerclage wiring for the surgical treatment of displaced patella fractures:**

Surgery was performed under spinal anaesthesia and in the supine position with slight flexion of the knee joint. Ten millimetre and 5-mm medio-lateral skin incisions were made at the superior and inferior margins of the patella, respectively (Fig. 9-A). The tip of the inner tube cannula was bent and used as a cable passer (Fig. 9-B). For the cable, the AI-wiring system was used (Fig. 9-C,D). Firstly, the cable passer was inserted into

the patellar tendon through the skin incision at the inferior margin, followed by the passage of the cable (Fig. 9-E). The cable was passed around the patella including the soft tissues, penetrating through the quadriceps femoris tendon proximally, and then passed along the superior margin of the patella (Fig. 9-F). This cable wiring was applied in each of the superficial and deep layers (Fig. 9-G,H-Matsuo *et al.*, 2014).

On realignment of the patello femoral joint, congruency of the patella to the knee joint was confirmed by bending and extending it. Tension was applied using a cable tensioner to lock the sleeve. Post-operatively, range-of motion training of the knee joint was initiated on the day following surgery and limited by the patient's comfort. In addition, full weight-bearing with the knee joint held in extension was permitted. The range of motion of the knee joint at the final follow up, time required to bone union on plain X-ray radiography, X-ray features of osteoarthritis of the patello femoral joint and complications were recorded (Matsuo *et al.*, 2014).



**Figure (9-A):** Ten-millimetre and 5-mm small mediolateral skin incisions at the superior and inferior margins of the patella, respectively, **(9-B):** The tip of the inner tube of a Sur-flo was bent and used as a cable passer, **(9-C):** Cable, **(9-D):** sleeve: for these, the AI-wiring system was used, **(9-E):** The cable passer was inserted into the patellar tendon through the skin incision at the inferior margin of the patella, **(9-F):** The cable was applied around the patella including the soft tissues, penetrating through the quadriceps femoris tendon on the proximal side, and then passed along the superior margin of the patella, **(9-G):** Frontal view after fixation on plain X-ray radiography and **(9-H):** lateral view after fixation on plain X-ray radiography: two cable wires were passed through the shallow and deep layers, respectively (Matsuo et al., 2014).

## Rehabilitation:

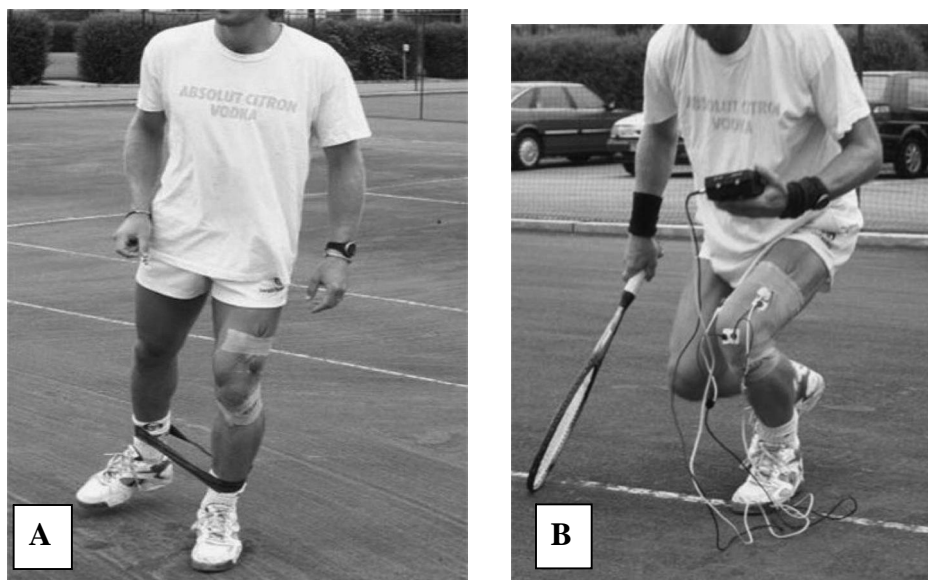
### Stretching tight soft tissue structures:

The deep lateral retinacular structures may require stretching, which can be done in side lying. The anterior hip structures are usually tight as these individuals often have anteverted femurs. These structures may be stretched in a “figure-of-four” position in prone (McConnell, 2007).

**Muscle training:** Individuals with patello femoral instability need to up-train the

VMO and the gluteal musculature to improve the dynamic stability of the patello femoral joint (fig. 10-A,B) (McConnell, 2007).

**Improving proximal control:** Training the gluteal musculature to improve stance phase of gait is required to decrease the lack of femoral control in weight-bearing and improve the stability of the lower extremity (McConnell, 2007).



**Figure (10-A): Training the gluteals using elasticized band, VL. (10-B): Functional training of the quadriceps (McConnell, 2007).**

## SUMMARY

Open repair of displaced patellar fractures is still the most widely used technique and can offer satisfactory results (Wright et al., 2009). However, complications associated with open treatment such as infection, delayed wound healing, broken wires, irritation, immigration of Kirschner wires, fixation failure, and revision were reported with different frequencies between 7% and 43% (Lebrun et al., 2012). These complications were related with open approach, fixation device, or both. Displaced transverse patellar fractures are easier for anatomic reduction by closed manipulation and potential candidates for percutaneous osteosynthesis. Less invasive technique with percutaneous fixation may reduce postoperative wound complications and the possibility of delayed operation. However, there is paucity of research in this field. There

were a few articles describing techniques using closed methods for patellar fractures (Luna-Pizarro et al., 2006).

However, they were not often indicated for significantly displaced transverse patellar fractures or these fixation methods were not considered to be as rigid as traditional tension band methods. In a recent study, we reported a minimally invasive technique with figure-eight wiring through two parallel cannulated screws under arthroscopy and fluoroscopy assistances (Lebrun et al., 2012).

Percutaneous surgical techniques preserve the vascular supply of patellar fragments, which may improve fracture consolidation. However, this treatment is technically demanding and not applicable to all fracture patterns. This technique combines the advantages of minimal invasive surgery and rigid internal fixation, thereby permitting early

rehabilitation and good functional outcome (**Tian et al., 2011**)

The objective of the present study was to assess the closed reduction and percutaneous cannulated screw fixation in patellar fractures by the aid of fluoroscopy as a method of patellar fracture fixation regarding its postoperative pain, surgical time, knee-joint function in the postoperative period and complications (**Melvin and Mehta, 2011**).

To improve fracture consolidation, many techniques were designed to achieve this goal, percutaneous screws or tension band wiring using special devices like percutaneous patellar osteosynthesis system (PPOS) technique (**Tian et al., 2011**).

## CONCLUSION

Patella fractures represent a broad spectrum of injuries ranging from subtle non-displaced fractures to open comminuted fractures with significant bone loss. Treatment should be directed to obtaining an anatomic reduction and using a fixation method that maximizes stability while minimizing hardware prominence. Surgeons should select fixation techniques that best address the fracture pattern being treated, as there is little high-quality evidence comparing treatment methods. Despite all of the advances in surgical treatment options, functional impairment, pain, and decreased quadriceps strength and endurance persist to 12 months postoperatively and beyond. Knee joint mobilization and range of motion as early as fixation stability permits will help to minimize post traumatic arthritis and allow optimal postoperative recovery.

## REFERENCES

1. **Cho, J. H. (2013):** Percutaneous cannulated screws with tension band wiring technique in patella fractures. *Knee Surgery & Related Research*, 25(4): 215-219.
2. **Elghaffar, T. M. A., Elgheet, H. A. A. and Zayed, F. H. (2012):** closed reduction and percutaneous cannulated screw fixation in patellar fracture. *Al-Azhar Assiut Medical Journal*, 10(2): 15-19.
3. **El-Sayed, A. M. M. and Ragab, R. K. I. (2009):** Arthroscopic-assisted reduction and stabilization of transverse fractures of the patella. *The Knee*, 16(1): 54-57.
4. **Lebrun, C. T., Langford, J. R. and Sagi, H. C. (2012):** Functional outcomes after operatively treated patella fractures. *Journal of Orthopaedic Trauma*, 26(7): 422-426.
5. **Luna-Pizarro D, Amato D, Arellano F, Hernandez A and Lopez-Rojas P. (2006):** Comparison of a technique using a new percutaneous osteosynthesis device with conventional open surgery for displaced patella fractures in a randomized controlled trial. *J Orthop Trauma*, 20:529e35.
6. **Matsuo, T., Watari, T., Naito, K., Mogami, A., Kaneko, K. and Obayashi, O. (2014):** Percutaneous cerclage wiring for the surgical treatment of displaced patella fractures. *Strategies in Trauma and Limb Reconstruction*, 9(1): 19-23.
7. **McConnell, J. (2007):** Rehabilitation and nonoperative treatment of patellar instability. *Sports Medicine and Arthroscopy Review*, 15(2): 95-104.
8. **Melvin JS and Mehta S (2011):** Patella fractures in adults. *J Am Acad Orthop Surg*. 19:198–207.
9. **Tian, Y., Zhou, F., Ji, H., Zhang, Z. and Guo, Y. (2011):** Cannulated screw and cable are superior to modified tension band in the treatment of transverse patella fractures. *Clinical Orthopaedics and Related Research*, 469(12): 3429-3435.
10. **Wright, P. B., Kosmopoulos, V., Cote, R. E., Tayag, T. J. and Nana, A. D. (2009):** FiberWire is superior in strength to stainless steel wire for tension band fixation of transverse patellar fractures. *Injury*, 40(11): 1200-1203.

## تثبيت كسور عظمة الرضفة عن طريق الجلد

محمد صلاح عبد الحفيظ - محمد عبد المنعم نجم - تامر محمد عبد العظيم

قسم جراحة العظام- كلية الطب- جامعة الأزهر

لا يزال الإصلاح المفتوح من كسور الرضفة المتحركة الأكثر استخداماً على نطاق واسع، ويمكن أن تقدم نتائج مرضية. ومع ذلك، فقد اكتشفت المضاعفات المرتبطة بهذه التقنية مثل العدوى، وتأخر إلتئام الجروح، وأسلاك مقطوعة، وتهيج وهجرة الأسلاك المعدنية، وفشل التثبيت، واحتمال إعادة هذه الحالات ما بين ٧٪ و ٤٣٪. وترتبط هذه المضاعفات مع تقنية الإصلاح المفتوح، وجهاز التثبيت، أو كليهما. وكسور الرضفة المتحركة العرضية أفضل من الناحية التشريحية. الإصلاح عن طريق الرد المغلق وتثبيت طرفي العظم عن طريق الجلد، وتقنية أقل في فتح الجلد مع تثبيت عن طريق الجلد مما قد يقلل من مضاعفات الجرح بعد العملية الجراحية وأيضاً يعطي تثبيتاً قوياً.

وتحافظ التقنيات الجراحية عن طريق الجلد على إمدادات الغذاء لأجزاء الرضفة، والتي قد تؤدي إلى تحسين توحيد الكسر. وهذا الأسلوب من التثبيت يجمع بين مزايا جراحة التدخل المحدود من فتح الجلد و التثبيت الداخلي القوي، مما يسمح للتأهيل المبكر و نتائج وظيفية جيدة.

وقد صممت العديد من التقنيات لتحسين توحيد كسر الرضفة باستخدام أجهزة خاصة مثل تقنية النظام الرضفي وتثبيت طرفي العظم.

والتقنيات المستخدمة لتثبيت كسور عظمة الرضفة عن طريق الجلد هي:

- الرد المغلق وتثبيت الكسر عن طريق الجلد بواسطة تقنية النظام الرضفي لتثبيت طرفي العظم.
- استخدام المنظار الجراحي كوسيلة لتثبيت كسور الرضفة.
- تثبيت كسور الرضفة عن طريق الجلد بواسطة المسامير المجوفة.