

Comparison of Two Percutaneous Approaches in Varicocele Embolization: Study of Complications, Radiations and Recurrence Rate

MOHAMED MAGDY EL-RAKHAWY, M.D.

The Department of Radiodiagnosis, Faculty of Medicine, Mansoura University, Egypt

Abstract

Background: In this retrospective study, we will compare two approaches in percutaneous embolization of varicocele, right common femoral vein access and right internal jugular vein access, we will compare technical success, complications and recurrence rate.

Aim of the Study: This study constructed, to compare two percutaneous access routes in varicocele embolization, the transfemoral and the jugular routes. It was a comparison of complications, radiations and recurrence rates.

Patients and Methods: This study was retrospective study of the records of 34 male patients with clinically and radiologically proved varicocele who were treated by percutaneous embolization, in the period from 2014 to 2016. They included two groups, Group I (17 patients) treated using the transfemoral route and Group II (17 patients) treated using jugular route. The embolic materials used included, coils (14 patients), N-butyl-2-cyanoacrylate (12 patients) and sclerosing agents or polidocanol in 8 patients. The catheters used were cobra head-5-Fr, Bern 4Fr and microcatheter (progreat 2,7F). The complications, time of radiation, technical success and recurrence were compared in both groups.

Results: In Group I (percutaneous transfemoral route), there was failure of catheterization of right internal spermatic vein in one patient due to acute angle, while in Group II there was successful catheterization of left and right internal spermatic vein in all (17 patients). Also, post-procedural pain was seen in 3 patients in Group I and in 2 patients in Group II. Contrast extravasation was seen in one patient in Group I, groin hematoma in 2 patients, glue migration in one patient and recurrence in 2 patients, while in Group II no vein injury, no hematoma or glue migration and recurrence was seen in one patient only. The mean procedure time and the fluoroscope time were longer in Group I as compared to Group II. In Group I the mean procedure time was 52 minutes and fluoroscopy time was 23 minutes while in Group II. They were 40 minutes and 15 minutes respectively.

Correspondence to: Dr. Mohamed Magdy El-Rakhawy, The Department of Radiodiagnosis, Faculty of Medicine, Mansoura University, Egypt

Conclusion: Percutaneous embolization of varicocele is relatively safe technique and has high success rate. The percutaneous transjugular route is easy for catheterization of both right and left internal spermatic vein, while for left sided varicocele, the right common femoral vein access is easy and safe. The transjugular route has less complications, less radiation time and low recurrence rate.

Key Words: Varicocele embolization – Radiations – Recurrence rate.

Introduction

VARICOCELE is defined as the presence of dilated tortuous veins in the spermatic cord extending around the superior, posterior and inferior aspects of the testicles. It is seen approximately in 15% of men, 35% of men with primary infertility and in about 80% of men with secondary infertility [1,2].

Several options are used for treatment of varicocele, the commonest surgical ligation of internal spermatic vein either by open surgical ligation or laparoscopic ligation. The second modality of treatment, through percutaneous embolization of internal spermatic vein [3]. The percutaneous vascular accesses, include, right common femoral vein, left common femoral vein, internal jugular vein or basilic vein approach [3].

Patients and Methods

This retrospective study included, review of the records of 34 male patients with bilateral varicocele, treated by percutaneous embolization in vascular and Interventional Unit, Mansoura University Hospital, Mansoura Egypt in the period from July 1996 to May 2016. Their ages ranged from 18 to 45 years of age (mean age of 32 years). All patients were treated for infertility, 20 patients

for primary infertility and 14 patients for secondary infertility.

Patients were classified into two groups, Group I: Included 17 male patients treated by using right common femoral vein as a vascular access, while in Group II: The internal jugular vein as a vascular access for varicocele embolization.

Local anaesthesia was used in both groups, using 5-10ml of xylocain (Lidocaine hydrochloride 2%). No sedation or general anaesthesia was used in both groups. After puncture of the groin or neck a 6-F sheath was secured, then 5-Fr cobra-head catheter or 4Fr Bern (Cook, Europe Bjaeverskov, Denmark) was introduced over 0.32 and 0.35 Terumo J-shape guide-wire. Then catheterization of either the right or left internal spermatic vein was performed, then a pre-embolization angiogram was obtained with the patient using Valsalva maneuver. Reflux or insufficiency was documented by retrograde opacification of the spermatic vein and pampiniform plexus of veins A2.7 Fr. microcatheter (Terumo-progreat, interventional system, Japan) was used in 20 patients.

In Group I & II (17 patients in every group), the embolization was performed using mechanical agents (coils) in 14 patients, gluing agent-N-butyl-2-cyanocrylate (NBCA-MS) or Glubran 2-vrareggio-Italy) was used in 12 patients, and lastly embolization procedure was performed using a sclerosing agent or polidocanol 2% (Aetoxyscleral-Kreussler-Pharma, Paris, France) was used in 8 patients in every group.

In patients treated by gluing agent (Glubran), the dead-space of the catheter was filled with an anionic solution as dextrose 5% to avoid intracatheter glue polymerization followed by rapid injection of 5ml of dextrose 5% also, then rapid withdrawal of the catheter.

The choice of the embolic agents depends on two factors, the available embolic agent in the vascular and interventional unit, as well as on the operator preference and experience.

Then after varicocele embolization a post-embolization venogram for the embolized side was performed for assessment of the success of embolization procedure. Then patients were observed for 4 hours after the procedure, then patients were discharged from the unit as the procedure is considered as an out-patient procedure.

Results

This retrospective study included 34 patients with technically successful varicocele embolization, no major complications were seen in both groups. Minor complications were seen in 8 patients in the Group I (transfemoral route) and only in 2 patients of Group II (jugular route). Minor complications of the first group include testicular pain in two patients, vein lesion in the form of contrast extravasation in one patient, and it was self-limiting lesion and did not require treatment, temporary groin hematoma was observed in two patients and treated by compression for 15 minutes and then resolved, glue migration was observed in one patient as glue migrated during withdrawal of the progreat catheter to the left renal vein up to its junction with the IVC. In Group II only two patients experienced post-procedural testicular pain. No hematomas were observed nor glue-migration or vein injury.

No pampiniform plexus phlebitis was observed in both groups. No coil migration in both groups. No testicular loss also in both groups.

In Group I: Successful embolization of 33 spermatic veins was performed (17 left internal spermatic vein and 16 right internal spermatic vein), while in one patient catheterization of the right spermatic vein was very difficult and failed due to acute angle between this right internal spermatic vein and IVC, while in Group II (transjugular route) there was successful embolization of 34 spermatic veins (17 right and 17 left), there was no technical failure.

As regards to the radiation time it was more in Group I (femoral route) because the mean procedure time was 52 minutes, while in the Group II (transjugular route) the procedure time was shorter about 40 minutes. Also the mean fluoroscopy time in the first group was 23 minutes and in the second group it was 15 minutes. This is due to repeated trails to catheterize the right internal spermatic vein, which is usually difficult through the transfemoral approach.

Recurrence of varicocele was evaluated after 6 months using color-Doppler flow imaging for the scrotum. In Group I recurrence was documented by color-Doppler in two patients and in Group II in only one patient, where recurrent grade 2 varicocele of the left side of their scrotum was documented.

The fertility data were not assessed as is not the aim of this work.

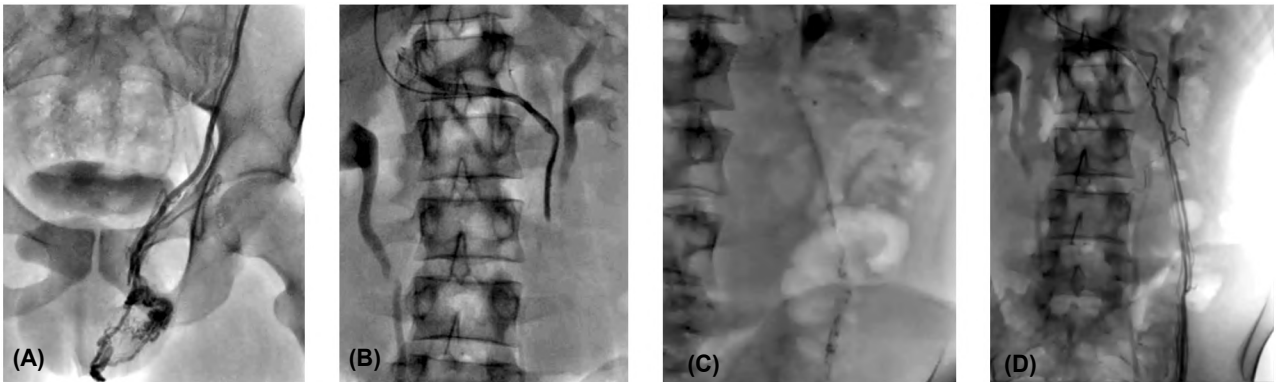


Fig. (1): A case of left side varicocele treated by transjugular route. (A) Initial angiogram shows the left renal vein and spermatic vein origin. (B) Left spermatic vein angiogram shows dilated left scrotal veins. (C) Left spermatic vein angiogram shows collaterals related to the proximal part. (D) Post embolization image show dense NBCA along the left spermatic vein up to the collaterals level.

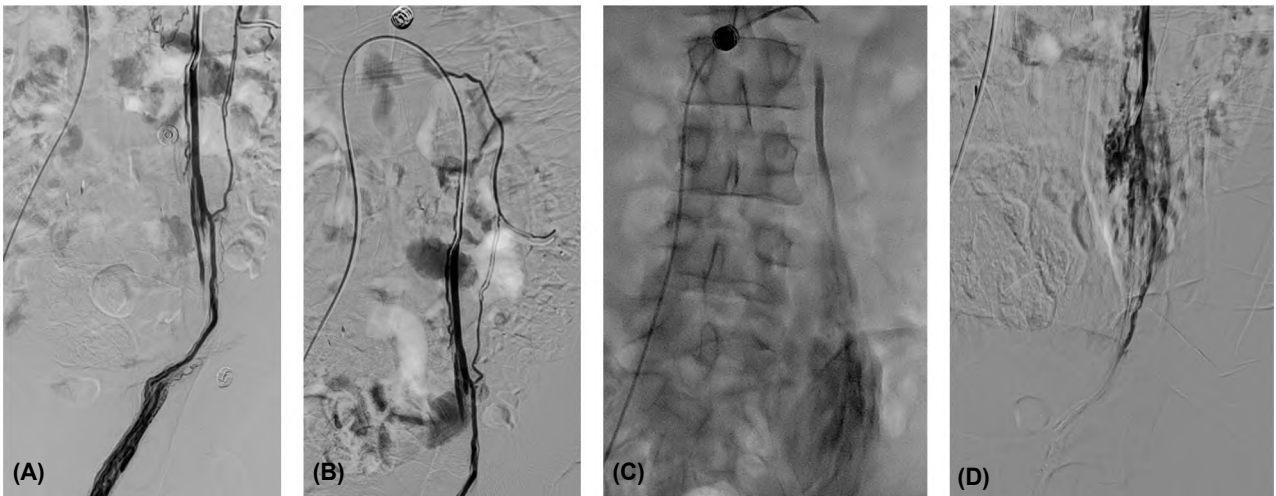


Fig. (2): A case of left side varicocele treated by transfemoral route. (A,B) Left spermatic vein angiograms show dilated veins with collaterals related to the proximal and distal parts. (C) Left spermatic vein angiogram show contrast leak within small hematoma at the mid-portion of the spermatic vein (D) Post embolization image show dense NBCA along the left spermatic vein at the level of hematoma and up to the collaterals level.

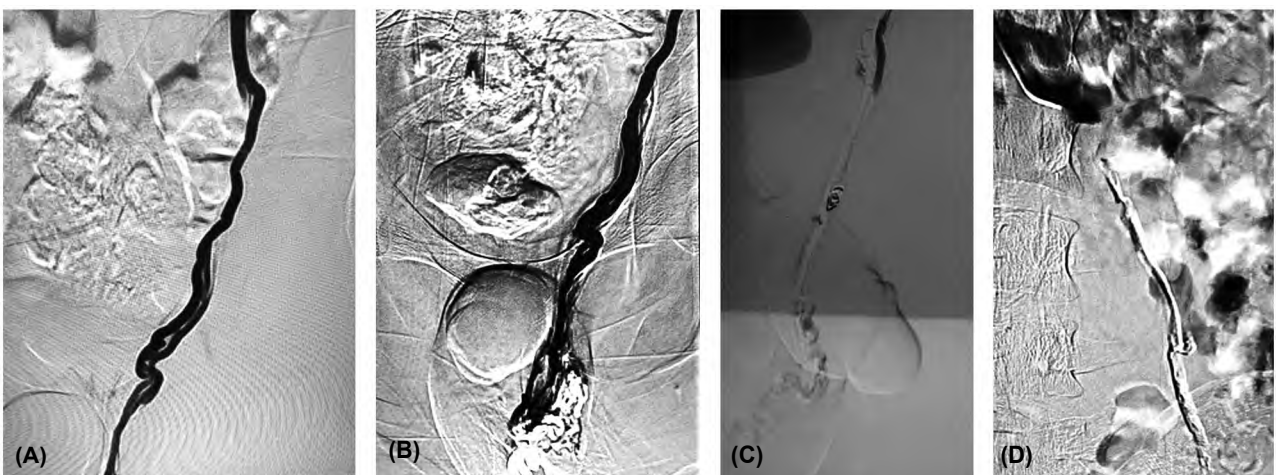


Fig. (3): A case of left varicocele treated by coiling of left internal spermatic vein through transfemoral route. (A) Initial angiogram shows the left renal vein and spermatic vein origin. (B) Left spermatic vein angiogram (C) Coil in place (D) Post embolization image show total occlusion of the spermatic vein.

Table (1): Comparison of complications in Group I and II.

Complications	Group I	Group II
• Pain	3	2
• Contrast extravasation	1	–
• Vein spasm		–
• Hematoma	2	–
• Glue migration	1	–
• Coil migration		–
• Failure	1	
• Recurrence	2	1
• Failure of catheterization of right spermatic vein	1	–

Discussion

Percutaneous embolization of varicocele is a non-surgical method for treatment and control of varicocele. This catheter-based technique is performed by the interventional, radiologists and has a potential advantages over surgical treatment [4].

In the literature, sclerotherapy and embolization of varicocele, reported a success rates of 80-100% Seyferth et al., [5]; Carmignani et al., [6]; Vanlangenhove et al., [7] and Urbano et al., [8]; Ali et al., [9]. The most commonly used embolic agents is coils as they are safe, easy to use and widely available Kuroiwa et al., [10] and Puche-Sang et al., [11].

Percutaneous embolization of the internal spermatic vein with coils is an effective, safe and less invasive. The obtained results can be compared to the results of surgical ligation as regards the technical success and the number of complications [12].

The most commonly used access for interventional treatment of varicocele is the right common femoral vein, followed by the internal jugular vein and basilica vein approach [3].

In this retrospective study, we evaluated the technical success complications, radiation exposure and recurrence rates, in 34 patients with varicocele treated by percutaneous embolization using two differed routes either the transfemoral route at the right groin of the transjugular route.

In this study (34 patients), we found that the commonly used route for left internal spermatic vein, is the right common femoral vein as it is easier than the jugular route. The right sided access is routinely used as it is technically easier for catheterization of the left renal vein and left internal spermatic vein. For embolization of right sided

varicocele the internal jugular approach is better due to the fact that the angle between the IVC and right internal spermatic vein in narrow which renders its catheterization through the transfemoral vein difficult.

These results are more or less similar to the results obtained by Halpern et al., [3], also they stated that for left sided varicocele alone, it is better to use the right common femoral vein approach, while in bilateral or right side varicocele the transjugular approach is preferred.

Favard et al., [4], had a retrospective study for 182 patients treated for varicocele using the transfemoral or transjugular routes, they compared the tolerance, radiation and recurrence rate. They did not encounter major complications, while minor complications were seen in 7 patients (3.8%), they found self limiting vein lesion in two patients one with spasm and one with perforation and contrast extravasation. Temporary groin hematoma in 4 patients that resolved spontaneously. No non target embolizations or pampiniform plexus phlebitis was diagnosed. Nearly we have similar results, where pain was seen in 3 patients in Group I and in two patients in Group II; contrast extravasation in one patient, groin hematoma in 2 patients, glue migration in one patient and recurrence after 6 months in 3 patients (2 in Group I and one in Group II).

In this study the duration of the procedure was longer in the Group I (transfemoral route), about 52 minutes and the time of scopy was also longer about 23 minutes, while it was shorter in Group II, the transjugular route as the time of procedure was 40 minutes and fluoroscopy time was 15 minutes. This is due to the fact that many trials for catheterization of the right internal spermatic vein through the right femoral approach due to narrow angle.

The mean scopy time in this study in both groups was 19 minutes, which is exactly similar to that of Favard et al., [4] who stated that the mean time of fluoroscopy in a big serious (182 patients was 19 minutes).

Conclusion:

Percutaneous embolization of varicocele is a safe procedure; it can be used as an alternative to surgery. Both transfemoral access route and transjugular routes can be used, sparing the femoral alone and in bilateral varicocele, it is better to use transjugular route.

References

- 1- WEIN A.J., KAVOUSSI L.R. and CAMPBELL M.F.: In Campbell-Walsh Urology by Wein, A.J.; Kavoussi, L.R and Campbell, M.F. (eds), Philadelphia, RA, Elsevier Saunders, 2012.
- 2- PASTUZAK A.W. and WANG R.: Varicocele and testicular function. *Asian J. Androl.*, 17: 659-67, 2015.
- 3- HALPERN J., MILTAL S., PEREIRA K., BHATIA S. and RAMASAMY R.: Percutaneous embolization of varicocele: Technique, indications, relative contraindications and complications. *Asian J. of Androl.*, 18: 234-8, 2016.
- 4- FAVARD N., MOULIN M., FAUQUE P., BESTAUT A., FARELEIR S., ESTIVALET L., MICHEL F., COMIER L., SAGOT P. and LOFFROY R.: Comparison of three different embolic materials for varicocele embolization: Retrospective study of tolerance, radiation and recurrence. *Quant. Imaging ed. Surgery*, 5 (6): 806-14, 2015.
- 5- SEYFERTH W., JECHT E. and ZIEDER E.: Percutaneous sclerotherapy of varicocele. *Radiology*, 139: 335-40, 1981.
- 6- CARMIGNANI L., CASELLATO S., GALASSO G., BOZZINI G., SPINELLI M., DELL'AGNOLA C.A. and ROCCO F.: Sclerotherapy of the pampiniform plexus with modified Marmar technique in children and adolescents. *Urol. Int.*, 82: 187-90, 2009.
- 7- VANLANGENHOVE P., De KEUKELEIRE K., EVERAERT K., VAN MAELE G. and DEFREYNE I.: Efficacy and safety of two different N-butyl-2-cyanoacrylates for the embolization of varicoceles: A prospective, randomized, blinded study. *Cardiovasc. Intervent. Radiol.*, 35: 598-606, 2012.
- 8- URBANO J., CABRERA M. and ALONSO-BURGOS A.: Sclerosis and varicocele in 41 patients with N-butyl cyanoacrylate: Experience in 41 patients. *Acta Radiol.*, 55: 179-85, 2014.
- 9- ALI A., WIRTH S. and TREID K.M.: Treatment of male varicoceles by transcatheter polidocanol foam sclerotherapy: Evaluation of clinical success, complications, and patients' satisfaction with regard to alternative techniques. *Eur. Radiol.*, 25: 2889-97, 2015.
- 10- KUROIWA T., HASUO K., YASUMORI K., MIZUSHIMA A., YOSHIDA K., HIRAKATA R., KOMATSU K., YAMAGUCHI A and MASUDA K.: Transcatheter embolization of testicular vein for varicocele testis. *Acta. Radiol.*, 32: 311-4, 1991.
- 11- PUCHE-SANZ L., FLORES-MARTIN J.F., VAZQUEZ-ALONSO F., PARDO-MORENO P.I. and COZAR-OLMO J.M.: Primary treatment of painful varicocele through percutaneous retrograde embolization with fibred coils. *Andrology* 2: 7: 716-20, 2014.
- 12- GEORGIU I., STAINHAUER G., KARTSOUNI V., GALIATSATOS N. and ALHENS G.R.: Percutaneous transcatheter treatment for varicocele: *European Society of Radiology*, 10: 1594, 2011.

مقارنة بين طريقتين لإنصمام دوالي الخصية عن طريق الجلد، عبر الوريد الفخذي وعبر الوريد الوداجي؛ مقارنة بين المضاعفات، والتعرض للإشعاع ومعدلات تكرار دراسة

خلفية البحث: تمت هذه الدراسة لمقارنة طريقتين لإنصمام دوالي الخصية عن طريق الجلد، عبر الوريد الفخذي وعبر الوريد الوداجي. وكانت مقارنة بين المضاعفات، والإشعاع ومعدلات تكرار.

المرضى وطرق البحث: كانت هذه الدراسة دراسة بأثر رجعي لسجلات ٣٤ مريضاً من الذكور الذين تم تشخيص إصابتهم بدوالي الخصية بالفحص السريري والأشعة التشخيصية الذين تم علاجهم عن طريق الإنصمام عن طريق الجلد في الفترة من ٢٠١٤ إلى ٢٠١٦. شملت الدراسة مجموعتين، المجموعة الأولى (١٧ مريضاً) تم علاجهم عن طريق الوريد الفخذي والمجموعة الثانية (١٧ مريضاً) عن طريق الوريد الوداجي. وشملت المواد الصامة للوريد، لفائف (١٤ مريضاً)، بيوتيل-سيانوأكريلات (١٢ مريضاً) والمواد المصلبة أو بوليديوكانول في (٨ مريضاً). القسطرة المستخدمة كانت الكوبرا مقاس ٥-فرنش، والقسطرة برن مقاس ٤ فرنش والقسطرة متناهية الصغر (بروغريت ٧ مقاس ٢ فرنش). تمت مقارنة المضاعفات ووقت التعرض للإشعاع والنجاح التقني أو إرتجاع الدوالي في المجموعتين.

النتائج: في المجموعة الأولى (عن طريق الوريد الفخذي)، كان هناك فشل في الوصول إلى الوريد المنوي الداخلى في مريض واحد بسبب الزاوية الحادة للوريد، بينما في المجموعة الثانية كان الوصول إلى الوريد المنوي الداخلى الأيمن والأيسر ناجحاً في جميع المرضى (١٧ مريضاً). أيضاً أعراض الألم بعد الإجراء التداخلى ظهرت في ٣ مرضى في المجموعة الأولى وفي مريضين في المجموعة الثانية. تسرب الصبغة خارج الوريد حدث في مريض واحد في المجموعة الأولى، التجمع الدموي حدث في ٢ من المرضى، وهجرة الغراء في مريض واحد، إرتجاع الدوالي حدث في مريضين، في حين أنه في المجموعة الثانية لم يحدث أى إصابة للوريد أو تجمع دموي أو هجرة للغراء بينما حدث إرتجاع الدوالي في مريض واحد فقط. كان متوسط زمن العملية ووقت التعرض للأشعة أطول في المجموعة الأولى بالمقارنة مع المجموعة الثانية. في المجموعة الأولى كان متوسط وقت الإجراء ٥٢ دقيقة وكان وقت التعرض للأشعة ٢٣ دقيقة بينما في المجموعة الثانية. كانت ٤٠ دقيقة و ١٥ دقيقة على التوالي.

الإستنتاج: إنصمام دوالي الخصية عن طريق الجلد تقنية آمنة نسبياً ولها نسبة نجاح عالية. الإنصمام عن طريق الوريد الوداجي وجد أن لديه مضاعفات أقل، ووقت تعرض للإشعاع أقل ومعدل منخفض لإرتجاع الدوالي.