

## Mammographic and Ultrasound Features of Mondor's Disease of the Breast (Original Article)

YASMIN M. TOHAMEY, M.D.\* and AMR FAROUK, M.D.\*\*

The Department of Radiology, Faculty of Medicine\* and National Cancer Institute\*\*, Cairo University

### Abstract

**Background:** Mondor's disease of the breast or superficial thrombophlebitis of the breast is a rare benign breast entity, may be due to lack of awareness of the entity.

**Aim of Work:** The purpose of this study was to demonstrate the mammographic and sonographic findings in patients with Mondor's disease of the breast.

**Material and Methods:** 10 patients (9 females and 1 male) presented with a painful palpable cordlike structure. The youngest patient was 29 years old and the oldest patient is 64 years old. All patients were evaluated by Ultrasound. Mammography only was performed on 6 patients. Mammographic and sonographic findings were evaluated retrospectively.

**Results:** The sonographic finding of a superficial vessel without flow on Doppler imaging in addition to a mammographic finding of a tubular density are diagnostic of Mondor's disease of the breast. Being familiar with the imaging findings of Mondor's disease will help its diagnosis & avoiding the pitfall of mistaking it for a dilated duct.

**Conclusion:** The clinical presentation together with sonomammographic findings are useful in diagnosing Mondor's disease. Being familiar with these radiologic features prevent misdiagnosis and unnecessary treatment.

**Key Words:** Breast – Mondor's disease – Superficial thrombophlebitis.

### Introduction

**SUPERFICIAL** thrombophlebitis of the chest wall and breast was described as a clinical entity almost 100 years ago. Thrombophlebitis of the thoraco-epigastric veins and its extensions, especially those extensions coursed up over the lower and outer portions of the breast [1].

Mondor's disease of the breast is a rare benign breast entity. An understanding of the epidemiology, pathogenesis, clinical presentation and the sono-

mammographic imaging findings of Mondor's disease of the breast is important for proper diagnosis [2].

The disease is more prevalent in women than in men [up to a ratio of 3:1], and mostly presents in middle aged patients. The pathophysiological process include thrombus formation, thrombus organization, partial recanalization, and re canalized vein with fibrous wall. The most common venous vessels involved in the chest wall are the lateral thoracic, thoracoepigastric, and superior epigastric veins [3].

It is suggested that direct trauma to the vein or pressure on the lateral thoracic veins lead to stasis of blood may be the pathophysiologic cause [1].

Mondor's disease may be primary (idiopathic) or secondary to local trauma, surgical procedures [including mastoplasty and excision breast biopsies], bandaging, tight clothing, infections, intravenous drug injection, vasoconstriction drugs, rheumatologic diseases and may also be associated with breast cancer [3,4].

The most common symptoms include lateral chest wall tension and pain or tender subcutaneous linear cord-like structure often with skin redness, edema or retraction and sometimes visible cord [5].

These symptoms corresponding to the acute phase of thrombophlebitis and findings are usually self-limiting and resolve in approximately 2 to 8 weeks [6].

Resolution of symptoms follows the recanalization of the affected vessel [3].

The main complication of this condition is a cosmetic deformity due to phlebosclerosis and hyalinization [7].

**Correspondence to:** Dr. Yasmin M. Tohamey, The Department of Radiology, Faculty of Medicine, Cairo University

Mondor's disease of the breast is self-limiting, requiring only symptomatic treatment including anti-inflammatory, analgesic medications and warm compresses to the skin over the affected site [7].

The purpose of this study was to demonstrate the mammographic and sonographic findings in patients with Mondor's disease of the breast.

### Material and Methods

During the 4-year period between 2010 and 2014, ten patients with Mondor's disease were identified. Patients presented to outpatient clinic at Khartoum Breast Care Center (Sudan). Patients were submitted to the following:

#### I- Clinical history and examination:

Full history taking including sex, age, clinical presentation (tender lump) and past medical history with dedicated examination.

#### II- Imaging procedures:

All 10 patients underwent B-mode ultrasound examination including real-time sonography and color Doppler imaging of the area of concern. We used an ultrasound device of GE Healthcare (LOGIQ E5 with XDclear premium ultrasound) with a superficial linear 12MHz probe.

A standard two-view mammogram was obtained in only 6 patients as 2 were young (27 and 28

years) and two were lactating. Mammograms were done using the digital mammography system (using GE Senographe 2000D full-field digital mammography system from GE Healthcare; Chalfont St-Giles, UK).

### Results

During a 4-year period, we identified ten patients (9 females and 1 male) with Mondor's disease of the breast presenting to our outpatient clinics. The patients ranged in age from 27 to 64 years (average age 41 years). 9 patients presented with a localized tender palpable mass at the time of the mammographic and sonographic evaluation. The male patient had a palpable lump without pain.

Two of the eight women were lactating. Two of the ten patients had a history of minor trauma of the affected breast.

We presumed the cause of Mondor's disease in the 10 patients to be post traumatic in 2 patients and idiopathic in 8 patients.

The location of the thrombosed vein was outer quadrants of the breast, 2 cases near the axillary tail and 1 case peri-areolar in location.

In six patients the mammograms revealed a superficially located tubular density. The density was seen in the upper outer breast Fig. (1).

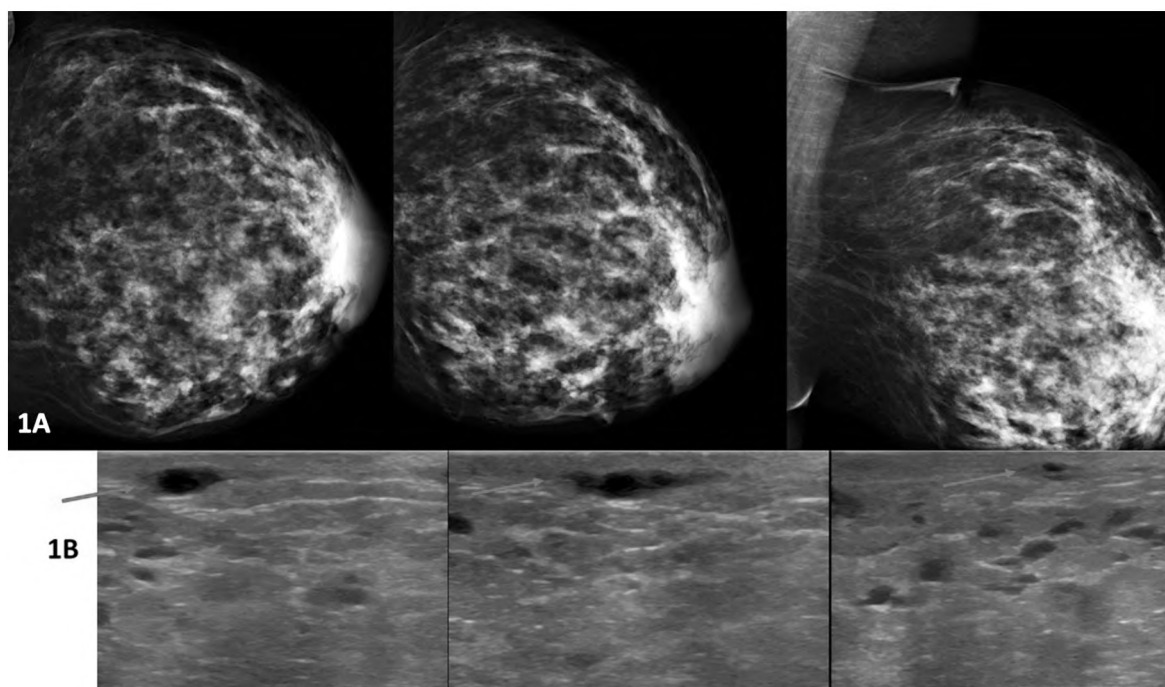


Fig. (1): 42 year old with history of minor trauma 10 days earlier presented with a left breast palpable painful mass. (A) Left breast craniocaudal and mediolateral oblique mammograms show a linear density at upper outer quadrant. (B) Sonogram reveals a hypoechoic tubular structure of varying width (arrows) that corresponds to the palpable abnormality.

Sonograms of 9 patients showed a hypoechoic tubular structure of varying width with or without intraluminal echogenic that corresponds to the palpable abnormality. In 1 patient a collapsed tubular anechoic structure was seen. No flow was present in these structures on color Doppler studies.

**Discussion**

Mondor's disease of the breast also known as superficial thrombophlebitis of the region is an uncommon pathologic breast entity [8].

The most common clinical presentation is a tender, painful, palpable, and sometimes visible cord. Symptoms are usually self-limiting and resolve in approximately 2 to 8 weeks [6].

Mammographic evaluation is indicated in patients with suspected Mondor's disease primarily for the evaluation of a palpable finding in the breast. However sonography is the first examination in younger patients with a palpable mass [2-8].

The mammographic finding of Mondor's disease is asymmetric tubular density or thickened ropelike density which may be contiguous with the uninvolved visible vessel [9].

Sonography shows a non-compressible hypoechoic tubular structure (thrombosed vein) of varying width giving a beaded appearance. On Doppler application lack of internal color Doppler flow is noted [7] (Fig. 2).

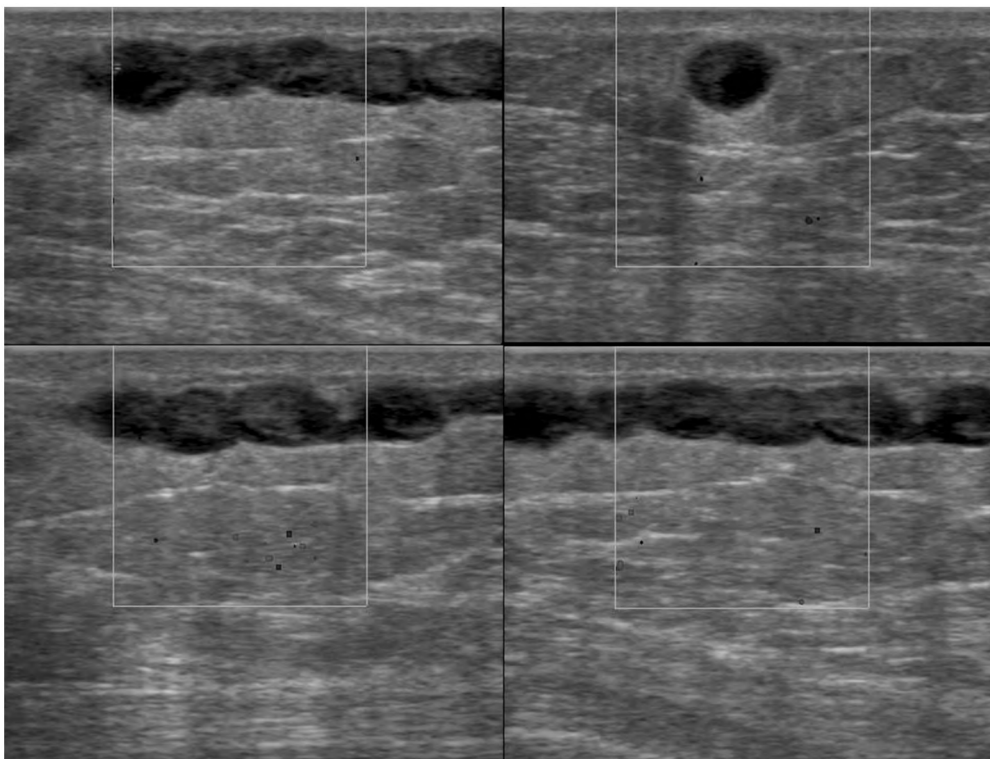


Fig. (2): 64 year old woman presented with a palpable painful mass at axillary tail. Sonogram of the palpable abnormality reveals a hypoechoic tubular structure of varying width and beaded appearance with no flow on color Doppler application. An occluded vein can be difficult to differentiate from a dilated duct.

To avoid this mistake at mammography dilated ducts appear on mammogram as tubular or branching structures in the subareolar region.

Sonography enables further differentiation as it enables identification of the entire course of the thrombosed vessel, which may not be visible in a mammographically dense breast.

A thrombosed vein tends to be longer than a duct, have a beaded appearance, and is seen most

commonly in the upper outer aspect of the breast. When in a periareolar location, a thrombosed vein does not terminate at the areola, unlike a lactiferous duct [2].

A thrombosed vein is 3 to 5mm in diameter with lengths varying from 5 to 30mm [4].

In our study we had older age patients doing a mammogram and sonography while younger age patients doing a sonography only.

The location of the thrombosed vein was in the upper outer quadrant.

On mammogram the appearance of a tubular uneven superficial structure suggested a superficial lesion.

On sonography we found subcutaneous superficial tubular structure of varying width and sometimes beaded appearance, not continuous with a lactiferous duct corresponding to the clinically palpable tender lump. Further confirmation of the diagnosis was obtained via color Doppler application showing no color signal.

#### Conclusion:

The clinical presentation together with sonomammographic findings are useful in diagnosing Mondor's disease. Being familiar with these radiologic features prevent misdiagnosis and unnecessary treatment.

#### References

- 1- HOGAN G.F.: Mondor's disease. Archives of Internal Medicine, 113: 881-5, 1964.
- 2- SHETTY M.K. and WATSON A.B.: Mondor's disease of the breast: Sonographic and mammographic findings. AJR. American Journal of Roentgenology, 177: 893-6, 2001.
- 3- RAVIV B. and ISRAELIT S.: Mondor's disease of the chest wall-a forgotten cause of chest pain: Clinical approach and treatment. J. Gen. Pract., 2: 2, 2014.
- 4- KAMARIAH S. and HUMAIRAH S.: Mondor's disease. The International Medical Journal of Malaysia, 10, 2011.
- 5- HOU M.F., HUANG C.J., HUANG Y.S., HSIEH J.S., CHAN H.M., WANG J.Y., et al.: Mondor's disease in the breast. Kaohsiung J. Med. Sci., 15: 632-9, 1999.
- 6- PUGH C.M. and DeWITTY R.L.: Mondor's disease. Journal of the National Medical Association, 88: 359-63, 1996.
- 7- Vascular abnormalities of the breast: Arterial and venous disorders, vascular masses, and mimic lesions with radiologic-pathologic correlation. RadioGraphics, 31: E117-E136, 2011.
- 8- CONANT E.F., WILKES A.N., MENDELSON E.B. and FEIG S.A.: Superficial thrombophlebitis of the breast (mondor's disease): Mammographic findings. A.J.R. American Journal of Roentgenology, 160: 1201-3, 1993.
- 9- KIM H.S., CHA E.S., KIM H.H. and YOO J.Y.: Spectrum of sonographic findings in superficial breast masses. Journal of Ultrasound in Medicine, 24: 663-80, 2005.

## تصوير مرض موندور بالثدي

مرض موندور أو التهاب الوريد الخثاري السطحي للثدي هو مرض نادر حميد قد يكون راجعا إلى نقص الوعي به. إن فهم علم الأوبئة المرضية، العرض السريري ونتائج التصوير سونو-ما موغرافيك مرض موندور من الثدي مهم للتشخيص السليم.

الغرض من هذه الدراسة هو إظهار نتائج التصوير الشعاعي للثدي والسونار في المرضى الذين يعانون من مرض موندور من الثدي.

حددنا عشرة مرضى (٩ إناث و١ من الذكور) مع مرض موندور في الثدي وتقديمها إلى العيادات الخارجية لدينا. وتتراوح أعمار المرضى بين ٢٧ و٦٤ عاما (متوسط العمر ٤١ عاما). قد م ٩ مرضى مع كتلة العطاء ملموس المحلية في وقت التقييم الماموغرافي والتصوير السونوغرافي. كانت إثنان من النساء الثماني مرضعات. كان موقع الوريد الخثاري الأرباع الخارجية من الثدي.

العرض السريري جنبا إلى جنب مع النتائج سونو-ماموغرافيك هي مفيدة في تشخيص مرض موندور. العثور على الثدي هو غير أنبوبي غير المتماثلة أو سميكة الكثافة التي قد تكون متجاورة مع المشاركة مرئية يتوافق مع مظهر مطرز على التصوير بالموجات فوق الصوتية مع عدم وجود اللون الداخلي.

تدفق دوبلر على تطبيق دوبلر. الدراية بهذه الميزات الإشعاعية يمنع التشخيص الخاطئ والعلاج غير الضروري.