

Diagnostic Accuracy of Contrast Enhanced Spectral Mammography in Assessment of Indeterminate Breast Lesions in Patients after Breast Conservation Surgery

ASMAA M. ABD EL-MAGIED, M.D.* and EMAD S. KHALIFA, M.D.**

The Departments of Radiodiagnosis and General Surgery**, Faculty of Medicine, Cairo University*

Abstract

Background: Breast cancer in women represents a major public health problem being the most common cancer among women in both developed and developing countries, it accounts for 22.9% of all new female cancers. In Egypt breast cancer accounts for 37.7% of the total new cancer cases. Contrast Enhanced Spectral Mammography (CESM) is an emerging advanced technique that depict breast tumor angiogenesis. CESM as an adjunct to Mammography (MG) with or without Ultrasound (US) has higher diagnostic accuracy compared to MG with or without US.

Aim of Work: To evaluate the diagnostic accuracy of contrast enhanced spectral digital mammography versus the digital mammography in assessment of indeterminate breast lesions in patients after breast conservation surgery.

Patients and Methods: 20 female patients under follow-up after breast conservative surgery presenting with indeterminate/suspicious breast lesion on mammography had been evaluated by dual-energy contrast enhanced spectral mammography. The age ranged from 40 to 65 years (mean=50.3). Results of histo-pathological examinations of surgical or biopsy specimens were obtained and served as the gold standard.

Results: The surgical and pathological results of our patients revealed 6/20 (30.0%) benign lesions and 14/20 (70.0%) malignant lesions. CESM had a sensitivity of 85.7%, a specificity of 71.4%, a positive predictive value of 92.3%, a negative predictive value of 71.4% compared to digital mammography results which were 71.4%, 71.4%, 90.9% and 55.6% respectively.

Conclusion: CESM is a promising tool for increasing the sensitivity and the diagnostic accuracy of conventional mammography in follow-up of patients with breast conservative surgery.

Key Words: Breast cancer – Breast conservative surgery – Digital mammography – Contrast enhanced spectral mammography.

Correspondence to: Dr. Asmaa Mahmoud Abd El-Magied, The Department of Radiodiagnosis, Faculty of Medicine, Cairo University

Introduction

BREAST cancer in women represents a major public health problem being the most common cancer among women in both developed and developing countries, it accounts for 22.9% of all new female cancers. In Egypt breast cancer accounts for 37.7% of the total new cancer cases [1].

Patients with early breast cancer are readily treated nowadays by Breast Conservation Surgery (BCS) while mastectomy is mandatory in about 20% of patients with multicentric lesions, diffuse DCIS, large or recurrent cancers [2].

Digital mammography is readily used for detecting breast cancer. However, it has its limitations specially in patients with dense breast as about 50% of malignant masses can be. The tumor and the surrounding breast tissue has similar density thus reducing the mammographic sensitivity and specificity, in addition to summation of tissues that can obscure underlying masses [3].

The main factor of tumor growth is the neo-angiogenesis, so different imaging modalities using intravenous contrast medium help in detection of such lesions [4]. Higher intra-tumoral shunting is statistically correlated with a greater incidence of metastases [4].

Techniques using iodine contrast agents have been performed to improve the visualization of malignant breast lesions like contrast enhanced breast CT and contrast enhanced MRI [5].

Contrast Enhanced Spectral Mammography (CESM) is an emerging advanced technique that depict breast tumor angiogenesis. CESM as an adjunct to Mammography (MG) with or without

Ultrasound (US) has higher diagnostic accuracy compared to MG with or without US [3,6].

Patients and Methods

This study was prospectively carried on 20 female patients under follow-up after breast conservative surgery. The study was carried out from December 2014 to January 2016 at new Kasr El-Aini Teaching Hospital. Patients were referred from the outpatient clinics of the surgery and Radiotherapy Departments. The study was approved by the Ethics Committee and the Institutional Review Board. This study included 20 female patients presented with indeterminate breast lesions (BIRASD 3 and 4) on digital mammography after breast conservative surgery. The age ranged from 40 to 65 years (mean=50.3).

Exclusion criteria:

- Patients with no past history of breast surgery.
- Patients who have contraindications to radiation exposure (pregnant females, etc...).
- Contraindication to IV contrast media injection, such as:
 - Allergic patients or those known to have history of complications from contrast media such as anaphylactic reaction.
 - Patients with renal impairment.

20 lesions were detected by digital Mammography (MG). 9 of them were assigned BIRADS 3 (probably benign) and 11 lesions were assigned BIRADS 4 (suspicious).

All patients were submitted to a) clinical history: Full history taking including clinical presentation (complaint), age, family and past medical history, b) Bilateral digital mammography and CSEM and c) Pathologic diagnosis: Samples of breast lesions attained by core biopsy, surgical excision or radical surgery were evaluated and analyzed.

Technique:

The conventional and contrast enhanced mammography studies were performed using General Electric Sonograph 2000D full-field digital mammography system.

The arm contra lateral to the breast of concern was chosen for the intravenous line. 1 .5mL/kg body weight of non-ionic contrast medium (Iohexol (Omnipaque) 300; GE healthcare, USA) was given using a power injector at a rate of 4mL/s.

Image acquisition:

During single breast compression, the dual-energy CESM was performed after 2min from the starting the contrast injection by acquiring low- and high-energy images in the MLO view followed by CC view after 4min. The subtracted images (MLO and CC views) are generated using specific software processing. The whole study is conducted takes approximately 7-10 minutes.

Patient are exposed to total radiation dose slightly higher than that of standard digital mammogram (about 1 .2 times) depending on breast thickness and tissue composition.

Image analysis:

The digital mammographic images were analyzed for the suspicious lesions in terms of site, size, margin, shape and density as well as calcification, architecture distortion and focal or global asymmetry.

CESM was assessed for the presence or absence of enhancement. Pattern of enhancement varies from mass enhancement either homogenous or heterogenous and non-mass enhancement.

Comparison with histopathological examinations:

Lesions were biopsied under US guidance using fine needle aspiration, true cut needle biopsy (via 14-18-gauge needles) or referred for surgical excision. Results of histopathological examinations of surgical or biopsy specimens were obtained and served as a reference.

Statistical analysis:

Accuracy was represented using the terms sensitivity, specificity, positive predictive value and negative predictive value.

Results

The study included 20 patients who had undergone conservative breast surgery and on follow-up presented with indeterminate breast lesions BIRADS 3 or 4.

Out of the 20 lesions, operative bed lesions were 17/20 (85.0%). One patient showed newly developed ipsilateral lesion 1/20 (5.0%). Two contralateral breast lesions were identified in 2/20 patients (10.0%).

Among the 20 lesions, the final histopathology diagnosis was 6/20 benign and 14/20 were malignant.

MG and CESM were done for all the twenty patients.

Out of the twenty patients, according to mammographic findings 9/20 (45.0%) patients were assigned BIRADS 3 (benign), where 11/20 (55.00%) patients were assigned BIRADS 4 (suspicious).

According to the histopathology, out of the 9 lesions; 5/9 was found out to be true negative & 4/9 was found out to be false negative.

Among the 11 lesions, 10/11 patients were proved to be true positive and one was found out to be false positive.

The MG findings encountered in these patients are shown in Table (1).

All the patients had done CESM.

Of all the twenty patients, according the CSEM findings, 7/20 (35.0%) lesions were assigned benign (BIRADS 3) with no contrast uptake and 13/20 (65.0%) lesions were assigned malignant (BIRADS 4) showing enhancing lesions. Pattern of enhancement in CESM is described in Table (2).

According to the histopathology, 5/7 lesions were true negative and two were false negative. The two false negative cases were infiltrating ductal carcinoma with no contrast uptake.

Among the 13 lesions; 12/13 were true positive and one was false positive.

The compared diagnostic indices of MG and CESM emphasizing the added value of CESM are illustrated in Table (3).

The contrast enhanced spectral mammography showed higher sensitivity, positive and negative predicative values compared to the mammography.

Selected cases were demonstrated in Figs. (1-4).

Table (1): Mammography findings among studied lesions.

MG findings	No. of lesions
Masses	9
Focal asymmetry and architectural distortion	5
global asymmetry and edema	3
Micro calcifications	3

Table (2): Pattern of enhancement in CESM.

Pattern of enhancement in CESM	No of lesions
Homogenous enhancing lesions	3
Heterogeneous enhancing lesions	4
Non-mass enhancement	3
Ring enhancing lesions	3

Table (3): Diagnostic indices of MG and CESM.

	MG	CESM
Sensitivity	71.4%	85.7%
Specificity	71.4%	71.4%
Positive predictive value	90.9%	92.3%
Negative predictive value	55.6%	71.4%

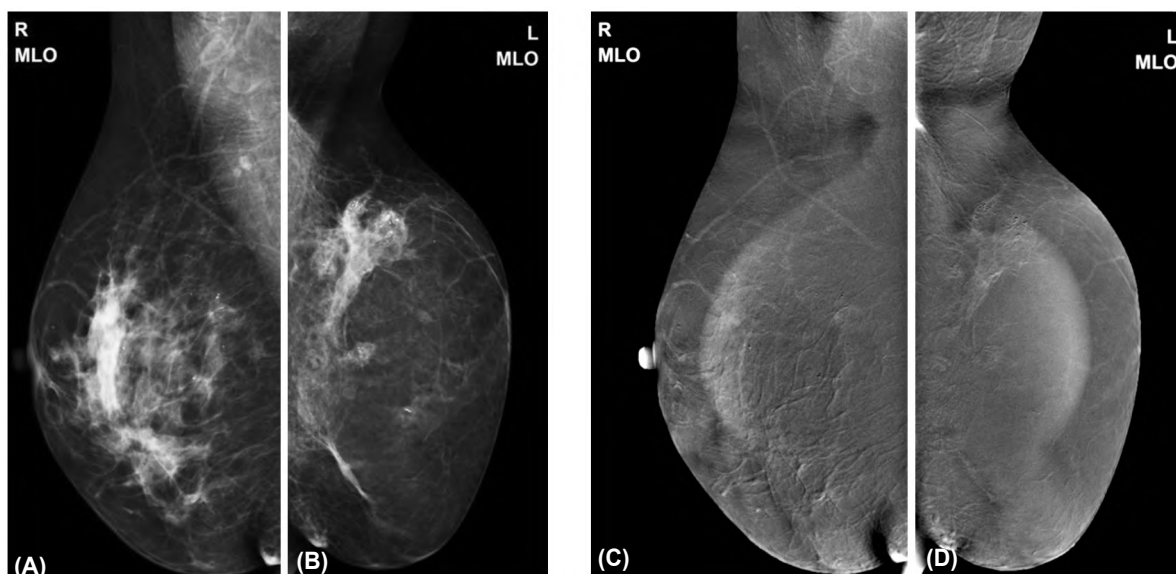


Fig. (1): 55 years old female patient who underwent left BCS coming for her regular annual checkup. Digital mammography of both breasts in MLO (A,B) Views revealed left UOQ focal asymmetry and with extensive pleomorphic malignant calcification. BIRADS 4. CESM (C,D) Revealed left breast non-mass enhancement. BIRADS 4. Final diagnosis is IDC.

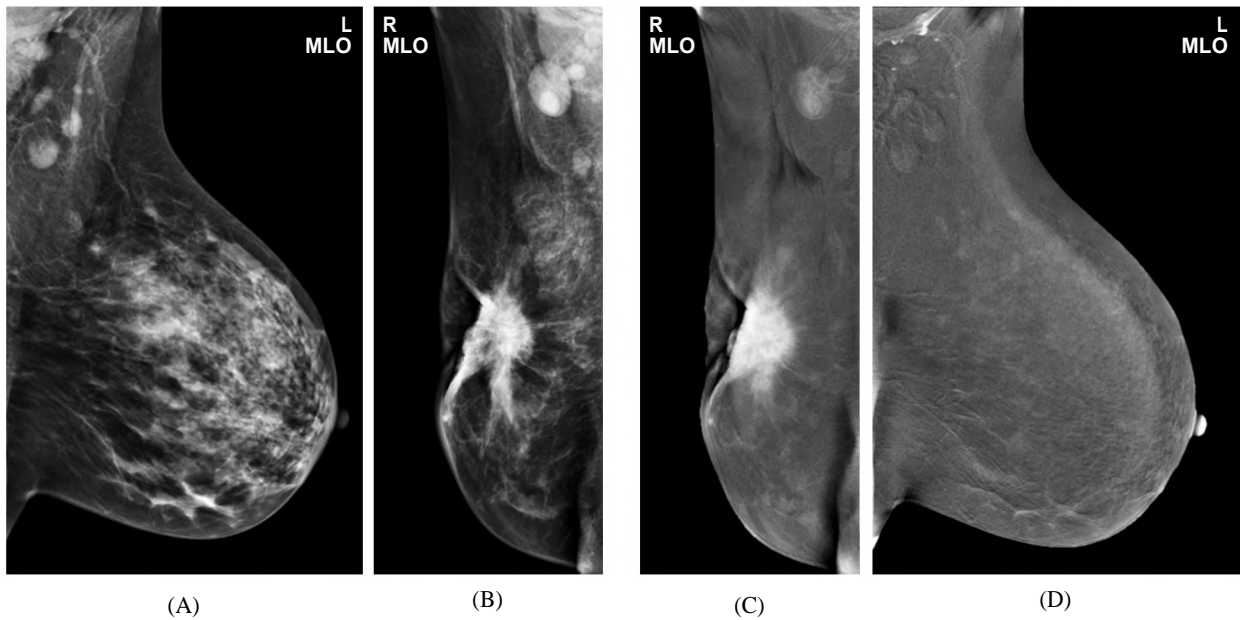


Fig. (2): 60 years old female patient with right breast conservation surgery. Digital mammography of both breasts in MLO (A,B) Views revealed right breast operative bed spiculated mass and pathological axillary lymph nodes. BIRADS 4. CESH of both breasts (C,D) Revealed right breast operative markedly enhancing spiculated mass and enhancing axillary lymph node. BIRADS 4c. Final diagnosis: IDC.

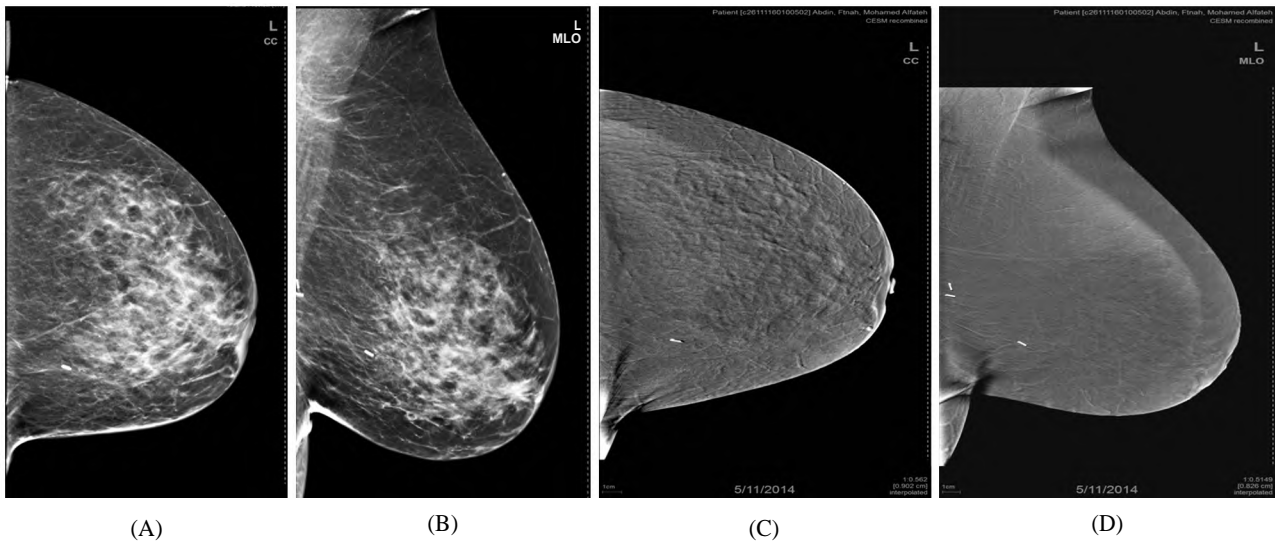


Fig. (3): 52 years old female patient, had underwent left BCS. She presented with palpable lesion at scar. Digital mammography of left breast CC (A) and MLO (B) Views revealed mild architectural distortion. BIRADS 3. CESH of left breast (C,D) Revealed no contrast uptake, BIRADS 3. Final diagnosis: Operative bed fat necrosis.

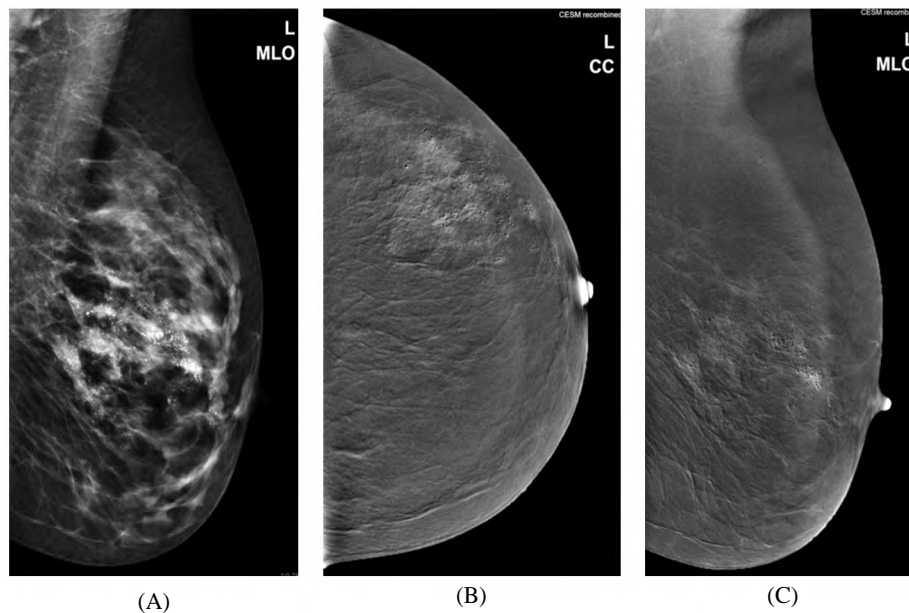


Fig. (4): 34 years old female patient, had underwent right BCS presenting with left palpable lesion and nipple discharge. Digital mammography of left breast MLO (A) View revealed clustered segmental pleomorphic micro calcification. BIRADS 4. CESM of left breast (B,C) Revealed segmental non-mass enhancement, BIRADS 4. Final diagnosis is DCIS.

Discussion

Women with past history of breast cancer are at increased risk for developing local recurrences, a second breast cancer in same side, or contralateral breast cancer. Breast conservative surgery is the treatment of choice for early stages. Many studies showed no significant difference in survival rates between those treated with breast conservative surgery and those treated with mastectomy [7].

About 5% of patients experience loco-regional recurrences. Suspicious findings in the early post-operative period, are more likely to represent residual disease. While recurrence occurs years after operation. Early detection of local recurrence is essential to improve long-term survival [8]. Post-operative architectural distortion and increased breast density at the lumpectomy site in addition to post-treatment edema contribute to the impaired accurate detection of recurrence at FFDM and US [8].

Imaging techniques using contrast medium are able to detect breast cancer more owing to the tumor angiogenesis which leads to lesions enhancement [9].

Contrast Enhanced Spectral Mammography (CESM) is used recently as an advanced technique for detection of the tumors neoangiogenesis [3,4].

Previous studies results suggested that CESM is superior in evaluation of lesion size, assessment

of full extent of lesion and detection of other lesions (multifocal and multicentric lesions) not readily seen by MG alone or combined with US [6,10].

Different studies on CESM in the past few years has shown CESM to have better diagnostic accuracy versus conventional mammography alone [3].

Dromain et al., [11] conducted a study on 20 patients with malignant lesions, where temporal CESM had the potential to detect tumor angiogenesis with contrast enhancement depicted in 80% of the lesions.

Diekmann et al., [12] results showed improvement in the sensitivity and specificity of conventional mammography alone versus temporal CESM and mammography.

Fallenberg et al., [10] hypothesized that CESM is more accurate in lesion detection and size assessment than MG with the increase in lesion detection using CESM was 17.5% compared to MG.

This study was prospectively carried on 20 female patients with breast conservation surgery presenting with indeterminate findings in MG. All patients performed mammography and CESM.

According to the final histopathology diagnosis; patients were classified into two groups; the benign

lesions group 6/20 (30.0%) and the malignant lesions group 14/20 (70.0%).

As regards the mammographic findings; 9/20 (45.0%) lesions were assigned (BIRADS 3) and 11/20 (55.0%) lesions were assigned suspicious (BIRADS 4).

Upon correlating the mammography findings to the final diagnoses; 10 lesions were true positives, one lesion was false positive, 4 lesions were false negatives and 5 lesions were true negatives.

The false positive case was due to the architectural distortion and increased breast density at the lumpectomy site as well as post-treatment edema. Four cases were false negative, they were small de novo lesions masked by dense breast tissue. They were non-visualized by MG and missed at operator dependent US.

Regarding the mammographic findings; it had a sensitivity of 71.4%, a specificity of 71.4%, a positive predictive value of 90.9%, a negative predictive value of 55.6%.

These results are in concordance with study done by Yalcinkaya et al., [13] who concluded false negative mammography results in patients with breast conservative surgery and radiotherapy are high due to the parenchymal distortion and edema.

As regards the CESM findings; 13/20 (65%) lesions showed contrast uptake and were assigned BIRADS 4 where 7/20 (35%) lesions showed no contrast uptake and were assigned BIRADS 3.

Upon correlating the CESM findings to the final diagnoses; 12 lesions were true positives, one lesion was false positive, 5 lesions were true negatives and 2 lesions were false negatives.

Based on the CESM findings; it had a sensitivity of 85.7%, a specificity of 71.4%, a positive predictive value of 92.3%, a negative predictive value of 71.4%.

The only false positive case was misdiagnosed due to increased vascularity in some non-malignant post-operative sequelae.

Our two false negative cases were misdiagnosed due to non-apparent contrast uptake by the malignant lesions. This is in concordance with Roberta et al., [14] who revealed in their initial clinical experience that 8/10 malignant lesions showed enhancement at CESM. In one case of ductal carcinoma in situ and one case of invasive ductal carcinoma, enhancement was not observed.

Our results are in agreement with those of Helal et al., [3], Saraya et al., [4] and Dromain et al., [6] as well as Mokhtar and Mahmoud [9] and Lobbes et al., [11] who found that CESM as an adjunct to sono-mammography is superior in terms of diagnostic accuracy compared to sono-mammography alone.

Kamal et al., [16] showed that malignant breast lesions enhancement was significant with an overall sensitivity and specificity being 88.99% and 83.33% respectively.

According to the results of our study; contrast-enhanced spectral mammography has more diagnostic accuracy compared to the MG specially in postoperative patients owing to the parenchymal distortion and breast edema encountered.

Conclusion:

Contrast-enhanced spectral mammography is recommended as an adjunct to digital mammography for assessment of indeterminate breast lesions in patients with breast conservation surgery.

References

- 1- ZEENELDIN A.A., RAMADAN M., GABER A.A., et al.: Clinico-pathological features of breast carcinoma in elderly Egyptian patients: A comparison with the non-elderly using population-based data. *J. Egypt Natl. Canc. Inst.*, Mar., 25 (1): 5-11, 2013.
- 2- PETIT J.Y., VERONESI U., LUINI A., et al.: When mastectomy becomes inevitable: The nipple-sparing approach. *Breast*, 14: 527-31, 2005.
- 3- M. HELAL, MANAL F. ABU SAMRA B., et al.: Accuracy of CESM versus conventional mammography and ultrasound in evaluation of BI-RADS 3 and 4 breast lesions with pathological correlation. *The Egyptian Journal of Radiology and Nuclear Medicine*, 48: 741-50, 2017.
- 4- SARAYA S., ADEL L. and MAHMOUD A.: Indeterminate breast lesions: Can contrast enhanced digital mammography change our decisions? *The Egyptian Journal of Radiology and Nuclear Medicine*, 48: 547-52, 2017.
- 5- ROBSON K.J.: Advances in mammographic imaging *The British Journal of Radiology*, 83: 273-5, 2010.
- 6- DROMAIN C., THIBAUT F., DIEKMANN F., et al.: Dual-energy contrast-enhanced digital mammography: Initial clinical results of a multireader, multicase study. *Breast Cancer Research*, 14 (3): R94, 2012.
- 7- BLICHERT-TOFT M., NIELSEN M., DÜRING M., et al.: Longterm results of breast conserving surgery Vs. mastectomy for early stage invasive breast cancer: 20-year follow-up.
- 8- DRUKTEINIS J.S., GOMBOS E.C., RAZA S. M.D., et al.: MR Imaging Assessment of the Breast after Breast Conservation Therapy: Distinguishing Benign from Malignant Lesions *Radio. Graphics*, 32: 219-34, 2012.

- 9- MOKHTAR O. and MAHMOUD S.: Can contrast enhanced mammography solve the problem of dense breast lesions? Egypt J. Radiol. Nucl. Med., 45 (3): 1043-52, 2014.
- 10- FALLENBERG E.M., DROMAIN C., DIEKMANN F., et al.: Contrast-enhanced spectral mammography versus MRI: Initial results in the detection of breast cancer and assessment of tumour size. Diagn. Interv. Imaging, 95 (3): 351-2, 2014.
- 11- DROMAIN C., BALLEYGUIER C., ADLER G., et al.: Contrast-enhanced digital mammography. Eur. J. Radiol., 69: 34-42, 2009.
- 12- DIEKMANN F. and BICK U.: Tomosynthesis and contrast-enhanced digital mammography: Recent advances in digital mammography. Eur. Radiol., 17: 3086-92, 2007.
- 13- YALCINKAYA M., MAKBULE VARER M., SARSILMAZ A., et al.: The Contribution of MRI to the Mammographic Findings in Patients with Elevated Risk of Malignancy Kocatepe Medical Journal, 15 (2): 156-63, 2014.
- 14- ROBERTA A. JONG, MARTIN J. YAFFE, MIA SKARPATHIOTAKIS, et al.: Contrast-enhanced digital mammography: Initial clinical experience. Radiology, Sep., 228 (3): 842-50, 2003.
- 15- LOBBES M.B.I., LALJI U., HOUWERS J. et al.: Contrast-enhanced spectral mammography in patients referred from the breast cancer screening programme Eur. Radiol., 24: 1668, 2014.
- 16- KAMAL R., HELAL M., RASHA WESSAM R., et al.: Contrast-enhanced spectral mammography: Impact of the qualitative morphology descriptors on the diagnosis of breast lesions. Eur. J. Radiol., 84 (6): 1049-55, 2015.

الدقة التشخيصية للتصوير الإشعاعي الرقمي للثدي المعزز بالصبغة في تقييم آفات الثدي الغير محدودة في المريضات بعد جراحة الثدي التحفظية

الهدف: تقييم الدقة التشخيصية للتصوير الإشعاعي الرقمي للثدي المعزز بالصبغة في تقييم آفات الثدي الغير المحددة في المريضات بعد جراحة الثدي التحفظية.

آساليب البحث: ٢٠ مريضة تحت المتابعة بعد جراحة الثدي التحفظية يعانون من آفات الثدي الغير محددة تم تحديدهم عن طريق التصوير الإشعاعي الرقمي للثدي تم فحصهم باستخدام التصوير الإشعاعي المزدوج الطاقة للثدي مع التعزيز بالصبغة. تراوحت أعمارهم من ٤٠ إلى ٦٥ سنة (المتوسط=٥٠.٣). وقد تم الحصول على نتائج العملية لعينات الجراحة أو الخزعة والإعتماد عليها كمرجع.

النتائج: أظهرت النتائج الجراحية والعملية أن ٦/٢٠ (٣٠.٠٪) من المريضات لديهم آفات حميدة وأن ١٤/٢٠ (٧٠.٠٪) من المريضات يعانون من آفات خبيثة. أظهر التصوير الإشعاعي الرقمي للثدي المعزز بالصبغة حساسية ٨٥.٧٪ وخصوصية ٧١.٤٪ وقيمة تنبؤية إيجابية ٩٢.٣٪ وقيمة تنبؤية سلبية ٧١.٤٪ مقارنة مع نتائج التصوير الإشعاعي الرقمي للثدي بدون صبغة التي كانت 71.4%, 90.9% and 55.6% على التوالي.

الإستنتاج: التصوير الإشعاعي الرقمي للثدي المعزز بالصبغة هو فحص واعد لزيادة حساسية والدقة التشخيصية للتصوير الماموجرام التقليدي للثدي في متابعة المريضات بعد جراحة الثدي التحفظية.