

## Bladder Sparing Protocol with Tri Modality Therapy (TMT) “A Prospective Study”

SAMI A. ABBAS, M.D.\*<sup>1</sup>; ALAA A. EL-SHENNAWY, M.D.\*<sup>2</sup>; AYMAN M. EDREES, M.D.\*<sup>3</sup>;  
MOHAMMAD K. SAIFELNASR, M.D.\*; MOHAMED FAWZY, M.D.\* and  
MARWA N. ABDEL-HAFEZ, M.D.\*\*<sup>4</sup>

*The Departments of Urology & Nephrology\*<sup>1</sup> and Pathology\*\*<sup>2</sup>, National Institute of Urology & Nephrology, Cairo, Egypt<sup>1</sup> and Departments of Nephrology, Faculties of Medicine, Al-Azhar Girls University<sup>2</sup>, Faculties of Medicine, Al-Fayoum University<sup>3</sup> and National Cancer Institute, Cairo University, Egypt<sup>4</sup>*

### Abstract

**Background:** To evaluate the response of the modern bladder-preservation treatment modality; trimodal therapy (TMT) in muscle-invasive bladder cancer (MIBC). Aiming at bladder preservation in MIBC, TMT was to offer a quality-of-life advantage and avoid potential morbidity and mortality of radical cystectomy (RC) without compromising oncologic outcomes.

**Aim of Study:** To investigate the TMT as a treatment option for muscle-invasive bladder cancer confirmed by cancer specific and overall survival rates in two different institutes.

**Material and Methods:** The study included 64 consecutive patients between 2008 and 2013, and was conducted in National Institute of Urology and Nephrology, Cairo, Egypt, Al-Azhar University, Girls Div., Urology Dept., Cairo, Egypt and National Cancer Institute, Cairo University, Cairo, Egypt. Forty nine patients were males and 15 were females. Mean age was 61 ± 9 years (range, 34-82 years). Sixty nine percent of patients (44) were below 65 years old while 31% (20) were above 65. Sixty six percent (42 patients) were fit for surgery but refused RC as first line of treatment and 34% (22 patients) were unfit for surgery.

**Results:** One third of patients (20) failed TMT and under went RC. Five years overall survival (OS) was 57% and disease specific survival (DSS) was 61%. There was no significant difference observed in OS or DSS between different age, sex or surgical fitness patients groups. Tumor stage showed significant statistical difference between T2 and T3 ( $p < 0.05$ ). Lymph nodes disease progression and distant metastases were recorded in 13 and 10% with TMT respectively.

**Conclusion:** This study suggests that bladder preservation with TMT leads to acceptable outcomes comparable with RC and therefore may be considered a reasonable treatment option in well-selected patients.

**Key Words:** Bladder cancer – MIBC – Trimodal therapy – Bladder preservation.

### Introduction

**RADICAL** cystectomy (RC) remains the standard of care for patients with muscle invasive bladder cancer. However, several therapeutic strategies aimed at bladder preservation like trimodality therapy (TMT) was introduced as an alternative to cystectomy [1].

Local failure rate with conventional radiotherapy alone was disappointingly high and this approach as a monotherapy has largely been abandoned [2]. However radiation monotherapy was initially used in patients who were not candidate for surgery. The 5-year local control rate for those patients ranged from 30 to 40% while the 5-year overall survival (OS) ranged from 25 to 40% [3]. These results were inferior to those of cystectomy series for patients with MIBC where 5-year OS rates ranged from 40-60% according to clinical staging [4].

A combination between TURBT and MVAC (Methotrexat, Vinblastin, Adriamcin and Cisplatin) chemotherapy resulted in lower rates of bladder preservation than that associated with accompanied radiotherapy [5].

Bladder preservation approaches are reasonable alternative to cystectomy for patients who are medically unfit for surgery and those seeking a substitute to RC. The decision to use a bladder preserving approach is partially based on the location of the tumor, status of the uninvolved urothelium and status of the patient [6]. TMT is composed of transurethral resection of bladder tumor (TURBT) followed by radiotherapy with concurrent tumor sensitizing cisplatin based chemotherapy. This technique has recently shown improvement in local control of bladder cancer disease [7,8].

**Correspondence to:** Dr. Sami A. Abbas, The Department of Urology & Nephrology, National Cancer Institute, Cairo, Egypt

Despite the promising results of TMT, its acceptance is still not widely spread. The European association of urology and US National Comprehensive Cancer Network (NCCN) accepted bladder preservation approach as an adequate alternative to cystectomy in selected patients with T2 and T3 disease [9,10]. The 5-year OS and DSS rates are comparable with the results reported with radical cystectomy for patients with similar clinical and pathologic stage [11].

#### Objective:

The aim of this study is to investigate the TMT as a treatment option for muscle-invasive bladder cancer confirmed by cancer specific and overall survival rates in two different institutes.

### Material and Methods

The study included 64 consecutive patients between 2008 and 2013, and was conducted in National Institute of Urology and Nephrology, Al-Azhar University, Girls Div., Urology Dept., Fayoum University, Urology Dept and National Cancer Institute, Cairo University. Forty nine patients were males and 15 were females. Mean age was  $61 \pm 9$  years (range, 34-82 years). Age and sex distribution of our patients' cohort is shown in Table (1).

Table (1): Age and sex distribution.

Age	Male	Female	Total
<65 n Ys	37	7	44
65 Ys	12	8	20
Total	49	15	64

The eligibility criteria included patients with Muscle Invasive Bladder Cancer (MIBC), Transitional Cell Carcinoma (TCC) of the bladder as shown in Table (2).

Table (2): Inclusion criteria.

Tumor stage: T2-T3b, N0, M0
Tumor size: < 6 cm
No CIS
No hydro-ureteronephrosis

Twenty two patients (34%) were medically unfit for surgery, while 42 (66%) refused Radical Cystectomy (RC) as the first treatment option for their disease (Table 3).

Table (3): Patients' fitness/age.

Age	Fit	Unfit	Total
<65 n Ys	33	10	43
65 Ys	9	12	21
Total	42	22	64

Patients underwent contrast enhanced abdomino-pelvic CT to assess local tumor, upper urinary tract, lymph nodes, and abdomino-pelvic metastases. Chest X-ray and chest CT were done to exclude chest secondaries. CT brain and bone scan were commenced when clinically indicated. Complete blood picture, liver and renal function tests, urinalysis and urine cytology were done in all patients.

In all patients, cystoscopy and Trans-Urethral Resection of Bladder Tumor (TURBT) was carried out with the aim of tissue diagnosis, staging, grading and maximal safe excision of the bladder lesion.

Treatment course was conducted in a split form that composed of TURBT, concurrent Chemo-Radiotherapy (CRT), re-evaluation TURBT followed by consolidation Chemo-Radiotherapy as shown in the algorithm in Fig (1).

#### A- TURBT:

Aggressive safe TURBT was attempted in all patients. Tumor bulk, as well as, tumor margins of normally appearing bladder mucosa were included in the resection. A separate tumor base biopsy was taken. Care was taken not to exceed perivesical fat during resection. Selected site mucosal biopsies were taken from suspicious areas, as well as, random bladder biopsies to exclude carcinoma in situ (CIS). Two to four weeks later, a 2<sup>nd</sup> look TURBT was carried out before commencing chemo-radiotherapy (CRT).

#### B- Concurrent CRT:

Two to four weeks after 2<sup>nd</sup> look TURBT, concurrent chemo-radiotherapy was started.

#### a- Radiotherapy:

A total dose of 45Gy of radiotherapy was given. Radiation was delivered to small pelvis (bladder and hypogastric, obturator, external iliac and presacral lymph nodes) in fractions of 1.8Gy for 5 days a week for 5 weeks.

#### b- Chemotherapy:

Cisplatin was given in a dose of 20mg/m<sup>2</sup>/day by continuous IV infusion over 30 minutes, once per week for 5 weeks concurrently with radiotherapy.

After completion of concurrent CRT course, patients were evaluated for treatment morbidity and response by complete blood picture, serum creatinine, creatinine clearance, abdomino-pelvic CT, urine cytology.

**C- Re-evaluation TURBT:**

Four to six weeks after completion of the course of concurrent CRT, re-evaluation cystoscopy was performed. Biopsies were taken from previous tumor site (by TUR) and other suspicious bladder mucosa. Patients who had complete response (CR), i.e.; negative histopathologic results of biopsies had passed to the course of consolidation chemo-radiotherapy. Patients with NMIBC recurrence were given a complete course on intra-vesical therapy. Then after, they completed the course of TMT with strict follow-up. Others who had recurrence with MIBC were subjected to salvage cystectomy (Fig 1).

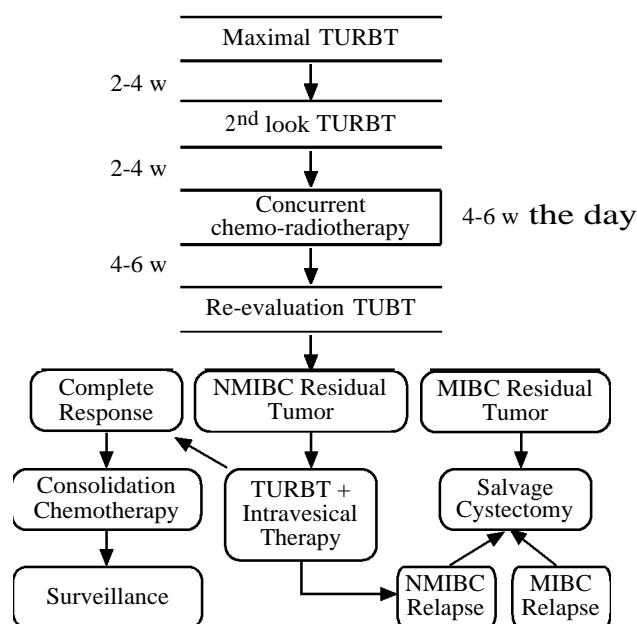


Fig. (1): Schema for organ preservation with TMT for MIBC.

**Consolidation CRT:**

Patients with CR were subjected to a course of consolidation chemo-radiotherapy.

**a- Radiotherapy:**

A total dose of 18Gy (1.8Gy/fraction for 5 days a week for two weeks) were given.

**b- Chemotherapy:**

The course consisted of:

- Cisplatin in a dose of 20mg/m<sup>2</sup>/day once per week for 2 weeks.
- Gemcitabine, 1 5-3 0mg/m<sup>2</sup>/day in 5 0- 1 00ml saline, 2-6h before radiation twice a week for 2 weeks. Escalation was considered by 5mg/m<sup>2</sup>/day according to maximal tolerated dos (MTD).

**D- Surveillance:**

In the first year, follow-up was carried out every 3 months with abdominal and pelvic CT, urine cytology and rigid cystoscopy. These procedures were also carried out every 6 months for the next 2 years and every year for the following 3 years. Bladder biopsy was performed from the site of the previous resection and any recurrent tumor or suspicious areas. After 3 years, in patients with negative evaluation, the biopsy was omitted if no worrisome endoscopic finding were present.

Clinically, complete response (CR) is considered if no tumor or suspicious lesions were detected by CT or cystoscopy and both tumor site biopsy and urine cytology were negative. The median follow up to the time of analysis for all surviving patients was about 4 years.

**Statically analysis:**

Actuarial survival curves using Kaplan-Meier method. Survival intervals were calculated from the day of the first TURBT to the time of death or the last follow-up examination. All statistical comparisons were performed using two-tailed tests.

**Results**

Of the sixty four eligible patients, 60 completed the study (48 males and 12 females). Four patients withdrew during the course of concurrent CRT and were excluded from the study.

Tumor stage and grade of the 60 evaluable patients are shown in Table (4).

Table (4): Tumor stage and grade.

	G2	G3	Total
T2	14	25	39
T3	3	18	21
<b>Total</b>	<b>17</b>	<b>43</b>	<b>60</b>

In patients with stage T3 (21), eighteen were having T3a (free CT, microscopic invasion of perivesical fat and free tumor base biopsy) and only 3 had T3b (extravesical mass on CT and no free tumor base on staging TURBT).

Mean and median follow-up periods were 45 (range 28-68mo) and 50mo respectively. Survival intervals were calculated from the day of the first TURBT to the time of death or the last follow-up examination. Of the 60 patients who completed the study, 1/3 of them (20) underwent radical cystectomy (RC) due to tumor recurrence (16 were diagnosed on re-evaluating TURBT as MIBC). Ten

patients had NMIBC recurrence on follow-up cystoscopies. Six had intra-vesical therapy and completed the study with no recurrence and 4 were converted to RC as they developed tumor relapse (one MIBC and 3, NMIBC) (Table 5).

Table (5): Distribution of T2 & T3 for TMT/RC.

	c TMT*	RC	Total
T2	27	12	39
T3	13	8	21
Total	40	20	60

\* Continue TMT.

Five years overall survival (OS) and disease specific survival (DSS) were 57% and 61% respectively (Table 6).

Table (6): 5 Years OS, rates/stage.

	c TMT*		RC		Total	
	n*	%	n*	%	n*	%
T2	18	67	6	50	24	62
T3	7	54	3	38	10	48
Total	25	63	9	45	34	57

\* Continue TMT. n: Number.

OS and DSS in relation to age, surgical fitness, sex and tumor stage are shown in Table (7).

Table (7): Survival outcome of TMT according to patients and tumor characteristics.

	n	OS	DSS
<b>Age:</b>			
<65	41	55%	65%
65	19	51%	59%
<b>Fitness:</b>			
Fit	40	56%	63%
Unfit	20	53%	56%
<b>Sex:</b>			
F	12	59%	60%
M	48	52%	64%
<b>Stage:</b>			
T2	39	62%	71%
T3	21	48%	53%

No significant differences were noted as regard age, sex or surgical fitness groups. The only significance was recorded in tumor stage ( $p < 0.05$ ).

Pelvic lymph node disease progression was recorded in 8 cases (4 in RC cases). In the 4 patients who completed TMT course, one was directed to RC and the other 3 cases were followed for 4 years with no signs of local or distant progression. Fig. (2): Rates of OS & DSS according to clinical tumor stage.

Distant metastases were recorded in 6 patients (4 in RC cases and 2 who continued TMT). All were T3, G3 cases and were transferred to systemic chemotherapy.

### Discussion

The standard of care for transitional-cell muscle invasive bladder cancer (MIBC) is radical cystectomy (RC) with bilateral pelvic lymph node dissection (PLND). All modalities of treatment have to be compared with this for assessing efficacy, survival and quality of life. Bladder preservation schemes were initially developed as a palliative alternative for patients who were not amenable to radical cystectomy or refused this surgery [12]. Adequate local control cannot be achieved with transurethral resection of the bladder tumor (TURBT), chemotherapy or radiotherapy, when used alone [13]. Several groups have reported the value of combining all three modalities (Tri-Modality Therapy, TMT), with salvage cystectomy being reserved for patients with incomplete response or local relapse. Cumulative experience has gradually refined the procedures and patient selection and today it may be stated that the bladder can be preserved in selected patients without compromising survival rates [14]. Hence, TMT, with maximal TURBT, radiation therapy, and concurrent chemotherapy has been tried, and this has shown to produce 5 and 10 year overall survival rates comparable to radical cystectomy [15].

The best candidates for TMT are those with solitary tumor, small size (<5 cm), early stage (T2-T3 disease), without surrounding carcinoma in situ (CIS), a complete TURBT, a normal renal function and without hydronephrosis, pelvic lymph node or distant metastases [16,17]. In the current study, patients with almost the same criteria were included.

Although bladder preservation strategies have often been perceived to result in inferior cancer-related outcomes as compared with radical cystectomy, a randomized trial to support this conclusion does not exist [17]. This therapy is generally well tolerated and has been shown to produce survival rates comparable to those of radical cystectomy in indirect comparisons with large surgical series [18].

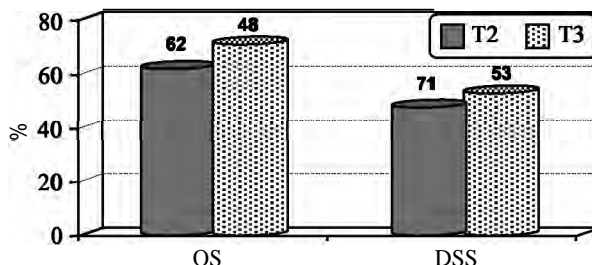


Fig. (2): Rates of OS & DSS according to clinical tumor stage.

The gold standard treatment for MIBC is radical cystectomy with pelvic lymph node dissection [15]. Nevertheless, as a result of the presence of micrometastasis, only 50% of patients (35-75%) are cured by cystectomy [19,20].

Tri-modality treatment had shown to produce 5-year and 10-year overall survival (OS) rates comparable to those of radical cystectomy. Currently, 5-year OS rates range from 50 to 67% with this approach and 75% of surviving patients preserve their bladder [15,16,17]. The current data suggest that this TMT provides high response rates and can be offered as an alternative option to radical cystectomy in selected patients without deferring survival probability [21].

The current study demonstrated that 5 years OS and DSS were 57% and 61% respectively. Seventy four percent of surviving patients preserved their bladders.

Multivariate analysis demonstrated that the Pathological stage, nodal involvement, positive surgical margins, patient's age at surgery, and loss of histologic differentiation were predictive of poor cancer-specific survival in RC series. CIS was found not to have a negative influence on cancer-specific survival [22,23]. Five years OS rates were 60% and 33% for T2 and T3 respectively whereas, DSS were 69% and 37% [15,29].

Among patients undergoing TMT, 5 and 10 yr OS rates were 52% and 35%, (T2 : 61% and 43%, T3-4 : 41% and 27%) respectively. Only 22% required cystectomy. TMT achieves preservation of the native bladder in more than 70% of patients while offering long-term survival rates comparable to contemporary cystectomy series [6].

In our study, 5 years OS for T2 and T3 were 62% and 48% respectively. Five years DSS were 71% and 53% for T2 and T3 respectively and were comparable to the results recorded in the literatures. RC was performed in 1/3 of patients.

Age, sex and surgical fitness were not predictive factors affecting the outcome of TMT [25]. This was also noted in our study.

Early and late morbidity after radical cystectomy can be problematic. Even the construction of a neobladder can not be a substitute for a person's original bladder and is also associated with both acute and long term metabolic, neuro-mechanical and sexual complications [26].

Majority of patients with MIBC present above the age of 60 years. Naturally, it follows that

medical co-morbidities are frequent compounding problems in the management of bladder cancer [27]. TMT with bladder preservation strategy is attractive for older patients with bladder cancer whose co-morbidities may place them at greater risk for short- and long-term complications related to surgery [17].

In TMT and selective bladder preservation, efforts should be exerted to identify factors that may predict treatment response, risk of relapse, and survival [25]. When undergoing trimodal therapy, the extent of TUR correlates with outcome [28,29]. Five and 10 years OS rates of 57% and 39% were recorded for patients with a visibly complete TUR respectively, while these rates were 43% and 29% in patients with visibly incomplete TUR. Additionally, the rates of RC for visibly complete and incomplete TUR were 22 and 42% respectively [8]. In our study, only 3 patients had incomplete TURBT (T3b).

Superficial recurrence was noted in 26% of patients treated with TMT [30]. No significant difference in 5-year survival between those with superficial recurrence and those that remained free of disease.

In our study, recurrence with NMIBC was experienced in 10 patients (17%). Four of them were subjected to RC (1 had MIBC relapse and 3 had NMIBC relapse after intra-vesical therapy). The other 6 patients continued TMT with no recurrence.

TMT still run the risk of failure and subsequent need for salvage RC. Rates of progression to salvage RC vary between studies and have been described as about one-third of patients [31]. In our study, MIBC relapse were noted in 17 patients (28%) and were subjected to RC.

Among patients showing CR, 10-yr rates of pelvic lymph nodes and distant recurrences were 11%, and 32%, respectively [6,25].

In the current study, pelvic lymph node disease progression was recorded in (13%) 8 cases (4 in RC cases). In the 4 patients who completed TMT course, one was directed to RC (local relapse) and the other 3 cases were followed for 3 years with no signs of local or distant progression. Distant metastases were recorded in 6 cases (10%) (4 in RC cases and 2 who continued TMT). All were transferred to systemic chemotherapy.

Good responders with intact bladders have to be followed closely by cystoscopy and CT or magnetic resonance imaging (MRI) surveillance,

with prompt salvage RC in cases of invasive recurrence. Authors also recommended systematic tumor-site rebiopsy (routine resection rather than a cold cup biopsy of the tumor scar) and bimanual examination under general anesthesia at the first assessment following TMT. Subsequent 2-3 cystoscopic evaluations over the next 9-12mo may include routine cold-cup biopsies. Nevertheless, no recommendation can be made concerning the follow-up interval subsequent to the initial assessment. Voided urine cytology is obtained before each evaluation. In addition to the bladder, it is recommended that the urologist perform risk-adapted surveillance for distant metastasis and the upper tract [9]. In our study, similar surveillance protocol was followed.

Sophisticated techniques for urinary diversion after RC have been developed to improve patients' quality of life. Even the construction of a neobladder with continent urinary diversion, however, cannot substitute for the patient's original bladder [32]. One of the frequent arguments against trimodality approach is the lack of prospective QOL data. Recently, the Study Group on Genito-Urinary Tumors provided results of a prospective evaluation both by investigators and patients on quality of life for bladder preservation. This study reported 67% with good quality of bladder function and 79% of preserved sexual function [2,26,33]. Urodynamic study in preserved bladder showed good bladder function (75%) after TMT [34].

#### *Conclusion:*

Recent data appear to indicate that bladder preservation strategies with tri-modality approaches in bladder cancer has come of age and should be considered as an alternative first line treatment to radical surgery in selected group of patients with MIBC.

Proper patient selection, patient education regarding realistic goals in bladder preservation and multidisciplinary coordination and cooperation are all vital in producing the best possible outcome and survival of TMT.

Majority of patients with MIBC present above the age of 60 years. TMT with bladder preservation strategy is attractive for those older patients with bladder cancer whose co-morbidities may place them at greater risk for complications related to surgery.

The close collaboration of urologists, radiation oncologists and medical oncologists is of paramount importance in succeeding in bladder preservation.

Future investigations will focus on optimizing radiation techniques, more effective systemic therapy, molecular markers, targeted biologic agents and translational research to identify molecular predictors to chemo-radiation.

#### **References**

- 1- GAKIS G., EFSTATHIOU J., LERNER S.P., et al.: ICUD-EAU International Consultation on Bladder Cancer 2012: radical cystectomy and bladder preservation for muscle-invasive urothelial carcinoma of the bladder. *Eur. Urol.*, 63: 45-57, 2013.
- 2- SHIPLEY W.U., KAUFMAN D.S., ZEHR E., HENEY N.M., LANE S.C., THAKRAL H.K., et al.: Selective bladder preservation by combined modality protocol treatment: longterm outcomes of 190 patients with invasive bladder cancer. *Urology*, 60: 62-8, 2002.
- 3- ALUWINI S., VAN ROOIJ P.H., KIRKELS W.J., et al.: Bladder function preservation with brachytherapy, external beam radiation therapy, and limited surgery in bladder cancer patients: Long-term results. *Int. J. Radiat. Oncol. Biol. Phys.*, 88: 611-17, 2014.
- 4- SHABSIGH A., KORETS R., VORA K.C., et al.: Defining early morbidity of radical cystectomy for patients with bladder cancer using a standardized reporting methodology. *Eur. Urol.*, 55: 164-76, 2009.
- 5- KIM H.L. and STENBERY G.D.: Complication of cystectomy in patients with a history of pelvic irradiation. *Urology*, 58: 557-60, 2001.
- 6- EFSTATHIOU J.A., SPIEGEL D.Y., SHIPLEY W.U., HENEY N.M., KAUFMAN D.S., ZIETMAN A.L., et al.: Long-Term Outcomes of Selective Bladder Preservation by Combined-Modality Therapy for Invasive Bladder Cancer: The MGH Experience. *Eur. Urol.*, 55: 177-86, 2009.
- 7- TESTER W., PORTER A., ASBELL S., et al.: Combined modality program with possible organ preservation for invasive bladder carcinoma: Results of RTOG protocol 85-12. *Int. J. Radiat. Oncol. Biol. Phys.*, 25: 783-90, 1993.
- 8- ZACHARY L.S., JOHN P.C., STEPHEN M.K., MALKOWICZ S.B. and GUZZO T.J.: Bladder preservation in the treatment of muscle-invasive bladder cancer (MIBC): A review of the literature and a practical approach to therapy. *BJUI*, 112: 13-25, 2013.
- 9- PLOUSSARD G., DANESHMAND S., EFSTATHIOU J.A., et al.: Critical analysis of bladder sparing with trimodal therapy in muscle-invasive bladder cancer: A systematic review. *Eur. Urol.*, 66: 120-13 7, 2014.
- 10- NCCN Guidelines, National Comprehensive Cancer Network: Bladder cancer. [http://www.nccn.org/professionals/physician\\_gls/pdf/bladder.pdf](http://www.nccn.org/professionals/physician_gls/pdf/bladder.pdf), 2015.
- 11- RÖDEL C., GRABENBAUER G.G., KÜHN R., et al.: Combined modality treatment and selective organ preservation in invasive bladder cancer: Long-term results. *J. Clin. Oncol.*, 20: 3061-71, 2002.
- 12- RÖDEL C., WEISS C. and SAUER R.: Trimodality treatment and selective organ preservation for bladder cancer. *J. Clin. Onco.*, 24: 5536-44, 2006.

- 13- JAMES N.D., HUSSAIN S.A., HALL E., et al.: Radiotherapy with or without chemotherapy in muscle-invasive bladder cancer. *N. Engl. J. Med.*, 366: 1477-88, 2012.
- 14- MAYANS A.R., COSTA D.R., BERGERA J.Z., ZUAZU J.R., ABAD J.B., EIZAGUIRRE E.T., VARGAS L.R. and PIEDROLA I.P.: Response and progression-free survival in T2 to T4 bladder tumors treated with trimodality therapy with bladder preservation. *Actas. Urol. Esp.*, 34: 775-80, 2010.
- 15- BEENA K., NAMBIAR V.R. and DINESH M.: Trimodality treatment in Muscle Invasive Bladder Cancer-What is the current status? *Amrita J. Med.*, 9: 14-21, 2013.
- 16- KHOSRAVI-SHAHI P. and CABEZÓN-GUTIÉRREZ S.L.: Selective organ preservation in muscle-invasive bladder cancer: Review of the literature. *Surg. Oncol.*, 21: 17-22, 2012.
- 17- BALAR A., BAJORIN D.F. and MILOWSKY M.I.: Management of invasive bladder cancer in patients who are not candidates for or decline cystectomy. *Ther. Adv. Urol.*, 3: 107-17, 2011.
- 18- KAUFMAN D.S., WINTER K.A. and SHIPLEY W.U.: The initial results in muscle-invading bladder cancer of RTOG 95-06: Phase I/II trial of transurethral surgery plus radiation therapy with concurrent cisplatin and 5-fluorouracil followed by selective bladder preservation or cystectomy depending on the initial response. *Oncologist*, 5: 471-76, 2000.
- 19- RAGHAVAN D., SHIPLEY W.U., GARNICK M.B., et al.: Biology and management of bladder cancer. *N Engl J Med.*, 322: 1129-38, 1990.
- 20- MAAROUF A.M., KHALIL S., A. SALEM E., ELADL M., NAWAR N. and ZAITON F.: Bladder preservation multimodality therapy as an alternative to radical cystectomy for treatment of muscle invasive bladder cancer. *BJUI*, 107: 1605-10, 2013.
- 21- DANESI D.T., ARCANGELI G., CRUCIANI E., ALTAVISTA P., MECOZZI A., SARACINO B. and OREFICI F.: Treatment of Invasive Bladder Carcinoma by Transurethral Resection, Protracted Intravenous Infusion Chemotherapy, and Hyperfractionated Radiotherapy: Long-Term Results. *Cancer*, 101: 2540-8, 2004.
- 22- FRAZIER H.A., ROBERTSON J.E., DODGE R.K. and PAULSON D.F.: The value of pathologic factors in predicting cancer-specific survival among patients treated with radical cystectomy for transitional cell carcinoma of the bladder and prostate. *Cancer*, 71: 3993-4001, 1993.
- 23- STEIN J.P., LIESKOVSKY G., COTE R., GROSHEN S., FENG A.C., BOYD S., SKINNER E., BOCHNER B., THANGATHURAI D., MIKHAIL M., RAGHAVAN D. and SKINNER D.G.: Radical cystectomy in the treatment of invasive bladder cancer: Long-term results in 1,054 patients. *J. Clin. Oncol.*, 19: 666-75, 2001.
- 24- GHONEIM M.A., EL-MEKRESH M.M., EL-BAZ M.A., EL-ATTAR I.A. and ASHAMALLAH A.: Radical cystectomy for carcinoma of the bladder: Critical evaluation of the results in 1,026 cases. *J. Urol.*, 158: 3 93-9, 1997.
- 25- WRIGHT J.L., LIN D.W. and PORTER M.P.: The association between extent of lymphadenectomy and survival among patients with lymph node metastases undergoing radical cystectomy. *Cancer*, 112: 2401-08, 2008.
- 26- HENNINGSOHN L., WIJKSTROM H., DICKMAN P.W., et al.: Distressful symptoms after radical radiotherapy for urinary bladder cancer. *Radiotherapy Oncol.*, 62: 215-25, 2002.
- 27- FIGUEROA A.J., STEIN J.P., DICKINSON M., SKINNER E.C., THANGATHURAI D., MIKHAIL M.S., BOYD S.D., LIESKOVSKY G. and SKINNER D.G.: Radical cystectomy for elderly patients with bladder carcinoma: an updated experience with 404 patients. *Cancer*, 83: 141-7, 1998.
- 28- CHOEIRI T.K. and RAGHAVAN D.: Chemotherapy for muscle-invasive bladder cancer treated with definitive radiotherapy: Persisting uncertainties. *Nat. Clin. Pract Oncol.*, 5: 444-54, 2008.
- 29- EFSTATHIOU J.A., SPIEGEL D.Y., SHIPLEY W.U., et al.: Long-term outcomes of selective bladder preservation by combined-modality therapy for invasive bladder cancer: The MGH experience. *Eur. Urol.*, 61: 705-11, 2012.
- 30- ZIETMAN A.L., GROCELA J., ZEHR E., et al.: Selective bladder conservation using transurethral resection, chemotherapy, and radiation: management and consequences of T<sub>a</sub>, T<sub>1</sub>, and T<sub>is</sub> recurrence within the retained bladder. *Urology*, 58: 380-5, 2001.
- 31- RENE N.J., CURY F.B. and SOUHAMI L.: Conservative treatment of invasive bladder cancer. *Curr. Oncol.*, 16: 36-47, 2009.
- 32- CHOUDHURY A., SWINDELL R., LOGUE J.P., ELLIOTT P.A., LIVSEY J.E., WISE M., et al.: Phase II study of conformal hypofractionated radiotherapy with concurrent gemcitabine in muscle-invasive bladder cancer. *J. Clin. Oncol.*, 29: 733-8, 2011.
- 33- LAGRANGE J., MOLLEVI C.B., GEOFFROIS L., et al.: Quality of Life assessment after concurrent chemoradiation for invasive bladder cancer: Results of a multicentre prospective study (GETUG 97-015). *Int. J. Radiat. Oncol. Biol. Phys.*, 79: 172-8, 2011.
- 34- ZIETMAN A.L., SACCO D., SKOWRONSKI U., et al.: Organ conservation in invasive bladder cancer by transurethral resection, chemotherapy and radiation: Results of a urodynamic and quality of life study on long term survivors. *J. Urol.*, 170: 1772-6, 2003.

## الحفاظ على المثانة البولية عن طريق إستخدام العلاج ثلاثى التدخل

إن سرطان المثانة الموهل فى الجدار أحد الأسباب الرئيسية لوفاة الإنسان وبعد إستئصال المثانة الجذرى وتحويل مجرى البول بأحدى الطرق المعروفة هو العلاج الأمثل لمثل هذه الحالات. يقدم العلاج الثلاثى التحفظى لهذا المرض متضمناً إستئصال الورم بالمنظار الضوئى مع إعطاء جرعات كيميائية وإشعاعية محددة طريقة جديدة وفعالة للعلاج.

أثبتت نتائج هذا البحث ومثيله من الأبحاث التى سبقته أن هذا العلاج الثلاثى يعطى نتائجاً مقاربة بل مماثلة للعلاج بالاستئصال الجذرى للمثانة مع الحفاظ على المثانة الأصلية للمريض. تحتاج هذه الطريقة لمواصلة الأبحاث والتعاون بين جراحى المسالك البولية وأطباء العلاج الإشعاعى والكيميائى للوصول إلى النتائج المثلى.