

Metabolic Acidosis after Orthotopic Detubularized Ileocaecal Pouch versus Ileal Neobladder (Y Pouch)

ABDALLA M. EL-AZAB, M.Sc.; SHARIF ABD AL-KARIM, M.Sc.; MOHAMMED S. MOHAMMED, M.D. and AMRO A. ATTIA, M.D.

The Department of Surgical Oncology, National Cancer Institute, Cairo University, Egypt

Abstract

Background: To compare metabolic acidosis early and late following orthotopic detubularized ileocaecal pouch versus ileal neobladder (Y pouch) after radical cystectomy for invasive urinary bladder cancer.

Aim of Study: To compare metabolic acidosis early and late following orthotopic detubularized ileocaecal pouch versus ileal neobladder (Y pouch) after radical cystectomy for invasive urinary bladder cancer.

Patients and Methods: Patients presenting to the National Cancer Institute, Cairo University from March 2014 to April 2015; Acid base disturbance and metabolic acidosis were measured in 31 patients with orthotopic detubularized ileocaecal pouch versus 31 patients with ileal neobladder (Y pouch) with mean follow-up every 2 months for 1 year post-operative.

Results: In ileal neobladder (Y pouch), Mild Metabolic acidosis was noticed in seven patients (25.9%) in comparison to nine patients (32.1%) in orthotopic detubularized ileocaecal pouch with no significant changes between both groups.

Conclusion: There is no significant difference in relation to metabolic acidosis between orthotopic detubularized ileocaecal pouch versus ileal neobladder after radical cystectomy.

Key Words: Metabolic acidosis – Orthotopic diversion.

Introduction

LONG-TERM follow-up of urinary diversion usually focuses on two important aspects; metabolic aspects and specific complications of different types of urinary diversions [1]. Metabolic complications can be minimized by careful patient selection, choosing of the appropriate bowel segment, and meticulous and strict follow-up. There are important measures that should be taken to prevent metabolic dysfunction. These measures are keeping good renal function, regular voiding to completion, sterile urine and normal blood gas analysis [2].

Correspondence to: Dr. Abdalla M. El-Azab,
[E-mail: dr_abdallaazab@hotmail.com](mailto:dr_abdallaazab@hotmail.com)

Hyperchloremic acidosis is prevalent well-known clinical finding following continent diversion where urine comes in contact with the whole colonic mucosa. However, chloride absorption and bicarbonate excretion are more pronounced in the colon, and there is evidence suggesting that inherent chloride absorption is maintained when in long contact with urine. To reduce the risk of hyperchloremic acidosis particularly in patient with renal impairment, ileum should be used rather than colon for bladder reconstruction [3]. In patients with a continent urinary diversion, logically the time of contact of urine is markedly longer and the exposed surface area of bowel mucosa to urine is much larger and consequently this longer contact can lead to a higher incidence of electrolyte disturbances with metabolic acidosis and may reach up to 50% of patients [1]. In these patients, the elevated concentration of serum chloride is associated with a decrease in base excess. Therefore, treatment of hyperchloremic acidosis consists of administration of alkalinizing agents. Prophylactic alkali substitution should be commenced at a base excess below -2.5 mmol/L, aiming at avoiding the long-term complications of clinically evident acidosis [3].

Patients and Methods

Carcinoma of urinary bladder cases attending NCI from March 2014 to April 2015 fulfilling these criteria were included:

- Muscle invasive bladder cancer with no involvement of prostatic urethra with no history of urinary incontinence or urethral structure, Serum creatinine less than 1.50 umol/l and no known disease of the intestine.

Hyperchloremic acidosis was evaluated every 2 months starting from the date of surgery for 1 year.

Between March 2014 to April 2015, 62 cases of bladder cancer were recruited and met the inclusion criteria for orthotopic neobladder reconstruction following radical cystectomy; they are arranged into 2 groups:

- Group A represents 31 patients with orthotopic detubularized ileal neobladder (Y pouch) in which all pouches formed via non absorbable lineal staplers
- Group B represents 31 patients with orthotopic detubularized ileocaecal neobladder in which 17 patients pouches formed through manual techniques and another 14 patient pouches formed through non absorbable lineal staplers.

Surgical technique:

After radical cystectomy in males and anterior pelvic exenteration in females with bilateral pelvic lymphadenectomy till the bifurcation of common iliac vessels with preservation of neurovascular bundles, Y pouch as example of detubularized ileal pouch and detubularized ileocaecal pouch will be done accordingly:

Y pouch:

The procedure entails the following 10:

After radical Cystectomy in males or anterior pelvic exenteration in females with urethral sphincter sparing. Taking about 40cms of the distal ileum after sparing 15-20cms from the ileocaecal junction. Separating this loop of ileum with its mesentery and performing an ileo-ileal anastomosis by hand sewing or lineal stapler then the isolated intestinal segment was arranged in a Y-shape with two central segments of 15cm and two limbs of 5cm. The two central segments were brought together and detubularized, with a non-absorbable mechanical stapler inserted through an opening made at the lowest point of the neobladder. A small puncture at the curved tip is performed and then 15cms are detubularized by a linear stapler leaving 5cms at the end of each limb with closed ends.

Urethral anastomosis will be performed over a three-way 22f silicone catheter in which the Y-neobladder will be anastomosed to the urethra with five sutures of 2-0 polyglycolic acid. The ureters are then anastomosed after spatulation (retroperitoneally either end to end or end to side to the ipsilateral Y pouch arm after insertion of a ureteric stent of French size 4.5 with the end extruded in the three-way catheter from the urethral opening. Water tightness is checked intraoperatively using colored water soluble agent and lastly the two limbs will be fixed to the psoas muscles.

Detubularized ileocaecal pouch [5]:

After radical Cystectomy in males or anterior pelvic exenteration in females with urethral sphincter sparing, mobilization of the right colon till the hepatic flexure will be done then the segments of 10-15cm of equal length will be isolated at the terminal ileum and the cecum and ascending colon. Bowel continuity will be restored with ileocolonic anastomosis.

The isolated bowel will be prepared by irrigation with saline and povidone iodine with removal of the appendix and other adhesions. The antimesenteric borders of both the ileum and cecum will be approximated with running absorbable sutures, followed by complete incision of these borders 5mm away from the sutures. The free edges will be sutured to form the second posterior layer.

Distal end of the opened pouch will be then sutured to the urethra first, to avoid tension on the ureteric-pouch anastomoses, using 4-6 interrupted 2/0 vicryle over three ways 22F silicon catheter. Ureters will be implanted with 4/0 interrupted vicryle sutures over ureteric stents brought through the anterior abdominal wall or urethra. Lastly the anterior wall of the pouch will be then closed in two layers allowing the ureteric stents to come through. Also detubularization will be also performed using linear stapler in 2-3 sequential steps till the ileocaecal valve which will be also opened.

Follow-up:

Early follow-up in the form of general and local observation such as vital signs, complete labs, drains, wound infection, urinary leakage. On the 14th to the 21st day, after exclusion of leaks by routine cystography, the indwelling catheter will be removed and patients will initiate spontaneous voiding via the Valsalva's maneuver in a sitting position every 2 hours.

Arterial blood gases will be investigated routinely every 3 days and on suspecting acidosis. Patients will have a follow-up at 2 months interval for 1 year. Follow-up consist of Arterial blood gases, abdominal US to assess residual urine volume and renal back pressure, chest X-ray, excretory urography, CT abdomino-pelvic and relevant serum investigations.

Statistical analysis:

Results will be analyzed using SPSS (statistical package of social science version 12). Numerical data was be expressed as mean, standard deviation (SD) or median and range as appropriate. Qualitative data will be expressed as frequency and per-

centage. Chi-square test or Fisher's exact test will be used to examine the relation between qualitative variables and *t*-test or Mann-Whitney for quantitative factors as appropriate, *p*-value will be significant if <0.05 .

Results

Group A represents 31 patients with orthotopic detubularized ileal neobladder (Y pouch) in which all pouches formed via non absorbable lineal staplers.

Group B represents 31 patients with orthotopic detubularized ileocaecal neobladder in which 17 patients pouches formed through manual techniques and another 14 patient pouches formed through non absorbable lineal staplers.

Metabolic acidosis:

In group A, Mild Metabolic acidosis was recorded in seven patients (25.9%) in comparison to nine patients (32.1%) in group B with no significant changes between both groups (*p*-value is 0.768).

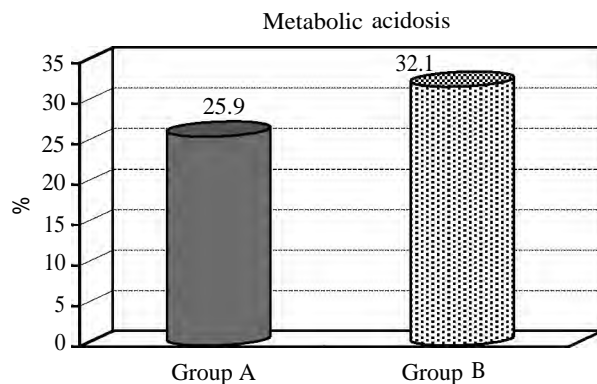


Fig. (1): Metabolic acidosis

Discussion

Following bladder reconstruction with the bowel, detectable subclinical metabolic disturbance is common; however, clinically significant metabolic complications are rare. Patients with significant renal impairment, dehydration or poor neobladder emptying are at greatest risk, so vigilant long-term follow-up is required for all patients to try and maintain adequate electrolyte and fluid intake along with regular and complete neobladder emptying. Oral bicarbonate is sufficient for most patients to prevent significant metabolic acidosis [6]. In our study, Mild Metabolic acidosis was recorded in about (25.9%) in group A in comparison to (32.1%) in group B with no significant changes between both groups, all cases were treated with oral bicarbonate alkali two to three times daily, also all

patients in this study routinely received oral bicarbonate alkali as prophylactic treatment against metabolic acidosis. Nearly the similar results were reported by Beduk et al., [7] and Kulkarni et al., [8] which also comparing ileal to ileocaecal neobladder. Pfitzenmaier et al., [9] reported metabolic changes as a common complication in which one third of patients needed alkali and vitamin B12 for life (37% and 32%, respectively). But Khafagy et al., [10] reported that acidosis is more common in ileal neobladder than ileocaecal neobladder and he explain this as it may be due to large surface area of ileal neobladder with more contact with urine. From these result we observed that there is no significant difference between both groups in relation to metabolic acidosis.

Conclusion:

There is no significant difference in relation to metabolic acidosis between orthotopic detubularized ileocaecal pouch versus ileal neobladder (Y pouch) after radical cystectomy.

References

- 1- STEIN R. and RUBENWOLF P.: Metabolic Consequences after Urinary Diversion. *Front Pediatr*, 2: 15, 2014.
- 2- MOON A., VASDEV N. and THORPE A.C.: Continent urinary diversion. *Indian J. Urol.*, 29 (4): 303-309, 2013.
- 3- VASDEV N., MOON A. and THORPE A.C.: Metabolic complications of urinary intestinal diversion. *Indian J. Urol.*, 29 (4): 310-315, 2013.
- 4- FONTANA D.: Y-neobladder: An easy, fast, and reliable procedure. *Urology*, 4 (63): 699-703, 2004.
- 5- PETER N., KOLETTIS ERIC A., KLEIN A.C., NOVICK J., CHRISTIAN W., RODNEY A. and APPELL A.: The Le Bag Orthotopic Urinary Diversion. *Journal of Urology*, 156: 926-930, 1996.
- 6- ROBERT MILLS: Keys to Successful Orthotopic Bladder Substitution, Bowel Segments in the Urinary Tract, Metabolic Consequences, ebook Chapter 8: p. 105-115, 2015.
- 7- BEDUK Y., KADIRTURKOLMEZ S.B. and CAGATAY G.: Comparison of clinical and urodynamic outcome in orthotopic ileocaecal and ileal neobladder. *European Urology*, 43: 258-262, 2003.
- 8- KULKARNI J.N., PRAMESH C.S., RATHI S. and PANTVAIDYA G.H.: Long-term results of orthotopic neobladder reconstruction after radical cystectomy. *BJU International*, 91: 485-488, 2003.
- 9- PFITZENMAIER J., LOTZ J., FALDUM A., BERINGER M., STEIN R. and THUROFF J.W.: Metabolic evaluation of 94 patients 5 to 16 years after ileocecal pouch (Mainz pouch 1) continent urinary diversion. *J. Urol.*, 170: 1884-7, 2003.
- 10- KHAFAGY M., SHAHEED F.A. and MONEIM T.A.: Ileocaecal vs ileal neobladder after radical cystectomy in patients with bladder cancer: A comparative study. *BJU Int.*, 97 (4): 799-804, 2006.

المقارنة بين إستخدام الأمعاء والقولون الأنبوبية مقابل الأمعاء الأنبوبية لعمل مثانة صناعية (المضاعفات)

الهدف من هذه الرسالة هو تقييم إستخدام الأمعاء والقولون الأنبوبية مقابل الأمعاء الأنبوبية لعمل مثانة صناعية وكذلك تحليل مضاعفات ما بعد الجراحة حسب معايير دولية ثابتة وذلك لتقديم بدائل بسيطة وفعالة للمثانة البولية بعد الاستئصال الجذرى للورم.

تم إجراء هذه الجراحة على مريضا، وذلك للمقارنة بين إستخدام الأمعاء والقولون الأنبوبية مقابل الأمعاء الأنبوبية لعمل مثانة صناعية بهدف تحليل النتائج الوظيفية والمضاعفات ومعدلات التحكم فى البول مع مقارنة تلك النتائج بما قد تم نشره دولياً فى هذا الصدد وقد أظهرت النتائج أنها طريقة أمنه جراحياً مع عدم وجود اختلاف يذكر بين نتائج المجموعتين.

وأخيراً فإن عملية استئصال المثانة جذرياً هى العلاج الأساسى لسرطان المثانة، ولكن المشكلة الرئيسية هنا ليست استئصال المثانة جذرياً، إنما كيفية تحويل البول بطريقة يتحكم بها المريض فى التبول ، بحيث لا تخل بوظائف الكلى أو التمثيل الغذائى مع تحسين نوعية حياة المرضى وقد تم تصميم هذه الدراسة على أنها تجربة عشوائية للمقارنة بين إستخدام الأمعاء الدقيقة الأنبوبية والأمعاء والقولون الأنبوبية لعمل مثانة صناعية بعد استئصال المثانة الجذرى مع معدل مقبول من المضاعفات فى كلتا المجموعتين، مقارنة بالعديد من الدراسات الدولية الأخرى.