

## Role of Ultrasonography in Evaluation of Rotator Cuff Muscle Injury

Mohammed Zaki Ali Mourad<sup>1</sup>, Medhat Ibrahim Mohamed<sup>1</sup>, Ahmed Roshdy Elagamy<sup>2</sup>, Samar Maher Mohamed<sup>1</sup>

Departments of <sup>1</sup> Diagnostic Radiology, <sup>2</sup>Rheumatology and Rehabilitation, sohag Faculty of Medicine, Sohag University

### Abstract

The term “rotator cuff” referred to the four muscles supporting the humeral head originating from the scapular anterior and posterior aspects with their tendons inserted in the lesser and greater tuberosity. These muscles are the subscapularis; supraspinatus; infraspinatus and teres minor.

**Objective:** The aim of this study was to evaluate the accuracy of musculoskeletal ultrasound in the detection of rotator cuff injuries as compared to MRI as a gold standard technique.

**Patient and methods:** This study included 30 patients presented to the radiology department of Sohag University, with shoulder pain for evaluation of the rotator cuff integrity. Ultrasonography and non-enhanced MRI were done to all patients by 2 different radiologists being blind to the results of the other examination to minimize the bias. The age of our cases had two peaks, one at the age of 50 and a smaller one at around the age of 30.

**Results:** The mean age was 42.07years, with ages ranged from 25 to 60 years.10 were males and 20 were females. In our study the sensitivity statistics of MSUS compared to MRI were as follows: sensitivity (96.6%); specificity (100%); positive predictive value (100%); negative predictive value (50%) and accuracy (98.3%).

**Conclusion:** Ultrasound has comparable accuracy with MRI for identifying rotator cuff injuries. Ultrasound can be used as screening modality since it is easily available and cost-effective.

**Keywords:** Ultrasonography, MRI, Rotator Cuff Muscle Injury

### Introduction

With tendinopathy the term rotator cuff failure is used to describe the transformation of rotator cuff tear from partial to full-thickness tears involving the supraspinatus tendon and may proceed to entangle the infraspinatus tendon and/or the subscapularis tendon. A spectrum of etiologies that can give rise to shoulder pain is cuff defects – partial and full-thickness, acute and chronic, traumatic and degenerative. Others are degenerative cuff failure, impingement syndromes, tendinitis, tendinopathy, posterior capsular tightness, subacromial abrasion, cuff tear arthropathy. Rotator cuff injury is the most common lesion

of the shoulder and early and accurate diagnosis is essential for appropriate management [1].

Tears of the rotator cuff are a common cause of shoulder pain and variable disability. Early diagnosis allows for proper conservative treatment and for surgical treatment planning that can prevent functional impairment [2].

The role of imaging in such a condition is to identify the presence of the tear and the tendon injured and its extent as tears of the cuff muscles are difficult to be identified clinically. The decision making in the treatment of the rotator cuff tears relies mainly upon the correct diagnosis of the type and extent

of the tear. According to the diagnosis, whether conservative or surgical treatment is chosen, even the type of surgical intervention (open or arthroscopic) would differ according to the diagnosis. In addition, identifying the extent of tendons retraction and the condition of the ruptured edges, as well as the quality of the muscle itself influences the management policy [3].

To evaluate the painful shoulder a variety of imaging tests have been used; yet for diagnosing a rotator cuff tear the standard imaging modalities such as unenhanced MRI, MR arthrography, and ultrasonography (US) are used. US of the shoulder is increasingly utilized in healthcare settings to assess the integrity of the rotator cuff. It is a non-invasive examination with practically no side effects. Plain MRI is a non-invasive modality that is superior in allowing imaging in multiple planes with high resolution, yet it is a static examination [3].

### Aim of the Work

1. To assess the diagnostic accuracy of US for the detection of rotator cuff muscle injury.
2. To identify tendinopathic changes, partial thickness, and full-thickness rotator cuff tears and to assess the sensitivity and specificity of the US to diagnose each of them.

### Patients and Methods

**Study design:** Prospective, descriptive study.

**Patients:** This study included 30 patients presented to the radiology department of Sohag University, with a clinical diagnosis of shoulder impingement for evaluating the rotator cuff integrity.

**Study protocol:** US and non-enhanced MRI were done to all patients by 2 different radiologists being blind to the

results of the other's examination to minimize the bias.

### Methods:

*For each patient, the following data was collected:*

1. **Demographic data:** Name, Age, Sex, Residence, and Occupation.
2. **Clinical history:** History of trauma, inflammation, instability or operations.
3. **Shoulder Ultrasound examination**



Figure(1) Ultrasound machine ( Toshiba Aplio500)

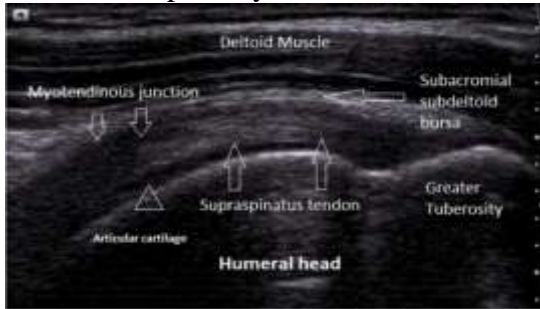
### Ultrasound protocol

- The US of the shoulder was done using a US machine ( Toshiba Aplio 500) with 12-18 MHz linear-array transducer using musculoskeletal settings with the following technique.
- The long head of the biceps is used as the landmark in the rotator cuff examination by the US. Then scanning of the subscapularis followed by the supraspinatus then the infraspinatus and teres minor muscles were performed.

### Ultrasound criteria for rotator cuff pathology:

- **Normal US :**
- The tendon parallels the curved contour of the humeral head, flattening out as it inserts onto the greater tuberosity
- It has a fibrillary pattern

- The subacromial-subdeltoid bursa should be seen as a single thin hyperechoic line paralleling the tendon superiorly



**Figure (2).** supraspinatus tendon, normal anatomy, longitudinal view[12].

- **Tendinosis:** Characterized by a heterogeneous, ill-defined, hypoechoic area in the tendon with variable change in the caliber (enlarged/thinned) without a tendon defect

- **Partial-thickness tendon tear:** Characterized by a well-defined hypoechoic or anechoic abnormality that disrupts the tendon fibers.

Interstitial tear: does not extend to the bursal or articular surface.

Articular tear: extends to the articular surface.

Bursal tear: extends to the bursal surface.

**Full-thickness tear:** Characterised by a well-defined hypoechoic or anechoic abnormality that disrupts the hyperechoic tendon fibers and extends from the articular to bursal surface of the tendon.

**Subacromial and subdeltoid bursitis:** Normally 1-2 mm of a hypoechoic layer of synovial fluid surrounded by hyperechoic bursal wall and perirenal fat layer. Any increase in the amount of bursal fluid and / or synovial thickening / echoic in the bursal fluid is considered abnormal.

**Acromioclavicular joint arthritis:** Indicated by capsular distension (more than 3 mm), bone irregularity,

osteophyte formation, joint space narrowing

- o **MRI of the shoulder was done using Magnetom Avanto scanner 1.5 T Philips with the following technique:**

- o Patient position: The patients were scanned in the supine position, with the arm by the side of the body.
- o The dorsum of the hand was parallel to the coronal plane of the magnet.
- o The circular coil was used (C 200) placed over the wrist, elbow and shoulder joints, and was rapped and fixed by rubber bands.
- o The slice thickness – 5mm.
- o Field of view (FOV)- 16 to 20 cm.
- o Sequences performed were:
  - o **Oblique coronal :** T2 FSE STIR , DUAL-DR
  - o **Oblique sagittal :** T2 FSE
  - o **Axial :** T1 FSE T2 FSE

#### **Ethical considerations:**

- Each patient in our study had oral and written consent before performing the examination.
- The study protocol was agreed by the Scientific Ethical Committee of Sohag Faculty of Medicine.

#### **Statistical analysis:**

- Statistical package for social sciences (IBM-SPSS), version 24 IBM- Chicago, USA (May 2016) was used for statistical data analysis.
- Data expressed as mean, standard deviation (SD), number and percentage. Mean and the standard deviation was used as a descriptive value for quantitative data, while number and percentage were used to describe qualitative data.
- Sensitivity statistics were done to estimate the value of musculoskeletal ultrasound in the diagnosis of supraspinatus tar taking MRI as a gold standard test.

▪ **Results**

Risk factors	No	Percent
Trauma	4	13.3 %
Lifting heavy object	6	20.0%
Foreign body penetration	1	3.3%
No definite history	19	63.4%
Total	30	100.0%

**Table (1): Risk factors**

The mean age of the study group was around 42 years, with ages ranged from 25 to 60 years. According to the following histogram, the age of our cases had two peaks, one at the age of 50 and a smaller one at around the age of 30.

Two-thirds of our cases were males, male 20 cases ( 66.7%), females 10 cases (33.3%).

This table shows that identified risk factors were detected in only one-third of the cases, with history of lifting heavy object was found in 20% of cases, while trauma was recorded in only 4 cases (13.3%) of our cases and history of foreign body penetration was found in one case. The other 19 cases showed no definite history of probable cause of rotator cuff injury.

Mean	9.00 months
Median	9.00 months
Std. Deviation	4.495
Minimum	2 months
Maximum	18 months

**Table (2): Disease duration of the study group**

This table and figure are showing that the mean disease duration of our study population was 9 months, with a wide range from 2 months to 1.5 years.

	No	Percent
Pain	5	16.7%
Shoulder dislocation	1	3.3%
No definite clinical symptoms	24	80%
Total	30	100.0 %

**Table (3): Clinical manifestations**

This table shows that pain was the presenting symptom in 5 of our cases, while shoulder dislocation was present in one case.

	No	Percent
Joint effusion	Non	23 76.7
	Minimal/Mild	5 16.7
	Moderate	2 6.7
AC joint arthritis	No	16 53.3
	OA	14 46.7
Supraspinatus tear	Non	2 6.7
	Partial	25 83.3
	Total	3 10
Other pathology	Retracted muscles	8 26.7
	Calcific tendinitis	4 13.3
	Thickened tendon	4 13.3

**Table (4): US findings**

This table shows that joint effusion was detected in 7 cases ( 23.4%), and this was minimal in an amount in the majority of cases. AC osteoarthritis was seen in 14 cases ( 46.7%). Supraspinatus tear was seen by US in 28 cases (93.3% of cases) while only two cases showed no tear by the US. Supraspinatus tear was partial in 25 cases (83.3%) while total tear was detected in 3 cases (10%). Regarding the other pathologies, retracted muscles were found in 8 cases, while calcific tendinitis and thickened tendons were present in 4 cases. In summary, US findings were agreed by the MRI findings, with the exception of supraspinatus tear detection, which

was detected in 29 cases by MRI

		No	Percent
Joint effusion	Non	23	76.7
	Minimal	3	10.0
	Mild	2	6.7
	Moderate	2	6.7
AC joint arthritis	No	16	53.3
	Mild OA	8	26.7
	Moderate OA	6	20
Supraspinatus tear	Non	1	3.3
	Partial	20	66.7
	Near total	6	20
	Total	2	6.7
	Avulsion	1	3.3
Gap defect in mm (in complete tear cases)	Mean	15	
	Median	15	
	Std. Deviation	5.228	
	Range	6-22	
Other pathology	Retracted muscles	8	26.7
	Calcific tendinitis	4	13.3
	Thickened tendon	4	13.3

compared to 28 cases by US.

**Table (5): MRI findings**

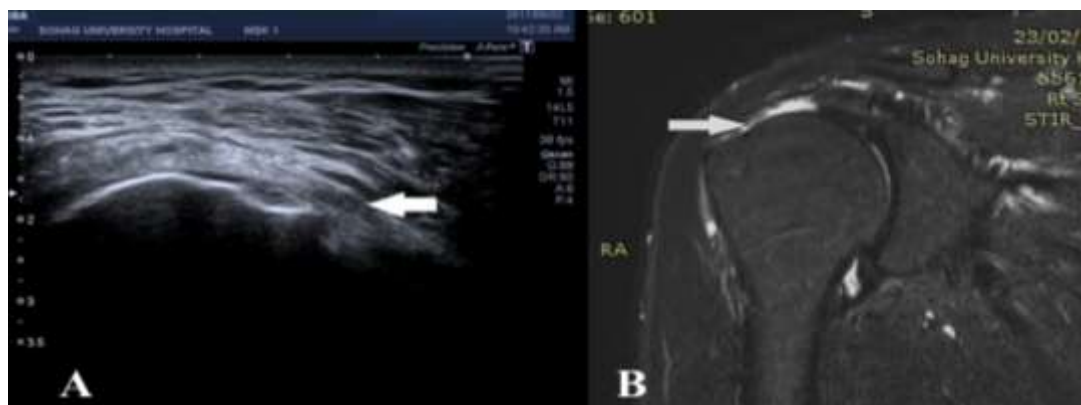This table shows that joint effusion was detected in 7 cases ( 23.4%), and this was minimal in an amount in the majority of cases. AC osteoarthritis was seen in 14 cases ( 46.7%), and was mild in 8 cases (26.7%) and moderate in another 6 cases (20%). Supraspinatus tear was seen by MRI in 29 cases (96.7% of cases) while only one with complete tear was 15 mm, with a range from 6-22 mm. Regarding the other pathologies, retracted muscles were found in 8 cases, while calcific tendinitis and thickened case showed no tear by MRI. Supraspinatus tear was partial or near-total in the majority of cases (66.7% and 20%; respectively) while total and avulsion tears were detected in 3 cases (2 for total tear and one for avulsion tear). The mean gap defect in cases tendons were present in 4 cases.

		MRI	
		Positive	Negative
US	Positive	28	0
	Negative	1	1

**Table(6): Sensitivity statistics of US to detect supraspinatus tear**

Sensitivity : 96.6%

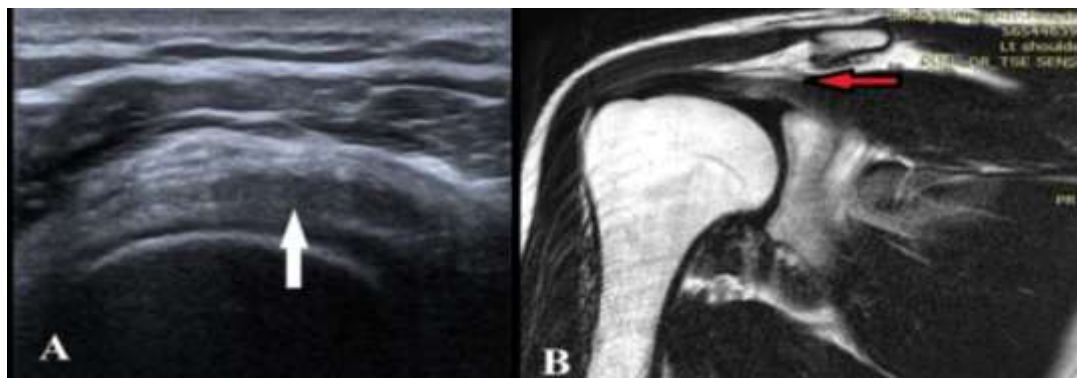
- Specificity :100%
- Positive predictive value : 100%
- Negative predictive value :50%
- Accuracy : 98.3%



**Figure (3 A&B):**

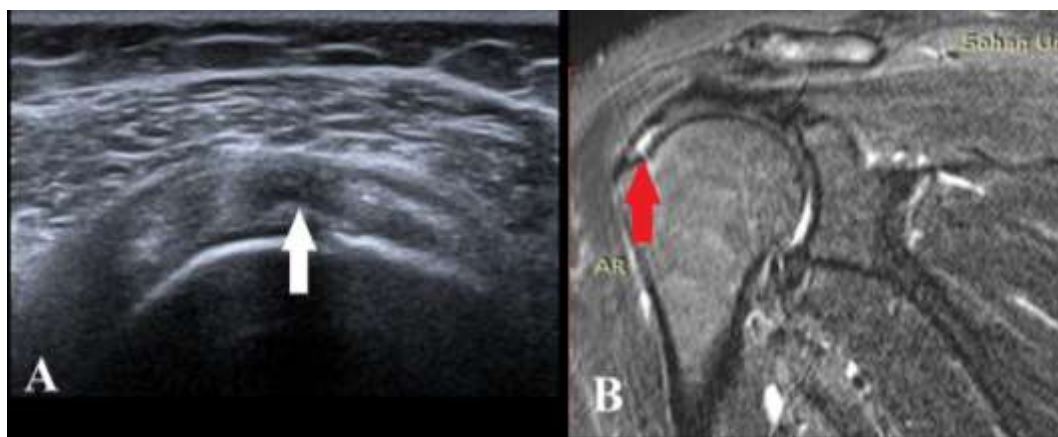
Male patient 42 ys old, manual worker (lifting heavy objects), complaining of right shoulder pain. Images showed full-thickness tear of supraspinatus tendon near its insertion with gap defect 22mm, no muscle atrophy or retraction. (A) US: shows hypoechoic area representing distortion of tendon fibers. (B) MRI: coronal STIR sequence shows abnormal hyperintense signal near tendon insertion.





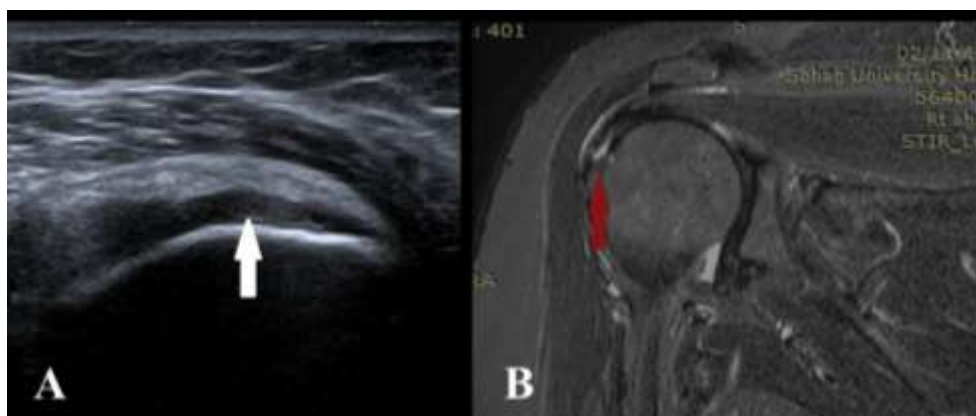**Figure (4 A&B):**

Male patient 26 ys old, a medical representative with shoulder pain 3 ys ago, no history of trauma. Images show partial-thickness intrasubstance tear at the myotendinous junction of the supraspinatus tendon. **(A) US:** shows abnormal linear hypoechoic discontinuity of tendon fibers. **(B) MRI:** coronal DUAL DR shows abnormal linear hyperintense signal at myotendinous junction.



**Figure (5 A&B):**

Female patient, 50ys, housewife (lifting heavy objects), complaining of right shoulder pain with no history of trauma. Images show partial thickness tear of supraspinatus tendon at humeral surface near its insertion. **(A) US:** abnormal linear hypoechoic discontinuity of tendon fibers at humeral surface with intact hyperechoic fibers at bursal surface. **(B) MRI:** coronal STIR sequence shows abnormal hyperintense signals near tendon insertion with joint effusion.



**Figure (6 A&B):**

female patient 60 yrs, housewife. History of shoulder pain 2 months ago with no history of trauma. Images show partial thickness tear of supraspinatus tendon at humeral surface near its insertion. **(A) US:** shows abnormal linear hypoechoic discontinuity of tendon fibers at humeral surface with intact hyperechoic fibers at bursal surface. **(B) MRI:** coronal STIR sequence shows abnormal hyperintense signal near tendon insertion on humeral surface with minimal joint effusion.

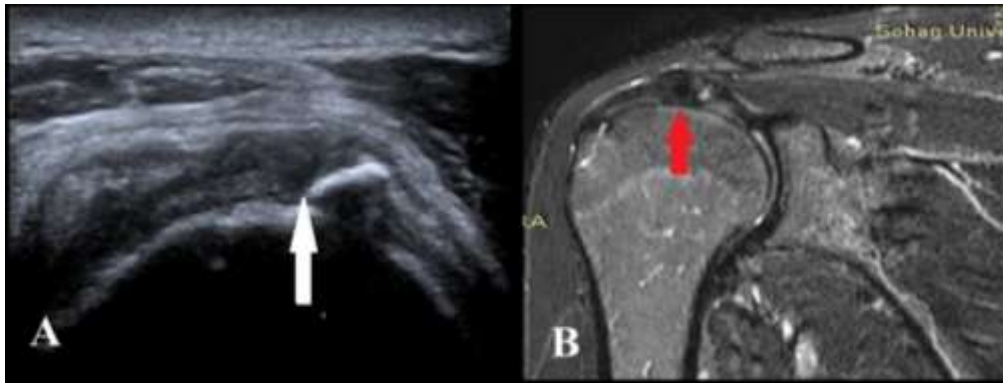


Figure (7 A&B):

Male patient, 30yrs, driver, complaining of shoulder pain with a history of shoulder dislocation. Images show partial thickness tear with calcific tendinitis. **(A) US:** shows thickened supraspinatus tendon with heterogeneous hypoechoic pattern and intratendinous calcification. **(B) MRI:** coronal STIR sequence shows thickened tendon, abnormal hyperintense signal, and intratendinous hypointense signal /signal void.

### Discussion

The aim of this study was to evaluate the accuracy of musculoskeletal ultrasound in the detection of rotator cuff injuries as compared to MRI as a gold standard technique. The mean age of the study group was around 42 years, with age ranged from 25 to 60 years. The age of our cases had two peaks, one at the age of 50 and a smaller one at around the age of 30. A new study done by Saraya *et al.* [3] included 40 patients with age somewhat older than our cases (with a mean age of 56 years and range from 34-65 years). Around two thirds of our cases were males. This was opposite to the study done by Saraya *et al.* [3] in which females predominated (27 females versus only 13 males).

Identified risk factors were detected in only one third of our study cases, with history of lifting heavy object was found in 20% of cases, while trauma

was recorded by only 4 cases (13.3%) of our cases and history of foreign body penetration was found in one case. The other 19 cases showed no definite history of probable cause of rotator cuff injury. The mean disease duration of our study population was 9 months, with a wide range from 2 months to 1.5 years.

The pain was the presenting symptom in 5 of our cases, while shoulder dislocation was present in one case. Joint effusion was detected in only 7 cases 23% of cases, and this was minimal in amount in 3 of cases. AC osteoarthritis was seen in 14 (46.7%) of the cases, and was mild in 8 cases (26.7%) and moderate in another 6 cases (20%). Supraspinatus tear was seen by MRI in 29 cases (96.7% of cases) while only one case showed no tear by MRI. Supraspinatus tear was partial or near-total in the majority of

cases (66.7% and 20%; respectively) while total and avulsion tears were detected in 3 cases (2 for total tear and one for avulsion tear). The mean gap defect in cases with complete tear was 15 mm, with a range from 6-22 mm. Regarding the other pathologies, retracted muscles were found in 8 cases, while calcific tendinitis and thickened tendons were present in 4 cases.

The results of **Hapani et al. [4]**, showed that; out of 27 patients, 10 patients were having full-thickness tear and 17 patients were having partial thickness tear. 14 patients were having isolated supraspinatus tendon tear, 2 patients were having isolated infraspinatus tear, 2 patients were having isolated subscapularis tendon tear and 1 patient was having isolated teres minor tear; rest of the 8 patients were having two or more tendon tears. According to **Prashanth et al. [5]**, out of their 31 cases, 13 patients had partial tear, 6 patients had a complete tear and 12 patients had tendinopathy and 3 patients had tendinopathy and partial tear of supraspinatus tendon in both ultrasound and MRI. 4 patients had combined tendinopathy and rotator cuff tear.

The study done by **Abd-ElGawad et al. [6]**, 5 cases (12.5%) showed a full-thickness tear, 13 cases (32.5%) showed partial thickness tear and 10 cases (25%) showed tendinitis.

Joint effusion was detected in only one-quarter of cases, and this was minimal in amount in the majority of cases. AC osteoarthritis was seen in around half of the cases. Supraspinatus tear was seen by US in 28 cases (93.3% of cases) while only two case showed no tear by US. Supraspinatus tear was partial in the majority of cases (83.3%) while total tear was detected in 3 cases (10%). Regarding the other pathologies, retracted muscles were

found in 8 cases, while calcific tendinitis and thickened tendons were present in 4 cases.

US findings were agreed by the MRI findings, with the exception of supraspinatus tear detection, which was detected in 29 cases by MRI compared to 28 cases by the US. Thus the sensitivity statistics of MSUS in our study compared to MRI were as follows: sensitivity (96.6%); specificity (100%); positive predictive value (100%); negative predictive value (50%) and accuracy (98.3%). According to **Hapani et al. [4]**, the sensitivity of MSUS in comparison to arthroscopy was 94.1% for partial thickness rotator tears and 90% for full-thickness tears, while the specificity was 100%. He stated that the sensitivity for MRI in comparison to arthroscopy was 88.2% for partial thickness tear and 100% for full-thickness tears, with specificity for 100%. However, he did not make head to head comparison between MSUS and MRI.

The sensitivity statistics of the US in comparison to arthroscopy according to **Abd-ElGawad et al. [6]** were: sensitivity 92.3%; specificity 92.6% and accuracy 92.5% for partial thickness rotator tear and 92.6%, 94% and 95% for full-thickness tears; respectively.

**Al Shawi et al. [7]**, studied 143 consecutive patients ultrasound and compared with sub-segment arthroscopy and showed that ultrasound had a sensitivity of 95.4%, Negative predictive value of 95.7% for full-thickness tear and 89.5% for partial thickness tear.

The new Egyptian study done by **Saraya et al. [3]**, showed that compared to MRI, ultrasound sensitivity for tendinitis detection was 85% with 86% NPV and 90%



accuracy, while for partial-thickness tears, its sensitivity, specificity, PPV, NPV, and accuracy were 88%, 89%, 94%, 80%, and 83% respectively. But in full-thickness tears, its sensitivity and specificity were 100% each.

Also, our results were better than **Iannotti *et al.* [8]**, who reported that office-based ultrasound to assess rotator cuff has 88% accuracy for full-thickness tear and 70% for partial thickness.

In fact, although MSUS provided high accuracy in the detection of rotator injuries compared to MRI; many clinicians prefer MRI as preoperative imaging than ultrasound because ultrasound provides less information regarding the morphology of torn ends of cuff muscles and the exact size and extent of tear [9]. **Okoroha *et al.* [10]**, retrospectively studied ultrasound and MRI of 144 patients who underwent arthroscopic repair of rotator cuff and showed that there is a greater difference between the two modalities in the measurement of tear size and retraction status and concluded that ultrasound is the imaging modality for detection of rotator cuff tear and MRI should be done for surgical planning of large tears. Also, **Sipola *et al.* [11]**, prospectively studied 77 patients with suspected rotator cuff tear with ultrasound and MRI and showed that ultrasound underestimated the tear size by ~15mm as compared to MR arthrogram and suggested that ultrasound should be used as a screening modality for detection of rotator cuff tear.

### Conclusion

Ultrasound has comparable accuracy with MRI for identifying rotator cuff injuries. Ultrasound can be used as a screening modality to detect rotator cuff integrity since it is easily available and cost-effective.

### Recommendations

We recommend a further study upon a big number of patients with surgical correlation.

### References

1. Vijayvargiya RA, Atram A, Daftary. Role of MRI in Rotator Cuff Injury & Comparing its Diagnostic Accuracy With USG, National Journal of Medical and Dental Research, 2014; 3(1): 38-43.
2. Aggrawal J, Bansal RP, Vinod S, Gothecha L, Kollu R. USG and MRI correlation of rotator cuff tears. International Medical Journal. 2014; 1(10):603.
3. Saraya S, El Bakry R. Ultrasound: Can it replace MRI in the evaluation of the rotator cuff tear. The Egyptian Journal of Radiology and Nuclear Medicine. 2016; 47(1): 193-201.
4. Hapani H, Sood M, Trivedi A, Chawla A, Virda I, Radadiya K. Ultrasound, MRI and Arthroscopic Correlation of Rotator Cuff Tears. International Journal of Contemporary Medical Research, 2017; 4(3): 77-83.
5. Prashanth S, Prasad S, Nisha P, Suresha B, Nataraj A R. Comparative study of ultrasound and MRI in assessing rotator cuff tear. International Journal of Contemporary Medicine Surgery and Radiology. 2017; 2(3):70-7.
6. Abd-ElGawad E, Ibraheem MA, Fouly EH. Evaluation of supraspinatus muscle tears by ultrasonography and magnetic resonance imaging in comparison with surgical findings. The Egyptian Journal of Radiology and Nuclear Medicine. 2013; 824-834.
7. Al-Shawi A, Badge R, Bunker T. The detection of full-thickness rotator cuff tears using ultrasound. British Editorial Society of Bone and Joint Surgery. 2008; 90(7): 889.
8. Iannotti JP, Ciccone J, Buss DD, Visotsky JL, Mascha E, Cotman K, Rawool NM. Accuracy of office-based ultrasonography of the shoulder for the diagnosis of rotator cuff tears. J Bone Joint Surg Am., 2005; 87(6):1305-11.

9. Rutten MJ, Maresch BJ, Jager GJ, Blickman JG, van Holsbeeck MT. Ultrasound of the rotator cuff with MRI and anatomic correlation. *Eur J Radiol.*, 2007; 62(3): 427-436.
10. Okoroha KR, Mehran N, Duncan J, Washington T, Spiering T, Bey MJ, Van Holsbeeck M, Moutzouros V. Characterization of Rotator Cuff Tears: Ultrasound Versus Magnetic Resonance Imaging. *Orthopedics.* 2017; 40(1):124-130.
11. Sipola P, Niemitukia L, Kröger H, Höfling I, Väättäinen U. Detection and quantification of rotator cuff tears with ultrasonography and magnetic resonance imaging - a prospective study in 77 consecutive patients with a surgical reference. *Ultrasound Med Biol.*, 2010; 36(12):1981-9.
12. S. P. Ivanoski; Ohrid/MK, Ultrasound assessment of most frequent shoulder disorders, European society of radiology, ECR 2014 page 22-3