

# EFFECT OF PREGNANCY ON THE STRUCTURE OF THE ANTERIOR ABDOMINAL WALL IN MAN

N. N. RIZK AND H. I. EL-EISHI.

*Departments of Anatomy, Faculty of Medicine,  
Cairo and Mansoura Universities*

## INTRODUCTION

A new description of the anatomy of the anterior abdominal wall, which is believed to have an important bearing effect on its function, has been given by Rizk (1976). The present work reports the structural changes observed as a result of repeated pregnancy in the muscles and aponeuroses of the anterior abdominal wall of Egyptian females.

## MATERIALS AND METHODS

The material included 28 specimens of female anterior abdominal wall, 16 of which are nulliparous and 12 multiparous. The age of the nulliparous specimens varied between 12 and 28 years of age, while that of multiparous specimens varied between 20 and 37 years of age. The number of pregnancies in the multiparous specimens varied between two and six.

The specimens were obtained from the postmortem shortly (within six hours) after death. They were

fixed in 5% formalin solution for a period of 24 hours only to avoid shrinkage or distorsion of the fibres. Prior to fixation, the specimens were stretched on wooden frames (40 X 60 cm.) by strong silk threads. This was also helpful to prevent shrinkage of the tissues. The individual aponeurotic bundles were followed in each aponeurotic plane by using hand lenses and the dissecting microscope. Drawings were accurately made by the identical square technique. The specimens, while stretched, were applied to another identical frame divided by thin silk threads into equal squares (3X3 cm.), and the drawing paper (transparent) was applied to another paper divided into similar squares. Each square of the specimen was drawn in its corresponding square on the paper.

## RESULTS

### OBSERVATIONS

The structural changes observed on the human anterior abdominal

wall as a result of repeated pregnancy were thinning and expansion of the muscles, thinning and expansion of the aponeuroses. appearance of characteristic aponeurotic bundles in the infra-umbilical region of the rectus sheath and dimensional changes in the linea alba.

The fleshy bundles of the abdominal muscles were found to become relatively thinner and more expanded. The general average thickness of the fleshy belly of the external oblique was found to be 4 mm. in multiparous specimens, while in nulliparous specimens it was 6 mm.

The widest breadth of the rectus abdominis muscle was found to be greater in multiparous specimens than in nulliparous ones. On the average, it was 7.8 mm. with a range of variation between 7.5 and 8.0 cm. in multiparous specimens; while it was 7.2 cm. on the average with a range of variation between 4.5 and 7.5 cm. in nulliparous specimens.

The aponeuroses of the abdominal muscles were generally thinner than usual. Their fibres were found to group together in well identified bundles separated from each other by spaces filled with thin fascial membranes. The thickness of these aponeurotic bundles and the distance between them increased with increase in the number of pregnancies. In specimens with a large number of pregnancies, these bundles

were so thick (2-3 mm) specially in the infra-umbilical region to give the abdominal wall a network appearance (Fig. 1). As a result of stretch the aponeurotic bundles of the posterior rectus sheath became nearly horizontal instead of oblique (Fig. 2). In other specimens, with a fewer number of previous pregnancies, the aponeurotic bundles were thinner and nearer to each other (Fig. 3).

The linea alba was affected both in length and breadth. The length of the fully stretched linea alba of the multiparous specimens, measured from the xiphoid process to the upper border of the symphysis pubis varied between 30 - 38cm. with an average of 33.5 cm. However, in nulliparous adult specimens, the length of the linea alba was found to be between 24 - 34cm. with an average of 26.7 cm.

The breadth of the linea alba was found to be similarly increased particularly in the upper half of the abdomen. The breadth of the fully stretched and fixed linea alba was measured at four different levels : 1— at the xiphoid process, 2— at a level midway between the xiphoid process and the umbilicus, 3— at the umbilicus, and 4— at a level midway between the umbilicus and symphysis pubis. The following table illustrates the differences in the breadth of the linea alba in multiparous and adult nulliparous specimens.

Level	Nulliparous adult specimens		Multiparous specimens	
	Variations	Average	Variations	Average
1	4 — 17 mm.	9.3	6 — 18 mm.	11.5
2	12 — 35 mm.	19.5	27 — 52 mm	35.0
3	17 — 42 mm	24.5	42. — 65 mm.	53.5
4	2 — 14 mm.	6.8	12 — 25 mm.	16.0

The position of the umbilicus was observed to be nearer to the symphysis pubis in the multiparous specimens than in the nulliparous ones. The average ratio between the infra-umbilical and the supra-umbilical portions of the linea alba was found to be in nulliparous adult specimens 1 : 1.08 while in the multiparous specimens it was 1 : 1.63.

### DISCUSSION

The anatomical picture of the anterior abdominal wall has not been changed since long time. References concerning the subject are relatively deficient ( Chouke, 1935 ; Walmsley, 1937; Anson and (Mc vay 1938 and Mc Vay and Anson,(1940) A new anatomical description of the anterior abdominal wall has been recently given (Rizk, 1974, 1976 & 1978). Repeated pregnancy was found to affect much the anterior abdominal wall however, it confirms also the new description given (Rizk, 1976). Most of the changes due to repeated pregnancy could be

attributed to the stretching effect of pregnancy.

The average thickness of the fleshy belly of the external oblique was diminished by one third of the average usual thickness. The average breadth of the rectus muscle in its widest part was also increased by about one third of the average usual breadth. Thinned muscles are probably weaker than muscles with normal thickness.

The aponeuroses of the abdominal wall showed that their fibres were grouped in bundles which appeared discrete. This is most probably, due to the dispersion of the aponeurotic fibres in a wider area without actual increase in their number. The aponeurotic bundles were thick in the infraumbilical region. They were thicker in specimens with a higher number of repeated pregnancies than in those with a smaller number. The development of these bundles could be a response to the repeated strain

of the gravid uterus. This also explains their appearance in the infra-umbilical part which is involved more in the support of the weight of the dependant uterus.

The linea alba was seen to be much affected by the stretching influence of pregnancy. Its dimensions were increased both in length and breadth. The average length was increased by about one fourth of the average usual length. The breadth of the linea alba was also increased; the maximum increase (more than double the normal breadth) was noticed at the level of the umbilicus, and midway between the umbilicus and symphysis pubis. The increased dimensions of the linea alba inevitably diminish its thickness and density. The fibres thus become separated, and small rhomboid slits appear between them. Widening of these slits creates the hernial orifices.

The position of the umbilicus in the linea alba was observed to shift towards the symphysis pubis as a result of repeated pregnancy. The ratio between the supraumbilical and infra-umbilical regions of the linea alba increased to about one and a half of the average usual value. This probably means that the supra-umbilical part of the abdomen is more expanded by pregnancy than its infraumbilical part. This can be explained by the fact that by the time the fundus of the uterus becomes massive enough to induce

effective expansion of the abdomen it is usually present in its upper part.

It is thus concluded that the lower abdomen is more susceptible to the strain of the weight of the gravid uterus, while the upper abdomen is more expanded by the massive fundus. When this conclusion is compared to the fact that herniation of the linea alba in females is usually met with in the supra-umbilical rather than in the infra-umbilical regions, it can be seen how pregnancy increases the liability for the occurrence of herniation of the linea alba

### SUMMARY

The anterior abdominal wall of 28 women of various ages and parity were studied. The fleshy bellies of the abdominal muscles decrease in thickness and increase in breadth. The aponeurotic fibres become discrete and more horizontal, they form thick characteristic bundles in the infra-umbilical region to support the weight of the uterus. The linea alba exhibits characteristic dimensional changes. Its herniation, regarding the mechanism of formation is discussed.

### REFERENCES

1. Anson, B. J. and Mc Vay, C. B. : The anatomy of the inguinal and hypogastric regions of the abdominal wall. *Anat. Rec.*, **70** : 211 - 225 (1938).
2. Chouke, K. S. : Constitution of the sheath of the rectus muscle. *Anat. Rec.*, **61** : 341 (1935).
3. Mc Vay, C.B. and Anson, B.J. : Aponeurotic and fascial continuities in the abdomen pelvis and thigh. *Anat. Rec.* **76** : 213-231 (1940).

4. **Rizk, N.N. :** A study on the anterior abdominal wall. M.D. thesis, Faculty of Medicine, Cairo University (1974).
5. **Rizk, N.N. :** A new description of the anterior abdominal wall. *Anat. Rec.*, **184** : 515 (1976).
6. **Rizk, N.N. :** A new description of the rectus sheath in man and mammals. *J. Anat.*, (in press) (1978).
7. **Walmsley, R. :** The sheath of the rectus abdominis. *J. Anat.*, **71** : 404 - 414 (1937).

### EXPLANATION OF FIGURES

Fig. (1) An illustration of the anterior surface of the anterior abdominal wall of a woman aged 35 years and had 6 previous pregnancies. F.I. : fibres directed downwards and medially, F. 2. : fibres directed downwards and laterally, U. : Umbilicus, L. A.: linea alba. The thickened aponeurotic bundles forming a network appearance in the infra-umbilical region are seen.

Fig. (2) : An illustration of the posterior rectus sheath of the specimen in fig. 1 Tr. : transversus abdominis.

int.: internal oblique, X.: xiphoid process, G.: inferior epigastric artery. The direction of the aponeurotic fibres is nearly horizontal.

Fig. (3) : An illustration of the anterior abdominal wall of a woman aged 25 years and had only two previous pregnancies. F.I. : downwards and medially, F. 2.: downwards and laterally The aponeurotic fibres in the infra-umbilical region are thinner and closer to each other.

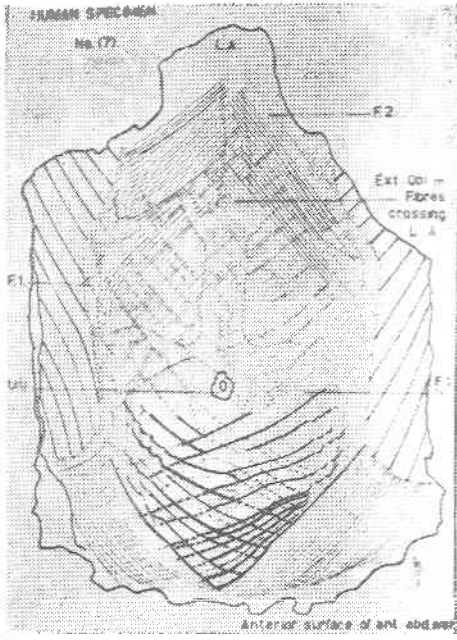


Fig. (1)

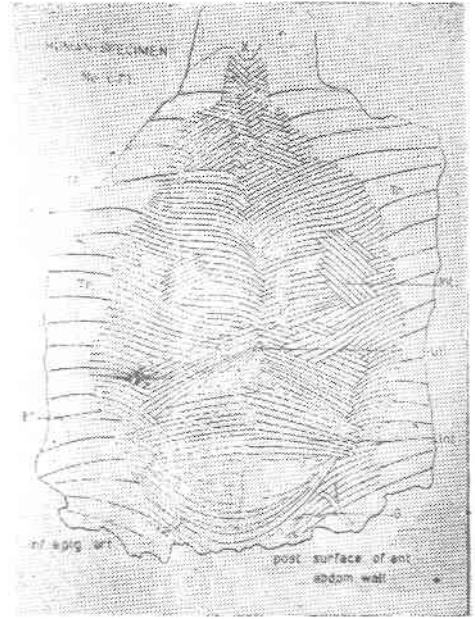


Fig. (2)

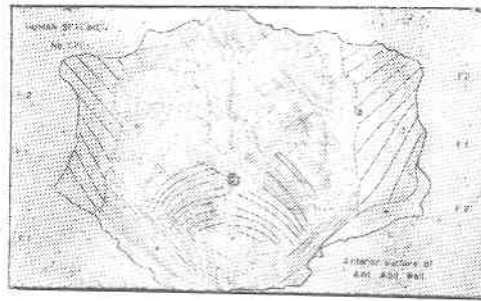


Fig. (3)