

Partial Resection Versus Complete Resection of Costal Cartilage in Breast Reconstruction by DIEP Flap

Mohamed M. El-Ghor*, Abdelhady Omar, Tarek M. El-Banouby, Ahmed Taha, Abdelfatah El-Shekh
Department of Plastic and Reconstructive Surgery, Faculty of Medicine, Al-Azhar University

*Corresponding author: Mohamed M. El-Ghor; Mobile: (+20) 01145999220

ABSTRACT

Background: Breast reconstruction is a vital component of the overall treatment plan of breast cancer patients. Surgical breast reconstruction is not only desired by most patients, but is recommended by law in many countries.

Aim of the Work is to compare between partial resection and complete resection of costal cartilage in breast reconstruction by DIEP flap as regard postoperative pain mainly and other factors as operative time, blood loss, blood transfusion, and hospital stay.

Patient and Methods: Forty patients were recruited in this study and were divided into 2 groups, 20 patients underwent breast reconstruction by DIEP flap with partial resection of costal cartilage and 20 patients underwent breast reconstruction by DIEP flap with complete resection of costal cartilage.

Results: DIEP flap with partial resection of costal cartilage does in fact cause less postoperative pain than DIEP flap with complete resection of costal cartilage.

Conclusion: The DIEP flap is an excellent choice for breast reconstruction, and is usually the first choice of flap for breast reconstruction in our practice. Over the past 3 years in our practice it has shown to be safe and reliable and provide a breast reconstruction with a superior long-term result with minimal donor site morbidity.

Keywords: Costal Cartilage, Breast Reconstruction, DIEP Flap, Blood loss, Blood transfusion.

INTRODUCTION

Breast cancer is one of the most common cancer affecting females all over the world. It is considered one of the major health problems as it represents 37% of total female cancers and 17% of total cancer cases. It is the most common cause of death due to cancer among women all over the world ⁽¹⁾. The use of autologous tissue allows the reconstruction of a breast which looks and feels most like a normal breast. The advent of perforator flaps now allows for minimal donor site morbidity and good flap durability. The abdomen is an ideal source of tissue for breast reconstruction. Most patients who develop breast cancer are at an age when they also have excess skin and fat overlying the abdomen. The fat is typically soft and easy for the surgeon to shape and closely approximates the feel of a normal breast ⁽²⁾.

Pain management is a primary factor in the postoperative care of plastic surgical patients. They are largely treated in ambulatory surgery centers, and failure to control pain in that setting has negative effects. It increases the time in the surgery center, delays recovery, and can lead to unanticipated readmissions to the facility or to a hospital. Hospital inpatients also require careful pain management ⁽³⁾.

Pain control is key peri-operatively and must be taken into account by the physician from the initial consultation and discussed in detail with the patient ⁽³⁾.

In the majority of cases; the dissection of internal thoracic artery necessitates at least one costal cartilage resection which is the main factor of pain. So, in this study we will compare between

partial and complete resection of costal cartilage and their effect on postoperative pain ⁽⁴⁾.

AIM OF THE WORK

Is to compare between partial resection and complete resection of costal cartilage in breast reconstruction by DIEP flap as regard postoperative pain mainly and other factors as operative time, blood loss, blood transfusion, and hospital stay.

PATIENT AND METHODS

Prospective non randomized comparative study of 40 breasts, which underwent breast cancer surgery and reconstructed using DIEP flap. partial resection of costal cartilage was performed in 20 patients while complete resection of costal cartilage was performed in 20 patients during dissection of internal mammary artery

Inclusion criteria: Patient with early breast cancer stage I and II (when conservative breast surgery is not applicable), patient well for breast reconstruction.

Exclusion criteria: Patients with locally advanced breast cancer stage III, stage IV. Patient with medical disease contraindicating long anesthetic procedure as heart failure, patients who prefer other modalities of breast reconstruction, when DIEP flap is contraindicated e.g. previous abdominal surgery as abdominoplasty.

Ethical approval and written informed consent :

An approval of the study was obtained from Al-Azhar University Academic and Ethical

Committee. Every patient signed an informed written consent for acceptance of the operation.

CT angiography (CTA) of the abdominal wall was done, up to three deep inferior epigastric perforator (DIEP) vessels were marked. It's useful for determination of the calibre, determination of the number and site of the skin perforators, determination of the direction and length of the intramuscular, sub-fascial, and subcutaneous segments of the skin perforators, and detection of any anatomical vascular variations.

Evaluation of the patient was based on pain score:

The 6 point Behavioral Rating Scale (BRS-6); BRS-6 an adaptation from a scale developed by Budzynski et al. to measure the intensity of pain. It is referred to as the Behavioral Rating Scale because patients are asked to rate the intensity of their pain in terms of its behavioral effects. Each set of descriptive words on the BRS is given a score from 1 (for the description indicating no pain) to 6 (for the description indicating incapacitating pain), and the patient's intensity score equals the score associated with the chosen description.

The 6-points Behavioral Rating Scale (BRS-06):

(1) No pain, (2) Pain present; but can easily be ignored, (3) Pain present. Cannot be ignored; but does not interfere with everyday activities, (4) Pain present. Cannot be ignored. It interferes with concentration, (5) Pain present. Cannot be ignored. Interferes with all tasks except taking care of basic needs such as toileting and eating, (6) Pain present. Cannot be ignored. Rest or bed rest required.

Also measurement of postoperative morphia to determine intensity of pain was detected. All patients were fixed on the same protocol of postoperative pain control regarding analgesic drug through patient controlled analgesia (PCA).

Other operative factors were assessed such as blood transfusion, length of the operation (time acquired), hospital stay after operation, and postoperative complications

All flaps were harvested with the patient in supine position and the upper extremities were adducted and immobilized next to the trunk. First, the positions of the major perforators were marked on the skin according to the findings of the preoperative CTA study.

Operative technique:

The flap was harvested from the lower abdomen which allowed simultaneous two-team work. One team was responsible for resection/recipient site preparation while the other team was responsible for flap elevation.

Preparation of the Recipient Area:

This step should be done simultaneously (in a two-team approach.). In delayed reconstruction, the level of the infra-mammary fold was marked more superiorly than the final desired position. The pectoralis muscle was split. The chosen intercostal space with its cranial and caudal ribs was exposed from the sternocostal junction to the costochondral junction (**Fig. 1**).

The preferred level for rib cartilage excision was the third rib, as the vessels here are consistently large. More distally, the vein narrows and bifurcates, generally becoming unsuitable below the fourth space. The third rib was palpated and the overlying pectoralis muscle was split along its fibers entering the subpectoral plane, exposing the third rib from the sternocostal junction to the costochondral junction and the second and third intercostal spaces (**Fig. 2**). Internal mammary perforators coursed through the intercostal and pectoralis muscles and served as a guide to the location of the internal mammary vessels. These were ligated with clips.

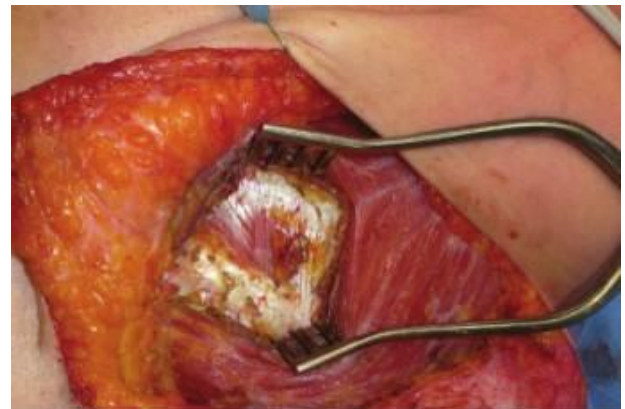

Figure (1): The exposure of intercostal space was maintained with self-retaining retractors and hooks.

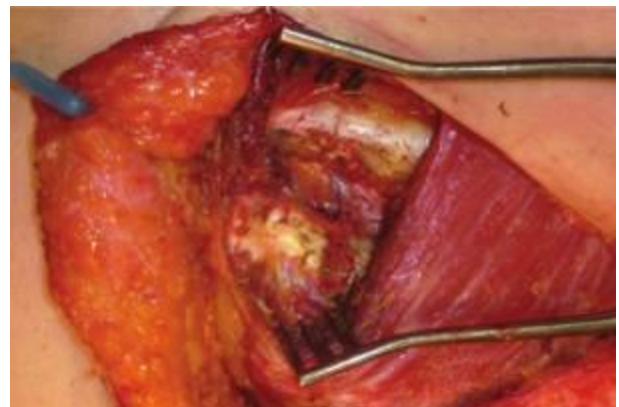


Figure (2): The intercostal space was unroofed, exposing the parietal pleural and fatty connective tissue containing.

Group (1): Complete Resection of Costal Cartilage to Expose Internal Mammary Vessels

The anterior perichondrium of the third rib cartilage was incised. Subperichondrial dissection of the third rib cartilage was performed all around with a periosteal elevator. A narrow rongeur was then used to progressively excise the segment of rib. Every effort was made to leave the posterior perichondrium intact throughout this part of the procedure so that final exposure of the vessels was controlled and deliberate (**Fig. 3**). The subperichondrial space was approached by incising the perichondrium with a blunt tip scissors, away from the internal mammary vessels, taking care not to damage the underlying pleura. The perichondrium and attached intercostal muscles were elevated medially toward the sternum. This exposed the internal mammary vessels, which are enclosed within a fatty conn was usually located lateral to the vein, and where the vein has bifurcated; the artery lies in the middle. Intervening fat or lymph nodes were excised.

Side branches were ligated with clips so that the internal mammary vessels were completely freed along the exposed length. Great care was taken when dissecting the vein, which is thin walled (**Fig. 4**). When the length and caliber were enough, the distal ends were clipped. Microvascular clamps were applied proximally, and the vessels were cleanly transected with a pair of microscissor (**Fig. 5**).

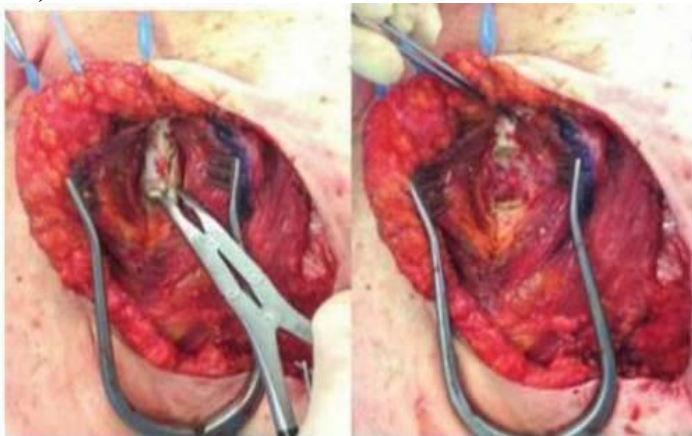


Figure (3): The segment of rib cartilage was resected with a rongeur, keeping the posterior perichondrium intact.

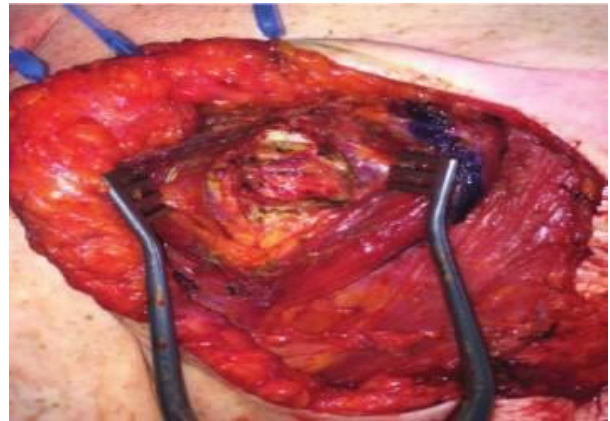


Figure (4): The thin fascia over the fat pad was incised and the vessels can then be dissected. Here two veins are seen with the artery in between.

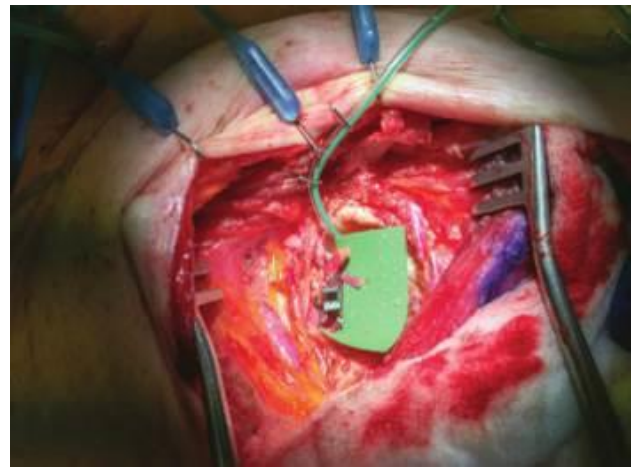


Figure (5): The internal mammary vessels were ready for anastomosis.

Group (2): Partial Resection of Costal Cartilage

Partial resection of costal cartilage was done in a horizontal manner that allowing adequate and a comfortable area for microvascular anastomosis (**Fig. 6**) as arrows points to vertically transected 2nd and 3rd costal cartilages. The anterior perichondrium was incised and elevated subperichondrially with a Josephs elevator. A narrow rongeur was then used to carefully excise the rib edge, creating a gentle trough.

The posterior perichondrium can now be elevated in a craniocaudal direction thus exposing the internal mammary vessels. Vessel dissection proceeds in the same manner described previously, but might be more challenging as the space available was limited between the adjacent partially resected ribs (**Fig. 7**). Pedicle length was maximized by extending the vessel dissection deep to the cranial portion of the caudal rib, so that the vessel might be ligated as far distally as possible under the rib.

Microvascular Anastomosis:

In settings where two teams were available, the patient’s legs could be raised to facilitate donor site closure during the microvascular anastomosis expediting the procedure. The flap was turned 180 degrees and fixed to the chest with a moist laparotomy pad and staples. For technical reasons, the medial vessel was anastomosed before the lateral vessel. End to end anastomoses was done (Fig. 8).

DIEP Flap Inset:

With an assistant supporting the flap to ensure that there was no traction of the pedicle, the towel that was used to wrap the artery perforator was carefully removed. The flap was inset in the same position as the anastomosis that was, upside down with the umbilicus facing 6 o’clock. The mastectomy flap was retracted to visually confirm that there was no twisting, kinking, or extrinsic compression of the pedicle.

Postoperative care:

Postoperatively, the patient was observed in the Surgical Intensive Care Unit overnight and transferred to the ward in the morning of the first postoperative day. Usually oral analgesics were given 1st postoperative day onwards. The patient ambulated on 1st postoperative day and was discharged home on 4th to 6th postoperative day. A second stage revision and nipple creation were performed under local anesthesia with intravenous sedation in the operating room between 8 and 12 weeks after the initial surgery to further refine and finish the appearance of the breast.

space available is limited between the partially resected 2nd and 3rd ribs.

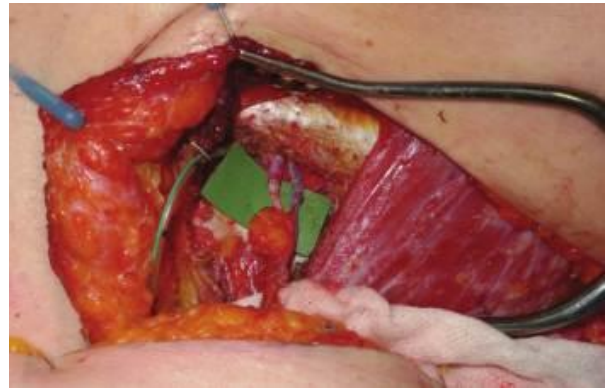


Figure (8): Microsurgical anastomosis was done.

Statistical analysis

Recorded data were analyzed using the statistical package for social sciences, version 20.0 (SPSS Inc., Chicago, Illinois, USA). Quantitative data were expressed as mean± standard deviation (SD). Qualitative data were expressed as frequency and percentage.

The following tests were done:

- Independent-samples t-test of significance was used when comparing between two means.
- Chi-square (χ^2) test of significance was used in order to compare proportions between two qualitative parameters.
- The confidence interval was set to 95% and the margin of error accepted was set to 5%. The p-value was considered significant as the following:
 - P-value <0.05 was considered significant.
 - P-value <0.001 was considered as highly significant.
 - P-value >0.05 was considered insignificant.

RESULTS

Patient Characteristics are listed in table one.

Table (1): Comparison between age within the two study groups.

		Complete resection group N= 20	Partial resection group N= 20	Test of significance
Age	Mean ± SD	35.36 ± 3.17	33.97 ± 2.06	P >0.05
	Median (range)	36 (30- 45)	34 (29- 44)	

As regard post-operative pain; comparison of the pain scores classes between the two study groups is listed in table 2.

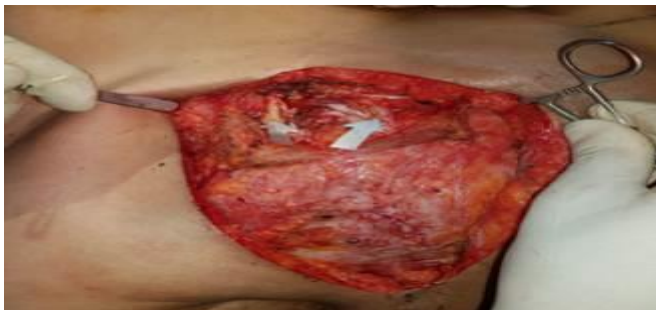

Figure (6): Arrows points to partially resected 2nd and 3rd costal cartilages horizontally with adequate space for microvascular anastomosis.

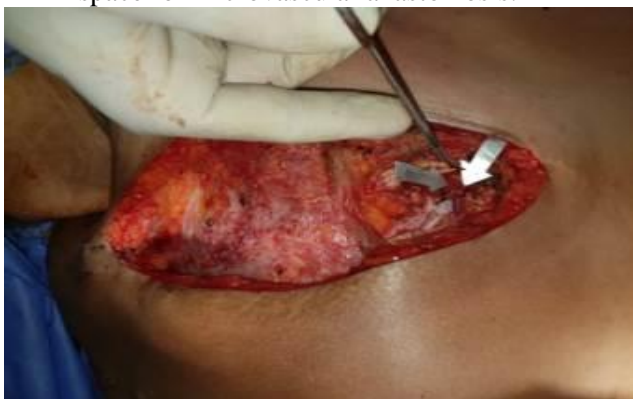

Figure (7): Arrows points to internal mammary vessels which were dissected carefully as the

All patients who undergo breast reconstruction in our hospital are treated with narcotics, using a patient-controlled pump. Morphine is usually the narcotic of choice, but some patients do not tolerate morphine well and are therefore given alternative drugs. Patients who had received intravenous drugs other than morphine (such as pethidine) were excluded from this study, even if they had also received morphine.

Table (2): Comparison of the pain scores classes between the two study groups.

	Complete resection group N= 20	Partial resection group N= 20	Test of significance
Pain score groups			
Score 1	0 (0%)	1 (5%)	P < 0.001*
Score 2	0 (0%)	11(55%)	
Score 3	8 (40%)	4 (20%)	
Score 4	11(55%)	3 (15%)	
Score 5	1 (5%)	1(5%)	
Score 6	0 (0%)	0 (0%)	

*= significant difference

Patient with partial resection of costal cartilage developed less received less amount of narcotic analgesic (Table 3).

Table (3): Comparison between morphine dose within the two study groups.

	Complete resection group N= 20	Partial resection group N= 20	Test of significance
Morphine dose	Mean ± SD	1.65 ± 1.03	P = 0.005*
	Median (range)	1.4 (0.6- 2.5)	
		0.74 ± 0.2	
		0.67 (0.3- 1.2)	

*= significant difference

Hospital stay: for those patients underwent complete resection of costal cartilage average was (5.10 days) but the difference was not statistically significant. While those patients underwent partial resection of costal cartilage average hospital average (4.73 days)

Table (4): Comparison between hospital stay within the two study groups

	Complete resection group N= 20	Partial resection group N= 20	Test of significance
Hospital stay	Mean ± SD	34 ± 1.84	< 0.001*
	Median (range)	5.5 (3.4- 8.7)	
		26 ± 1.04	
		3.9 (1.9- 6.3)	

*= significant difference

Operative time

In this study: the average time needed for breast reconstruction with DIEP flap either with complete resection was (6-8) Hours, while for partial resection group operative time was (7-9) hours.

Table (5): Comparison between operative time within the two study groups

	Complete resection group N= 20	Partial resection group N= 20	Test of significance
Operative loss	Mean ± SD	6.24 ± 0.86	P<0.001*
	Median (range)	6 (6- 8)	
		7.85 ± 0.95	
		8 (7- 9)	

*= significant difference

Complications are listed in table 6.

Table (6): Comparison of the complications between the two study groups

	Complete resection group N= 20	Partial resection group N= 20	Test of significance
Pain score groups			
Partial flap loss	4 (20%)	5 (25%)	P >0.05
Complete flap loss	2 (10%)	3 (15%)	
Fat necrosis	9 (45%)	8 (40%)	
Seroma at donor site	5 (25%)	7 (35%)	

As regard to the amount of blood loss, the average amount of blood loss both group procedures was with a range of 1000 to 1200 cc.

Table (7): Comparison between blood loss within the two study groups

	Complete resection group N= 20	Partial resection group N= 20	Test of significance
Blood loss	Mean ± SD	965.36 ± 86.86	P >0.05
	Median (range)	850 (800- 1200)	
		976.27 ± 79.47	
		900 (700- 1200)	

DISCUSSION

The most common autogenous procedures used in frequency are latissimus dorsi flap, pedicled TRAM, free TRAM and DIEP flap. The internal

mammary vessels are one of the most frequently used recipient sites for free-flap breast reconstruction; an advantage is their central position on the chest which allows the use of a short pedicle and the location also allows the flap to be positioned medially on the chest to create medial breast fullness ⁽⁵⁾.

Three options are available: dissection of the internal mammary vessels with rib excision (traditional), dissection of the internal mammary vessels with rib preservation, and dissection of the internal mammary perforators. The preferred level for rib cartilage excision is the third rib, as the vessels here are consistently large. More distally; the vein narrows and bifurcates, generally becoming unsuitable below the fourth space. It was found that removal of rib cartilage does not result in noticeable contour deformities, as the flap and pectoralis muscle provide adequate cover. As the rib cartilage is removed with the cranial and caudal intercostal muscles, this technique provides excellent exposure and vessel length of 3 to 4 cm ⁽⁶⁾.

A standard approach to the internal mammary vessels involves the removal of a 3-cm segment of costal cartilage, of the third or fourth rib, but this can be associated with a visible medial chest-wall depression in up to 15% of patients ⁽⁷⁾.

Methods used to reduce this problem include placing the transferred free-flap over the area of cartilage resection, using careful closure of a local pectoralis major flap, positioning the costal cartilage resection lower on the chest and reducing the length of the costal cartilage excised ⁽⁸⁾.

Darcy et al. ⁽⁸⁾ had a study for internal mammary vessel exposure, based on 8 years of experience, involves a modification wherein a narrow intercostal space, the posterior aspect of the costal cartilage, is carved out without compromising the anterior surface of the costal cartilage.

As described by **Shokrollahi et al.** ⁽⁶⁾, the intercostal spaces are first assessed by palpation through the pectoralis muscle. The ideal intercostal space has the following attributes: Sufficiently wide (1.5 to 2 cm), adjacent ribs run parallel without a tendency to converge acutely at the sternum, and easily accessible through the available mastectomy approach. This usually corresponds to the third intercostal space.

Granzow et al. ⁽²⁾ found that the intercostal space approach, with the removal of a portion of a rib, gives access to a 2-3 cm length of internal mammary vessels that is sufficient to perform microsurgical anastomoses.

Kim et al. ⁽⁹⁾, had found that rib-sparing technique is to avoid chest wall morbidity associated

with removal of costal cartilage, and end to end anastomosis can preserve internal mammary artery for future cardiac surgery.

CONCLUSION

The DIEP flap is an excellent choice for breast reconstruction, and is usually the first choice of flap for breast reconstruction in our practice. Over the past 3 years in our practice it has shown to be safe and reliable and provide a breast reconstruction with a superior long-term result with minimal donor site morbidity.

In conclusion, our data suggest that the DIEP flap with partial resection of costal cartilage does in fact cause less postoperative pain than DIEP flap with complete resection of costal cartilage. As such, it has real advantages and deserves serious consideration by surgeons who perform postmastectomy breast reconstruction with autologous tissues.

1. REFERENCES

- Rouesse J, Khaled H, Omar S (2010):** Epidemiology of breast cancer. *East Mediterr Health J.*, 9(3):448-63.
- Granzow JW, Levine JL, Chui ES (2006):** Breast reconstruction with the deep inferior epigastric perforator flap: history and an update on current technique. *J Plast Reconstr Aesthet Surg.*, 59:571-9.
- Jensen MP, Karoly P, Braver S (1986):** The measurement of clinical pain intensity: A comparison of six methods. https://www.researchgate.net/publication/222390778_The_measurement
- Haywooda RM, Raurella A, Perksa AGB et al. (2003):** Autologous free tissue breast reconstruction using the internal mammary artery as recipient vessels. *The British Association of Plastic Surgeons*, 56: 689–691.
- Drazan L, Vesely J, Hyza P (2008):** Bilateral breast reconstruction with DIEP flaps: 4 years experience. *J Plast Reconstr Aesthet Surg.*, 61:1309-15.
- Shokrollahi K, Whitaker IS, Nahai F (2017):** Flaps practical reconstructive surgery. *The Internal Mammary System as Recipient Vessels for Breast Microsurgical Reconstruction.* *Plast Reconstr Surg.*, 123(5):1403-7.
- Schwabegger AH, Grischmizter C, Ninkovic MM (1999):** Contour deformity at the internal mammary recipient site. *Br J Plast Surg.*, 52:674-9.
- Darcy CM, Smit JM, Audolfsson T, and Acosta R (2009):** Surgical technique: The intercostal space approach to the internal mammary vessels in 463 microvascular breast reconstructions. *JPRAS., J Plast Reconstr Aesthet Surg.* ,64(1):58-62.
- Kim H, Lim SY, Pyon JK et al. (2013):** Rib-Sparing and Internal Mammary Artery-Preserving Microsurgical Breast Reconstruction with the Free DIEP Flap. *Plast Reconstr Surg.*, 131(3):327-34.