

ACCURACY OF CONE BEAM COMPUTED TOMOGRAPHY (CBCT) IN ASSESSMENT OF MANDIBULAR MOLAR FURCATION DEFECTS AS COMPARED TO THE INTRA-OPERATIVE FINDINGS

Hisham M. Warda¹BDs, Yousria S. Gaweesh² PhD, Adel M. Rizk³ PhD, Rania A. Fahmy⁴ PhD

ABSTRACT

INTRODUCTION: The precise assessment of mandibular molar furcation defects is crucial before a prognosis and a treatment strategy can be established. The use of CBCT in periodontology has led to an increased precision in diagnosis of bone morphology.

OBJECTIVES: The aim of this study is to determine the accuracy of cone beam computed tomography (CBCT) in the assessment of mandibular molar furcation defects when compared to intra-surgical assessment.

MATERIALS AND METHODS: The study included 19 mandibular molar furcation defects. Three different CBCT measurements were taken: (bone loss in the horizontal direction – 'BL-H'), degree of bone loss in vertical direction (BL-V) and width of the furcation entrance (FW). Measurements were compared to the intra-surgical measurements and results were statistically analysed.

RESULTS: There was no significant difference between measurements taken using CBCT and measurements taken intra-surgically giving a p value of 0.101, 0.201 and 0.910 for FW, BL-V and BL-H respectively.

CONCLUSIONS: CBCT is an accurate way in assessing mandibular molar furcation defects

KEYWORDS: CBCT, Furcation, Mandibular molar.

1-Instructor at Oral Medicine, Periodontology, Oral Diagnosis and Radiology Department, Faculty of Dentistry, Alexandria University, Alexandria, Egypt.

2-Professor of Oral Medicine, Periodontology, Oral Diagnosis and Radiology Department, Faculty of Dentistry, Alexandria University, Alexandria, Egypt.

3-Professor of Radiology, Faculty of Medicine, Alexandria University, Alexandria, Egypt.

4-Lecturer of Oral Medicine, Periodontology, Oral Diagnosis and Radiology Department, Faculty of Dentistry, Alexandria University, Alexandria, Egypt.

Corresponding author:

E-mail: hishamwarda@gmail.com

INTRODUCTION

Periodontitis is a disease of the periodontium characterized by irreversible loss of connective tissue attachment and supporting alveolar bone. The extension of periodontal disease into the bi- or trifurcation of multirooted teeth is known as furcation involvement (FI). This presents a unique set of challenges to the periodontal management of posterior dentition (1).

Furcation lesions are usually caused by plaque, as a consequence of periodontal disease. However, other factors may also contribute to furcation involvement such as occlusal trauma, periodontal pulp disease (accessory pulp canal), root fracture, invagination of the enamel, enamel pearls, and developmental grooves (2).

When periodontal disease affects the furcation of a tooth, the chance that it will be lost increases considerably. An increase in the exposed root surface, anatomical peculiarities and irregularities of the furcation surface all favor the growth of bacteria. These problems make it harder for the patient to maintain hygiene, and impede adequate treatment (3,4).

Treatment of furcation involvement will depend on the extent of the disease, the strategic importance of the affected tooth, and the degree of patient cooperation. All therapy must first begin with periodontal treatment (systemic and basic phases, followed by re-evaluation) and adequate hygiene on the part of the patient. Undoubtedly, the furcation constitutes one of the zones in the oral cavity where plaque is most difficult to remove (5).

Periodontists commonly encounter difficulty of accurately assessing and treating furcations affected by periodontal disease. Mandibular molars are typically affected and highly damaged by this disease. Studies have demonstrated that multi-rooted teeth do not respond so well to nonsurgical periodontal treatment, when compared to the single-rooted teeth (6,7).

The precise diagnosis of FI must be obtained before a prognosis and treatment strategy can be established (8).

Furcation involvement (FI) is assessed using a combination of probing and radiographs. The accuracy of probing is dependent on factors such as tooth position, inclination, the presence of adjacent teeth, variability in operator technique, the type of probe, probe tip diameter, probing force, and root anatomy. As a result, radiographs are often needed to supplement findings (9,10).

A number of intraoral and extraoral imaging modalities are available to assist in the management of the periodontally affected patient. Commonly used modalities include bitewing, periapical and panoramic radiography. However, radiographs give a 2-D representation of 3-D structures, and their limitations have been well described. (11,12). Also the minimum size necessary to detect a lesion using conventional periapical radiography is 0.5mm due to the technical problems of correctly positioning the X-ray film, and the superimposition of anatomical structures (2). These limitations reduce the sensitivity of intraoral periapical radiograph and generally result in underestimating actual bone loss even when high quality images are produced (11-13).

To overcome the inherent difficulties of intraoral periapical radiograph, 3-D image analysis by computed tomography (CT) has been introduced and is widely used for 3-D maxillofacial imaging in dentistry (14).

The Computed tomography (CT) has been considered the gold standard for radiographic interpretation for many years due to the precise three dimensional data it provides. But recently it has been increasingly replaced by the latest imaging technology cone beam computed tomography (CBCT), that is very promising relevant to dental imaging. It is a new variant of the known medical grade CT that was first introduced in the European market in 1996 and into the US market in 2001 (15,16).

Cone beam computed tomography (CBCT) generates 3D volumetric images which provide axial, coronal and sagittal multi-planar reconstructed images without magnification and renders image guidance throughout the treatment phase.(17) The effective dose of radiation for CBCT was shown to be much lower as compared with medical grade CT, where in the maxillofacial imaging procedures, CBCT produces 8- to 10-fold lower effective dose than a medical grade CT examination using standard protocol.(18) In this regard CBCT achieves the ALARA rule (which states that all radiographic information should be obtained with radiation doses that are As Low As Reasonably Achievable). Also, CBCT units are smaller in size and offer lower cost less time and easier procedure as compared to CT technology (17-20).

During a CBCT scan, the scanner rotates around the patient's head, obtaining up to nearly 600 distinct images. The scanning software collects the data and reconstructs it, producing a digital image that can then be manipulated and visualized with specialized software (21,22).

The selection of an appropriate therapy for furcation involvement is often based on the accurate diagnosis and classification of FI. In addition, the contour of residual bone, root trunk length, root morphology and degree of root separation will contribute to the decision-making process of treatment planning.

As CBCT allows us to visualize all of these parameters, it seems likely that the utilization of this modality in a periodontal setting will improve the diagnosis and management of patients with furcation-involved teeth, however, more clinical studies are needed to support this conclusion. The aim of this study, therefore, is to investigate the accuracy of dental CBCT in assessing FI in mandibular molars.

MATERIALS AND METHODS

i. Study design

A prospective comparative study conducted on nineteen furcation defects chosen from patients presenting to the outpatient clinic at the department of Oral Medicine, Periodontology, Oral Diagnosis, and Oral Radiology, Faculty of Dentistry, Alexandria University. Patients received a CBCT examination to measure their mandibular molar furcation defect and the measurements were compared with clinical intra-surgical readings taken during the surgical treatment.

ii. Sample Size

A sample of 19 furcation defects (23) was required to estimate an average agreement between CBCT assessment and intra-surgical measurements = 82.4%(24), using alpha

error = 0.05 and precision of 10% will provide a study power of 80%

The sample size was calculated using Med Calc software.

iii. Criteria for patient selection

iv. Inclusion Criteria

- 1- Patients with periodontal disease with one or more advanced furcation defects, defined as horizontal inter-radicular loss of periodontal tissues of degree II or III (Hamp et al. (1975) (24,25).
- 2- Patients age range between 30-60 years.
- 3- Patients indicated for surgical approach for the treatment of the furcation defect (25,26).

Exclusion Criteria

- 1- Patients not indicated for periodontal surgery.
- 2- Pregnant females.
- 3- Patients with furcation caries
- 4- Silver amalgam fillings near the alveolar crest.
- 5- Metal crowns in CBCT irradiation area (24).

v. patient preparation

- All patients were informed of the purpose of this study and signed an informed consent form.
- Initial therapy, including oral hygiene instruction, scaling and root planing with ultrasonic devices and hand instruments and occlusal adjustment was performed.

vi. Evaluation of the furcation defect

A- Pre-surgical clinical measurements:

FI of the selected mandibular molars were measured from the buccal aspect

The horizontal furcation measurements were taken using a Nabers Probe (Hu-Friedy) starting at the furcation entrance to the greatest horizontal depth. Measurements were rounded up to the nearest millimeter (24).

B- Measurements of dental CBCT

Prior to surgery, CBCT was performed in the posterior mandibular area using the high-resolution imaging system 3D J. Morita, Kyoto, Japan. Fig (1).

The slice thickness was set at 0.5 mm, and the pitch was set at 0.125 mm.

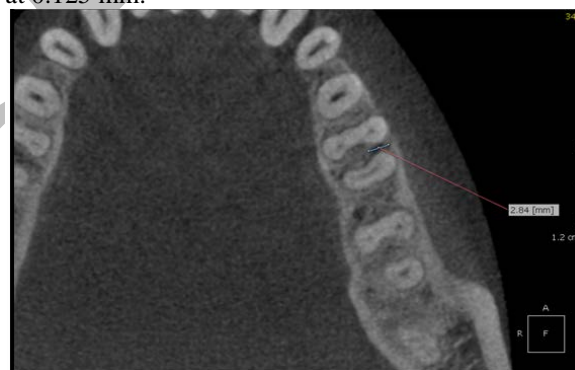

Figure (1): CBCT BL-H measurement

Measurements were made to the nearest 0.01 mm using the On Demand 3D software by Cybermed Inc. with a linear measurement tool and a digital magnification lens (24).

2- Furcation involvement was calculated in the horizontal plane by measuring the distance between the outer root surface and the inter-radicular bone (bone loss in the horizontal direction – 'BL-H') Fig (2).

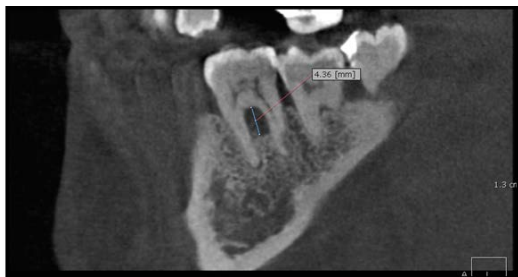


Figure (2): CBCT BL-V measurement

3- Degree of bone loss in vertical direction (BL-V) was decided by measuring the distance from the furcation entrance to the base of the defect in the vertical direction. Fig (3).

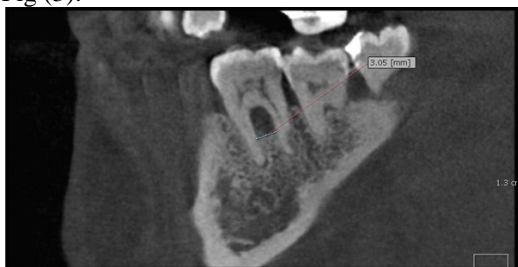

Figure (3): CBCT FW measurement

4- The width of the furcation entrance (FW) was measured by measuring the greatest mesio-distal distance in the furcation. (24) Fig (4).

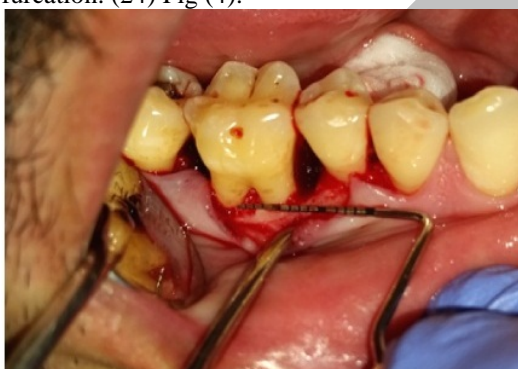

Figure (4): intra-surgical FW measurement

C-Intra-surgical measurements

The patients were administered local anaesthesia, flaps were reflected, defects were debrided and all direct surgical measurements were made (24,25).

1. Furcation width (FW) for the buccal was a measure of the greatest mesio-distal distance in the furcation. Fig (5).

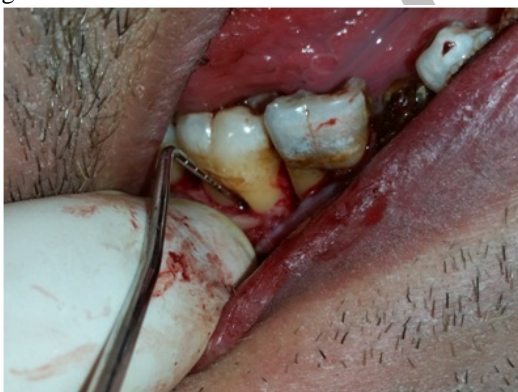

Figure (5): intra-surgical BL-V measurement

2. Degree of BL-V in the furcation was decided by measuring the distance from the furcation entrance to the base of the defect in the vertical direction. Fig (6).

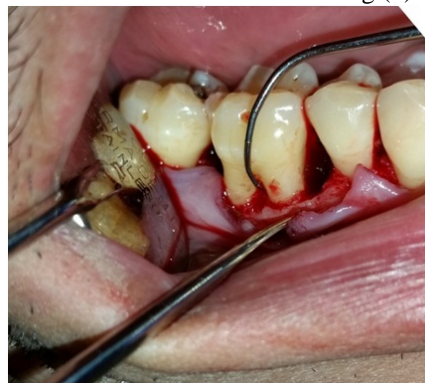

Figure (6): intra-surgical BL-H measurement

3. Horizontal measurement was recorded representing the distance between the outer root surface and the interdental bone (bone loss in the horizontal direction – ‘BL-H’). Fig (7).

Hard tissue measurements rounded up to the nearest millimeter were taken for each defect using a curved scaled Nabers probe (HU-Friedy), marked at 3 mm intervals, and a manual 9 mm periodontal probe (HU-Friedy, Michigan probe).

Appropriate treatment for the furcation defects was done simultaneously while acquiring measurements for the furcation defects.

Wounds were sutured using size 4-0 silk, and patients will be advised to rinse twice a day with 0.12% chlorhexidine.

Postoperative care:

All patients received:

- Antibiotic, amoxicillin/clavulanate (Augmentin) 1g tablets every 12 hours
- Non-steroidal anti-inflammatory was also prescribed 3 times daily for 4 days. The patients were instructed to follow good oral hygiene instructions.
- The sutures were removed 7-10 days, post-operatively.

Statistical analysis

Mean values for each measurement were calculated. Differences were analyzed using t-test.

RESULTS

This study was conducted to evaluate the accuracy of CBCT in the assessment of mandibular molar furcation defects when compared to intra-surgical assessment.

Nineteen furcation defects were measured pre-operatively using CBCT scans and 3 measurements were recorded (FW, BL-V, BL-H) using the Ondemand software and then the same measurements were recorded during the treatment surgery for the defects and the results are shown in table 1,2 and 3.

Table (1): Comparison between the two studied cases according to FW in mm

Width of furcation entrance (FW)	Intra-surgical (n=19)	CBCT (n=19)	p
Min. – Max.	1.0 – 4.0	1.10 – 3.80	0.101
Mean ± SD.	2.68 ± 1.06	2.58 ± 0.91	
Median	3.0	2.81	

p: value for **Paired t-test** for comparing between CBCT and Clinical

Table (2): Comparison between the studied cases according to BL-V in mm

Vertical bone loss (BL-V)	Intra-surgical (n=19)	CBCT (n=19)	p
Min. – Max.	2.0 – 6.0	2.0 – 5.94	0.201
Mean ± SD.	3.58 ± 1.02	3.49 ± 1.01	
Median	3.0	3.30	

p: value for **Paired t-test** for comparing between CBCT and Clinical

Table (3): Comparison between the studied cases according to BL-H in mm

Horizontal bone loss (BL-H)	Intra-surgical (n=17) [#]	CBCT (n=17) [#]	p
Min. – Max.	1.0 – 8.0	1.20 – 7.54	0.910
Mean ± SD.	3.29 ± 1.69	3.30 ± 1.51	
Median	3.0	3.10	

p: value for **Paired t-test** for comparing between CBCT and Clinical

[#]: There are two cases that were dropped due to having a grade III through and through furcation involvement which had no measurement for BL-H

With reference to Table (1) the results of the comparison of the FW measurement between the intra-surgical and the CBCT measurements shows a mean of 2.68 ± 1.06 for intra-surgical measurements and a mean of 2.58 ± 0.91 for the CBCT.

A minimum measurement of 1.0 and a maximum of 4.0 for the intra-surgical measurements and a minimum measurement of 1.10 and a maximum of 3.80 for CBCT measurements were recorded.

There was no significant difference between the two methods for the FW measurement ($p= 0.101$) As shown in table (1).

With reference to Table (2) the results of the comparison of the BL-V measurement between the intra-surgical and the CBCT measurements shows a mean of 3.58 ± 1.02 for intra-surgical measurements and a mean of 3.59 ± 1.01 for the CBCT.

A minimum measurement of 2.0 and a maximum of 6.0 for the intra-surgical measurements and a minimum measurement of 2.0 and a maximum of 5.94 for CBCT measurements were recorded.

There was no significant difference between the two methods for the BL-V measurement ($p= 0.201$) As shown in table (2).

With reference to Table (3) the results of the comparison of the BL-H measurement between the intra-surgical and the CBCT measurements shows a mean of 3.29 ± 1.69 for intra-surgical measurements and a mean of 3.30 ± 1.51 for the CBCT.

A minimum measurement of 1.0 and a maximum of 8.0 for the intra-surgical measurements and a minimum measurement of 1.20 and a maximum of 7.54 for CBCT measurement.

There was no significant difference between the two methods for the BL-H measurement ($p= 0.910$) As shown in table (3).

DISCUSSION

Cone beam computed tomography (CBCT) represents a promising diagnostic tool in the field of oral and maxillofacial surgeries. CBCT provides sectional information of dental anatomy and pathology at a fraction of the radiation dose received in conventional medical CT. Kasaj and Willershausen concluded that the low dosage and superior image quality in comparison with conventional CT are promising for periodontal applications, especially in the areas of intrabony defects, dehiscence and fenestration defects, and periodontal cysts, and in the diagnosis of furcation-involved molars (26). As CBCT allows us to visualize all parameters of periodontal defect morphology and tooth form, it seems likely that the utilization of this modality in a periodontal setting will improve the diagnosis and management of patients with furcation-involved teeth (27).

This study was performed to investigate the accuracy of dental CBCT in assessing FI in mandibular molars. CBCT generated data of FI in mandibular molars were analysed in comparison with intra-surgical assessments, the current "gold standard" for diagnosis of FI.

The present study has demonstrated that CBCT assessment of mandibular molar FI has shown no significant difference between the intra-surgical and CBCT for all 3 assessed measurements (FW, BL-V, BL-H). Furthermore, CBCT generated data added a substantial amount of information about the form of the furcation, the morphology of the defect, the roots and the severity of the lesions that cannot currently be obtained from conventional clinical assessments.

The superiority of CBCT over clinical assessment was confirmed through several studies where Walter et al showed that CBCT provides more detailed information about the degree of FI compared to the clinical findings and periapical radiographs. Also recently Cimbaljevic in 2015 concluded that the number of FI detected by means of CBCT was larger than by means of periodontal probing and suggested that CBCT may be used as an adjunct tool for FI assessment (28,29,30).

The results of the present study showed that the difference between FW and BL-V based on CBCT data and intra-surgical assessment was not statistically significant ($p > 0.05$). FW measurements for CBCT and intrasurgical assessment were 2.58 ± 0.91 and 2.68 ± 1.06 respectively, and for the BL-V 3.49 ± 1.01 and 3.58 ± 1.02 respectively. The difference detected was less than 0.5 mm the minimum accuracy of periodontal probing. One explanation of the error that exists between CBCT and direct clinical measurements is the different accuracy of both measurements. In this study, probing measurements were

only able to be made to the nearest 0.5 mm, whereas CBCT measurements were able to be made to the nearest 0.1 mm. Another explanation may be due to the location of the furcation entrance. Where Santana in 2004 observed 100 extracted permanent human mandibular molars and found that clinical measurements of horizontal probing depth that used the external surfaces of roots as reference points overestimated the true anatomical component of FI in mandibular molars (31).

Therefore, the error between CBCT based data and intra-surgical assessment of mandibular molar FI could be accepted in periodontal clinical application. In other words, CBCT-based data accurately reflects the true state of mandibular molar FI.

Of the three parameters assessed in this study, the intra-surgical findings BL-H was confirmed in the CBCT based data. Readings revealed by CBCT were 3.30 ± 1.51 mm, which was most consistent with the intra-surgical value of 3.29 ± 1.69 mm ($p > 0.05$). Regarding the BL-V and FW, CBCT appears to give an underestimation however the difference was not statistically significant. It was previously demonstrated that estimates from a three-dimensional cone-beam computed tomography of the furcation involvement of maxillary molars have a high degree of agreement with those from intrasurgical assessments. Where, 84% of the CBCT data were confirmed by the intrasurgical findings. While 14.7% were underestimated (CBCT < intrasurgical value), and 1.3% were overestimation compared to the intrasurgical analysis (28).

Several studies have confirmed the accuracy of CBCT in assessment of periodontal defects and FI in accordance to the present. (31-34) Umetsubo et al who evaluated CBCT images of artificially created furcation involvement of the second molars in pig mandibles, reported accuracy for furcation lesion detection between 78% and 88% (34). In 2010 Walter et al reported that cone beam computed tomography (CBCT) and intrasurgical assessments of maxillary molar furcation involvement were found to be in substantial agreement and that CBCT enables an exact estimation and classification of furcation involvement as well as a visualization of the root morphologies with root proximities or root fusions as in the present case (28).

Feijo et al 2012 evaluated the accuracy of CBCT in the measurement of horizontal periodontal bone defects. They measured periodontal bone defects of eight maxillary molars during surgery and compared the results with data taken from CBCT images. The results showed that CBCT accurately reproduced the clinical measurement of horizontal periodontal bone defects (32).

In 2014 Qiao reported the same results regarding the accuracy of the CBCT. they concluded that CBCT and intra-surgical assessments of maxillary molar FI were found to be in strong agreement. CBCT enables the accurate estimation and classification of FI as well as a visualization of the root morphologies (35).

On the other hand, The accuracy of (CBCT) in detecting incipient furcation involvement was studied in simulated lesions created chemically by applying 70% perchloric acid. It was concluded that CBCT imaging showed high accuracy and moderate reproducibility in the detection of incipient furcation involvement. However, the authors stated that incipient furcation lesions are not considered major indications for CBCT (36).

In a systematic review for the assessment of (CBCT) for diagnosis and treatment planning in periodontology, Walter et al in 2016 (37) confirmed our findings stating that sufficient evidence indicated a high accuracy of CBCT imaging for the analysis of furcation involvement of maxillary molars in particular. In addition, data from one case series indicated a discrepancy in treatment recommendations for the majority of molars with the treatment decisions based on clinical data and periapical radiographs compared to those obtained by additional CBCT. However, Walter et al (37) stated that radiographic imaging using CBCT still enables a higher radiation dose compared to conventional 2D images, including periapical radiographs and panoramic images. Therefore, the use of CBCT and its potential risks and benefits needs to be carefully considered in each individual case.

It is obvious that the accurate detection of the furcation involvement and the assessment of the root morphology affects the diagnosis and is consequently essential for the choice of treatment, the tooth prognosis, and the maintenance procedures. Within the scope of the previous studies and the present study, CBCT provided high accuracy for detecting furcation involvement and morphology of surrounding periodontal tissues. CBCT can thus facilitate more detailed surgical treatment planning with a clear decision about resective interventions, and the roots that are planned to be kept (29). CBCT can thus aid complex treatment planning.

CONCLUSION

Within the limitation of our study we concluded that:

- There is no significant difference between measurements taken using CBCT and measurements taken intra-surgically
- CBCT is an accurate way in assessing mandibular molar furcation defects.

CONFLICT OF INTEREST

The authors declare that they have no conflicts of interest.

REFERENCES

1. Bascones-Martínez A, Figuero-Ruiz E. Periodontal diseases as bacterial infection. *Med Oral Patol Oral Cir Bucal* 2004; 9 Suppl: 101-7, 92-100.
2. Sánchez-Pérez A, Moya-Villaescusa M. Periodontal disease affecting tooth furcations. A review of the treatments available. *Med Oral Patol Oral Cir Bucal* 2009 Oct 1; 14 (10):554-7.
3. Hirschfeld L, Wasserman B. A long-term survey of tooth loss in 600 treated periodontal patients. *J Periodontol* 1978; 49: 225-237.
4. McFall WT. Tooth loss in 100 treated patients with periodontal disease. A long-term study. *J Periodontol* 1982; 53: 539-549.
5. McClain PK, Schallhorn RG. Focus on furcation defects-guided tissue regeneration in combination with bone grafting. *Periodontol* 2000; 22:190-212.
6. Nordland P, Garrett S, et al., The effect of plaque control and root debridement in molar teeth. *J Clin Periodontol* 1987;14(4), 231-6.
7. Loos, B, Nyland K, et al. Clinical effects of root debridement in molar and non-molar teeth. A 2-year follow-up. *J Clin Periodontol* 1989;16(8), 498-504.

8. DeSanctis M, Murphy KG. The role of resective periodontal surgery in the treatment of furcation defects. *Periodontol* 2000; 22:154-68.
9. Ramadan AB, Mitchell DF. A roentgenographic study of experimental bone destruction. *Oral Surg Oral Med Oral Pathol.* 1962;15:934-43
10. Theilade J. An evaluation of the reliability of radiographs in the measurement of bone loss in periodontal disease. *J Periodontol.* 1960;31:143-53.
11. Gupta, A., Devi, P., Srivastava, R., & Jyoti, B. (2014). Intra oral periapical radiography-basics yet intrigue: A review. *Bangladesh Journal of Dental Research & Education*, 4(2), 83-87.
12. Theilade J. An evaluation of the reliability of radiographs in the measurement of bone loss in periodontal disease. *J Periodontol.* 1960;31:143-53.
13. Prichard J. Interpretation of radiographs in periodontics. *Int J Periodontics Restorative Dent.* 1983;3(1):8-39
14. Ramachandran GN, Lakshminarayanan AV. Three dimensional reconstruction from radiographs and electron micrographs: Application convolutions instead of Fourier Transforms. *Proc Natl Acad Sci.* 1971;68:2236-40.
15. Monsour PA, Dudhia R. Implant radiography and radiology. *Aust Dent J.* 2008 Jun; 53 Suppl 1:11-25.
16. Scarfe WC, Farman AG, Sukovic P. Clinical applications of cone-beam computed tomography in dental practice. *J Can Dent Assoc* 2006; 72:75-80.
17. Suomalainen A, Pakbaznejad Esmaeili E, Robinson S. Dentomaxillofacial imaging with panoramic views and cone beam CT. *Insights Imaging.* 2015 Feb;6(1):1-16.
18. Tsiklakis K, Donta C, Gavala S, Karayianni K, Kamenopoulou V, Hourdakakis CJ. Dose reduction in maxillofacial imaging using low dose Cone Beam CT. *European Journal of Radiology.* 2005;56(3):413-7.
19. Danforth RA. Cone beam volume tomography: a new digital imaging option for dentistry. *J Calif Dent Assoc.* 2003 Nov; 31(11):814-5.
20. Palomo, J.M., Rao, P.S. & Hans, M.G. Influence of CBCT exposure conditions on radiation dose. *Oral Surgery, Oral Medicine, Oral Pathology, Oral Radiology & Endodontics* 2008;105: 773-782.
21. Hatcher DC. Operational principles for cone-beam computed tomography. *Journal of the American Dental Association.* October 2010;141 (Suppl 3): 3S-6S.
22. Orth RC, Wallace MJ, Kuo MD. C-arm cone-beam CT: general principles and technical considerations for use in interventional radiology. *Journal of Vascular and Interventional Radiology.* June 2008;19 (6): 814-20.
23. Ramachandran GN, Lakshminarayanan AV. Three dimensional reconstruction [6] from radiographs and electron micrographs: Application convolutions instead of Fourier Transforms. *Proc Natl Acad Sci.* 1971;68:2236-40.
24. Daniel W. *Biostatistics. A foundation for analysis in the health science.* 6th edition, NY: John Wiley and sons, Inc; 1995.
25. Hamp SE, Nyman S, Lindhe J. Periodontal treatment of multirooted teeth. Results after 5 years. *J Clin Periodontol* 1975;2:126-135.
26. Kasaj A, Willershausen B. Digital volume tomography for diagnostics in periodontology. *Int J Comput Dent* 2007;10:155-68.
27. Svärdröm G, Wennström JL. Prevalence of furcation involvements in patients referred for periodontal treatment. *J Clin Periodontol.* 1996;
28. Walter C, Weiger R, Zitzmann NU. Accuracy of threedimensional imaging in assessing maxillary molar furcation involvement. *J Clin Periodontol* 2010; 37: 463-441.
29. Walter C, Kaner D, Berndt DC, Weiger R, Zitzmann NU. Three-dimensional imaging as a pre-operative tool in decision making for furcation surgery. *J Clin Periodontol* 2009;36:250-257.
30. Milena M. Cimbaljevic, DDS1/Rubens R. Spin-Neto, DDS, MSc, PhD2/Vesna J. Miletic, BDS, MSc, PhD3/Sasa M. Jankovic, DDS, MSc, PhD4/Zoran M. Aleksic, DDS, MSc, PhD4/Natasa S. Nikolic-Jakoba, DDS, MSc, PhD5 Clinical and CBCT-based diagnosis of furcation involvement in patients with severe periodontitis *Quintessence Int* 2015;46:863-870
31. Santana RB1, Uzel MI, Gusman H, Gunaydin Y, Jones JA, Leone CW. Morphometric analysis of the furcation anatomy of mandibular molars. *J Periodontol.* 2004 Jun;75(6):824-9.
32. Feijo CV, Lucena JG, Kurita LM, Pereira SL. Evaluation of cone beam computed tomography in the detection of horizontal periodontal bone defects: an in vivo study. *Int J Periodontics Restorative Dent.* 2012;32(5):e162-68.
33. Grimard BA, Hoidal MJ, Mills MP, Mellonig JT, Nummikoski PV, Mealey BL. Comparison of clinical, periapical radiograph, and cone-beam volume tomography measurement techniques for assessing bone level changes following regenerative periodontal therapy. *J Periodontol* 2009;80:48-55.
34. Umetsubo OS, Gaia BF, Costa FF, Cavalcanti MG. Detection of simulated incipient furcation involvement by CBCT: an in vitro study using pig mandibles. *Braz Oral Res.* 2012;26:341-347.
35. Qiao J, Wang S, Duan J, Zhang Y, Qiu Y, Sun C, Liu D. The accuracy of conebeam computed tomography in assessing maxillary molar furcation involvement. *J Clin Periodontol* 2014; 41: 269-274
36. Otavio Shoití Umetsubo; Bruno Felipe Gaia; Felipe Ferreira Costa; Marcelo Gusmão Paraiso Cavalcanti. Detection of simulated incipient furcation involvement by CBCT: an in vitro study using pig mandibles *Braz. oral res.* vol.26 no.4 São Paulo July/Aug. 2012
37. WALTER, Clemens, et al. Cone beam computed tomography (CBCT) for diagnosis and treatment planning in periodontology: A systematic review. *Quintessence Int*, 2016, 47.1: 25-3.