

Case Report:

Intracranial Extra-Medullary Hematopoiesis in a Child with Osteopetrosis

SHAKIR A. ALJERDAH, M.D.

The Department of Medicine, College of Medicine, Najran University, Najran, Kingdom of Saudi Arabia

Abstract

Background: To present a case report of intracranial extra-medullary intracranial hematopoiesis in a Saudi female child with osteopetrosis.

Case Report: We report a case of a Saudi girl child aged seven years, who presented to the Emergency Department of Najran University Hospital, with headache, repeated vomiting and decreased level of consciousness. She was previously diagnosed as a case of osteopetrosis at the age of one year. She was found to have intracranial extra-medullary hematopoiesis, as evidenced by CT brain along with subsequent intracranial complications.

Conclusions: Osteopetrosis is a rare disease, especially among children. Its complications should be considered in management of children with osteopetrosis complaining of manifestations of increased intracranial pressure.

Key Words: *Osteopetrosis – Extramedullary hematopoiesis – Hydrocephalus – Optic nerve atrophy – Splenectomy.*

Introduction

OSTEOPETROSIS, or "marble bone disease", includes a clinically and genetically heterogeneous group of conditions that share the hallmark of increased bone density on radiographs [1]. The increased bone density is attributed to defected remodeling, caused by failure of normal osteoclast differentiation or function [2].

Osteopetrosis is quite rare, especially among children, with an estimated prevalence of only one case in 100,000 to 500,000. Its severity can widely range from asymptomatic to fatal in infancy [3].

Serious forms of osteopetrosis can result in stunted growth, deformity, and an increased like-

lihood of fractures. Osteopetrosis can also result in blindness, facial paralysis, and deafness, due to the increased pressure put on the nerves from the excess bone formation encroaching on the cranial nerve foramina. Patients may also suffer anemia, recurrent infections, hepatosplenomegaly, and extramedullary hematopoiesis [4].

In view of the rarity of osteopetrosis, especially in the pediatric age group, this paper aims to present a case report of intracranial extra-medullary intracranial hematopoiesis in a Saudi female child with osteopetrosis.

Case Report

On September 21st, 2017, a 7-year old Saudi girl presented to the Emergency Department of Najran University Hospital, with headache, repeated vomiting and decreased level of consciousness.

The girl was the only daughter of her parents who were cousins. She was diagnosed as a case of osteopetrosis at the age of one year, and has been frequently hospitalized since then. No other similar cases were noted in her family. In 2013, the child was hospitalized with severe anemia and low platelet count and underwent splenectomy.

Non-enhanced CT scan of the brain with no IV contrast revealed stigmata of osteopetrosis seen in the skull, with presence of severely thickened calvarium, facial bones and skull base and narrowing of skull base foramina and optic canals with probable optic nerve atrophy and there is proptosis particularly on the left side. There was total obliteration of the marrow (diploic) spaces with development of bilateral areas of extra-axial spontaneously hyperdense tissue along the parietal convexities and around the superior sagittal sinus

Correspondence to: Dr. Shakir A. Aljerdah,
The Department of Medicine, College of Medicine,
Najran University, Najran, Kingdom of Saudi Arabia

and torcular herophili that are suggested to be related to areas of extramedullary hematopoiesis (Fig. 1). The brain was protruding upward into the anterior fontanelle as a result of limited intracranial volume (Fig. 2).

Moreover, there was evidence of crowding of the posterior fossa structures and tonsillar ectopia with supratentorial long-standing hydrocephalus and cerebral white matter hypodensities, suggestive of development of leukoencephalopathy.

The radiologic conclusion for our case was a known case of osteopetrosis in a child, which seems

to be of the malignant autosomal recessive type, with presence of classical severe thickening and sclerosis of the calvarium, facial bones and skull base with total absence of the diploic spaces and development of bilateral extra-axial extramedullary hematopoiesis along the parietal convexities and there is upward protrusion of the brain parenchyma into the anterior fontanelle as a result of limited intracranial volume. Tonsillar ectopia is present with long-standing hydrocephalus and development of leukoencephalopathy. No evidence of intraparenchymal hemorrhage or infarction. Stenosis of the skull base foramina and optic canals with probable optic nerve atrophy and proptosis.

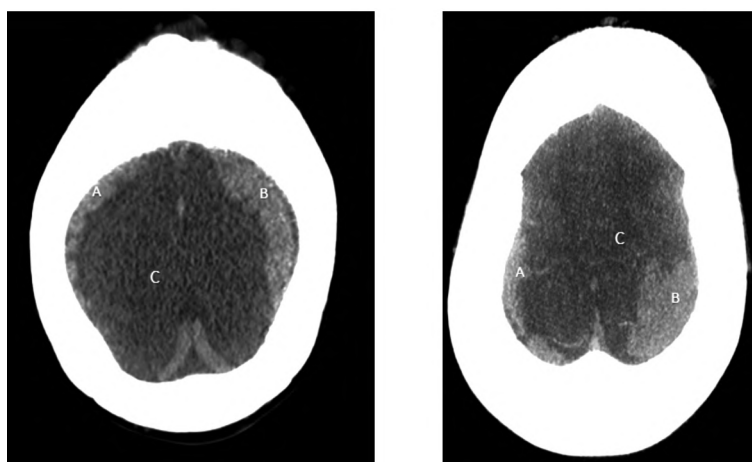


Fig. (1): Skull CT scan showing hyperdense tissue along the parietal convexities and around the superior sagittal sinus (A, B) that are related to areas of extra-medullary hematopoiesis. Note the edematous low density brain parenchyma (C).

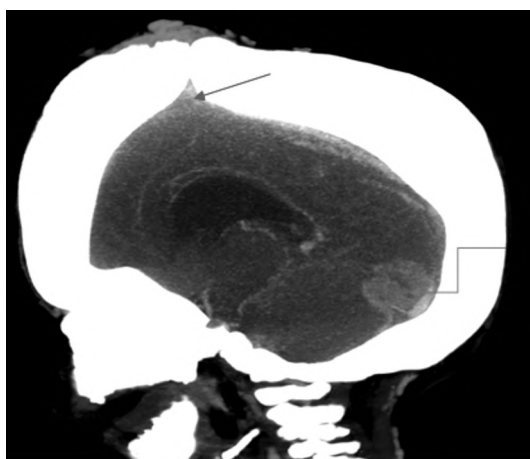


Fig. (2): Skull CT scan showing upward protrusion of the brain parenchyma into the anterior fontanelle (red arrow), and intracranial hematopoiesis (blue arrow). Also note the thickened skull bone.

Discussion

Osteopetrosis is a rare hereditary metabolic bone disorder characterized by generalized skeletal sclerosis caused by a defect in bone resorption and remodeling [5].

Our case was a 7-year old Saudi girl, who was diagnosed shortly after her first year of age as a case of osteopetrosis of the malignant autosomal recessive type. She was a daughter for her parents who were cousins, but no similar condition was present in her family. The diagnosis of her condition was mainly based on clinical and radiological assessment of her condition.

Osteopetrosis is very rare disease. It presents in two major clinical forms-a benign autosomal dominant form and a malignant autosomal recessive form. The autosomal dominant adult (benign) form is associated with few, if any, symptoms, and the autosomal recessive infantile (malignant) form is typically fatal during infancy or early childhood if untreated [6].

The incidence of the autosomal recessive type is 1 in 250,000 births, while the autosomal dominant osteopetrosis has an incidence of 5 in 100,000 births [1]. El-Sobky et al. [5] stressed that the role of accurate clinical and radiological assessment remains an important contributor to the diagnosis of infantile osteopetrosis.

Skull CT scan for our case showed thickened skull bone and extra-medullary intracranial hematopoiesis.

Jamjoom et al. [7] noted that, in osteopetrosis, the osteoclasts dysfunction affects cartilage clearance, which reduces marrow spaces in long bones and leads to extramedullary hematopoiesis and because of reduced bone clearance results in “bone-in-bone formation”. Since membranous bone does not have cartilage, the irregular bone deposition does not occur and the skull demonstrates radiologically a smooth generalized bone thickening from failure of bone resorption rather than focally over suture sites.

Within few years after diagnosis, several complications occurred to our case, e.g., severe anemia, low platelet count, hydrocephalus, and optic nerve atrophy. She underwent splenectomy for management of the low platelet count.

These findings are in accordance with those reported by Turgut et al., who reported that clinical symptoms of osteopetrosis include anemia, hepatosplenomegaly, and cranial nerve and/or brainstem compression and hydrocephalus due to foraminal narrowing in the skull.

Wilson and Vellodi [9] noted that children with osteopetrosis usually present within the first year of life and frequently as early as within the first three months. Parental concern regarding the child's vision is the most common presenting complaint. Other presentations include failure to thrive and recurrent infection, both secondary to the underlying anemia and bone marrow involvement. Excessive bruising, fractures, and an abnormal craniofacial appearance are less common presenting complaints. Hepatosplenomegaly is usually present at an early age, but it may be missed and because of the disease rarity a correct clinical diagnosis is often not initially made.

Yadav et al. [9] stated that, in cases of osteopetrosis, the abnormal expansion of bone interferes with medullary hematopoiesis resulted in life-threatening pancytopenia and extra-medullary hematopoiesis which may lead to enlargement of liver and spleen. This form is fatal in majority of cases within the first five years of life.

The increased bone mass in cases of osteopetrosis can result in phenotypic features such as macrocephaly and altered craniofacial morphology, but more importantly impacts on other organs and tissues, notably the bone marrow and nervous systems [2]. Therefore, extra-medullary hematopoi-

esis is a compensatory phenomenon and commonly involves liver, spleen and lymph nodes, but very rarely the brain may be involved [10].

Raghunath [1] stated that management strategies for osteopetrosis include correcting anemia thrombocytopenia and treating infections. Bone marrow transplant and splenectomy may be useful in some patients.

Skeletal alterations of patients are so characteristic that diagnosis is ascertained usually by standard radiographs. The classic radiological features of osteopetrosis comprise diffuse sclerosis, affecting the skull, spine, pelvis and appendicular bones, medullary compartment often obliterated by immature unresorbed bone, bone modeling defects at the metaphyses of long bones, such as funnel-like appearance (Erlenmeyer flask deformity) and characteristic lucent bands, bone-in-bone appearance particularly in the vertebrae and phalanges, focal sclerosis of the skull base, pelvis and vertebral end plates-sandwich vertebrae and “ruggerjersey” spine and transverse fractures [12].

In conclusion, osteopetrosis is a rare disease. Among children, it is usually of the malignant autosomal recessive type. Its complications should be considered in management of children with osteopetrosis complaining of manifestations of increased intracranial pressure.

References

- 1- SUJITH DEVAPRASAD P. and CHANDRANNA B.: Osteopetrosis : A Case Report. *International Journal of Current Medical and Applied Sciences*, 6 (3): 159-162, 2015.
- 2- SUPERTI-FURGA A. and UNGER S.: The Nosology Group of the International Skeletal Dysplasia Society. *Nosology and Classification of genetic skeletal disorders: 2006 revision. American Journal of Medical Genetics A*, 143 (1): 1-18, 2007.
- 3- LANDA J., MARJOLIS N. and DI CESARE P.: Orthopaedic management of the patient with osteoporosis. *J. Am. Acad. Orthop. Surg.*, 15: 654-662, 2007.
- 4- LUZZI V., CONSOLI G., DARYANANI V., SANTORO G., SFASCIOTTI G.L. and POLIMENI A.: Malignant infantile osteopetrosis: Dental effects in paediatric patients. *Case reports. Eur. J. Paediatr. Dent.*, 7 (1): 39-44, 2006.
- 5- EL-SOBKY T.A., ELSOBKY E., SADEK I., ELSAYED S.M. and KHATTAB M.F.: A case of infantile osteopetrosis: The radioclinical features with literature update. *Bone Reports*, 4: 11-16, 2016.
- 6- ARUMUGAM E., HARINATHBABU M., THILLAI-GOVINDAN R. and PRABHU G.: Marble Bone Disease: A Rare Bone Disorder. *Cureus*, 7 (10): e339, 2015.
- 7- JAMJOOM A.A.B., JAMJOOM B.A., WALIUDDIN A.R. and JAMJOOM A.B.: Lessons from a case of oste-

- opetrosis oxycephaly and Chiari type I malformation: A case report. Cases J., 2: 6787, 2009.
- 8- WILSON C.J. and VELLODI A.: Autosomal recessive osteopetrosis: Diagnosis, management, and outcome. Arch. Dis. Child, 83: 449-452, 2000.
- 9- YADAV S., CHALISE S., CHAUDHARY S., SHAH G.S., GUPTA M.K., MISHRA O.P.: Osteopetrosis in two siblings: Two case reports. BMC Res. Notes, 9: 55, 2016.
- 10- SHAH B.K. and CHEN H.: Extramedullary Hematopoiesis in Osteopetrosis. J. Formos Med. Assoc., 109 (10): 735, 2010.
- 11- RAGHUNATH REDDY M.H.: Osteopetrosis (Marble Bone Disease): A Rare Disease in Children. Int. J. Clin. Pediatr. Dent., 4 (3): 232-234, 2011.
- 12- STARK Z. and SAVARIRAYAN R.: Osteopetrosis. Orphanet Journal of Rare Diseases, 4 (5): 8, 2009.

حالة نادرة لتحجر العظام في طفلة مع وجود مراكز خارج النخاع بالمخ لتكوين خلايا الدم

هدف البحث: عرض حالة نادرة لتحجر العظام في طفلة، مع وجود مراكز خارج النخاع، بالمخ ، لتكوين خلايا الدم.

تقرير الحالة: نعرض حالة طفلة سعودية تبلغ من العمر سبع سنوات، والتي جاءت إلى قسم الطوارئ في مستشفى جامعة نجران، بأعراض تشمل الصداع والقيء المتكرر وإنخفاض مستوى الوعي. وقد تم تشخيصها سابقاً على أنها حالة من تحجر العظام عندما كان عمرها سنة واحدة. وقد تبين بالفحص الإشعاعي وجود مراكز خارج النخاع بالمخ لتكوين خلايا الدم، مع مضاعفات داخل الجمجمة.

الاستنتاجات: إن تحجر العظام مرض نادر لا سيما بين الأطفال. وينبغي النظر في مضاعفاته عند علاج الأطفال الذين يعانون منه ويشكون من مظاهر زيادة الضغط داخل الجمجمة.