

## Comparison between Posterior Corneal Surface Changes after LASIK Measured by Sirius Pentacam and Orbscan IIz

AHMED F. HEIKAL, M.Sc.; WALEED A. ALLAM, M.D.; MOATAZ M. SABRY, M.D. and KHALED A. NAGY, M.D.

The Department of Ophthalmology, Faculty of Medicine, Tanta University, Egypt

### Abstract

**Purpose:** To investigate the reliability of Sirius Pentacam and OrbscanIIz in evaluating posterior corneal surface changes after LASIK.

**Methods:** This prospective observational case series study was conducted on thirty eyes of 15 patients underwent LASIK for myopia with or without myopic astigmatism at both the Ophthalmology Department of Tanta Universal Teaching Hospital and Nour El-Ein Hospital. OrbscanIIz and Sirius Pentacam examination (CSO, Firenze, Italy) were performed after LASIK to study their reliability in evaluating posterior corneal surface changes after LASIK.

**Results:** The mean elevation of the highest points on posterior corneal elevation maps after LASIK by Orbscan and Sirius was  $35.47 \pm 11.6 \mu\text{m}$  (range from  $14 \mu\text{m}$  to  $49 \mu\text{m}$ ) and  $9 \pm 2.9 \mu\text{m}$  (range from  $5 \mu\text{m}$  to  $16 \mu\text{m}$ ) respectively with no statistically significant difference between the values measured by the two methods ( $p$ -value 0.06). Regarding the maximal highest point on posterior corneal elevation maps by Orbscan and Sirius was  $50 \mu\text{m}$  and  $17 \mu\text{m}$  respectively, the difference of means by Orbscan and Sirius was 14.53 and 8 respectively, the limits of agreement from  $-8.2$  to  $37.3$  by Orbscan and  $2.4$  to  $13.6$  by Sirius respectively. The coefficient of repeatability was 36.20% by Orbscan and 16.60% Sirius, hence Orbscan is better than Sirius.

**Conclusions:** There was no statistically significant difference between the values measured by Orbscan IIz and Sirius ( $p$ -value 0.06). The coefficient of repeatability was 36.20% by Orbscan and 16.60% Sirius, hence Orbscan is better than Sirius. Surface irregularity has benefit to detect abnormal corneal topography with normal value about  $\pm 2$  within 3mm zone or  $\pm 2.5$  within 5mm zone. It is not present in Sirius but only Orbscan and this is one of advantages of Orbscan.

**Key Words:** Lasik – Posterior surface of the cornea – Orbscan II – Pentacam.

### Introduction

**LASIK** (Laser-Assisted In-Situ Keratomileusis) aims to change the shape of the anterior surface

**Correspondence to:** Dr. Ahmed F. Heikal, The Department of Ophthalmology, Faculty of Medicine, Tanta University, Egypt

of the cornea, thus changing its refractive power. This surgical procedure does not affect the posterior surface of the cornea directly and a large proportion of the optical changes can be explained at the anterior corneal surface level. Increase in posterior corneal curvature resulting from forward bulging of the cornea after LASIK has been reported [1,2].

Corneal ectasia is a serious complication after laser refractive surgery. This complication may progress to myopic regression, decreased visual acuity and corneal thinning which may eventually require corneal transplantation for visual rehabilitation. Because investigators suggest that changes in the posterior corneal shape are key to early recognition of corneal ectasia, it is important for clinicians to have an accurate method of studying posterior corneal elevation in post-LASIK patients [3,4].

In 1995, the Orbscan (Bausch & Lomb) was introduced. The original Orbscan used slit-scanning technology. A later model, the Orbscan II (Bausch & Lomb), combined slit scanning with a Placido disk device. The curvature and elevation of the anterior and posterior corneal surfaces can be assessed with the Orbscan II. The Pentacam uses a rotating Scheimpflug camera to measure the anterior and posterior corneal surfaces [5].

### Aim of work:

The aim of this study is to investigate the reliability of Sirius Pentacam and Orbscan IIz in evaluating posterior corneal surface changes after LASIK.

### Study design:

Prospective observational case series study was conducted on thirty eyes of 15 patients underwent LASIK for myopia with or without myopic astig-

matism at both the Ophthalmology Department of Tanta Universal Teaching Hospital and Nour El-Ein Hospital.

### Patients and Methods

This prospective observational case series study was conducted on thirty eyes of 15 patients underwent LASIK for myopia with or without myopic astigmatism at both the Ophthalmology Department of Tanta Universal Teaching Hospital and Nour El-Ein Hospital from April 2016 till October 2016.

#### Inclusion criteria:

- Patients with myopia less than  $-8.00D$  with or without myopic astigmatism less than  $-3.00D$ .
- Residual bed thickness not less than 300  $\mu m$  (calculated by subtracting the flap thickness and the calculated laser ablation depth for the particular refraction from the preoperative minimum corneal thickness).
- Age not less than 18 years.
- Refractive stability for at least 1 year before the procedure within  $\pm 0.5D$  over a period of 12 months.
- Pachymetry not less than 500  $\mu m$

#### Exclusion criteria:

- Keratoconus and forme-fruste keratoconus.
- Patients with abnormal front or back elevations of the cornea.
- Patients with too flat (less than  $+39.00D$ ) or too steep corneas (more than  $+48.00D$ ).
- Previous ocular or refractive surgery.
- Patients with corneal opacities or scars.
- Patients with lens opacities.
- Pregnant and lactating women.
- Severe Dry Eye Syndrome (DES).
- Chronic intraocular inflammations.
- Patients with other ocular disease; glaucoma, retinal detachments or optic nerve disease.

#### Preoperative evaluation:

All patients were subjected to:

##### 1- History:

Age-gender-previous history of herpetic keratitis-previous ocular or refractive surgery-previous use of contact lenses or eye drops-previous history of trauma.

##### 2- Examination:

- Slit-lamp examination of the anterior segment for:
  - A- Searching for signs of dry eye and tear film assessment (tear meniscus and breakup time), detailed examination of the cornea to rule out undiagnosed corneal dystrophies, allergic conjunctivitis, other pathologies of the conjunctiva and sclera.
  - B- Pupillary light reaction both direct and consensual and diameters in light and dim situations.
  - C- Intraocular pressure was measured using Goldmann applanation, to exclude glaucoma.
- External examination: to assess the eyelids, and orbit depth and possible obstacles for fitting the microkeratome.
- Ocular motility and assessment of phorias and tropias, confrontational visual field test.
- Manifest and cycloplegic refraction assessment.
- Measurement of the Uncorrected and Corrected Distance Visual Acuity (UDVA & CDVA).
- Fundus biomicroscopy: Detailed examination was made to reveal signs of diabetic retinopathy, maculopathy or optic nerve disease. Together with examining the periphery to exclude retinal detachment or peripheral retinal lesions, that may increase the risk of retinal detachment.
- Contact lens wearers were instructed to discontinue them for at least 2 weeks before the Pentacam and OrbscanIIz examination.
- Pre-operative corneal topography was a must to determine cases of keratoconus, KC suspect or irregular astigmatism for exclusion.

### Results

#### Statistical analysis:

Statistical analysis data was analyzed using SPSS (Statistical Package for Social Sciences) V16.0 (SPSS Inc., Chicago, USA). Qualitative data was presented as number and percent. Comparison between groups was done by Chi-Square test. Quantitative data was presented as mean  $\pm$  SD. Student *t*-test was used to compare between two groups.  $p < 0.05$  was considered to be statistically significant. The Coefficient of Repeatability (CR) can be calculated as 2 times the standard deviation of the differences between the two measurements ( $d_2$  and  $d_1$ ).

This prospective observational case series study was conducted on thirty eyes of 15 patients under-

went LASIK for myopia with or without myopic astigmatism to investigate the reliability of Sirius Pentacam and Orbscan IIz in evaluating posterior corneal surface changes after LASIK.

*Tomographic data:*

The mean elevation of the highest points on posterior corneal elevation maps after LASIK by Orbscan and Sirius was  $35.47 \pm 11.6 \mu\text{m}$  (range from 14  $\mu\text{m}$  to 49  $\mu\text{m}$ ) and  $9 \pm 2.9 \mu\text{m}$  (range from 5  $\mu\text{m}$  to 16  $\mu\text{m}$ ) respectively with no statistically significant difference between the values measured by the two methods ( $p$ -value 0.06).

Regarding the maximal highest point on posterior corneal elevation maps by Orbscan and Sirius was 50  $\mu\text{m}$  and 17  $\mu\text{m}$  respectively, the difference of means by Orbscan and Sirius was 14.53 and 8 respectively, the limits of agreement from -8.2 to 37.3 by Orbscan and 2.4 to 13.6 by Sirius respectively. The coefficient of repeatability was 36.20% by Orbscan and 16.60% Sirius, hence Orbscan is better than Sirius see (Table 2) and Figs. (1,2).

The mean value of the thinnest location after LASIK measured by Orbscan and Sirius was  $465.87 \pm 47.8 \mu\text{m}$  (range from 406  $\mu\text{m}$  to 472  $\mu\text{m}$ ) and  $465.37 \pm 41.7 \mu\text{m}$  (range from 430  $\mu\text{m}$  to 559  $\mu\text{m}$ ) respectively with no statistically significant difference between the values measured by the two methods see Fig. (3).

*Topographic data:*

The mean K1 after LASIK by Orbscan and Sirius was  $39.23 \pm 1.7\text{D}$  (range from 35.98D to

47.05D) and  $38.97 \pm 1.3\text{D}$  (range from 35.96D to 41.79D) respectively with no statistically significant difference between the values measured by the two methods see Fig. (4).

The mean K2 after LASIK by Orbscan and Sirius was  $40.46 \pm 1.4\text{D}$  (range from 37.10D to 43.00D) and  $40.38 \pm 1.4\text{D}$  (range from 36.99D to 43.72D) respectively with no statistically significant difference between the values measured by the two methods see Fig. (5).

The mean topographic cylinder after LASIK by Orbscan and Sirius was  $-0.50 \pm 0.3\text{D}$  (range from -1.40D to -0.2D) and  $-0.35 \pm 0.4\text{D}$  (range from -1.20D to 1.33D) respectively with no statistically significant difference between the values measured by the two methods.

The mean surface irregularity after LASIK by Orbscan within  $\pm 3\text{mm}$  zone  $1.3 \pm 0.3$  (range from 0.9 to 2). Surface irregularity has benefit to detect abnormal corneal topography with normal value about  $\pm 2$  within 3mm zone or  $\pm 2.5$  within 5mm zone. It is not present in Sirius but only Orbscan and this is one of advantages of Orbscan.

Table (1): Demographic data (age and sex).

Characteristic	Value
Age (Y):	
Mean $\pm$ SD	27.53 $\pm$ 3.3
Range	23 to 35
Sex:	
Male	9 (60%)
Female	6 (40%)

Table (2): Mean, standard deviation, difference of means, limits of agreement, coefficient of repeatability and  $p$ -value of highest points on posterior corneal elevation maps by Orbscan and Sirius.

Highest points on posterior corneal elevation maps	N	Mean	Std. deviation	Difference of means	Limits of agreement	Coefficient of repeatability	$p$ -value
Orbscan	30	35.47	11.6	14.53	-8.2 to 37.3	36.20%	0.06
Sirius	30	9	2.9	8	2.4 to 13.6	16.60%	

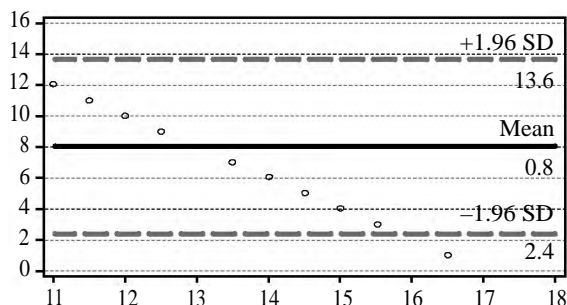


Fig. (1): Difference of means and limits of agreement of highest points on posterior corneal elevation maps by Sirius.

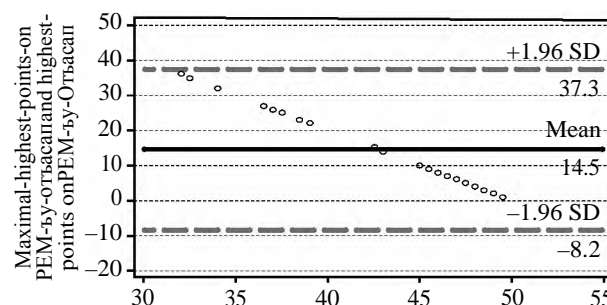


Fig. (2): Difference of means and limits of agreement of highest points on posterior corneal elevation maps by Orbscan.

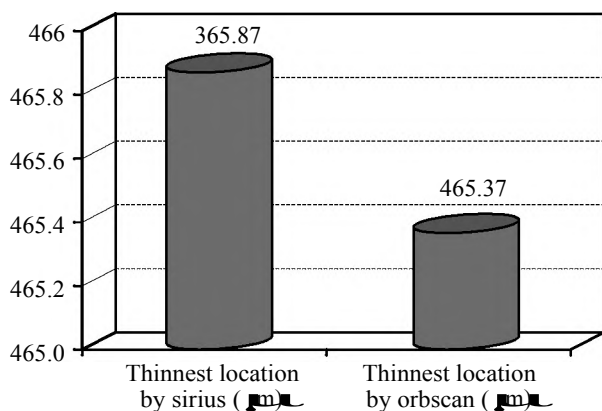


Fig. (3): Mean of thinnest location by Orbscan and Sirius.

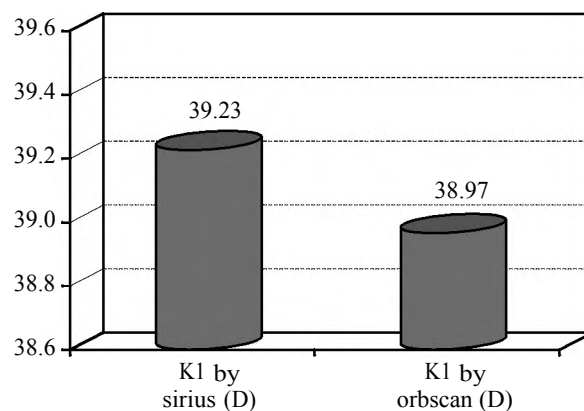


Fig. (4): Mean of K1 by Orbscan and Sirius.

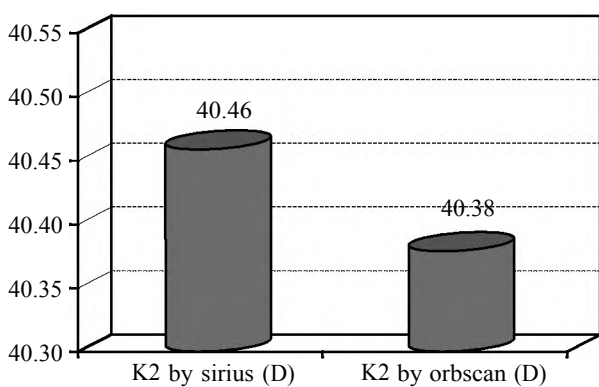


Fig. (5): Mean of K2 by Orbscan and Sirius.

### Discussion

Vicente D, et al. [7] defined the posterior corneal elevation by the maximum forward protrusion of the posterior cornea above the Best-Fit Sphere (BFS) in the central 4.0mm zone of topography (highest point on posterior elevation map) [7].

Hashemi & Mehravaran [6] compared between orbscan & pentacam in the accuracy of evaluation of posterior corneal changes after laser vision correction; they found that compared to the Pentacam, the Orbscan II yielded larger posterior elevation values before and after surgery and significant postoperative changes in Posterior Central Elevation (PCE) and Posterior Maximal Elevation (PME) [6].

Pérez-Escudero et al., [9] found that there is no evidence of surgically induced changes in the corneal posterior surface beyond 1 week after surgery. They concluded that Pentacam Scheimpflug system can be used reliably to assess changes in the posterior corneal radius of curvature after LASIK [9].

The results of our study disagreed with Berthold Seitz et al., [5] who concluded in their study on the

posterior corneal curvature after LASIK in myopic eyes using Orbscan system that the posterior corneal curvature changes suggested that mild “keratectasia” of the cornea may be common early after LASIK as they examined the cases 3 months post-operative, also they suggested that further studies with longer follow-up are required to clarify whether this biomechanical deformation is progressive and whether a residual stromal bed of >250 µm can completely prevent it. In that study they had a mean Residual Stromal Bed (RSB) after LASIK of  $280 \pm 42$  µm with some cases have RSB less than 250 µm which seems to be risky but in our study we had a RSB more than 300 µm while, Zhang & Wang [8] found that the displacement in the posterior corneal surface measured by Scheimpflug imaging (Pentacam) after LASIK was observed as time-dependent changes that protruded at an early stage but then returned to original levels 6 months after surgery [8].

Khyrat et al., [10] in their study for the changes that occur in the posterior corneal surface after Laser-Assisted In-Situ Keratomileusis (LASIK) for correction of myopia using Pentacam; found that post-LASIK changes of the posterior corneal surface affect mainly the vertical curvature, asphericity, and posterior corneal elevation. Fortunately, no case of post-LASIK ectasia was observed during the follow-up period of this study. Further studies are needed to document posterior corneal surface changes in patients with suspected post-LASIK ectasia [10].

Hernández-Quintela et al., [11] in their study to examine the histologic and ultrastructural features of human corneas after successful Laser In Situ Keratomileusis (LASIK); found that Permanent pathologic changes were present in all post-LASIK corneas. These changes were most prevalent in the lamellar interface wound. These changes along with other pathologic alterations in post-LASIK

corneas may change the functionality of the cornea after LASIK [11].

#### Conclusion:

There was no statistically significant difference between the values measured by Orbscan IIz and Sirius ( $p$ -value 0.06). The coefficient of repeatability was 36.20% by Orbscan and 16.60% Sirius, hence Orbscan is better than Sirius. Surface irregularity has benefit to detect abnormal corneal topography with normal value about  $\pm 2$  within 3mm zone or  $\pm 2.5$  within 5mm zone. It is not present in Sirius but only Orbscan and this is one of advantages of Orbscan.

#### Recommendations:

Further studies on the changes in the posterior cornea after correction of higher errors of refraction with LASIK and comparison them with preoperative posterior elevations by Orbscan IIz and Sirius.

#### References

- MARCOS S., BARBERO S., LLORENTE L., MERAYO and LLOVES J.: Optical Response to LASIK Surgery for myopia from total and corneal aberration measurements. Invest. Ophthalmol. Vis. Sci., 42: 3349-56, 2001.
- KAMIYA K., OSHIKA T., AMANO S., TAKAHASHI T., TOKUNAGA T. and MIYATA K.: Influence of excimer laser photorefractive keratectomy on the posterior corneal surface. J. Cataract. Refract. Surg., 26: 867-8, 2000.
- WANG Z., CHEN J. and YANG B.: Posterior corneal surface topographic changes after laser in situ keratomileusis are related to residual corneal bed thickness. Ophthalmology, 106: 406-9, 1999.
- TWA M.D., NICHOLS J.J., JOSLIN C.E., et al.: Characteristics of corneal ectasia after LASIK for myopia. Cornea 23: 447-57, 2004.
- SEITZ B., TORRES F., LANGENBUCHER A., et al.: Posterior corneal curvature changes after myopic laser in situ keratomileusis. Ophthalmology, 108: 666-72, 2001.
- HASHEMI H. and MEHRAVARAN S.: Corneal changes after laser refractive surgery for myopia: Comparison of Orbscan II and Pentacam findings. J. Cataract. Refract. Surg., 33 (5): 841-47, 2007.
- VICENTE D., CLINCH T.E. and KANG P.C.: Changes in posterior corneal elevation after laser in situ keratomileusis enhancement. J. Cataract. Refract. Surg., 34 (5): 785-8, 2008.
- ZHANG L. and WHANG Y.: The Shape of Posterior Corneal Surface in Normal, Post-LASIK and Post-epi-LASIK Eyes. Invest. Ophthalmol. Vis. Sci., 51 (7): 3468-75, 2010.
- PÉREZ-ESCUADERO A., DORRONSORO C., SAWIDES L., et al.: Minor influence of myopic laser in situ keratomileusis on the posterior corneal surface Invest. Ophthalmol. Vis. Sci., 50 (9): 4146-5, 2009.
- KHYRAT Y., ELSHAFEI A., ABDELRAHMAN R.M. and ABDELMALK N.H.: Assessment of the posterior corneal surface changes after LASIK treatment of myopia using Pentacam. J. Egypt Ophthalmol. Soc., 107: 10-5, 2014.
- HERNÁNDEZ-QUINTELA E., SAMAPUNPHONG S., KHAN B.F., et al.: Posterior corneal surface changes after refractive surgery. Ophthalmology, 108: 1415-22, 2001.

## المقارنة بين تغيرات السطح الخلفى للقرنية بعد الليزك بواسطة جهاز السيريز بنتاكام والأوربسكان ٢

يهدف الليزك إلى تغيير في شكل وقوة السطح الأمامى للقرنية. لا تؤثر عملية الليزك على السطح الخلفى للقرنية بشكل مباشر ومعظم التغييرات تحدث على مستوى السطح الأمامى للقرنية. زيادة إنحناء السطح الخلفى للقرنية ناتج من إنتفاخ القرنية للأمام بعد الليزك. يعد بروز القرنية الداخلى من أخطر المضاعفات بعد عملية تصحيح الإبصار بالليزر وتؤدي إلى ضعف الإبصار وترقق القرنية مما يتطلب ترقيع قرنية لتأهيل الإبصار. لأن الباحثين يقترحون بأن التغييرات لشكل السطح الخلفى للقرنية هي المفتاح لبدية التعرف على بروز القرنية فعلى الأطباء لمرآبة التغييرات إستخدام أدق وسيلة بالسطح الخلفى للقرنية للمرضى بعد عمليات الليزك. أدخل جهاز الأوربسكان عام ١٩٩٥م وإستخدام بتقنية المسح الشقى لقياس التغييرات الحادثة بالسطح الأمامى والخلفى للقرنية بينما يستخدم البنتاكام كاميرا دوراره لقياس السطح الأمامى والخلفى للقرنية. هدف البحث هو دراسة موثوقية جهاز السيريز بنتاكام والأوربسكان ٢ فى تقييم تغييرات السطح الخلفى للقرنية بعد الليزك. تشمل هذه الدراسة ٣٠ عين لخمسة عشرة مريض فى قسم الرمد بمستشفى طنطا التعليمى العالمى ومستشفى نور العين بعد إجرائهم لعملية الليزك لتصحيح قصر النظر لديهم من شهر أبريل ٢٠١٦ إلى شهر أكتوبر ٢٠١٦. لا يوجد إختلافات بين الجهازين فى قياس التغيرات فى السطح الخلفى للقرنية بعد الليزك وأن الأوربسكان له مزايا متفوقة على السيريز وهى وجود قراءه لعدم إنتظام سطح القرنية والتي تدل على وجود بروز لسطح القرنية والقيمة الطبيعية لها  $\pm 2$  داخل ٣مم أو  $\pm 2.5$  داخل ٥مم من الأوربسكان والميزة الأخرى أن المعامل التكرارى للأوربسكان أعلى من السيريز.