

# HISTOMORPHOMETRIC ANALYSIS OF BONE REGENERATION AFTER USE OF PROPOLIS VERSUS NANO BONE GRAFT MATERIALS FOR THE MANAGEMENT OF CLASS II FURCATION DEFECTS IN DOGS

Amr A. Zohery<sup>1</sup>BDS, Zubaida M. Nour<sup>4</sup> PhD, Samia S. Abd El Rehim<sup>3</sup> PhD,  
Marwa I. Mady<sup>2</sup> PhD

## ABSTRACT

**INTRODUCTION:** Nanotechnology has been greatly utilized for bone regeneration strategies. It helps overcome some of the current limitations associated with bone regeneration methods Propolis is a natural substance made by the honeybee, it has effective antioxidant, antimicrobial, and anti-inflammatory effects. Moreover, it has multiple biological effects including improvement of wound healing and bone regeneration.

**OBJECTIVES:** comparison of the effectiveness of NanoBone graft and propolis material on the inter-radicular bone regeneration in Mongrel dogs.

**MATERIALS AND METHODS:** A split mouth design was carried out using the third and fourth mandibular premolars of 3 healthy mongrel dogs. A total of 12 grade II furcation defects were surgically created. The defects in the right side were treated with NanoBone graft and then a collagen membrane was used to cover the defects. In the left side the defects were treated with propolis and then covered with collagen membrane. The dogs were sacrificed after 4 weeks. Segments of the jaw bone containing the defects were then dissected out and prepared for histological evaluation.

**RESULTS:** Both percentage of bone fill and percentage of bone surface area in defects treated with propolis powder were higher than those in NanoBone-filled defects.

**CONCLUSIONS:** Both propolis and NanoBone graft materials have bone regenerative effects with higher ability of propolis to regenerate bone.

**KEYWORDS:** Regeneration, Furcation, NanoBone, Bone graft, Propolis, Antioxidant.

- 
- 1- Instructor at Oral Medicine, Periodontology, Oral Diagnosis and Radiology Department, Faculty of Dentistry, Alexandria University, Alexandria, Egypt.
  - 2- Professor of Oral Medicine, Periodontology, Oral Diagnosis and Radiology Department, Faculty of Dentistry, Alexandria University, Alexandria, Egypt.
  - 3- Professor of Oral Biology, Faculty of Dentistry, Alexandria University, Alexandria, Egypt.
  - 4- Lecturer of Oral Medicine, Periodontology, Oral Diagnosis and Radiology Department, Faculty of Dentistry, Alexandria University, Alexandria, Egypt.

## INTRODUCTION

Periodontitis is one of the most common diseases encountered by humans affecting about 10-15% of most populations (1). It is a set of inflammatory diseases secondary to infection by periodontal bacteria. Periodontitis affects the periodontium that surrounds and supports the teeth, resulting in progressive loss of connective tissue attachment and supporting alveolar bone leading to formation of osseous defects or deformities (2).

Such periodontal bony defects must be treated to avoid interference with pocket elimination and recurrence of the disease (3). One of the main objectives of periodontal therapy is regeneration of the periodontium, including restoration of the alveolar bone defects, lost cementum and lost periodontal ligament caused by the disease (4, 5).

Periodontal regeneration can be achieved by different approaches, including the use of bone grafts, guided tissue regeneration, and growth factors (6). Guided tissue regeneration (GTR), imply the use of barrier membranes to delay the apical migration of the gingival epithelium. Thus allowing the cells derived from the periodontal ligament to repopulate the space adjacent to the denuded root surface (5). To support these barrier membranes, preventing their collapse, and promote bone formation, GTR has often been combined with the placement of bone grafts.

Different types of bone grafts are utilized in bone grafting procedures; these include autogenous bone grafts, allografts, xenografts, and alloplasts. One of the most widely used non-bone grafts are synthetic alloplastic grafts especially bioceramics such as hydroxyapatite and  $\beta$ -tricalciumphosphate (7). Alloplasts overcome the limitations of other bone grafts such as donor site morbidity of autogenous grafts (8) and the possibility of disease transmission of allografts (9).

However, the high sintering temperature during the processing of bioceramics negatively influences their osteoconductivity, delays their resorption at the implantation site and may even induce chronic inflammatory processes (10). New nanostructured materials could overcome these disadvantages.

Nanotechnology has emerged to be one of the most powerful engineering approaches in the past half century. Nanotechnology represents the science that manipulates atoms and molecules at the nanometer scale. One amazing application of nanotechnology is to synthesize nanomaterials that mimic the structure of natural tissues providing the proper extracellular environment for tissue repair and regeneration (11).

NanoBone graft material is a recently developed and approved granular material used in bone regeneration; it consists of synthetic nanocrystalline hydroxy-apatite

embedded in a silica gel matrix mimicking the structure of normal bone tissue (12). NanoBone graft possesses several properties that enhance bone regeneration. It has similar architecture to normal bone which enhances blood circulation within the NanoBone graft (13). The nano-roughness on the surface of the graft is the same as that of normal bone which provides a better medium for osteoblasts to grow and function (14). It also has a large surface area to volume ratio that increases adsorption of proteins such as fibronectin and vitronectin which mediate osteoblastic adhesion. So unlike other synthetic bone substitutes, NanoBone graft has osseointegrative and osseopromotive properties (15).

Another recent treatment approach used for bone regeneration is the use of antioxidant therapy. Antioxidant therapy affects bone metabolism via inhibition of osteoclastic activity and promotion of osteoblastic activity (16). Numerous studies have demonstrated a correlation between oxidative stress and bone metabolism. One of the most powerful natural antioxidants is Propolis which is a sticky resinous substance made by the honeybee. Over 300 biologically active substances have been isolated from propolis, the most important among them are flavonoids, phenolics and aromatic compounds. One of the main phenolic compounds found in propolis is caffeic acid phenethyl ester (CAPE) (17). CAPE and Flavonoids are known to be the most effective substances responsible for most of the biological activities in propolis (18).

Besides its antioxidant properties; propolis possesses other various biological activities. It has been reported to promote wound healing (19). It also possesses antibacterial (20) and anti-inflammatory properties (21) which have a beneficial effect on bone regeneration. Thus propolis powder as a natural product having multiple biological effects can be used to enhance bone regeneration.

From all of the above information, both NanoBone graft and propolis powder can be used in bone regeneration. The aim of this study is to compare the effect of both materials on inter-radicular bone regeneration.

## MATERIALS AND METHODS

### A) Material

#### Study Animals

Three adult male Mongrel dogs, about 18-24 months old, weighing approximately 18-24 Kg were selected for this study. The animals were adapted to the housing conditions during the study period.

#### Study design:

A split mouth study design was conducted.

#### Grafting materials:

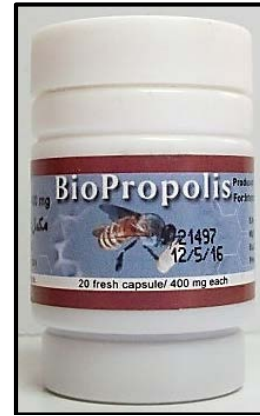
1- Nano-Bone grafting material (NanoBone®) (ARTOSS GmbH Company, Rostock, Germany):

A synthetic bone graft composed of nanocrystalline hydroxyapatite embedded in a matrix of silica gel (approx. 24% by weight) which is porous down to the nanometer size range.

2 - Propolis powder (Sigma Pharmaceutical Industries, Cairo Governorate, Egypt):

It was obtained by using the content of BioPropolis capsules. (1 capsule mixed with 2 drops saline).

Each capsule contains 400mg pure Egyptian propolis. (Figure 1)



**Figure (1):** BioPropolis which is the source of propolis used in the study.

### GTR barrier membrane

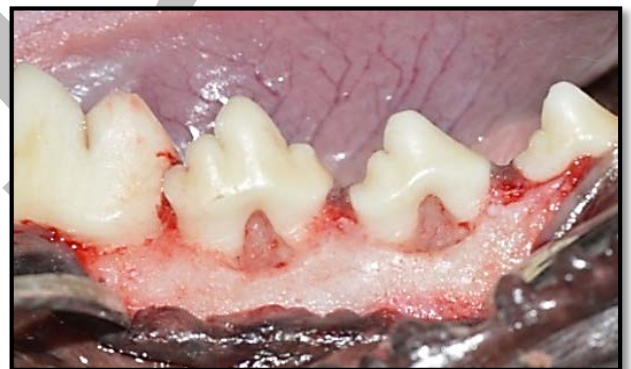
Collagen Membrane (25x25x0.2mm) (BioTECK Company, Italy)

Type I equine collagen (from Achilles tendon).

### B) Methods

#### Surgical creation of the defects

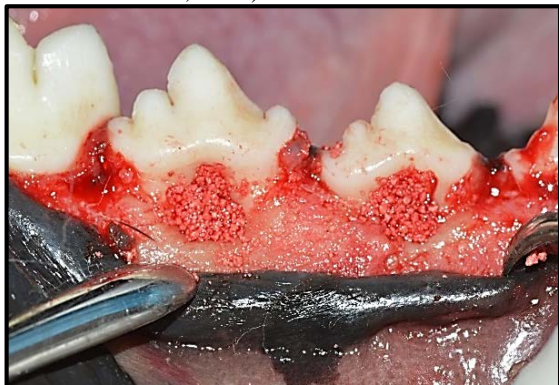- All procedures were performed under general anesthesia by intramuscular injection of a combination of 0.1ml ketamine hydrochloride (Alfas an Inc., Utrecht, Holland) and 0.05 ml xylazine hydrochloride (Bayer Inc., Toronto, ON, Canada) for each 100 gm body weight
- Sulcular incisions were performed, followed by the reflection of mucoperiosteal flaps buccally on the mandibular third (P<sub>3</sub>) and fourth (P<sub>4</sub>) premolars in the right and left jaw quadrants.
- Grade II critical sized furcation defects of about 4mm horizontally and 5 mm vertically were created in the mandibular P3 and P4 of each dog (22). (Figure 2)



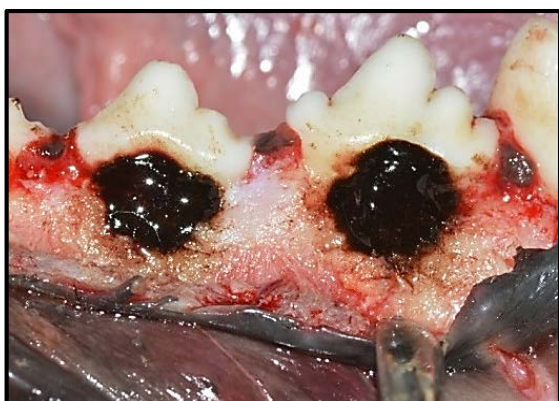**Figure (2):** Photograph showing the surgically created critical sized class II furcation defects in P3 and P4 of dogs.

- Two reference notches were made on the mesial and distal root surfaces at the base of each defect. These notches acted as reference points in the histologic examination and histomorphometric measurements.
- Root planing and conditioning were done.
- A split mouth design was conducted in all dogs. On both sides; GTR procedures were carried out. On the right sides, the created defects were filled with NanoBone graft material and then covered by collagen membranes. While on the left sides; the created defects were filled with Propolis powder then covered by collagen membranes. (Figures 3&4)

- The flaps were relocated in their original positions and sutured using 2-0 silk sutures (Ethicon silk suture, Johnson & Jhonson, USA).



**Figure (3):** Photograph showing NanoBone grafting material placed in the created furcation defects of P3 and P4 on the lower right side.



**Figure (4):** Photograph showing propolis material placed in the created furcation defects of P3 and P4 on the lower left side.

#### Postoperative Care

The animals received:

- Appropriate antibiotic (Ampicillin, Eipico, Egypt) that were given intramuscularly in the first day, and then mixed with dogs' food for seven days.
- Analgesics (Brufen 600 mg Abbot GmbH, Germany) were given intravenously in the first day.
- Dogs were fed on soft diet in the postoperative period to reduce the possibility of local trauma to the operating sites.

#### Euthanization of animals

After one month, the dogs were euthanized with intracardiac injection of xylazine+ ketamine, following successful euthanasia, the carcass were decapitated and the lower jaws were dissected out then bisected into two halves. Then the lower jaws were immersed in 10% neutral buffered formalin for one day and then segments containing the operated teeth were dissected out, left in the same percentage of neutral formalin (10%) for 4 days. After that they were processed and prepared to obtain mesiodistal 5 microns' thick sections. Finally, the sections were stained with H&E stain to be examined with the light microscope.

#### Histomorphometric analysis of the regenerative process outcome

On the histological sections measurements were performed using (Image J) software (23, 24) in order to calculate the following parameters:

- 1- Mean percentage of bone fill in the created furcation defects.

- 2- Mean percentage of the newly formed bone surface area.

Three sections of tissue from different three standardized depths were used to choose from for quantification of each block. One photograph was taken from the best of each three sections using the same magnification power for all photographs and containing the inter-radicular region between the two roots of the tooth, parts of PDL and parts of the adjacent two roots. Since six tissue blocks of specimens were made for each group, a total number of 18 sections for each group were obtained and photographed for histomorphometric analysis.

#### Steps of measuring the mean percentage of bone fill in the furcation area:

- 1- A straight line was drawn on each photograph from the beginning of the furcation area at the fornix till a line at the most apical end of the created defects marked by the notches made on the roots.

- 2- This line was drawn to set a scale of 5 mm on the photograph converting image pixels into millimeters.

- 3- Another straight line was drawn from the most coronal end of the formed inter-radicular bone till the apical line at the notches to measure the height of newly formed bone.

- 4- The height of newly formed inter-radicular bone was divided by the total vertical length of furcation defect to measure the percentage of bone fill of the furcation defect.

#### Steps of measuring the formed bone surface area (25):

- 1- A rectangle with standardized dimensions (2 x 1.5 cm) was drawn on each photograph containing the inter-radicular regenerated bone, parts of the two adjacent roots and PDL tissues to be measured using the image J program.

- 2- The total surface area occupied by the bone marrow, parts of the PDL and adjacent two roots of the tooth were selected and subtracted from the total surface area of the whole rectangle to measure the newly formed bone surface area.

#### STATISTICAL ANALYSIS

Mean values for each variable were calculated for each group. Differences were analyzed using t-test.

#### RESULTS

##### Clinical Observations

All animals tolerated the surgical procedures well. Following the surgical procedures done in the two study groups, healing was uneventful and no adverse reactions such as postoperative infection were noted following surgery in the treated teeth of the animals in both groups.

##### Histomorphometric results

Data obtained from the histomorphometric analysis regarding the percentages of bone fill and bone surface area showed comparable results in both groups with overall higher values for the propolis group.

After one month, the mean percentage of bone fill in the furcation area in defects treated with propolis was  $86.79 \pm 5.41\%$  which was higher than that in NanoBone group ( $82.48 \pm 3.04\%$ ). The data revealed a statistically significant difference between both groups ( $p=0.007$ ). [Table 1] (Figure 5).

However, for the mean percentage of bone surface area the values for propolis group was slightly higher than that for NanoBone group but without statistical significance ( $p>0.05$ ). After one month, the mean percentage of bone

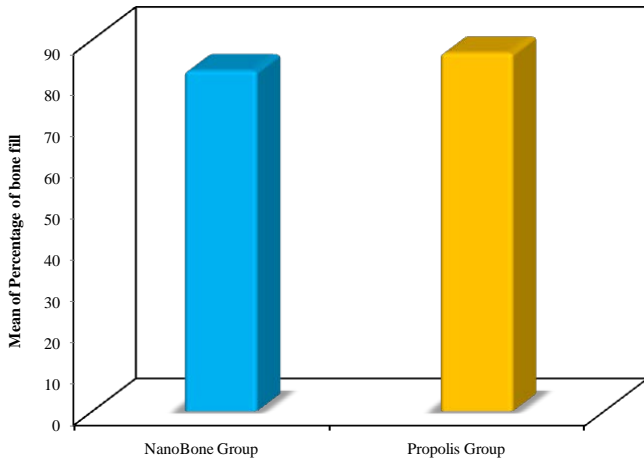


surface area in propolis group was  $75.1 \pm 5.95\%$  compared to  $74.8 \pm 5.9\%$  for NanoBone group. [Table 2] (Figure 6).

**Table (1):** Comparison between the two studied groups according to the percentage of bone fill after one month.

	NanoBone Group (n= 18)	Propolis Group (n= 18)	t	p
<b>Percentage of bone fill</b>				
Min. – Max.	78.2 – 88.4	77.76 – 93.58		
Mean $\pm$ SD.	$82.48 \pm 3.04$	$86.79 \pm 5.41$	2.947*	0.007*
Median	82.0	87.65		

t, p: t and p values for Student t-test  
 \*: Statistically significant at  $p \leq 0.05$

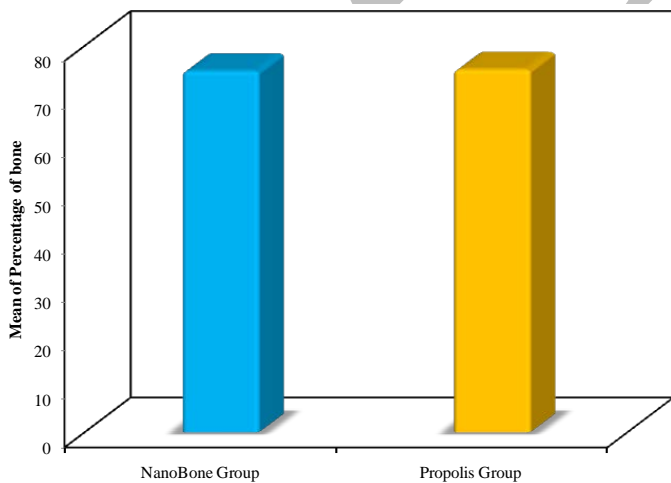


**Figure (5):** Bar representation comparing between the two studied groups according to the percentage of bone fill after one month.

**Table (2):** Comparison between the two studied groups according to the percentage of bone surface area after one month.

	NanoBone Group (n= 18)	Propolis Group (n= 18)	t	p
<b>%Percentage of bone</b>				
Min. – Max.	64.03 – 88.3	62.6 – 85.12		
Mean $\pm$ SD.	$74.8 \pm 5.9$	$75.1 \pm 5.95$	0.164	0.871
Median	74.08	76.97		

t, p: t and p values for Student t-test



**Figure (6):** Bar representation comparing between the two studied groups according to the percentage of bone surface area after one month

**DISCUSSION**

Management of furcation defects presents one of the greatest challenges faced in the management of periodontal diseases (26). The ultimate goal of periodontal therapy is periodontal regeneration which means restoration of the periodontium to its pre-disease state renewing the lost alveolar bone, cementum and PDL (5). GTR approach combined with grafting material was utilized for this study as it is considered the most predictable way to achieve periodontal tissue regeneration. Combining bone substitute with the membrane prevents the barrier membrane from collapse and thus ensures space maintenance (27).

Owing to the limitations of most of the current bone grafting materials, it was necessary to search for alternative products. Natural medicine products offer natural and cost-effective intervention to modulate the course of many chronic diseases and help regenerating many living tissues. Propolis is considered one of the natural products proven to have bone regenerative effect.

Although the effect of propolis on bone tissue healing and regeneration has been studied intensely, to the best of our knowledge till date, this study is the first to topically use propolis as a bone replacement material in periodontal (alveolar) bone defects. This experimental trial evaluates histomorphometrically the bone regenerative potential of propolis with regards to one of the synthetic bone grafting materials experimentally and clinically proven effective (NanoBone).

The histomorphometric analysis of the two groups revealed the high bone regenerative potential of both NanoBone graft and propolis with nearly comparable results. This was represented by high values of percentages of bone surface area and bone fill in the furcation defects. The mean values of surface area of the inter-radicular bone after one month were  $75.10 \pm 5.95\%$  &  $74.78 \pm 5.88\%$  for propolis and NanoBone groups respectively. These values shown in the current study exceed that reported by Gheith. et al. (25) who measured the percentage of bone surface area in dogs' class II furcation defects. In their study after one month, the mean percentage of bone surface area in the study group treated by  $\beta$ -tricalcium phosphate graft with modified perforated membrane was  $50.57 \pm 7.66\%$  while that of the control group treated with  $\beta$ -tricalcium phosphate graft and occlusive collagen membrane was  $43.11 \pm 4.98\%$ . This positive difference in the current study might be due to the greater regenerative effect of both materials used.

The mean percentages of bone fill at the furcation defects in the present study was  $86.79 \pm 5.41\%$  &  $82.48 \pm 3.04\%$  in propolis and NanoBone groups in order. These values overweigh that reported by Shahabuei et al. (28) in a study examining the effect of Bio-Oss graft with platelet- rich plasma (PRP) on bone regeneration of dog class II furcation defects. They found around  $60\%$  percentage of bone fill in the furcation defects after three months of treatment. These results show up the superior effects of propolis and NanoBone in bone regeneration more than the above mentioned materials.

The bone regenerative ability of NanoBone graft can be attributed to its inherent features. The manufacturing procedures of NanoBone depending on the sol-gel technique resulting in numerous interconnecting pores of several nanometers to micrometer size ranges provide an excellent osteoconductive and osteoinductive properties of the material (29). The proven high osteogenic ability of

NanoBone graft in the current study agree with many experimental and clinical studies done on NanoBone graft (15, 30, 31). NanoBone graft was found to enhance osteoblastic proliferation and differentiation through the nano-roughness and enhanced adsorption of multiple bone morphogenetic proteins such as osteocalcin (OC) and osteopontin (OP) (12, 30).

Concerning propolis, there are several mechanisms that can mediate its high bone regenerative potential. The antioxidant activity of propolis aids its osteogenic ability by inhibiting osteoclastic activity and promoting osteoblastic activity (32). The anti-oxidant role of propolis and its effect on bone healing was confirmed by Ahmet Guney et al (32). It was found that propolis increases a lot of bone formation markers as osteocalcin (OC), osteopontin (OP), alkaline phosphatase (AP), osteoprotegerin (OPG) and decrease the bone resorption ones as N-telepeptide of type 1 collagen and RANKL (33). Propolis phenolics were reported to modulate the accumulation of type I and III collagen and enhance the cumulation of chondroitin sulphate and hyaluronic acid which help bone to regenerate (34). Another mechanism that strongly elucidates the tissue or bone reparative/regenerative properties of propolis is that it contains many compounds which act thoroughly to enhance cell proliferation through the activation of ATPase and tetrasol reductase enzymes. This increases the mitotic index facilitating tissue regeneration and reducing the healing period (35).

From all of the above information, propolis can be used safely as a bone substitute. However, further studies should be conducted to evaluate the use of propolis as a bone replacement material in other periodontal osseous defects or around dental implants.

## CONCLUSIONS

Within the limitations of this experimental study, it could be concluded that:

- 1- Both propolis and NanoBone graft materials possess exceptionally high bone regenerative capacity.
- 2- Propolis has proved itself as a successful natural and cost-effective bone replacement material that can be used safely in bone regeneration of furcation defects.

## CONFLICT OF INTEREST

The authors declare that they have no conflicts of interest.

## REFERENCES

1. Papapanou P. Epidemiology of periodontal diseases: an update. *Journal of the International Academy of Periodontology*. 1999;1:110-6.
2. Petersen PE. The World Oral Health Report 2003: continuous improvement of oral health in the 21st century—the approach of the WHO Global Oral Health Programme. *Community Dentistry and oral epidemiology*. 2003;31:3-24.
3. Lindhe J, Karring T, Lang NP. *Clinical periodontology and implant dentistry*: Blackwell Munksgaard Copenhagen; 2003.
4. Kim CS, Choi SH, Cho KS, Chai JK, Wikesjö UM, Kim CK. Periodontal healing in one-wall intra-bony defects in dogs following implantation of autogenous bone or a coral-derived biomaterial. *Journal of clinical periodontology*. 2005;32:583-9.
5. Ivanovski S, Li H, Daley T, Bartold P. An immunohistochemical study of matrix molecules associated with barrier membrane-mediated periodontal wound healing. *Journal of periodontal research*. 2000;35:115-26.
6. Kalra N, Guruprasad C, Naik S, Pradeep A. Stem cells: a novel approach to periodontal regeneration. *AOSR*. 2011;1:116-21.
7. Al-Sanabani JS, Madfa AA, Al-Sanabani FA. Application of calcium phosphate materials in dentistry. *International journal of biomaterials*. 2013;2013.
8. Younger EM, Chapman MW. Morbidity at bone graft donor sites. *Journal of orthopaedic trauma*. 1989;3:192-5.
9. Garrido CA, Lobo SE, Turibio FM, LeGeros RZ. Biphasic calcium phosphate bioceramics for orthopaedic reconstructions: clinical outcomes. *International journal of biomaterials*. 2011;2011.
10. Abukawa H, Papadaki M, Abulikemu M, Leaf J, Vacanti JP, Kaban LB, et al. The engineering of craniofacial tissues in the laboratory: a review of biomaterials for scaffolds and implant coatings. *Dental Clinics of North America*. 2006;50:205-16.
11. Kubinová Š, Syková E. Nanotechnologies in regenerative medicine. *Minimally Invasive Therapy & Allied Technologies*. 2010;19:144-56.
12. Gerber T, Holzhüter G, Götz W, Bienengraber V, Henkel K-O, Rumpel E. Nanostructuring of biomaterials—a pathway to bone grafting substitute. *European Journal of Trauma*. 2006;32:132-40.
13. Gerike W, Bienengraber V, Henkel K, Bayerlein T, Proff P, Gedrange T, et al. The manufacture of synthetic non-sintered and degradable bone grafting substitutes. *FOLIA MORPHOLOGICA-WARSZAWA-ENGLISH EDITION*-. 2006;65:54.
14. Webster TJ, Ergun C, Doremus RH, Siegel RW, Bizios R. Enhanced functions of osteoblasts on nanophase ceramics. *Biomaterials*. 2000;21:1803-10.
15. Gáštý W, Lenz S, Reichert C, Henkel K, Pernicka L, Gundlach K, et al. A preliminary study in osteoinduction by a nano-crystalline hydroxyapatite in the mini pig. *Folia Histochem Cytobiol*. 2011;48:589-98.
16. Toker H, Ozdemir H, Eren K, Ozer H, Sahin G. N-acetylcysteine, a thiol antioxidant, decreases alveolar bone loss in experimental periodontitis in rats. *Journal of periodontology*. 2009;80:672-8.
17. Bai X-c, Lu D, Bai J, Zheng H, Ke Z-y, Li X-m, et al. Oxidative stress inhibits osteoblastic differentiation of bone cells by ERK and NF-κB. *Biochemical and biophysical research communications*. 2004;314:197-207.
18. Wang X, Stavchansky S, Bowman PD, Kerwin SM. Cytoprotective effect of caffeic acid phenethyl ester (CAPE) and catechol ring-fluorinated CAPE derivatives against menadione-induced oxidative stress in human endothelial cells. *Bioorganic & medicinal chemistry*. 2006;14:4879-87.
19. Celik S, Gorur S, Aslantas O, Erdogan S, Ocak S, Hakverdi S. Caffeic acid phenethyl ester suppresses oxidative stress in *Escherichia coli*-induced pyelonephritis in rats. *Molecular and cellular biochemistry*. 2007;297:131-8.
20. Koru O, Toksoy F, Acikel CH, Tunca YM, Baysallar M, Guclu AU, et al. In vitro antimicrobial activity of propolis samples from different geographical origins against certain oral pathogens. *Anaerobe*. 2007;13:140-5.

21. Blonska M, Bronikowska J, Pietsz G, Czuba Z, Scheller S, Krol W. Effects of ethanol extract of propolis (EEP) and its flavones on inducible gene expression in J774A. 1 macrophages. *Journal of Ethnopharmacology*. 2004;91:25-30.
22. Struillou X, Boutigny H, Badran Z, Fellah BH, Gauthier O, Sourice S, et al. Treatment of periodontal defects in dogs using an injectable composite hydrogel/biphasic calcium phosphate. *Journal of Materials Science: Materials in Medicine*. 2011;22:1707-17.
23. Abràmoff MD, Magalhães PJ, Ram SJ. Image processing with ImageJ. *Biophotonics international*. 2004;11:36-42.
24. Ferreira T, Rasband W. ImageJ user guide. IJ1 46r Natl Inst Health, Bethesda. 2012.
25. Ghaitth HM, Lotfy M, Soliman S, Fahmy RA. Quantitative Analysis of Interradicular Bone Regeneration after Use of Modified Perforated Collagen Membrane versus Occlusive Membrane in the Management of Grade II Furcation Defects in Dogs. 2016;5:402-7.
26. Desantis M, Murphy KG. The role of resective periodontal surgery in the treatment of furcation defects. *Periodontology 2000*. 2000;22:154-68.
27. Sculean A, Nikolidakis D, Schwarz F. Regeneration of periodontal tissues: combinations of barrier membranes and grafting materials—biological foundation and preclinical evidence: a systematic review. *Journal of clinical periodontology*. 2008;35:106-16.
28. Shahabuei M, Dabbagh E, Adibrad M, Vaziri S, Eslami B, Afshar SK. The Effect of Platelet-rich Plasma (PRP) and Bio-oss on Bone Regeneration in Furcation Class II Defects: A Histologic and Histomorphometric Study in Dogs. *Journal of Dentistry, Shiraz University of Medical Sciences*. 2011;12:1-10.
29. Götz W, Gerber T, Michel B, Lossdörfer S, Henkel KO, Heinemann F. Immunohistochemical characterization of nanocrystalline hydroxyapatite silica gel (NanoBone®) osteogenesis: a study on biopsies from human jaws. *Clinical oral implants research*. 2008;19:1016-26.
30. Ghanaati S, Barbeck M, Willershausen I, Thimm B, Stuebinger S, Korzinskas T, et al. Nanocrystalline hydroxyapatite bone substitute leads to sufficient bone tissue formation already after 3 months: histological and histomorphometrical analysis 3 and 6 months following human sinus cavity augmentation. *Clinical implant dentistry and related research*. 2013;15:883-92.
31. Ganz C, Xu W, Holzhüter G, Götz W, Vollmar B, Gerber T, editors. Comparison of bone substitutes in a tibia defect model in Wistar-rats. *Key Engineering Materials*; 2012.
32. Guney A, Karaman I, Oner M, Yerer MB. Effects of propolis on fracture healing: an experimental study. *Phytotherapy Research*. 2011;25:1648-52.
33. Al-Saeed HF, Mohamed NY. The Possible Therapeutic Effects of Propolis on Osteoporosis in Diabetic Male Rats. *Nature and Science* 13:136-40.
34. Olczyk P, Wisowski G, Komosinska-Vassev K, Stojko J, Klimek K, Olczyk M, et al. Propolis modifies collagen types I and III accumulation in the matrix of burnt tissue. *Evidence-Based Complementary and Alternative Medicine*. 2013;2013.
35. Kurek-Górecka A, Rzepecka-Stojko A, Górecki M, Stojko J, Sosada M, Świerczek-Zięba G. Structure and antioxidant activity of polyphenols derived from propolis. *Molecules*. 2013;19:78-101.