

EFFECT OF VITAMIN E ON THE PROGRESSION OF RENAL ISCHEMIA REPERFUSION INJURY IN FEMALE RATS

By

**Nehal M. B. Gamil, Soha M.Y. Mohamed, Doaa A. Abou-Bakr
and Basant S. M. Elsaid**

Department of Physiology, Faculty of Medicine, Ain Shams University

ABSTRACT

Background: Acute kidney injury (AKI) is a common worldwide disorder that is associated with high morbidity and mortality. Its pathophysiology is complex including a triad of oxidative tissue damage, inflammation and activation of clotting cascade.

Objective: Investigating the outcome of vitamin E acetate administration immediately after the induction of renal ischemia/reperfusion injury on its progression.

Materials and Methods: The present study was carried out on 48 adult female Wister rats, weighing 185-250 grams, randomly allocated into the following 3 groups: Sham-operated group (SHAM; n=18), renal ischemia/reperfusion injury group (RIR; n=20), and renal ischemia/reperfusion injury group treated with Vitamin E Acetate (RIR_{vit}; n=10). Rats were subjected to measurement of initial and final body weights (IBW, FBW), absolute and relative kidney weights (AKW, RKW), serum level of urea and creatinine as renal function tests, prothrombin time (PT), activated partial thromboplastin time (APTT) and fibrin degradation products (FDPs) as markers of blood coagulation, C-reactive protein (CRP) as an inflammatory marker, as well as plasma and renal tissue malondialdehyde (MDA_p, MDA_t) as oxidative stress markers, in addition to histopathological study of the kidney tissue.

* The majority of preclinical studies in AKI were performed in males (Skrypyk et al., 2016), so we focused to study the effect of RIR in female rats independent of estrus cycle.

Results: RIR rat group showed significant increase in AKW, RKW, as well as serum levels of urea and creatinine compared to sham operated group, but there was no significant change in their PT, APTT, FDPs, CRP, MDA_p, and MDA_t compared to the sham operated group. RIR_{vit} rat group exhibited insignificant changes in their AKW, RKW, serum urea, creatinine, PT, APTT, FDPs, CRP, MDA_p, and MDA_t compared to RIR. Histopathological study of RIR rat kidneys showed glomerular congestion with periglomerular edema and atrophy of some glomeruli as well as cystic tubular dilation with eosinophilic cast with tubular epithelial necrobiosis, and these changes were not improved by vitamin E treatment in RIR_{vit} rat kidneys.

Conclusion: Vitamin E acetate administration in a single dose of 1000 mg/kg B.W. immediately after induction of RIR could not interfere with the progression of AKI as proved by the non significant changes in kidney function tests and histopathological picture.

Key words: AKI, RIR, blood coagulation, oxidative stress, inflammation and Vitamin E.

INTRODUCTION

Ischemia/reperfusion (IR) represents the most frequent cause of AKI (Arfian et al., 2012). The kidney is vulnerable to IR

injury during a number of clinically important conditions including hypotension, sepsis and surgical procedures such as partial nephrectomy, cardiac bypass

surgery, as well as during kidney transplantation (Simmons *et al.*, 2008). Renal ischemia reperfusion (RIR) indicates restriction of blood supply to the kidney followed by restoration of blood flow and reoxygenation (Malek and Nematbakhsh, 2015). This could cause significant tissue damage and loss of cell viability and functionality due to necrotic, necroptotic, apoptotic, and autophagic mechanisms (Kalogeris *et al.*, 2012). Oxidative tissue damage, inflammation and activation of clotting cascade are closely related pathophysiological pathways that form a triad that establishes a fastened positive feedback mechanism that ends by terminating the life of the patient (Pet?j?, 2011 and Sureshbabu *et al.*, 2015). Being the cornerstone of AKI pathophysiology, oxidative stress was targeted by antioxidants to disrupt the positive feedback interactions between oxidative damage, inflammation and coagulation (Duffy *et al.*, 2014). Thus, it was intriguing to investigate the outcome of vitamin E acetate administration immediately after the induction of ischemia/reperfusion kidney injury.

MATERIALS AND METHODS

The present study was approved by the Ethics Committee under Federal Wide Assurance No. FWA 000017585

Experimental animals: This study was carried out on 48 adult female Wister rats, weighing 185-250 grams. Rats were purchased from the Modern Veterinary Office, Al-Haram, Giza, and were maintained in the Physiology Department Animal House, Faculty of Medicine, Ain Shams University under standard conditions of boarding at room temperature. Rats were kept in plastic

cages of 39cm x29cm x18cm dimensions (3-5 rats /cage) for 10 days for acclimation. Rats were fed ad libitum the regular rat chow. Meals were introduced daily at 8 am, with free access to water.

Experimental protocol: After the acclimation period, rats were allocated into the following groups: **Group I: Sham-operated rat group (SHAM; n=18):** These rats underwent surgical procedure identical to those of renal ischemia/reperfusion group (RIR) except that clamps were not applied to the renal pedicle. These rats received a single intraperitoneal (i.p.) injection of sesame oil. **Group II: Bilateral renal ischemia/reperfusion injury rat group (RIR; n=20):** These rats' renal pedicles were clamped bilaterally for 45 min, then reperused and immediately received a single i.p. injection of sesame oil according to Malek and Nematbakhsh (2014). **Group III: Renal ischemia/reperfusion injury rat group treated with Vitamin E Acetate (RIR_{ttt}; n=10):** These rats' renal pedicles were clamped bilaterally for 45 min, then reperused and immediately received a single i.p. injection of vitamin E acetate dissolved in sesame oil in a dose of 1000 mg/kg B.W. according to Naz?ro?lu *et al.* (2004), immediately after induction of RIR.

All rats were subjected to measurement of initial body weight (IBW, g), final body weight (FBW, g) and calculation of body weight gain [BWG, g] and percent weight gain (%BWG, %).

Experimental Procedures: All rat groups were sacrificed 24 hours after the surgical intervention. On the day of sacrifice, the overnight fasted rats with free access

to water, were weighed and anesthetized by i.p. injection of thiopental sodium (EPICO, Egypt) in a dose of 40 mg/kg B.W. (*Flecknell, 1998*). When the stage of surgical anesthesia had been reached as judged by loss of withdrawal reflex, the animal was placed on its back and fixed on the dissecting board. A midline abdominal incision was made to explore the abdominal aorta followed by its cannulation with polyethylene catheter and the blood was collected into 2 separate test tubes; one citrated glass tube that was centrifuged at 2500 RPM (revolutions per minute) for 15 min using Hettich EBA 8s centrifuge to obtain platelet poor plasma (PPP) to be used within 4 hours to determine Prothrombin time (PT) according to *Loeliger (1984)* using phosphoplastin RL kits (ISI number 1.04) supplied by *r² DIAGNOSTICS*, South Bend, Indiana; activated partial thromboplastin time (APTT) according to *Brandt and Triplett (1981)* by using Phospholin ES kits supplied by *r² DIAGNOSTICS*, South Bend, Indiana. Part of the plasma sample was stored at -80° C for later determination of fibrin degradation products (FDPs) semi-quantitatively by the latex agglutination as described by *Mirshahi et al. (1986)* and modified by *Nieuwenhuizen (1988)* using kits supplied by Diagnostica Stago, France; and Malondialdehyde (MDA_p) according to the technique of *Esterbauer and Cheeseman (1990)* using thiobarbituric acid test. The other tube contained coagulation accelerator serum separating gel that was centrifuged in the same way as previously described, then the separated serum was stored at -80° C for later determination of urea by a colorimetric test according to the Urease

Berthelot reaction indicated by *Fawcett and Soctt (1960)* using kits supplied by Bio-diagnostic- Egypt, as well as creatinine by the colorimetric method which was estimated kinetically by *Bartles et al. (1972) and Larsen (1972)* using kits supplied by Bio-diagnostic-Egypt, and C-reactive protein (CRP) according to *Ridker (2003) and Mitra & Panja (2005)*, using kits supplied by BioVendor-Laboratorn' medic'haa.s, Karasek, Brno, Czech Republic.

Both kidneys were dissected, weighed using Sartorius AG analytical balance, then left kidney was stored at -80°C for later determination of tissue Malondialdehyde level (MDA_t) according to the technique of *Esterbauer and Cheeseman (1990)* using thiobarbituric acid test, while right kidney immediately was fixed in 10% formalin, then was embedded in paraffin and tissue sections of 5 μm were obtained and stained with hematoxylin and eosin (H&E) for histopathological examination using light microscope according to *Adnan et al.*

(2013).

Statistical Analysis: Data were expressed as means ± SEM. Statistical significance of data was determined according to One way ANOVA (Analysis of variance) followed by post-hoc test (LSD). Chi square test was used for qualitative data analysis. Statistical analysis was performed by using SPSS (version 24). A probability of P < 0.05 was considered statistically significant. Body weight gain (BWG) was calculated by subtracting the FBW from the IBW. % BWG was calculated by dividing BWG by IBW. RKW was calculated by dividing KW by FBW.

RESULTS

IBW, FBW, BWG and % BWG were not significantly different among the three studied rat groups. As regard kidney weights, RIR group showed significant increase ($P < 0.002$ and 0.001 respectively) in absolute and relative kidney weights compared to SHAM group. RIR treated group showed no significant difference in either absolute or relative kidney weight compared to RIR rat group, although they showed significant increase ($P < 0.05$ and 0.02 respectively) compared to SHAM group (Table 1).

Prothrombin time (PT), activated partial thromboplastin time (APTT) and the plasma fibrin degradation products (FDPs) levels were non-significantly different in the three studied groups (Table 2).

Serum urea and creatinine significantly increased ($P < 0.001$ and 0.02 respectively)

in RIR group compared to SHAM group. RIR treated group had insignificant change in the level of serum urea and creatinine compared to RIR rats, and significantly increased ($P < 0.01$ and 0.001 respectively) compared to SHAM group. There was no significant difference in serum C-reactive protein (CRP), plasma malondialdehyde (MDA_p) and renal tissue malondialdehyde (MDA_t) among the three studied rat groups (Table 3).

Normal renal architecture was shown in fig. (1). Histopathological study of RIR rat kidneys revealed congestion of glomerular tuft with perivascular edema and atrophy of other glomerular tuft as well as tubular cystic dilation with intraluminal eosinophilic renal cast and necrobiosis of its epithelial lining (Fig. 2). These changes were also observed in RIR treated (Fig. 3).

Table (1): Initial body weight (IBW, g), final body weight (FBW, g), body weight gain (BWG, g), body weight gain percent (BWG%, %), absolute kidney weight (AKW, g) and relative kidney weight (RKW) in the 3 studied groups.

Parameters Rat groups	IBW (gm)	FBW (gm)	BWG (gm)	%BWG (%)	AKW (gm)	RKW
SHAM (18)	212.22 ±4.13	208.61 ±3.72	-3.61 ±1.89	-1.59 ±0.90	1.10 ±0.03	0.53 ±0.01
RIR (20)	218.00 ±4.21	215.50 ±4.91	-2.50 ±2.04	-1.20 ±0.93	1.28 ±0.04	0.60 ±0.01
P	NS	NS	NS	NS	<0.002	<0.001
RIR _{ttt} (10)	216.00 ±6.57	219.50 ±8.90	3.50 ±3.73	1.42 ±1.65	1.43 ±0.08	0.65 ±0.03
P	NS	NS	NS	NS	<0.001	<0.001
P₁	NS	NS	NS	NS	<0.05	<0.02

Values were expressed as mean ± SEM. In parenthesis is the number of rats.

P: Significance from sham- operated group.

P₁: Significance from RIR group.

NS: Non-significant.

Table (2): Prothrombin time (PT, sec), activated partial thromboplastin time (APTT, sec) and fibrin degradation products (FDPs, ug/ml) in the 3 studied groups.

Parameters Rat groups	PT (sec)	APTT (sec)	FDPs (µg/ml)		
			<5	≥5 <20	≥20
SHAM (18)	15.06 ±0.54	23.28 ±0.92	100%	0%	0%
RIR (20) P P*	15.60 ±0.56 NS	22.37 ±0.88 NS	100%	0%	0%
RIR_{ttt} (10) P P₁ P* P₁*	14.80 ±0.79 NS NS	23.20 ±1.52 NS NS	100%	0%	0%
				NS	NS

Values were expressed as mean ± SEM. In parenthesis is the number of rats.

P: Significance from sham- operated group. **P₁:** Significance from RIR group.

P*: Significance from sham-operated group. **P₁*:** Significance from RIR group.

NS: Non-significant.

Table (3): Serum urea (urea, mg/dl), serum creatinine (creatinine, mg/dl), serum C-reactive protein (CRP, mg/l), plasma malondialdehyde (MDA_p, µmol/l) and renal tissue malondialdehyde (MDA_t, µmol/gm wet tissue) in the 3 studied groups.

Parameters Rat groups	Urea (mg/dl)	Creatinine (mg/dl)	CRP (mg/l)	MDA _p (µmol/l)	MDA _t (µmol/gm)
SHAM (18)	33.75 ±4.07	1.19 ±0.11	2.87 ±0.25	1.46 ±0.07	1.90 ±0.11
RIR (20) P	130.77 ±21.40 <0.001	2.25 ±0.24 <0.02	2.28 ±0.20 NS	1.38 ±0.05 NS	1.69 ±0.10 NS
RIR_{ttt} (10) P P₁	117.50 ±19.03 <0.01 NS	3.19 ±0.58 <0.001 NS	2.26 ±0.26 NS NS	1.33 ±0.09 NS NS	1.55 ±0.17 NS NS

Values were expressed as mean ± SEM. In parenthesis is the number of rats.

P: Significance from sham- operated group. **P₁:** Significance from RIR group.

NS: Non-significant.

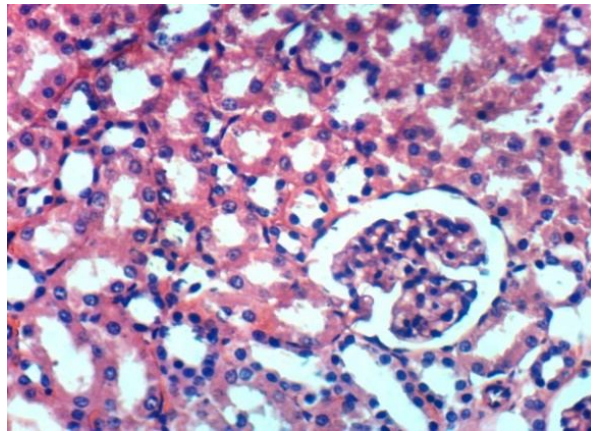


Figure (1): Kidney of sham-operated rat group showing the normal histological structure of renal parenchyma (H&E X 400).

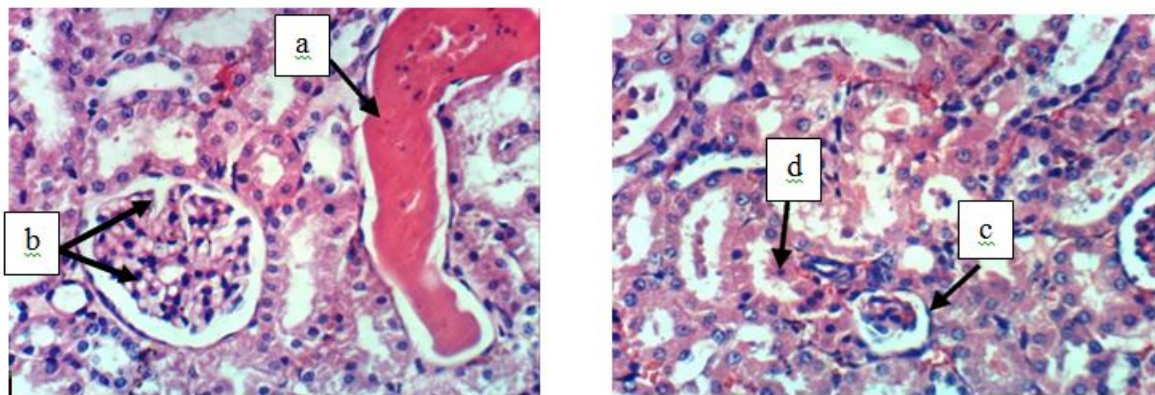


Figure (2): Kidney of RIR rat group showing (a) cystic dilation of renal tubules and intraluminal eosinophilic renal cast (b) congestion of glomerular tuft and perivascular edema (c) atrophy of glomerular tuft (d) necrobiosis of epithelial lining of some renal tubules (H & E X 400).

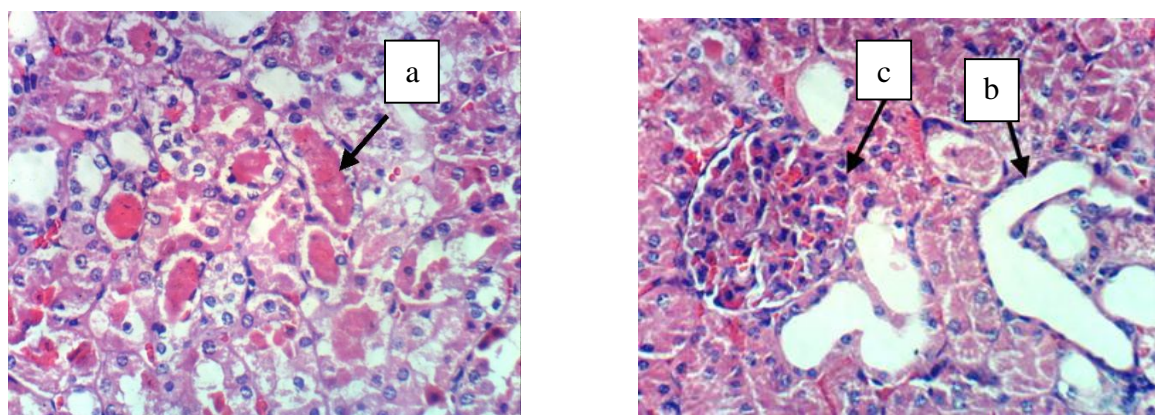


Figure (3): Kidney of RIR treated rat group with Vit. E Acetate showing (a) intraluminal eosinophilic renal cast (b) cystic dilation of renal tubules (c) hypertrophy of glomerular tuft (H& E X 400).

DISCUSSION

In the current study, both RIR and RIR treated rat groups did not show significant change from each other as regards the IBW, FBW, BWG or BWG%. These findings were contradicted with what was shown by *Nitescu et al. (2007)* of 10% reduction in body weight compared with sham-operated group. This might be explained by the difference in the timing of the body weight measurement in the present study which was at 24 hours after IR injury, while in the study of *Nitescu et al. (2007)* was after 48 hours.

The significant increase in absolute and relative kidney weights in RIR rat group were in agreement with the findings of *Nuransoy et al. (2015)*. The significant increase in these two parameters despite the loss in functioning kidney mass can be ascribed to the congestion and edema observed in the histopathologic pictures of these rats' kidneys. Edema could be due to increased capillary leakiness which would further compromise renal perfusion by compressing peritubular capillaries.

Increased serum levels of urea and creatinine in RIR rat group reflected acute renal dysfunction. This was in accordance to the findings of previous studies (*Venkatachalam et al., 2010 and Kim et al., 2011*). The significant increase in serum creatinine as previously reported by *Basile (2007)* suggested decreased creatinine clearance which would indicate decreased glomerular filtration rate possibly due to glomerular damage that was evident in the histopathological picture of these rat kidneys which revealed atrophy, congestion and hypertrophy of glomerular tufts as well as necrobiosis of tubular epithelial lining,

and tubular dilatation with proteinaceous material in their lumens. These findings clearly demonstrated the alteration in renal structure after IR injury which was consistent with the findings of *Skrypnyk et al. (2016)*.

It was worth noting that the RIR rat group didn't exhibit any significant increase in MDA levels in either the plasma or the kidneys which would exclude the possibility of oxidative stress as a suggested mechanism in the previous literature to be the cause of renal IR injury. This was consistent with the findings of *Rasoulian et al. (2008)* who showed unchanged MDA levels following IR, which was also supported by the findings of *Tucci Junior et al. (2008)* who showed that MDA rose significantly at 5 minutes of reperfusion and returned to pre-ischemic values after twenty-four hours. On the other hand, it was inconsistent with those of *Ersoz et al. (2009)* who found that MDA levels significantly increased after IR injury.

The unchanged levels of C-reactive protein in RIR rat groups excluded the possibility of post-surgery infection, and also excluded the possibility of inflammation as the mechanism underlying kidney injury. In support of this finding was the histological picture of the kidney that didn't show infiltration of kidney tissue by inflammatory cells.

Blood coagulation parameters (PT, APTT and FDP) were not significantly changed in the RIR rat group which might exclude the possibility of increased level or enhanced activity of intrinsic and extrinsic pathways of coagulation as the mechanism underlying AKI in these rats. These results were in contrast to the

findings of *Sevastos et al. (2007)* and *Ajay et al. (2012)* who showed that renal IR might cause the accumulation of fibrinogen in the kidney and formation of micro-thrombi. RIR treated had insignificant changes in their hemostatic tests compared to the RIR and the sham operated rat groups which were in agreement with the findings of *Bakaltcheva et al. (2001)* and *Morinobu et al. (2002)* who showed that PT, APTT and bleeding time were not changed by dietary supplementation of Vitamin E.

CONCLUSION AND RECOMMENDATION

Oxidative stress and inflammation - associated coagulopathy might not be the principal mechanism underlying AKI due to ischemic reperfusion injury of the kidney. The form, dose, timing and route of vitamin E administration in the present study didn't significantly improve the outcome of AKI induced by IR. Further studies using other forms, timing, doses and routes of vitamin E should be investigated.

ACKNOWLEDGEMENT

The authors would like to acknowledge their deepest gratitude and appreciation to **Prof. Dr. Kawkab Abdelaziz Ahmed**, Professor of Pathology, Faculty of Veterinary Medicine, Cairo University, for her histopathological comment.

REFERENCES

1. Adnan, A., Bilge, O., Sahin, K., Dilek, B., Hakan, S., Cengiz, U. M., Fahrettin, A. and Hilmi, O. (2013): The protective effect of silymarin on the antioxidant system at rat renal ischemia/reperfusion injury model. *African Journal of Pharmacy and Pharmacology*, 7(6): 220-226.
2. Ajay, A. K., Saikumar, J., Bijol, V. and Vaidya, V. S. (2012): Heterozygosity for fibrinogen results in efficient resolution of kidney ischemia reperfusion injury. *PloS one*, 7(9): e45628.
3. Arfian, N., Emoto, N., Vignon-Zellweger, N., Nakayama, K., Yagi, K. and Hirata, K. I. (2012): ET-1 deletion from endothelial cells protects the kidney during the extension phase of ischemia/reperfusion injury. *Biochemical and Biophysical Research Communications*, 425(2): 443-449.
4. Bakaltcheva, I., Gyimah, D. and Reid, T. (2001): Effects of α -tocopherol on platelets and the coagulation system. *Platelets*, 12(7): 389-394.
5. Bartels, H., Bohmer, M. and Heierli, C. (1972): Estimation of serum creatinine without removal of protein. *Clinica Chimica Acta*, 37: 193-197.
6. Basile, D. P. (2007): The endothelial cell in ischemic acute kidney injury: implications for acute and chronic function. *Kidney International*, 72 (2):151-156.
7. Brandt, J. T. and Triplett, D. A. (1981): Laboratory monitoring of heparin. Effect of reagents and instruments on the activated partial thromboplastin time. *American Journal of Clinical Pathology*, 76(4 Suppl): 530-537.
8. Duffy, M. M., McNicholas, B. A., Monaghan, D. A., Hanley, S. A., McMahan, J. M., Pindjakova, J., Alagensan, S., Fearnhead, O. H. and Griffin, M. D. (2014): Mesenchymal stem cells and a vitamin D receptor agonist additively suppress T helper 17 cells and the related inflammatory response in the kidney. *American Journal of Physiology-Renal Physiology*, 307(12): F1412-F1426.
9. Ersoz, N., Guven, A., Cayc?, T., Uysal, B., Turk, E., Oztas, E., Akgul, E. O., Korkmaz, A. and Cetiner, S. (2009): Comparison of the efficacy of melatonin and 1400W on renal ischemia/reperfusion injury: a role for inhibiting iNOS. *Renal Failure*, 31(8): 704-710.
10. Esterbauer, H. and Cheeseman, K. H. (1990): Determination of aldehydic lipid peroxidation products: malonaldehyde and 4-

- hydroxynonenal. *Methods in Enzymology*, 186: 407-421.
11. **Fawcett, J. K. and Scott, J. (1960):** A rapid and precise method for the determination of urea. *Journal of Clinical Pathology*, 13(2): 156-159.
 12. **Flecknell, P. A. (1998):** Analgesia in small mammals. *Seminars in Avian and Exotic Pet Medicine*, 7(1): 41-47.
 13. **Kalogeris, T., Baines, C.P., Krenz, M. and Korthuis, R.J. (2012):** Cell Biology of Ischemia/Reperfusion Injury. *Int. Rev. Cell Mol. Biol.*, 298: 229-317.
 14. **Kim, H. B., Shanu, A., Wood, S., Parry, S. N., Collet, M., McMahan, A. and Witting, P.K. (2011):** Phenolic antioxidants tert-butyl-bisphenol and vitamin E decrease oxidative stress and enhance vascular function in an animal model of rhabdomyolysis yet do not improve acute renal dysfunction. *Free Radical Research*, 45(9): 1000-1012.
 15. **Larsen, K. (1972):** Creatinine assay by a reaction-kinetic principle. *Clinica Chimica Acta*, 41: 209-217.
 16. **Loeliger, E. A. (1984):** ICSH/ICTH recommendations for reporting prothrombin time in oral anticoagulant control. *Acta Haematologica*, 72(6): 405-407.
 17. **Malek, M. and Nematbakhsh, M. (2014):** The preventive effects of diminazene aceturate in renal ischemia/reperfusion injury in male and female rats. *Advances in Preventive Medicine*, 2014: 740647.
 18. **Malek, M. and Nematbakhsh, M. (2015):** Renal ischemia/reperfusion injury; from pathophysiology to treatment. *Journal of Renal Injury Prevention*, 4(2): 20-27.
 19. **Mirshahi, M., Soria, J., Soria, C., Perrot, J. Y. and Boucheix, C. (1986):** A latex immunoassay of fibrin/fibrinogen degradation products in plasma using a monoclonal antibody. *Thrombosis Research*, 44(6): 715-728.
 20. **Mitra, B. and Panja, M. (2005):** High sensitive C-reactive protein: a novel biochemical markers and its role in coronary artery disease. *The Journal of the Association of Physicians of India*, 53: 25-32.
 21. **Morinobu, T., Ban, R., Yoshikawa, S., Murata, T. and Tamai, H. (2002):** The safety of high-dose vitamin E supplementation in healthy Japanese male adults. *Journal of Nutritional Science and Vitaminology*, 48(1): 6-9.
 22. **Naz̧rođlu, M., Karaođlu, A. and Aksoy, A. O. (2004):** Selenium and high dose vitamin E administration protects cisplatin-induced oxidative damage to renal, liver and lens tissues in rats. *Toxicology*, 195(2): 221-230.
 23. **Nieuwenhuizen, W. (1988):** New strategies in the determination of fibrin and fibrin (ogen) derivatives by monoclonal antibodies. *Annals of Hematology*, 57(5): 285-291.
 24. **Nitescu, N., Grimberg, E., Ricksten, S. E., Marcussen, N. and Guron, G. (2007):** Thrombin inhibition with melagatran does not attenuate renal ischaemia-reperfusion injury in rats. *Nephrology Dialysis Transplantation*, 22(8): 2149-2155.
 25. **Nuransoy, A., Beytur, A., Polat, A., Samdanci, E., Sagir, M. and Parlakpınar, H. (2015):** Protective effect of sitagliptin against renal ischemia reperfusion injury in rats. *Renal Failure*, 37(4): 687-693.
 26. **Peţj̧, J. (2011):** Inflammation and coagulation. An overview. *Thrombosis Research*, 127 (2): S34-37.
 27. **Rasoulıan, B., Jafari, M., Norroozzadeh, A., Mehrani, H., Wahhab-Aghai, H., Hashemi, M. S., Ghani, E., Esmaili, M., Asgari, A. and Khoshbaten, A. (2008):** Effects of ischemia-reperfusion on rat renal tissue antioxidant systems and lipid peroxidation. *Acta Medica Iranica*, 46 (5): 353-360.
 28. **Ridker, P. M. (2003):** High-sensitivity C-reactive protein and cardiovascular risk: rationale for screening and primary prevention. *The American Journal of Cardiology*, 92(4):17-22.
 29. **Sevastos, J., Kennedy, S. E., Davis, D. R., Sam, M., Peake, P. W., Charlesworth, J. A., Mackman, N. and Erlich, J.H. (2007):** Tissue factor deficiency and PAR-1 deficiency are

- protective against renal ischemia reperfusion injury. *Blood*, 109(2): 577-583.
- 30. Simmons, M. N., Schreiber, M. J. and Gill, I. S. (2008):** Surgical renal ischemia: a contemporary overview. *The Journal of Urology*, 180(1): 19-30.
- 31. Skrypnyk, N. I., Siskind, L. J., Faubel, S. and de Caestecker, M.P. (2016):** Bridging translation for acute kidney injury with better preclinical modeling of human disease. *American Journal of Physiology-Renal Physiology*, 310: F972- F984.
- 32. Skrypnyk, N. I., Voziyan, P., Yang, H., de Caestecker, C. R., Theberge, M. C., Drouin, M., Hudson, B., Harris, R.C. and de Caestecker, M.P. (2016):** Pyridoxamine reduces postinjury fibrosis and improves functional recovery after acute kidney injury. *American Journal of Physiology-Renal Physiology*, 311(2), F268-F277.
- 33. Sureshababu, A., Ryter, S. W. and Choi, M. E. (2015):** Oxidative stress and autophagy: crucial modulators of kidney injury. *Redox Biology*, 4: 208-214.
- 34. Tucci Junior, S., Carvalho, R. M. D., Celini, F. M., Cologna, A. J., Suaid, H. J., Tirapelli, L. F. and Martins, A. C. P. (2008):** Renal ischemia and reperfusion injury: influence of chlorpromazine on renal function and lipid peroxidation. *Acta Cirurgica Brasileira*, 23: 42-46.
- 35. Venkatachalam, M. A., Griffin, K. A., Lan, R., Geng, H., Saikumar, P. and Bidani, A. K. (2010):** Acute kidney injury: a springboard for progression in chronic kidney disease. *American Journal of Physiology-Renal Physiology*, 298(5): F1078-F1094.

تأثير فيتامين هـ علي تطور القصور الكلوي الحاد التجريبي الناجم عن إعادة التروية بعد الإقفار على إناث الجرذان

نهال محمد بهجت جميل، سهى محمد يسرى محمد، دعاء أحمد أبو بكر، بسنت شاكر محمد السيد

قسم الفسيولوجي، كلية الطب، جامعة عين شمس

خلفية البحث: يعد القصور الكلوي الحاد خلل شائع عالمياً يتسبب في الإعاقة و الوفاة بدرجة كبيرة. ان الفسيولوجيا المرضية للقصور الكلوي الحاد معقدة تشمل تلف الانسجة بالاجهاد التأكسدي، الالتهاب و تنشيط متتاليه التجلط.

الهدف من البحث: معرفة التأثير العلاجي لفيتامين هـ علي تطور القصور الكلوي الحاد التجريبي عند حقنه مباشرة" بعد إعادة التروية للكلى بعد الإقفار لمدة 45 دقيقة.

مواد وطرق البحث: أجريت هذه الدراسة على إناث الجرذان البالغة (48 جرذ) و اللاتي تتراوح أوزانهن بين 185- 250 جرام.

وقد تم تقسيم الفئران عشوائياً إلى المجموعات التالية:

- 1) مجموعة الجرذان الضابطة: خضعت هذه الفئران لجراحة كاذبة (العدد = 18).
- 2) مجموعة الجرذان المصابة بالقصور الكلوي الناجم عن إعادة التروية بعد الإقفار لمدة 45 دقيقة (العدد = 20).
- 3) مجموعة الجرذان المعالجة بفيتامين هـ مباشرة بعد الإصابة بالقصور الكلوي الناجم عن إعادة التروية بعد الإقفار لمدة 45 دقيقة (العدد=10).

وقد خضعت جميع الجرذان للقياسات التالية: وزن الجسم المبدئي و النهائي بعد 24 ساعة من الجراحة، و قد تم حساب النسبة المئوية للتغير في وزن الجسم و وزن الكليتين المطلق والنسبي و مستوي الكرياتينين واليوريا في الدم، و زمن البروثرومبين، و زمن الثرمبوبلاستين الجزئي المنشط، نواتج تكسير الفيبرين. هذا بالإضافة الى البروتين التفاعلي (ج)، والمالونديالدهيد في الدم والنسيج الكلوي، كما تم فحص النسيج الكلوي بالمجهر الضوئي.

النتائج: أظهرت نتائج هذه الدراسة عدم وجود تغير ذو دلالة إحصائية في وزن الجسم بين المجموعات الثلاثة الخاضعة للدراسة، أما فيما يخص وزن الكليتين المطلق والنسبي، فقد كانت هناك

زيادة ذات دلالة إحصائية بين المجموعة المصابة بالقصور الكلوي الناجم عن إعادة التروية بعد الإقفار لمدة 45 دقيقة، والمجموعة المعالجة بفيتامين هـ بعد الإصابة بالقصور الكلوي الناجم عن إعادة التروية بعد الإقفار لمدة 45 دقيقة بالمقارنة مع قيم المجموعة الضابطة. ولم تظهر الدراسة وجود تغير ذو دلالة إحصائية في زمن البروثرومبين والثرمبوبلاستين الجزئي المنشط، و كذلك نواتج تكسير الفيبرين بين المجموعات الثلاثة الخاضعة للدراسة. أما فيما يخص وظائف الكلى، فقد كانت هناك زيادة ذات دلالة إحصائية في مستوى اليوريا والكرياتينين في الدم في المجموعة المصابة بالقصور الكلوي الناجم عن إعادة التروية بعد الإقفار لمدة 45 دقيقة، والمجموعة المعالجة بفيتامين هـ بعد الإصابة بالقصور الكلوي الناجم عن إعادة التروية بعد الإقفار لمدة 45 دقيقة مقارنة مع قيم المجموعة الضابطة. كما أظهرت الدراسة عدم وجود تغير ذو دلالة إحصائية في مستوى البروتين التفاعلي (ج) والمالونديالدهيد في النسيج الكلوي أو الدم بين المجموعات الثلاثة الخاضعة للدراسة.

وقد أظهر الفحص النسيجي للكلية تغير في الشكل الطبيعي للنسيج الكلوي في كل المجموعات المصابة بالقصور الكلوي الناجم عن إعادة التروية بعد الإقفار لمدة 45 دقيقة سواء الغير المعالجة أو المعالجة بفيتامين هـ بعد الإصابة وذلك عند مقارنتهم بالمجموعة الضابطة، ولم يظهر الفحص النسيجي للكلية تحسناً "لموساً" في المجموعات المعالجة بفيتامين هـ عند مقارنتها بالمجموعة المصابة بالقصور الكلوي الناجم عن إعادة التروية بعد الإقفار لمدة 45 دقيقة والتي لم تعالج بفيتامين هـ.

الاستنتاج: فيتامين هـ بالجرعة المستخدمة في هذه الدراسة (1000 ملليجرام/ كيلوجرام وزن الجسم جرعه واحدة) مباشرة بعد الإصابة بالقصور الكلوي الناجم عن إعادة التروية بعد الإقفار لمدة 45 دقيقة لم يؤدي إلي تحسن ملموس في وظائف الكلى، و لم يساهم في تخفيف التلف الحادث في النسيج الكلوي نتيجة التروية بعد الإقفار.