

IMPRESSIONS PRODUCED BY DISC HERNIATIONS

ON THE BODIES OF HUMAN VERTEBRAE

M.F.GABALLAH, ZAIZAFON H. BADAUWY AND F. Z. HASSAN*

*Departments of Anatomy, Faculties of Medicine,
Cairo and Assiut* Universities*

INTRODUCTION

It is a common experience in medical practice that lesions of the intervertebral discs may be responsible for many cases of low back pain. The first detailed description of herniations of disc material into the spongiosa of adjacent vertebral bodies (Schmorl's bodies) was given by Schmorl (1927). A defect in the plate of cartilage present on either surface of the intervertebral disc was considered responsible for such herniation. This view was confirmed experimentally where disc herniations were produced in dogs after making surgical damage in the cartilage plates covering the discs (Compere and Keyes, 1933). Cases of disc prolapse into the adjacent vertebral bodies were reported in children who showed congenital defects in the cartilage plates (Schmorl, 1930). A degenerative process was also assumed to be an

underlying factor since many cases of Schmorl's bodies have also been observed in old subjects. In senile specimens, these prolapses were found firm in consistency due to calcium deposition and in some cases they were surrounded by a reactive shell of sclerosed bone that could be visualised on X-ray examination (Coventry, 1945).

The previous investigations on Schmorl's bodies were carried out using histological and radiological means but as far as our knowledge goes, no detailed study of their tracemarks on dried vertebrae has been done. The main objective of the present work is to describe the shape, course and distribution of their impressions as seen in dried specimens.

MATERIAL AND METHODS

Twenty-eight dried vertebrae showing the defects on the upper

and lower surfaces were selected for this study out of 90 vertebral columns of Egyptian subjects. The examined specimens were 16 thoracic and 12 lumbar vertebrae. More than one affected vertebra belonged to the same subject.

The depressions or grooves were described as regards their shape, size, number and direction. The presence of associated osteophytes or other atrophic degenerative changes in the examined vertebrae were also noted.

A specimen of disc prolapse into the adjacent vertebral bodies was removed from a cadaver aged about 60 years for histological study. The herniated mass was sectioned at 15 μ thickness and was stained with haematoxylin and eosin.

OBSERVATIONS

I— *Dried vertebrae* :

Shape and size : The impressions present on the upper surface of lumbar vertebrae vary from those found on the lower surface as regards the frequency of their shapes (figs. 1 & 2). Out of 9 depressions noted on the upper surface, 6 are oval, 2 are rounded while only one is curved. In contrast, 7 out of 10 cases present on the lower surface are curved with their convexities directed either anteriorly (3 cases) or posteriorly (4 cases), whereas the remaining 3 cases are either oval (one case) or slightly elongated (2 cases). The curved types are either semilunar or

V-shaped with its 2 limbs meeting each other at an acute angle. In some cases, a short ridge of bone measuring 1—5 mm in height intervenes between the 2 limbs of the V-shaped depression. In one case there are 3 depressions lying on a curved line on the lower surface and separated from each other by 2 ridges (fig. 1).

The impressions in the thoracic specimens are linear in outline. Their margins are either parallel or may diverge slightly as they are traced posteriorly (fig. 3). The size of the depressions in the lumbar vertebrae ranges from 4—22 mm in length, 4—16 mm in width and 2—5 mm in depth, while in the thoracic vertebrae the ranges are 3—25 mm, 2—11 mm and 1—4 mm respectively.

Most of the impressions present in the lumbar vertebrae run in a coronal direction with the exception of one case where the depression is elongated and run in a sagittal direction. On the other hand, in the thoracic vertebrae the grooves run anteroposteriorly in the sagittal plane. Moreover, in one thoracic vertebra (12th) the upper surface shows a V-shaped depression that runs in a coronal direction.

Position and course : The grooves in the lumbar vertebrae lie on both the upper and lower surfaces in 7 out of 12 specimens, in which the lower impressions are of larger dimensions. In 2 cases they lie only on the lower surface while in 3 cases they are confined solely to the

upper surface. The defects have a position equidistant between the the two sides of the vertebra but they are nearer the posterior than the anterior margin. They are separated from the posterior margin of the vertebra by a distance measuring 6—13 mm and from the anterior margin by 16—28 mm. They are always separated from the posterior margin of the body by an intact rim of bone.

In the thoracic vertebrae, the majority of the depressions (9 cases out of 16) lie on the lower surface while in 2 cases they are present only on the upper surface. In 5 cases however, the grooves are found on both surfaces. The impressions increase in depth as they run posteriorly and in some cases they become also wider. The depressions start near the centre of the vertebral body and extend backwards in a straight line till it reaches the posterior margin exactly in the median plane. In 8 vertebrae, of which 3 possess osteophytes, the grooves cut partially or completely into the posterior margin of the vertebral body (fig. 3). In one case the interruption of the posterior margin measures 2—5 mm and the groove extends farther on the posterior surface of the vertebra.

The examined vertebrae show slight degeneration in 6 specimens (2 thoracic and 4 lumbar), moderate atrophy with lipping in 5 specimens (2 thoracic and 3 lumbar) and severe degeneration with marked osteophytes in 7 specimens (5 thora-

cic and 2 lumbar). It is worth mentioning that out of the 28 vertebrae examined no such senile changes are apparent in 10 cases (6 thoracic and 4 lumbar).

II— *The cadaveric specimen :*

The cadaver examined is an old male subject with marked wasting of muscles. Excessive amounts of fat are observed inside the spongy tissue of the vertebral bodies as well as in between the muscles. Pro-lapsed masses from the 2nd and 3rd lumbar intervertebral discs are seen by the naked eye bulging into the adjacent spongiosa (fig. 4). The herniations measure about 4 mm in breadth and 4 mm in height. Microscopical examination shows the presence of other incomplete protrusions into the plate of cartilage in addition to the large ones seen by the naked eye. The prolapses consist of both the anulus fibrosus and nucleus pulposus and the plate of cartilage at the face of the prolapse is attenuated. The tissue of the disc in the vicinity of the prolapse shows fragmentation with the collagenous bundles coalesced into an amorphous mass. The cancellous bone in contact with the herniating tissue is fragmentary with no evidence of new bone formation (figs. 5, 6 & 7).

DISCUSSION

Intervertebral discs are common sites for early senile degeneration. This is expected from their poor blood supply and continuous ex-

posure to wear and tear. The present study demonstrated that herniations of the intervertebral disc into the adjacent bodies (Schmorl's bodies) varied in shape, size and frequency according to whether they occurred in the thoracic or lumbar vertebrae. Prolapse of lumbar discs produced oval or curved impressions with their long axes lying transversely while those of thoracic discs resulted in linear markings that run anteroposteriorly in the median plane. Such regional differences may be related to variations in size of the vertebrae as well as to the effects of continuous pressure imposed by the heads of the ribs on the sides of the thoracic vertebral bodies during respiratory movements.

Furthermore, a difference in thickness and strength of the epiphyseal plate of cartilage may exist between its periphery and its centre. Such difference may have a role in determining the shape and course of the herniations in both the thoracic and lumbar regions. Most of the thoracic impressions extend towards the posterior margin of the vertebral body where some of them may cut into it and encroach on the posterior surface of the body, while lumbar defects are always separated from the vertebral canal by an intact rim of bone. The strength and size of the attachment of the anulus fibrosus seem to act as an additional predisposing factor. In the lumbar region more than one impression

was found coalescing together indicating that several disc defects might have been produced simultaneously or successively in the plate of cartilage.

The depressions were noticed with equal frequency on the upper and lower surfaces of the bodies of the lumbar vertebrae while they were more predominant on the lower surface of the thoracic vertebrae. However, it was not uncommon to find depressions on both the upper and lower surfaces of the same vertebra.

These bony depressions were more frequent in senescent vertebrae as about 65% of the cases showed atrophic degeneration in their bodies with osteophytic lipping. It should be noted that such impressions were also encountered in apparently normal vertebrae. Saunders and Inman (1940) suggested that disc herniations inside the adjacent spongiosa were due to degenerative changes in old age and claimed that they started their appearance in young age and became well established by the second decade of life. These protrusions have also been described by Coventry et al (1945) in senile specimens (6th decade) where the plates of cartilage were found markedly degenerated.

Microscopical masses of disc tissue were observed in this study to infiltrate the plate of cartilage; a finding that may lead to the in-

ference that derangement in the structure of the disc precedes rupture of the plate. The absence of associated vascularisation or new bone formation is not in favour of an underlying inflammatory process. However, chemical changes have been found to affect the mucopolysaccharide and protein content of the intervertebral disc in old age, thus leading to diminution of its water binding capacity (Puschel, 1930; Inman and Saunders, 1947; Hendry, 1958). The presence of several herniations in the same disc directed both upwards and downwards may refer to an associated swelling of its tissue with consequent rupture of the plate of cartilage on either side of the disc.

SUMMARY

A series of human vertebrae was selected for this study due to their affection by a number of impressions on the upper and lower surfaces of their bodies. In addition, specimens were examined histologically from an old cadaver showing several disc herniations in the adjacent lumbar vertebrae. The vertebrae revealed differences in the shape, size and course of these impressions between the thoracic and lumbar regions. However, no similar defects were noticed in the cervical vertebrae.

In the thoracic vertebrae the depressions were observed to have a linear outline and extended anteroposteriorly in the median plane where some of them cut into the posterior margin of the vertebra. However, in the lumbar vertebrae

the impressions were mainly curved or oval in outline. They were situated with their long axes extending transversely leaving the posterior border of the vertebral body intact in all cases.

These changes are believed to be due to senile degeneration of the intervertebral disc where its contents become much swollen leading to rupture of the related plate of cartilage. No signs of increased vascularisation or new bone formation were noticed and accordingly an inflammatory etiology seems unjustifiable.

REFERENCES

1. **Compere, E.L. and Keyes, D.C. (1933):** cited by Coventry, M.B.; Ghormley, R.K. and Kernohan, G.W. Part III, (1945).
2. **Coventry, M.B.; Ghormley, R.K. and Kernohan, G.W. (1945):** The intervertebral disc. Part I: Its microscopic anatomy and pathology. *J. Bone and Joint Surg.*, 27(1) : 105---112.
3. **Coventry, M.B.; Ghormley, R.K. and Kernohan, G.W. (1945):** The intervertebral disc. Part II: Changes in the intervertebral disc concomitant with age. *J. Bone and Joint Surg.*, 27(2) : 233.
4. **Coventry, M.B.; Ghormley, R.K. and Kernohan, G.W. (1945):** The intervertebral disc. Part III: Pathological changes in the intervertebral disc. *J. Bone and Joint Surg.*, 27(2). 460 474.
5. **Hendry, G.C. (1958):** Cited by Davies, D.V. and Davies, F.; *Gray's Anatomy, Descriptive and applied*, 33rd edition, Longmans, London, p. 486, 1962.
6. **Inman, V.T. and Saunders, J.B. de C.M. (1947):** Cited by Davies, D.V. and Davies, F.; *Gray's Anatomy, Des-*

criptive and Applied, 33rd edition, Longmans, London p. 486, 1962.

7. **Puschel, J. (1930)** : Cited by Davies, D.V. and Davies, F.: Gray's Anatomy, Descriptive and Applied, 33rd edition, Longmans, London, p. 486, 1962.
8. **Saunders, J.B. de C.M. and Inman, V.T. (1940)** : Pathology of the intervertebral disc. Arch. Surg., 40 : 389-416.
9. **Schmorl, G. (1927)** : Cited by Coventry, M.B.; Ghormley, R.K. and Kernohan, G.W. Part III, 1945.
10. **Schmorl, G. (1930)** : Cited by Coventry, M.B.; Ghormey, R.K. and Kernohan, G.W., Part III, 1945.

LEGENDS

Fig. (1) : The lower surface of the body of a lumbar vertebra showing three depressions which appear nearly oval in shape.

Fig. (2) : A lumbar vertebra showing a curved depression on its upper surface. The long axis of the impression extends in a coronal plane and is well-separated from the posterior border of the vertebra.

Fig. (3) : A thoracic vertebra showing

a longitudinal depression present in the median plane and cutting into the posterior border of the vertebra. The circumference of the vertebral body reveals senile degenerative changes.

Fig. (4) : A sagittal section in lumbar vertebrae showing herniations (marked by an arrow) of two discs into the body of a lumbar vertebra. The upper and lower surfaces of the vertebral body are compressed inwards by the bulging discs. One disc shows deep cavities (C), while the other has a fissure (F).

Fig. (5) : A photomicrograph of an intervertebral disc and adjoining part of the spongiosa showing attenuation of the cartilage plate (C) at the site of impending prolapse (D). The latter part (D) is homogeneous in contrast to the more healthy peripheral part of the anulus fibrosus (H). The nucleus pulposus (N) shows wide fissures (F).

Fig. (6) : A photomicrograph showing a prolapse (P) with the cartilage plate ruptured (C). The cancellous bone (B) is fragmentary and no new bone formation is seen at the margin (M) of the prolapse. The tissue of the prolapse is obviously homogeneous.

Fig. (7) : A photomicrograph showing an early rupture of the cartilage plate (C). The site of rupture is marked by the arrow.

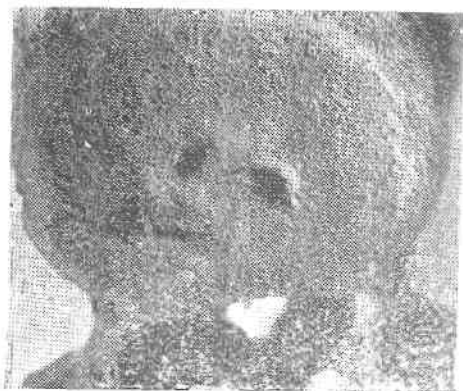

Fig. (1)

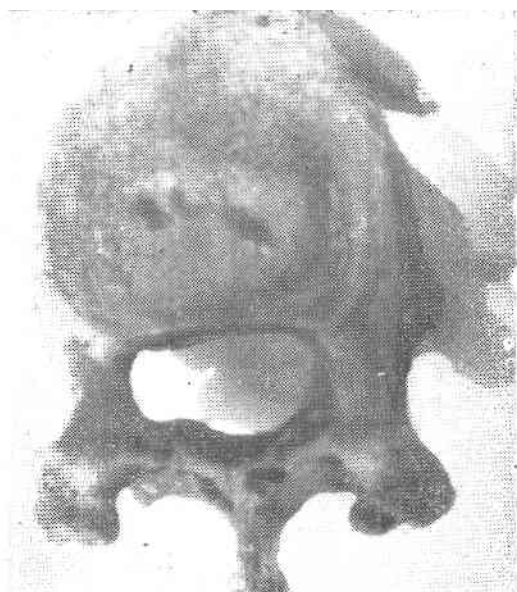


Fig. (2)

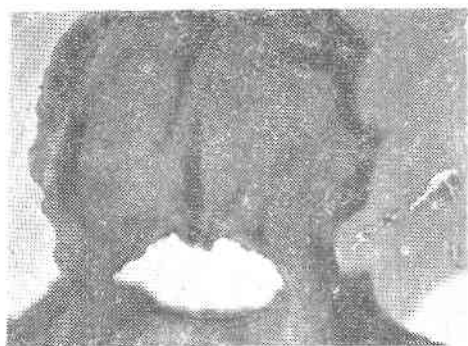

Fig. (3)

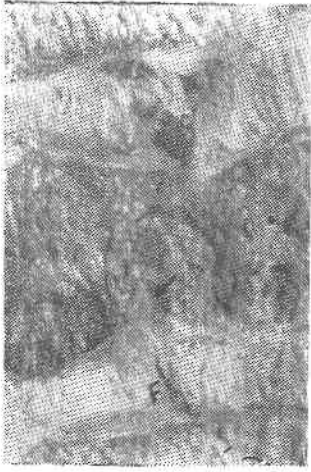


Fig. (4)

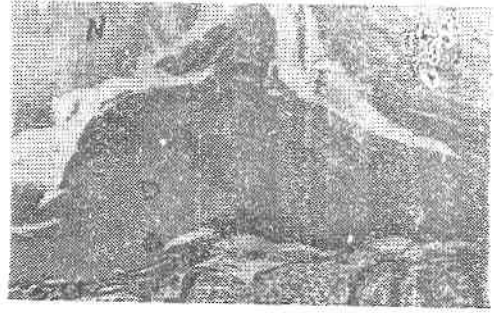


Fig. (5)




Fig. (6)



Fig. (7)