



EGYPTIAN ACADEMIC JOURNAL OF  
**BIOLOGICAL SCIENCES**  
**ZOOLOGY**


**B**



ISSN  
2090-0759

[WWW.EAJBS.EG.NET](http://WWW.EAJBS.EG.NET)

**Vol. 11 No. 3 (2019)**



## Evaluate Subchronic Toxic Effects of Repeated Exposure of Megadoses of Vitamin E in Male Albino Rats

Ahmad K. Hassan<sup>1</sup>, Eman E. ELaraby<sup>1</sup>, Heba N. Gad EL-Hak<sup>2</sup>, and Osama A. Abbas<sup>1</sup>

1-Zoology Department, Faculty of Science, Port said University, Port Said, Egypt.

2-Zoology Department, Faculty of Science, Suez Canal University, Ismailia, Egypt.

E.Mail: [Ahkhalaf71@yahoo.com](mailto:Ahkhalaf71@yahoo.com)

### ARTICLE INFO

#### Article History

Received:13/10/2019

Accepted:5/11/2019

#### Keywords:

Vitamin E,  $\alpha$ -Tocopherol, Subchronic, Liver function, Megadoses

### ABSTRACT

Vitamin E ( $\alpha$ -tocopherol) is a potent antioxidant and possesses an important role in deactivating free radicals in the cells and preventing the hazardous effects of reactive oxygen species thus stopping the lipid peroxidation process. However, the overdosing of a vitamin is toxic and leads to many harmful effects. The current work aimed to assess the potential subchronic toxicity of vitamin E megadoses for 90 days of treatment and after 45 days of recovery. Forty-seven male albino rats weighting (120-140 g) were used in this study and were divided into seven groups each of seven animals. The normal control group, three groups treated with (500, 1000, and 2000 mg/kg) of vitamin E for successive 90 days, and the last three groups were treated with the same doses and left 45 days for recovery. The results showed that higher doses of vitamin E had significantly increased liver enzymes ALT and AST, MDA, and altered hematological parameters. The toxicity was proportional to the dose and recovery period showed maintained liver toxicity while kidney regains their normal function. The study concluded that although vitamin E reported being a potent antioxidant, it is very toxic unless it had used within the range of recommended doses and should be used under the prescription of the physicians

### INTRODUCTION

Vitamins are organic compounds that are present naturally in most food and required for organisms due to their important role in the metabolism, vitality and growth processes (Hassan, 2012). Vitamin E has a multiple nature that began in 1936 when Evans *et al.* (1936) succeeded in isolating two active compounds from wheat germ oil,  $\alpha$ -tocopherol, and  $\beta$ -tocopherol. Since that time, numerous investigators have conducted studies of vitamin E (Rengaraj *et al.*, 2015). Vitamin E is a fat-soluble and strong antioxidant occurred in the cells, normally it accumulates in the mitochondria and endoplasmic reticulum membranes to protect against lipid peroxidation (Gavazza *et al.*, 2001). There are many natural food sources for providing vitamin E in significant amounts, fresh vegetables, nuts, seeds, and some oils in the most active form, alpha-tocopherol (Dietrich *et al.*, 2006). Shreds of evidence revealed that there are many different forms of vitamin E, eight lipid-soluble compounds, one of them is alpha-tocopherol which has a protective efficacy in cardiovascular diseases and the protection against reproductive damage (Tarber and Atkinson, 2007 and Devaraj *et al.*, 2008). Alpha-tocopherol intake in human and animal models has been shown to inhibit the lipid peroxidation process, decreasing the production of superoxides through impairing the

assembly of nicotinamide adenine dinucleotide phosphate oxidase and by downregulation of scavenger receptors (SR-A and CD36) expression in the cells. On the other hand, It was reported that the treatment with alpha-tocopherol, at high doses, in particular, inhibiting the release of the cytokines, IL-8 and the plasminogen activator inhibitor-1 (PAI-1) and decreasing the adhesion of monocytes to the endothelium (Singh *et al.*, 2005). Although vitamins are very significance for organisms, an extra supplement of vitamins can lead to their high storage in the bodies causing a toxic effect called hypervitaminosis or vitamin toxicity (Hassan, 2012).

It was reported that vitamins C and E are the most common in popular use as vitamin supplements (Vinson *et al.*, 2005). In Egypt, data collected and reported by the World Health Organization (WHO) since many years ago showed that the range of pharmaceutical preparations supplied to the peoples with or without be prescribed is similar (Benjamin *et al.*, 1996). In the face of supplementation with vitamin E at megadoses has been promoted to be adventitious to the aged people, there is no medical, scientific search certificate that this is correct (Gabriel *et al.*, 2008). In the fact, thousands of general population daily intake vitamin E in quantities that may be greater more times than recommended with a little proof of the predicted unwanted side effects (Machlin and Brin, 2008).

The current work aimed to investigate the safety margin for the vitamin E supplementation at different mega doses for 90 days and even after a recovery period of 45 days by using of pharmaceutical studies for achieving this target. These studies were involved with different biochemical parameters, ALT, AST, creatinine, urea, MDA, GSH and histological examination of liver and kidney.

## MATERIALS AND METHODS

### Experimental Animals:

Forty-seven male albino rats weighing 120-140 g were used in the present study and were obtained from the National Research Centre (NRC), Egypt. The animals were kept in polyethylene cages with well-aerated metal covers at normal environmental conditions ( $25\pm 5^{\circ}\text{C}$  and normal 12 hrs dark/light cycle) at the Animal House, Zoology Department, Faculty of Science, Port Said University, Port Said, Egypt. They were fed on commercial food pellets and daily provided with fresh tap water ad libitum. Animal care and maintenance were in accordance with the International Guiding Principles for Animal Research.

### Animal Grouping:

The animals were divided into seven groups (7 rats per group), treatment was orally for successive 90 days in all groups by using intragastric gavage, according to the following design:

Group I, animals was received distilled water. Group II, animals were treated with 500 mg/kg vitamin E. Group III, animals were treated with 1000 mg/kg vitamin E. Group IV, animals were treated with 2000 mg/kg vitamin E. Group V, animals were treated with 500 mg/kg vitamin E for successive 90 days and left 45 days for recovery. Group VI, animals were treated with 1000 mg/kg vitamin E for successive 90 days and left 45 days for recovery. Group VII, animals were treated with 2000 mg/kg vitamin E for successive 90 days and left 45 days for recovery.

### Vitamin E:

Vitamin E was in the form of (dl-alpha tocopherol acetate) and purchased from (Pharco Pharmaceutical Co., Egypt).

### Blood and Tissue Sampling:

Animals were sacrificed by decapitation under light anesthesia and blood samples were collected from animals in heparinized tubes for reduced GSH assay and EDTA tubes for

hematological parameter estimation, and into plain tubes for estimating the other biochemical parameters. The blood containing plain tubes were centrifuged at 5000 rounds per minute for 10 minutes and the serum was pipetted off and stored at -20°C until used. Soon after blood was collected, animals were dissected to obtain liver and kidney organs from each animal. After removing these organs, they were rinsed in saline (0.9% NaCl) as an isotonic solution for cleaning them from any excess of blood on their surfaces, then fixated in 10% formalin.

#### **Biochemical Assays:**

The serum urea concentration was determined using a commercial kit purchased from (BioMed diagnostics, Hannover, Germany, REF: URE 118240) according to manufacturer's instructions based on the method of Vassault *et al.* (1986). Serum creatinine concentration was estimated using the commercial kit of (Biodignostic, Dokki, Giza, Egypt, CAT.NO.CR 12,51) according to the colorimetric method of Bartels *et al.* (1972). Serum alanine aminotransferase (ALT) and aspartate amino transferase (AST) activities were measured by a colorimetric method using the commercial kit purchased from (Biodignostic, Dokki, Giza, Egypt, CAT.NO.AS10 31,45) according to the manufacturer's instructions and the method described by Reitman and Frankel, (1957). Reduced glutathione (GSH) was estimated in blood by a colorimetric method according to the steps described by the manufacturer (Sigma-Aldrich "Merck", Germany). Lipid peroxidation, malondialdehyde (MDA) was determined using a commercial kit of (Biodignostic, Dokki, Giza, Egypt, CAT NO.MD 25,29) according to the method of Ohkawa *et al.* (1979). All parameters were assayed using a spectrophotometer (Photometer 5010, Riele GmbH, Germany).

#### **Sections Preparation for the Histopathological Examination:**

The fixated organ samples were processed using standard histological methods. The samples after removing from the fixative were washed in running water overnight, dehydrated with an ascending series of ethyl alcohol, cleared in Terpeneol for two days, then embedded in three changes of pure paraffin wax to obtain paraffin blocks. The obtained paraffin blocks were cut with a microtome into about 5 microns thickness sections and mounted on clean glass slides, stained with hematoxylin and eosin (Lillie and Fuller, 1976). Finally, the slides were cleared by Xylene and mounted with DPX. The stained slides were examined and photographed by using the Axiostar Plus (Carl Zeiss, Göttingen, Germany) microscope supplied with Canon (PC 1200 Power shoot A641) digital camera and (Zoom Browser Ex) software at the central lab of the Zoology Department, Faculty of Science, Suez Canal University, Ismailia, Egypt.

#### **Statistical Analysis of Data:**

Results have been expressed as means  $\pm$  standard error (SE) for seven rats in each group (n=8). Tables and graphs were created using Microsoft Excel software. Data were statistically analyzed using the Statistical Package for Social Science (SPSS) version 18 software. The statistical significance of differences between groups was evaluated by using one-way analysis of variance (ANOVA) test which was followed by Post-hoc Duncan and Student's t-test. The obtained data were considered significant when the *P* values were  $\leq 0.05$ .

## **RESULTS**

#### **Hematological finding:**

The Result of the current study showed that the hemoglobin (Hb) level of the treated groups with vitamin E (500, 1000 and 2000 mg /kg) for 90 days was non-significantly increased with the dose 500 mg/kg of vitamin E ( $12.3 \pm 0.28$ ) compared to control ( $13.1 \pm 0.56$ ). Otherwise, Hb level was non-significantly decreased with (1000 and 2000 mg/kg) doses ( $12.1 \pm 0.09$  and  $11.9 \pm 0.19$ ). On the other hand, rats that treated for 90 days with the different doses of vitamin E (500, 1000, and 2000 mg/kg) and left for 45 days for

recovery showed a significant increase in the 500 mg/kg treated group ( $13.7\pm0.4$ ) and non-significant decrease in (1000 and 2000 mg/kg) treated groups ( $12.8\pm0.18$  and  $12.3\pm0.2$ ) in comparison with the control rats.

Total leukocyte count (TLC) was significantly increased in 2000 mg/kg, vitamin E treated group ( $10.9\pm1.2$ ) after 90 days of treatment and non-significantly increased in (500 and 1000 mg /kg) treated groups ( $8.1\pm.4$  and  $8.9\pm0.21$ ) compared with control (7.93). For recovery groups, TLC showed a non-significant increase in (2000 and 1000 mg/kg) treated groups (7.93 and  $8.3\pm0.7$ ) and non-significantly decreased in 500 mg/kg treated group ( $9.28\pm1.3$ ) compared with the control group.

Regarding platelets (PLT) count, it was significantly decreased in 2000 mg/kg, vitamin E treated group ( $398.5\pm6.6$ ) compared with control (600.2). PLT count after 45 days recovery period showed a non-significant increase in 2000 mg/kg treated group ( $398.5\pm6.6$ ) and a non-significant decrease in vitamin E (500 and 1000 mg/kg) treated groups ( $597\pm26.2$  and  $539\pm19.9$ ) compared with the control group (Table 1).

#### Biochemical Parameters:

##### Serum Urea Concentration:

Serum urea concentration was non-significantly increased in all treated groups with different doses of vitamin E (500, 1000 and 2000 mg/kg) for 90 days ( $22.3\pm0.38$ ,  $21.8\pm0.7$ , and  $23.4\pm0.7$  respectively) compared with control ( $21.6\pm0.65$ ). Otherwise, after the recovery period, the blood urea concentration was non-significantly decreased in all treated groups (500, 1000 and 2000 mg/kg) ( $22.1\pm0.49$ ,  $22.7\pm0.59$ , and  $22.49\pm0.58$  respectively) in comparison with the control group (Table 1).

##### Serum Creatinine Concentration:

The current data showed that the serum creatinine concentration in treated groups for 90 days was non-significantly increased with all doses of vitamin E (500, 1000 and 2000 mg/kg) ( $0.24\pm0.03$ ,  $0.26\pm0.031$ , and  $0.29\pm0.03$  respectively) compared with the control group ( $0.24\pm0.025$ ). As well as in the recovery groups creatinine concentration was non-significantly increased in all treated doses (500, 1000 and 2000 mg/kg) ( $0.27\pm0.025$ ,  $0.29\pm0.022$ , and  $0.30\pm0.014$  respectively) when compared with the control group (Table 1).

Table (1): Effect of treatment of vitamin E (500, 1000, 2000 mg/kg) on hematological and biochemical parameters of rats after 90 days of treatment and 45 days recovery.

Parameters Groups	Urea	Creatinine	ALT	AST	PLT x 10 <sup>3</sup> /mm <sup>3</sup>	TLC (x 10 <sup>3</sup> /mm <sup>3</sup> )	Hb (g/dl)
Control	21.6±0.4	0.24±0.25	51.1±4.6	113±1	600±36	7.93±0.85	12.21±.25
500 mg Vit E	22.3±0.3	0.24±0.03	56.3±2.8	120±1	597±26.3	8.1±0.4	12.3±0.3
1000 mg/kg Vit E	21.8±0.7	0.26±0.03	76±1.45*	173±9*	539±19	8.9±.21	12.1±1
2000 mg/kg Vit E	23.4±0.7	0.29±.03	94±2*	291±9*	398±6*	10.95±1.2*	11.9±0.2
500 mg Vit E (45 day Recovery)	22.1±0.5	0.27±0.02	53±2.5	128±4.9	597±10	9.28±1.3	13.7*±0.4
1000 mg/kg Vit E (45 day Recovery)	22.7±0.59	0.29±0.02	57±1*	133±6.2	527±10	7.11±.47	12.8±0.2
2000 mg/kg Vit E (45 day Recovery)	22.4±.58	0.3±0.01	68±1.4*	137± 6	674±31.68	8.30±.77	12.5±0.1

Values are expressed as a mean ± standard error (SE).

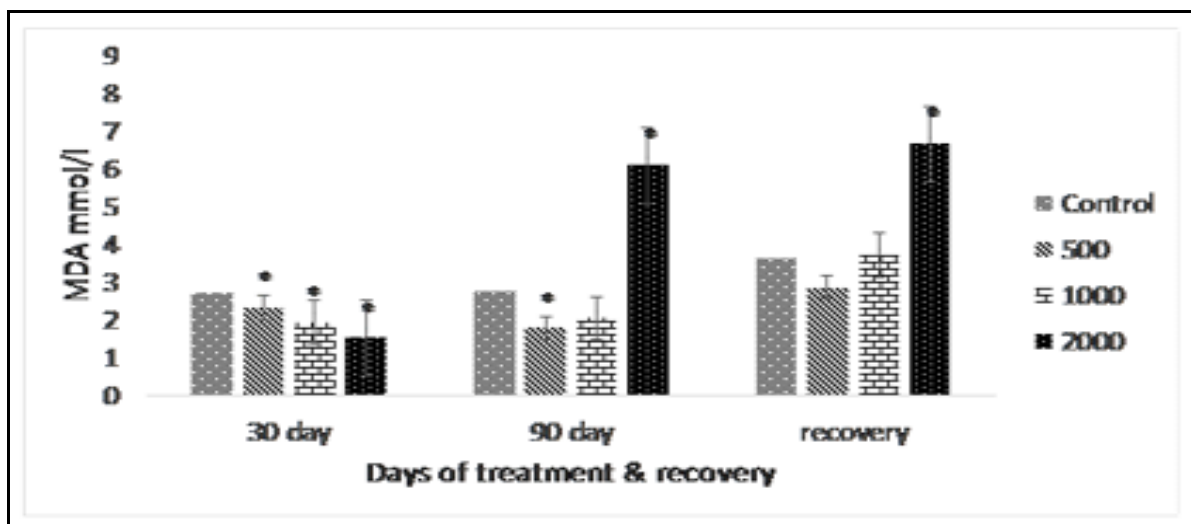
(\*) represents the significant differences between the corresponding control and treated groups using One Way ANOVA test when  $p<0.05$ .

### Liver Aminotransferases (ALT and AST) Activities in Serum:

ALT and AST activities were significantly increased at the doses (1000 and 2000 mg/kg) of vitamin E ( $76.3 \pm 1.45$  and  $94.6 \pm 2.01$ ) and ( $173.1 \pm 8.9$  and  $291.6 \pm 9.2$ ) compared with control ( $51.16$  and  $113 \pm 0.87$ ) while non-significantly increased in the 500 mg/kg treated group ( $56.3$  and  $120.8$ ) after 90 days of treatment. On the other hand, ALT in the recovery groups showed a significant increase in 2000 mg/kg treated group ( $68.16 \pm 1.4$ ) and a non-significant increase in (500 and 1000 mg/kg) treated groups ( $53.3 \pm 2.48$  and  $57.8 \pm 1.1$ ). AST activity in all groups (500, 1000 and 2000 mg/kg) was non-significantly increased ( $128.6 \pm 4.9$ ,  $133.8 \pm 6.29$ , and  $137.16 \pm 6.9$ ) after 45 days recovery in comparison with the control group (Table 1).

### Serum Malondialdehyde (MDA) Content:

MDA content after 90 days of treatment with vitamin E showed a significant increase at the dose 2000 mg/kg ( $6.09 \pm 0.46$ ), significant decrease at the dose 500 mg/kg ( $1.77 \pm 0.09$ ), and non-significant decrease at the dose 1000 mg/kg ( $2.04 \pm 0.04$ ) compared to control group ( $2.74 \pm 0.16$ ). On the other hand, after 45 days of recovery, MDA content was significantly increased in 2000 mg/kg treated group ( $6.67 \pm 0.28$ ), non-significantly increased in 1000 mg/kg treated group ( $3.72 \pm 0.557$ ), and non significantly decreased in 500 mg/kg treated group ( $2.86 \pm 0.99$ ) compared with the control group (Fig. 1).

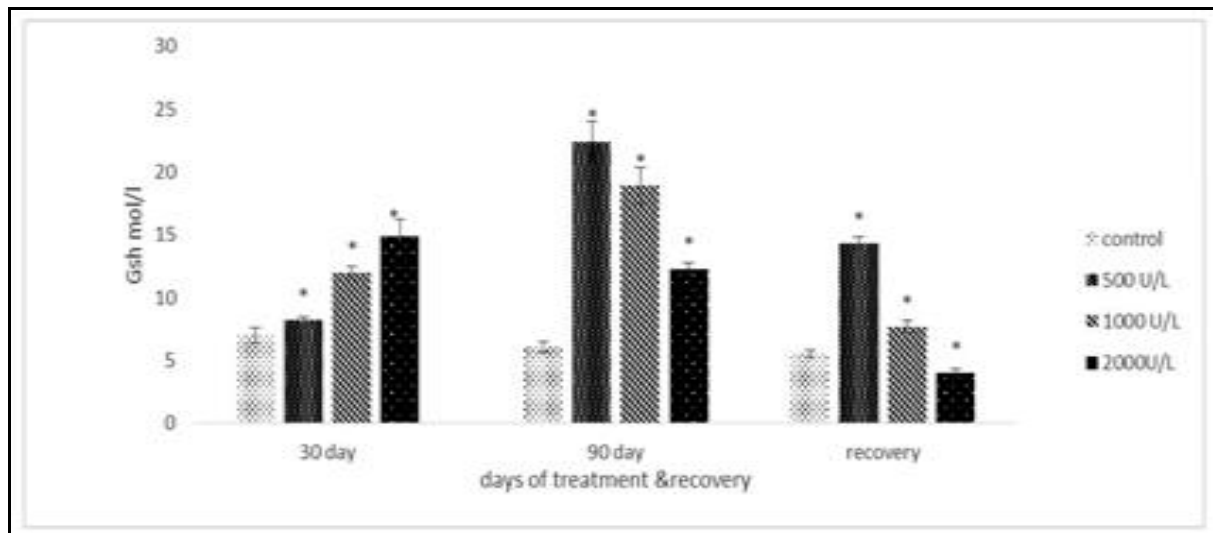


**Fig.1:** Effect of vitamin E (500, 1000, 2000 mg /kg) on lipid peroxidation malondialdehyde (MDA) content (mmol/l) of the rats at different duration time (30, 90 days) and recovery.

(\*) represents a significant difference between the corresponding control and treated groups, using One Way ANOVA test ( $p < 0.05$ ).

### Glutathione Reduced (GSH) Serum Content:

GSH revealed a significant increase after 90 days of vitamin E treatment with all doses (500, 1000 and 2000 mg/kg) ( $22.43 \pm 1.65$ ,  $18.93 \pm 1.41$ , and  $12.3 \pm 0.46$  respectively) in comparison with the control group ( $6.1 \pm 0.46$ ). On the other hand, GSH after 45 days recovery was significantly increased in (500 and 1000 mg/kg) treated groups ( $14.3 \pm 0.53$  and  $7.7 \pm 0.48$ ) and significantly decreased in 2000 mg/kg treated group ( $4.04 \pm 0.31$ ) in comparison with the control group (Fig. 2).



**Fig. 2:** Effect of vitamin E (500, 1000 and 2000 mg /kg) on glutathione (GSH) content (mg/dl) of the rats at different duration time (30 and 90 days) and recovery.

(\*) represents a significant difference between the corresponding control and treated groups, using One Way ANOVA test ( $p < 0.05$ ).

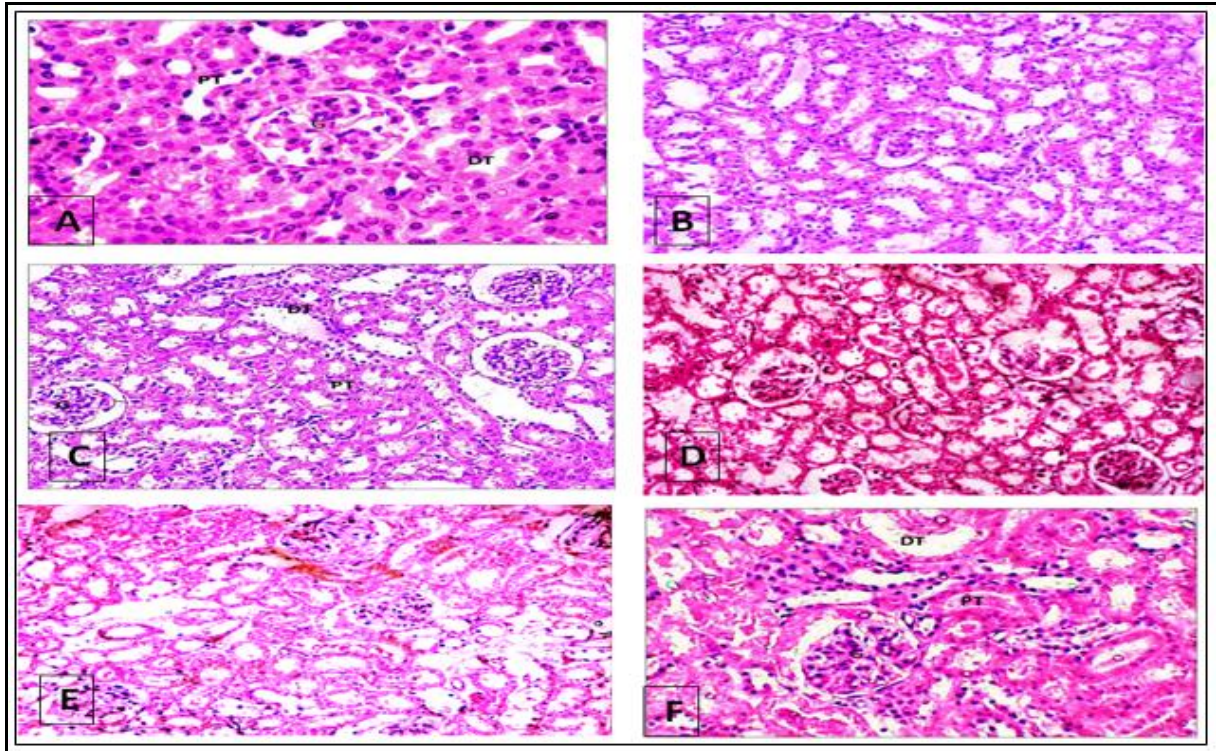
### **Histological Examination:**

#### **The Kidney:**

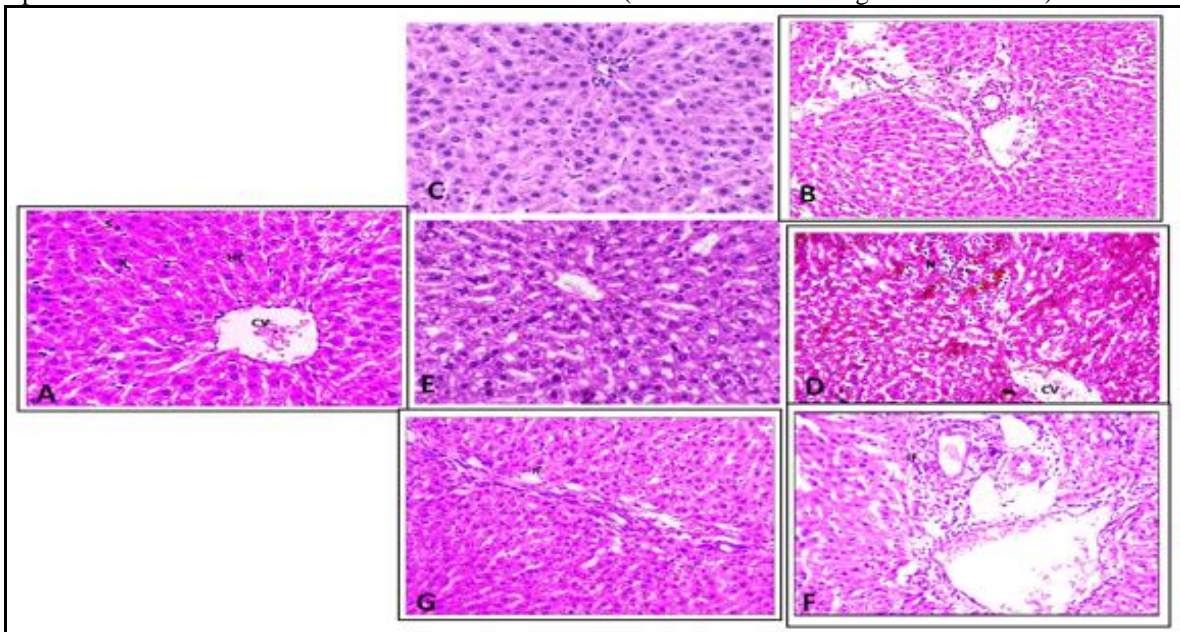
Histological examination of the kidney of normal control rats showed a normal structure of the kidney which consists of a huge number of urineferous tubules, the nephron, and the collecting tubules. The nephron is built up of Malpighian corpuscle and the nephric tubules. Nephric tubules are the proximal convoluted tubule, descending and ascending loop of Henle, and distal convoluted tubules. The outer wall of Bowman's capsule is composed of a single layer of simple squamous epithelia. The proximal convoluted tubular pyramidal cells are marked with basophilic cytoplasm. The distal convoluted tubules have a wide lumen bordered of cubical or low columnar epithelial cells with basally located basophilic nuclei. The collecting tubules are lined with simple cuboidal or columnar epithelium with a relatively clear cytoplasm. Histological examination of the kidney of rats after 90 days of vitamin E treatment with daily doses (1000 and 2000 mg/kg) showed slightly abnormal renal corpuscles with mild atrophic glomerulus and mild glomerulonephritis. Some of the proximal tubules showed a foamy appearance and in the others, protein casts could be seen. Convoluted proximal and distal tubules are dilated and slightly degenerated with pyknotic nuclei. For recovery groups, kidneys of rats that received (500, 1000, and 2000 mg/kg) vitamin E for 90 days and left 45 days for recovery showing the absence of any signs of histopathological damage (Fig 3).

#### **The Liver:**

Histological examination of the liver of normal control rats showed a normal hepatic architecture composed of polygonal hepatic cells, which are radiating around the central vein and forming hepatic strands. The cells are in alternation with blood sinusoids. The sinusoids contain phagocytic cells of the mononuclear type; Von Kupffer cells. Outside of the lobules at certain angles, portal islands of connective tissue are present, each contains a branch of the hepatic portal vein, hepatic artery, and a bile duct. After treatment with vitamin E for 90 days with daily doses (500, 1000 and 2000 mg/kg), liver tissues showed hydropic degeneration at the central and portal areas with a microvesicular fatty degeneration, focal necrosis, and increased infiltration with inflammatory cells mainly in the portal area. After 45 days for recovery, congestion of sinusoid, dilated blood vessel, increased kupffur cells, focal necrosis with pyknotic nucleus and infiltration with inflammatory cells could be observed (Fig 4).



**Fig. 3:** Photomicrograph of the kidney of rats after treatment with vitamin E for 90 days and after 45 days of recovery. **A)** Normal control with normal kidney structure. **B)** 500 mg/kg treated group with normal structure. **D)** 1000 mg/kg treated group showed mild glomerular atrophy and mild necrotic dilated and degenerated tubules. **C)** 1000 mg/kg treated group and after recovery showed normal kidney structure. **E)** 2000 mg/kg treated group showing glomerulonephritis with a large cellular crescent forming a cap over the glomerular tuft and degenerating tubules. **F)** 2000 mg/kg treated group after recovery showing glomerulonephritis and presence of protein casts with dilation of distal convoluted tubules. (HX& E stain and magnification X400).



**Fig. 4:** Photomicrograph of the liver of rats after treatment with vitamin E for 90 days and after 45 days of recovery. **A)** Normal control with normal liver structure. **B)** 500 mg/kg treated group showing mild infiltration of inflammatory cells in the portal area. **C)** 500 mg/kg treated group after recovery showing normal hepatocytes and a portal area contain a branch of the portal vein. **D)** 1000 mg/kg treated group showing focal necrosis with a pyknotic nucleus around the central vein. **E)** 1000 mg/kg treated group showing hydropic degeneration of the hepatocyte. **F)** 2000 mg/kg treated group showing severe infiltration of inflammatory cells in the portal area **G)** 2000 mg/kg treated group after recovery showing mild infiltrations of inflammatory cells around the portal area. (HX& E stain and magnification X400).



## DISCUSSION

Vitamin E supplements have many regular uses for medical purposes especially by patients with cardiovascular disorders, muscular dystrophies, dermal diseases, infertility and cancer (Miller *et al.*, 2005). Although the undesirable side effects of vitamin E hypervitaminosis due to, a recent study of Gussak *et al.* (2018) reported that the mega- doses of vitamin E supplementation had adverse effects. In the present study, three megadoses of vitamin E were used via subchronic oral administration to adult male albino rats to assess their toxicity or potential side effects.

The hematological parameters can be used to assess the health or pathological conditions and nutritional state of the animals (Ajayi and Raji 2012). So, the hemopoietic system is one of the most sensitive targets of toxic compounds and an important index of physiological and pathological states in both humans and animals (Risitano *et al.*, 2007). In the current study, treatment with vitamin E showed a significant increase in hemoglobin (Hb) content only in (500 mg/kg) treated group and after 45 days recovery, while non-significantly decreased in (1000 and 2000 mg/kg) treated groups for 90 days of treatment and after 45 days recovery in the comparison with control group. The increase in Hb content after treatment with the lowest dose of vitamin E (500 mg/kg) might be due to its antioxidant effects (George and Adegoke, 2012). A study by Abdo *et al.* (1986) revealed that treatment with a high dose of vitamin E (2000 mg/kg) for 13 weeks caused a decrease in hematocrit values and Hb concentrations. These findings revealed that treatment with vitamin E at high doses for a prolonged time could be potentially toxic. Total leukocyte count (TLC) in the groups that received doses of vitamin E for 90 days showed a significant increase with the dose (2000 mg/kg) and non-significant increase with the doses (500 and 1000 mg/kg), while TLC showed non-significant changes in the recovery groups in comparison with the control. The significant increase in TLC may be responding to the inflammation which had shown in the histopathological examination of the liver tissues after treatment with high doses in particular. Regarding Platelets (PLT) count, it was significantly decreased in (2000 mg/kg) treated groups, non-significantly decreased with the other doses (500 and 1000 mg /kg). However, after the recovery period, PLT count was non-significantly changed. Studies on healthy humans after vitamin E daily supplementation showed no changes in platelet aggregation or number (Steiner, 1993). Conversely, Jandak, *et al.* (1989) reported that they were markedly reduced following vitamin E intake at a dose of 400 mg/kg for 2 weeks. Tocopherol intake was reported to have a blood-thinning effect and reducing the ability of blood coagulation function through decreasing platelets aggregation (Pastori *et al.*, 2013).

Toxicity occurred on the kidneys is investigated by detecting tissue damage or elevation in the parameters of their excretory function (Cobbina *et al.*, 2015). Determination of serum urea and creatinine concentrations are usually perfect in the evaluation of the kidney function (Levey *et al.*, 1999). Serum urea and creatinine concentrations in the current study showed non-significant changes after 90 days of treatment with vitamin E with the different doses and also after 45 days of recovery compared with control. On the other hand, the microscopic histopathological examination of the kidney tissues after vitamin E treatments revealed normal kidneys structure, even in high doses except mild changes were seen but completely disappeared after recovery. The current results were in a line with Dietrich *et al.* (2006) who revealed that serum creatinine was unaffected by vitamin E treatment even with high doses. Conversely, a study of Ima-Nirwana *et al.* (2012) reported that serum creatinine was increased in their subchronic toxicity study and kidney weights were increased after treatment with Vitamin E (500 mg and 1000 mg/kg) and they suggested further studies to confirm these data.

ALT and AST are liver enzymes and considered as good indicators for the

determination of the liver function. The liver is the main target organ for vitamin E and other foreign substances being absorbed from the intestines in which they are metabolized to other active or non-active compounds (Tarber, 2013 and Kayden and Traber, 1993). So, the increase in the hepatic enzymes might be due to the hazard effects of a certain compound that could have potential liver toxicity that may be increased by dose leading to liver injury. In the current study, ALT and AST were significantly increased following treatment with (1000 and 2000 mg/kg) of Vitamin E for 90 days and still increased after recovery in comparison with the control group. ALT and AST activities are increased, according to Kim *et al.* (2011) in the cases of hepatocellular injury or death. A study by Dietrich *et al.* (2006) has reported that serum and liver vitamin E levels increased progressively with high doses of vitamin E after 13 weeks with an increase in liver enzymes. Where liver enzymes have not regained their normal values after 45 days of recovery, which indicated that higher doses of vitamin E have toxic hepatic effects and prolonged even after the drug discontinuation. These findings were in line with the provided histological examination of the liver which revealed that that rats have received 1000 and 2000 mg/kg of vitamin E for 90 days and after recovery showed some histological changes in the liver. These histological changes were marked hydropic degeneration and infiltration of inflammatory cells. The hepatocytes of the liver in the groups of rats that received high doses of vitamin E showed hydropic degeneration. The same finding was observed by Oudea *et al.* (1973) who explained that the hydropic degeneration was a response of excess water influx to the cells, which could be due to mitochondrial damage that leads to the entrance of sodium ions into the cells and consequently water accumulation. Subchronic study on animals treated with vitamin E, in the form dl-tocopheryl acetate, reported that the treated animals had massive organ hemorrhages and quit injury where liver tissues showed the presence of vacuolated lipid staining macrophages (Wheldon *et al.*, 1983).

MDA is the end product of the reactions that lead to the oxidation of the unsaturated fatty acids, so, it is an important biomarker of oxidative stress in the lipid peroxidation process (Gutteridge, 1995 and Ewelina *et al.*, 2019). Vitamin E is an important fat-soluble chain-breaking antioxidant that neutralizes the free radicals and protecting against lipid peroxidation for maintaining the membranes of living cells (Turgut *et al.*, 2006). Moreover, many antioxidants such as vitamin E, vitamin C, reduced glutathione (GSH), coenzyme Q10 (ubiquinone) and selenium may act synergically in preventing lipid peroxidation and cell degeneration (Lass and Sohal, 2000). In the present study, after treatment for 90 days with vitamin E (500, 1000, 2000 mg/kg) the lipid peroxidation (MDA) showed a significant increase with the dose 2000 mg/kg and significantly decreased in 500 mg/kg group, while non-significantly decreased with the dose 1000 mg/kg. In the recovery groups, MDA showed a significant increase only in 2000, mg/kg group and a non-significant decrease in 500 and 1000 mg/kg groups. Vitamin E, a strong fat-soluble antioxidant occurs in the cell, accumulated naturally in the membranes of cell organelles like mitochondria and endoplasmic reticulum and protects cells against lipid peroxidation (Matés *et al.*, 1999). In this case, vitamin E scavenges free radicals to preserve cell membrane functions such as ion transport and membrane fluidity and potentially diminishing the rate of lipid peroxidation (Chun-Chung *et al.*, 2018). This antioxidant function of the vitamin was clearly recognized with the lowest dose (500 mg/kg) in this study, while after treatment with the highest dose (2000 mg/kg) and after recovery, the exactly opposite has happened. Likewise, a study of Mascio *et al.* (1991) revealed that daily supplementation with vitamin E at high doses exceeding 1000 mg/kg had oxidant effects which are opposite of its antioxidant properties, potentially leading to oxidative stress (Rizvi *et al.*, 3014).

The current study revealed that GSH content after vitamin E treatment for 90 days was significantly increased with all doses (500, 1000 and 2000 mg/kg). Also, GSH was

significantly increased in (500 and 1000 mg/kg) treated groups while significantly decreased in 2000 mg/kg treated group after 45 days of recovery. Cells have a biological defense system for fighting oxidative stress process such as the antioxidant enzymes glutathione reductase and transferase, superoxide dismutase (SOD), and catalase as well as the non enzymatic antioxidants such as vitamins E and C, carotenoids, and GSH that can also act to vanquish such oxidative stress (Somia and Hamdy, 2012). The treatment with vitamin E is helpful in maintaining the erythrocyte GSH concentration at the normal levels due to its protective role (Ognjanoivc' *et al.*, 2003). In addition, rats treated with low doses of vitamin E showed an increase in the antioxidant enzyme activity and GSH level accompanied by an inhibition of lipid peroxidation, this may be due to that vitamin E eliminate free radicals and preserve cell membrane stability and fluidity by maintaining the sulfhydryl groups of the membrane proteins and decreasing the rate of lipid peroxidation (Mittal and Flora, 2007). The decreased GSH content in the 2000 mg/kg treated group might be due to the oxidative stress resulted from the toxicity of the high dosage intake and the consumption of GSH as one of the antioxidant defense systems. Lu, (2009) reported that the synthesis of GSH could be impaired due to different pathological disorders, one of them is a more alive injury. The present work has revealed that the treatment with 2000 mg/kg of vitamin E had toxic effects to the liver, so we suggested that could be another explanation for decreasing of GSH level with that dose.

Meta-analysis of several studies on vitamin E intake concluded that it is unlikely has a mortality regardless of dose (Berry *et al.*, 2009), in addition, supplementation with vitamin E should not be recommended as beneficent for longevity (Erin *et al.*, 2011). Till now the studies on the toxicity of vitamin E hypervitaminosis are insufficient and vitamin E in addition to all other vitamin toxicity should be studied in detail to assess their risks regardless of benefits. In conclusion, the current study revealed that the rats which had subjected to excess vitamin E for prolonged periods (subchronic treatment) with megadoses developed many hazards and toxic effects which have been sustained even after drug discontinuation. Such toxicity was reported mainly in the liver and some degree in hematological parameters while no toxicity was reported in the kidney even at high doses of treatment. So, vitamin E should be used in appropriate doses to avoid its toxicity and under continuous investigations during the treatment period and after discontinuation until recovery.

## REFERENCES

- Abdo KM, Rao G, Montgomery CA (1986). Thirteen week toxic study of d-tocoperyl acetate (vitamin E) in Fischer 344 rats. *Fd Chem Toxic* 24: 1043-1050.
- Ajayi Ayodeji F, and Raji Y (2012) *African Journal of Biotechnology* Vol. 11(35), pp. 8730-8734.
- Bartles H, Bohmer M and Heierli C (1972) Serum creatinine determination without protein precipitation. *Clinica Chimica Acta* 37: 193-197.
- Benjamin H, Smith F, and Motawi, UA (1996) Drugs dispensed with and without a prescription from community pharmacies in a conurbation in Egypt. *EMHJ - Eastern Mediterranean Health Journal*, 2 (3), 506-514.
- Berry D, Walthen JK and Newell M (2009) Bayesian model averaging in meta-analysis: vitamin E supplementation and mortality rate. *Clin Trials*. 6:28–41.
- Chun-Chung C, Yu-Chi S, Glen D, Chung-Yu C and Yi-Hung L (2018) Short-Term High-Dose Vitamin C and E Supplementation Attenuates Muscle Damage and Inflammatory Responses to Repeated Taekwondo Competitions: A Randomized Placebo-Controlled Trial. *International Journal of Medical Sciences*, 15(11): 1217-1226. doi: 10.7150/ijms.26340.
- Cobbina SJ, Chen Y, Zhou Z, Wu X, Zhao T, Zhang Z, Feng W, Wang W, Li, Q, Wu, X, et al (2015) Toxicity assessment due to sub-chronic exposure to individual and mixtures of

- four toxic heavy metals. *J. Hazard. Mater.* 294, 109–120.
- Devaraj S, Tang R, Adams-Huet B (2008) Effect of highdose alpha-tocopherol supplementaon on biomarkers of oxidave stress and inflammaon and carod atherosclerosis in paents with coronary artery disease. *Alterna veMedicine Review*, 13: 78-9.
- Di MP, Murphy ME and Sies H (1991) Antioxidant defense systems: the role of carotenoids, tocopherols, and thiols. *Am J Clin Nutr.* Jan;53(1Suppl):194S-200S.
- Dietrich M, Traber MG, Jacques PF, Cross CE, Hu Y, Block G (2006) Does  $\gamma$ -tocopherol play a role in the primary prevention of heart disease and cancer? A review. *Am J Coll Nutr*, 25:292-9. [PubMed abstract]
- Erin L, Abner MPH, Frederick A, Schmitt Marta S, Mendiondo D, Jennifer L, Marcum PH and Richard JK (2011) Vitamin E and all-cause mortality: A meta-analysis. *Curr Aging Sci.*4(2): 158–170.
- Evans HM, Emerson OH and Emerson GA (1936) The isolation from wheat germ oil of an alcohol,  $\alpha$ -tocopherol, having the properties of vitamin E. *J. Biol. Chem.* 113:319–332. doi: 10.1111/j.1753-4887.1974.tb06280.x. [PubMed]
- Ewelina R, Arleta M, Iwona C and Aleksandra MS (2019) Mitochondria Are Important Determinants of the Aging of Seeds. *Int J Mol Sci.* 2019 Apr; 20(7): 1568.
- Gabriel E, Machlin LJ, Filipski R, Nelson J (1980) Influence of age on the vitamin E requirement for resolution of necrotizing myopathy. *J Nutr*, 110:1372-1379.
- Gavazza M, Catala A. The effect of alpha-tocopherol on the lipid peroxidation of mitochondria and microsomes obtained from rat liver and testis (2001). *Mol Cell Biochem*, 225: 121-128.
- George MI and Adegoke AO (2012) Effect of Vitamin E on Haematological Parameters in Albino Rats Treated with Gasoline. *J. Sci. Res.* 4 (2), 437-444.
- Gutteridge JMC (1995) Lipid peroxidation and antioxidants as markers of tissue damage. *Clin Chem.*41:1819–28. [PubMed].
- Hassan BA (2012) Vitamins (Importance and Toxicity). *Pharmaceut Anal Acta* 3:e125. doi:10.4172/2153-2435.1000e125.
- Ima-Nirwana S., Nurshzawni, Y. Nazrun, A.S., Norliza, M. Norazlina, M. (2011) Subacute and subchronic toxicity studies of palm vitamin E in mice. *Journal of Pharmacology and Toxicology* 6(2): 166-173.
- Jandak JI, Steiner M, Richardson PD (1989) Alpha-tocopherol, an effective inhibitor of platelet adhesion. *Blood.* 1989 Jan;73(1):141-9.
- Kayden HJ and Tarber MG(1993) Absorption, lipoprotein transport, and regulation of plasma concentrations of vitamin E in humans. *Journal of lipid research*, 34, 343-358.
- Kim HY, Park J, Lee KH, Lee DU, Kwak JH, Kim YS, Lee SM (2011) Ferulic acid protects against carbon tetrachloride-induced liver injury in mice. *Toxicology* 282:104–111.
- Lass A and Sohal RS (2000) Effect of coenzyme Q10 and alpha-tocopherol content of mitochondria on production of superoxide anion radicals. *FASEB J* 14: 87-94.
- Levey AS1, Bosch JP, Lewis JB, Greene T, Rogers N, Roth D (1999) A more accurate method to estimate glomerular filtration rate from serum creatinine: a new prediction equation. Modification of Diet in Renal Disease Study Group. *Ann Intern Med.* 16;130(6):461-70.
- Lillie R and Fuller, H (1976) *Histopathologic technique and practical histochemistry.*Mc Graw- HillNew York.
- Lu SC (2009) Regulation of glutathione synthesis. *Molecular aspects of medicine.* 30(1-2), 42–59. doi:10.1016/j.mam.2008.05.005.
- Machlin LJ, Brin M, Vitamin E In (1980) Alfin-Slater RB, Kritchevsky D, eds. *Human nutrition.* Vol. 3B, Nutrition and the adult: micronutrients. New York: Plenum Press, 1980:245-266.

- Mates' JM, Cristina S, MEZ R and De Castro I (1999) Antioxidant Enzymes and Human Diseases. *Clinical Biochemistry*, Vol. 32, No. 8, 595–603
- Miller ER, Pastor-Barriuso R, Dalal D, Riemersma RA, Appel LJ and Guallar E (2005) Meta-analysis: high-dosage vitamin E supplementation may increase all-cause mortality. *Ann Intern Med*.4;142(1):37-46. Epub 2004 Nov 10.
- Mittal M and Flora SJ (3007) Vitamin E supplementation protects oxidative stress during arsenic and fluoride antagonism in male mice. *Drug Chem Toxicol* 2007;
- Ognjanovic BI, Pavlovici SZ, Maletic SD, éIkic RV, äTajn A, Radojicic RM, Saicic ZS, Petrovic VM (2003) Protective Influence of Vitamin E on Antioxidant Defense System in the Blood of Rats Treated with Cadmium. *Physiol. Res.* 52: 563-570.
- Ohkawa H, Ohishi N and Yagi K (1979) Assay for lipid peroxides in animal tissues by thiobarbituric acid reaction. *Anal Biochem.* 1979 Jun; 95(2):351-8. DOI: 10.1016/0003-2697(79)90738-3.
- Oudea MC, Collette M. and Oudea P (1973) Morphometric study of the ultrastructure changes induced in rat liver by chronic alcohol intake. *Dig. Dis.*, 18 (5):398 – 402.
- Pastori D1, Carnevale R, Cangemi R, Saliola M, Nocella C, Bartimoccia S, Vicario T, Farcomeni A, Violi F and Pignatelli P (2013) Vitamin E serum levels and bleeding risk in patients receiving oral anticoagulant therapy: a retrospective cohort study. *J Am Heart Assoc.* 28;2(6):e000364. doi: 10.1161/JAHA.113.000364.
- Reitman S and Frankel S. (1957) A colorimetric method for the determination of serum glutamic oxalacetic and glutamic pyruvic transaminases. *Am J Clin Pathol.* 1957 Jul;28(1):56-63. DOI:10.1093/ajcp/28.1.56
- Rengaraj D and Ho Hong Y (2015) Effects of Dietary Vitamin E on Fertility Functions in Poultry Species *International Journal of Molecular Sciences*, 16:9910-9921. doi:10.3390/ijms16059910 .
- Risitano AM, Maciejewski JP, Selleri C, Rotoli B (2007) Function and malfunction of hematopoietic stem cells in primary bone marrow failure syndromes. *Curr Stem Cell Res Ther.* 2(1):39-52.
- Rizvi S, Raza ST, Ahmed F, Ahmad A, Abbas S, Mahdi F (2014) The role of vitamin E in human health and some diseases. *Sultan Qaboos Univ Med J.* 14(2):e157–e165.
- Singh U, Devaraj S, Jialal I (2005) Vitamin E, oxidave stress, and inflammaon. *Annu Rev Nutr*, 25: 151-74.
- Somia El Maghraby and Hamdy A. T (2012) Amelioratory effects of vitamin E against biochemical toxicity induced by deltamethrin in male rats. *Journal of the Arab Society for Medical Research*, 7:92–96.
- Steiner M (1993) Vitamin E: more than an antioxidant. *Clin Cardiol* 16: 16-18.
- Tarber M G (2013) Mechanisms for the prevention of vitamin E excess. *Journal of Lipid Research*, 54, 2295-2306.
- Traber MG and Atkinson J (2007) Vitamin E, antioxidant and nothing more *Free Radic Biol Med*, 43: 4-15.
- Turgut G, Enli Y, Kaptanoglu B, Turgut S and Genc O (2006) Changes in the levels of MDA and GSH in mice serum, liver and spleen after Aluminium administration. *East J Med* 2006;11:7-12.
- Vassault A, Grafmeyer D, Naudun C, et al. (1986) Protocole de validation de techniques (document B, stade 3). *Ann Biol Clin* 1986;44:686-745.
- Vinson JA, Al Kharrat H, Andreoli L (2005) Effect of Aloe vera preparations on the human bioavailability of vitamins C and E. *Phytomedicine.* Nov;12(10):760-5.
- Wheldon GH, Bhatt A, Keller P, Hummler H (1983). d,1-alpha-Tocopheryl acetate (vitamin E): a long term toxicity and carcinogenicity study in rats. *Int J Vitam Nutr Res* 53: 287-296.

## ARABIC SUMMARY

تقييم التأثيرات السمية للتعرض المتكرر للشبة مزمن لجرعات كبيرة من فيتامين E على ذكور الجرذان البيضاء

احمد خلف محمد حسان<sup>1</sup>, ايمان السيد العربي<sup>1</sup>, هبة ناجح جاد الحق<sup>2</sup>, اسامة احمد عباس<sup>1</sup>

<sup>1</sup>-قسم علم الحيوان-كلية العلوم-جامعة بورسعيد - بورسعيد

<sup>2</sup>- قسم علم الحيوان-كلية العلوم-قناة السويس - الاسماعيلية

فيتامين (E) (توكوفيرول) هو أحد مضادات الأكسدة القوية وله دور مهم في إلغاء تنشيط الجذور الحرة في الخلايا ومنع الآثار الخطرة للأكسجين النشط وبالتالي إيقاف عملية اكسدة الدهون. ومع ذلك ، فإن جرعة زائدة من الفيتامين سامة وتؤدي إلى العديد من الآثار الضارة. يهدف العمل الحالي إلى تقييم السمية المحتملة لجرعات عالية من فيتامين (E) لمدة 90 يوماً من العلاج وبعد 45 يوماً من إيقاف التعرض. تم استخدام سبعة وأربعين ذكراً من الجرذان البيضاء (120-140 جم) في هذه الدراسة وتم تقسيمها إلى سبع مجموعات لكل منها سبعة حيوانات. مجموعة الضابطة، ثلاث مجموعات عولجت بـ (500 ، 1000 ، و 2000 ملجم / كجم) من فيتامين E لمدة 90 يوماً متتالية ، وعولجت المجموعات الثلاث الأخيرة بنفس الجرعات وتركت 45 يوماً للشفاء. أظهرت النتائج أن جرعات العالية من فيتامين (E) زادت بشكل كبير من إنزيمات الكبد ALT و AST ، و MDA ، وغيّرت تحاليل الدم. زادت السمية مع زيادة الجرعة وأظهرت فترة الشفاء عدم تعافى الكبد في حين استعادة الكلى وظائفها الطبيعية. وخلصت الدراسة إلى أنه على الرغم من أن فيتامين (E) ذكر أنه مضاد للأكسدة ، إلا أنه سام للغاية ما لم يستخدم ضمن نطاق الجرعات الموصى بها ويجب استخدامه تحت وصفاة الأطباء.