

UPDATES IN LAMINOPLASTY TECHNIQUES FOR TREATMENT OF MULTILEVEL CERVICAL STENOSIS

By

**Mohammed Hosam Eldin Abo Shahba, Hedaya Mohamed Hendam,
Ahmed Mohamed Taha, and Abd-Allah Mohamed Abd-Alwahab Slama**

Department of Neurosurgery, Faculty of Medicine (Damietta), Al-Azhar University

ABSTRACT

Background: The main goal of laminoplasty is to provide decompression of the spinal cord by widening the spinal canal, and used to gain wide access to the spinal canal to perform additional procedures, e.g. adequate dissection around the dural tube, duraplasty, and removal of spinal cord tumor.

Objective: A cross sectional cohort study to assess effectiveness and safety of laminoplasty in treatment of multilevel cervical canal stenosis and comparison of different techniques.

Patients and Methods: We studied 20 patients with multilevel cervical canal stenosis undergoing cervical laminoplasty. All patients were subjected pre-operatively to full general and neurological clinical assessment, routine laboratory work and neuroimaging by plain X-ray, CT scan and MRI cervical spine.

Results: This study included 20 patients (14 males and 6 females) and the mean age was 48.9 years. There were 7 patients with history of HTN and 5 patients with history of DM. There was a significant improvement post-operatively of Nurick grade score, Japanese Orthopedic Association scores and neck pain visual analog scale score.

Conclusions: Laminoplasty is becoming an increasingly popular treatment for multilevel cervical stenosis due to cervical spondylotic myelopathy. Laminoplasty minimizes the risk of certain complications associated with other surgical options, such as graft and fusion-related complications.

Keywords: Multilevel cervical stenosis, Laminoplasty.

INTRODUCTION

While multilevel cervical stenosis may occur for a variety of reasons, it is usually due to cervical spondylotic myelopathy (CSM) or ossification of the posterior longitudinal ligament (OPLL) (Mitsunaga et al., 2012). The goals of operative intervention in the treatment of

cervical spondylotic myelopathy include:

(a) decompression of the spinal cord and nerve roots, (b) deformity prevention by maintaining or supplementing spinal stability, and (c) alleviating pain. Achieving these goals will translate into improved clinical outcomes with stabilization or reversal of neurologic deficits, decreased pain, and maximal

functional restoration (Lebl *et al.*, 2011). Operative treatment of cervical spinal stenosis is recommended for patients who have either substantial or progressive impairment of neurologic function or failed conservative management, especially if myelopathy has been present for six months or longer (Praveen *et al.*, 2009)

In the original description, the open-door laminoplasty is kept open with a suture technique. Sutures are placed at each level through the base of the spinous process and then through the zgapophyseal articular capsule and surrounding muscle fascia on the hinge side. Closure of the laminoplasty using suture technique was reported. This prompted the development of a variety of methods using auto- or allograft, hydroxyapatite, glass ceramic and custom-made minititanium plates to act as spacers to keep the lamina in the open position (Gabriel *et al.*, 2015).

In expansive open-door laminoplasty technique, a hinge is created on one side of the lamina-spinous process-ligamentum flavum complex. This allows the roof of the canal to be opened on the contralateral side leading to an expansion of the spinal canal (Mitsunaga *et al.*, 2012). In double-door laminoplasty, the opening is created in the midline and expands the canal symmetrically. This is accomplished by splitting the spinous process in the midline with left and right hemi laminae hinging on the lamina-spinous process-ligamentum flavum complex bilaterally (Masayuki *et al.*, 2013).

Muscle-Sparing Laminoplasty Techniques; Stephan *et al.* (2015) described a

technique designed to minimize damage to the deep extensor muscles of the cervical spine and the attachments of the semispinalis cervicis (SSC) and multifidus muscles to the spinous processes. An operating microscope is recommended for this minimally invasive exposure. A longitudinal midline incision is made overlying the spinous processes of the planned laminoplasty levels (Mitsunaga *et al.*, 2012). Plain radiography and CT scan were used to confirm the site of anchor insertion.

The aim of the work was to assess effectiveness and safety of laminoplasty in treatment of multilevel cervical canal stenosis.

PATIENTS AND METHODS

This is a cross sectional cohort study done on Al-Azhar University Hospital (Damietta Branch). This study was conducted on 20 patients with multilevel cervical canal stenosis undergoing cervical laminoplasty. The work was during the period from January 2016 to May 2017, and participated after oral and informed consents.

Inclusion Criteria: Multilevel cervical canal stenosis with central compression and patients presented with neck pain and myelopathy.

Exclusion Criteria: Isolated radiculopathy, focal anterior compression, loss of anterior column support and absolute kyphosis.

The following were taken:

1. Careful history taking to check for inclusion and exclusion criteria

according to standardized research protocol.

2. History including medical diseases (DM, hypertension, coagulopathies, cardiac and pulmonary diseases...), previous operations or others.
3. All patients were examined pre-operatively: Clinically (general and neurological) and radiologically by plain X-ray, CT scan and MRI cervical spine.
4. Surgical procedure:
 - Operative position: After intubation we turned the patient in prone position on Hall frame. The patient head was fixed in a curved head rest, the shoulders were taped down on both sides to provide traction, enabling intra-operative radiographic visualization of the lower cervical spine. A slight flexed position of the neck made the laminoplasty easier. The table was tilted into the reverse Trendelenburg position to make the incision site flat and avoid blood congestion in the operative field.
 - Incision and exposure: Midline skin incision from C2 to C7, and in avascular midline plane dividing the nuchal ligament and right and left paraspinal muscles. Exposure was made to the spinous process, laminae and inner half of the lateral mass from C3 to C7.
 - Open -Door Laminoplasty: The spinous processes of C3 through C7 were cut at the base with a liston bone-cutting forceps and kept for use as bone graft. Bilateral troughs were

made at the junction of the lateral mass and lamina. To control the springiness of the elevated lamina, the open side of the "open door" was drilled first. A trough was made across each lamina using a high speed-drill with a 4-mm steel burr. After sufficiently thinning the inner cortex, an 8 to 10 mm raspator was inserted into the trough and twisted. The trough in the hinge side was done in the same manner. The laminae were elevated starting from the caudal lamina to the cranial lamina. The ligamentum flavum was cut under the trough and between the laminae, enabling the opening of the laminae over the extent of laminoplasty. Hemostasis from the epidural venous plexus was achieved by bipolar cauterization. Collagen hemostatic agents were used to gently tamponed bleeding sites. We used the autologous spinous processes from C6 and C7 as a supporting strut with non-absorbable 2-0 suture. We also used modified titanium miniplate (inverted V shaped with 2 outside small wings fitted in the cancellous bone of the lamina medially and in the lateral mass laterally without screws) to keep the laminoplasty opened. Closure of the wound tightly in layers with suction drainage.

- Post-operative care: The drainage tube was removed 1-2 days after surgery, sitting and walking were allowed from post-operative first day. Cervical neck collar was used for at least one month especially for patients with severe neck pain.

Cervical active range of motion exercise and isometric exercise were encouraged when pain was managed.

5. All patients were assessed post-operatively:
 - A) Clinically focusing on post-operative occurrence of any complications or neurological deficit including quadriplegia, cerebro spinal fluid leak, vertebral artery injury, nerve root injury, axial neck pain, loss of cervical motion, and loss of cervical alignment.
 - B- Radiologically: X-ray and CT scan to assess diameter of cervical canal and cervical stability and curvature. The post-operative changes in the cervical kyphosis /lordosis was assessed according

to the difference in the C2-7 angle in neutral position.

Statistical analysis of data: The collected data were organized, tabulated and statistically analyzed using statistical package for social sciences (SPSS) version 22 (SPSS Inc, Chicago, USA), running on IBM compatible computer. For qualitative data, frequency and percent distributions were calculated. For quantitative data, mean and standard deviation (SD) were calculated P value <0.05 was considered significant.

RESULTS

The mean age in the present study was 48.9 ± 3.7 . There were 14 (70%) male cases and 6 (30%) female cases. There were 7 (35%) cases with a history of hypertension and 5 (25%) cases with a history of diabetes miltus (**Table 1**).

Table (1): Demographic data of age, sex and history of studied cases.

Data		Range (years)	Mean \pm SD
Parameters			
Age		44 – 55	48.9 ± 3.7
Sex	Male	No	%
		14	70%
	Female	6	30%
History	Hypertension	7	35%
	Diabetes mellitus	5	25%

The mean operative time was about 167 minutes. The average blood loss was about 403.3 ml, and the average length of stay after operation was about 6.7 days (**Table 2**).

Table (2): Operative time, blood loss and length of hospital stay of the studied cases

Data Parameters	Range	Mean ± SD
Operative time	100 – 210 (minute)	167 ± 31.08
Blood loss	250 - 550 (ml)	403.3 ± 95.7
Length of stay	5 - 9 (days)	6.7 ± 1.6

There was a significant difference in between before and after operation of Nurick grade score of the studied cases (**Table 3**).

Table (3): Nurick grade score of studied cases.

Score Parameters	Range	Mean ± SD	p- value
Before operation	2-5	2.8 ± 0.94	<0.05
After operation	0-3	1.5 ± 1.18	

* In the present study, there was a significant difference in between before and after operation of the studied cases regarding (C2-7 angle; 15.2 ± 1.5 Vs 10.8 ± 1.53 -degree, cervical range of motion 26.9 ± 1.6 Vs 20.3 ± 2.2 , Japanese Orthopedic Association (JOA) score 9.4 ± 1.3 Vs 13.7 ± 1.8 , mean sagittal diameter by radiographic evaluation 11.6 ± 0.98 Vs 16.7 ± 1.9 , and neck pain visual analog scale (VAS) scores 3.1 ± 0.83 Vs 3.9 ± 0.79 , respectively (**Fig 1-2**).

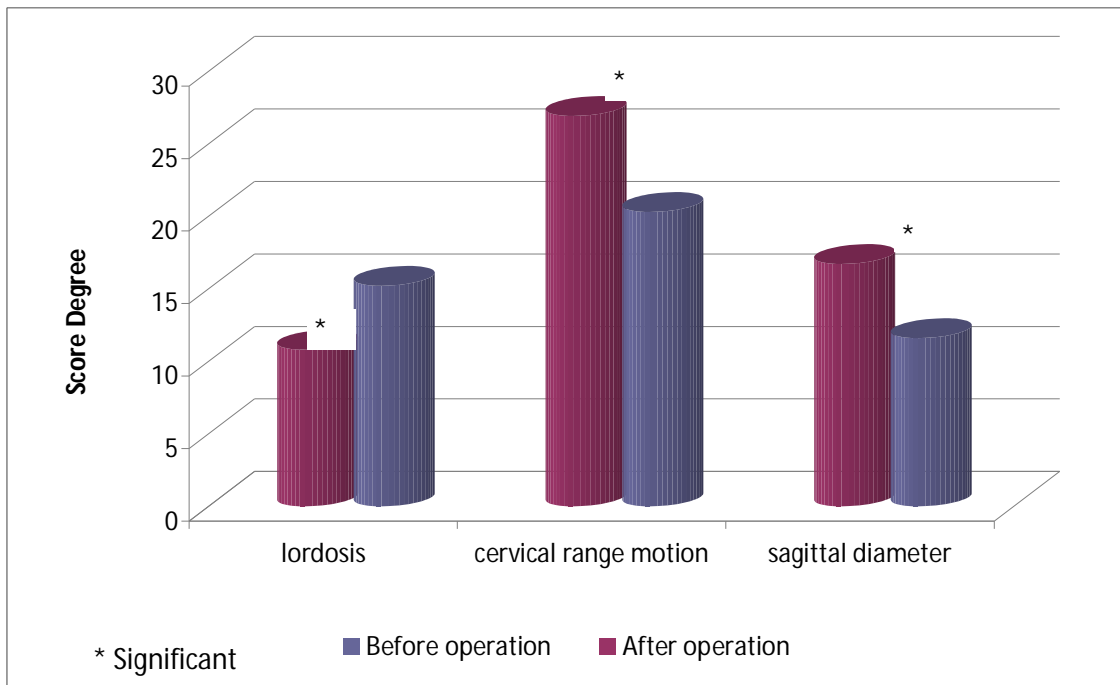


Figure (1): Comparison between before and after operation regarding lordosis, cervical range of motion and sagittal diameter of the studied cases.

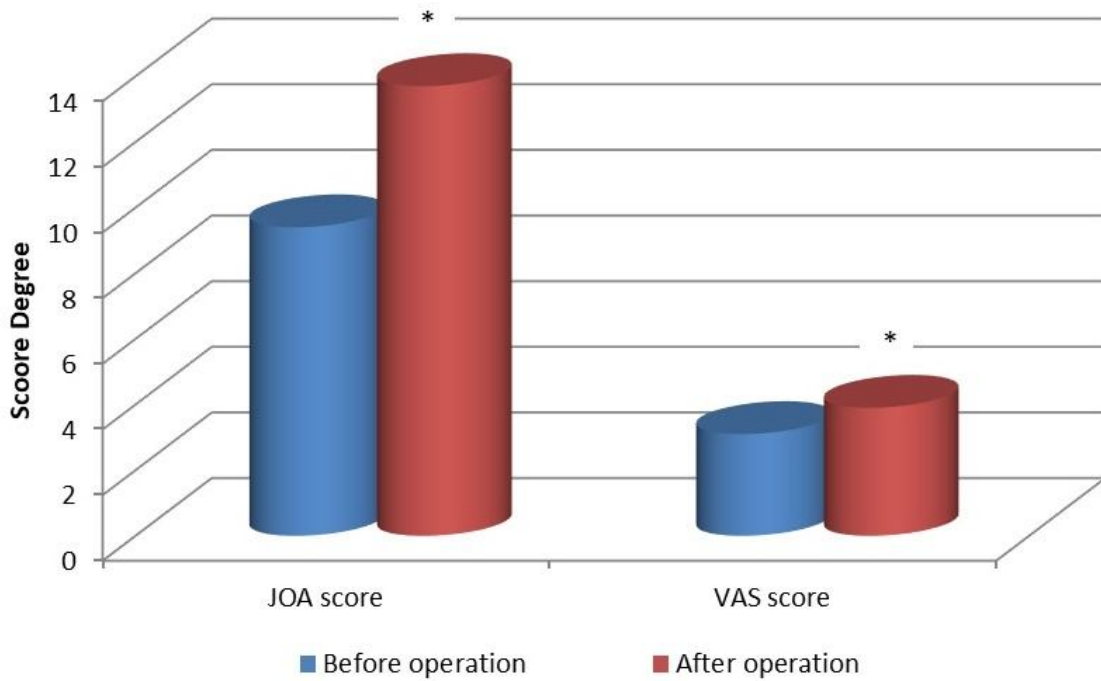


Figure (2): Comparison between before and after operation regarding JOA scores and VAS scores of the studied cases.

On average, patients lost lordosis, (15.2 ± 1.5 Vs 10.8 ± 1.53 degree) but maintained a lordotic curve post-operatively, and decreased post-operatively incidence of kyphosis. The range of motion was decreased post-operatively by about 6° less than pre-operatively (26.9 ± 1.6 Vs 20.3 ± 2.2).

The sagittal diameter of cervical canal was increased post-operatively by average 5 mm (11.6 ± 0.98 Vs 16.7 ± 1.9) (Fig 1).

There was an improvement of both JOA score (9.4 ± 1.3 Vs 13.7 ± 1.8) and VAS (3.1 ± 0.83 Vs 3.9 ± 0.79) post-operatively (Fig 2).

Case presentation

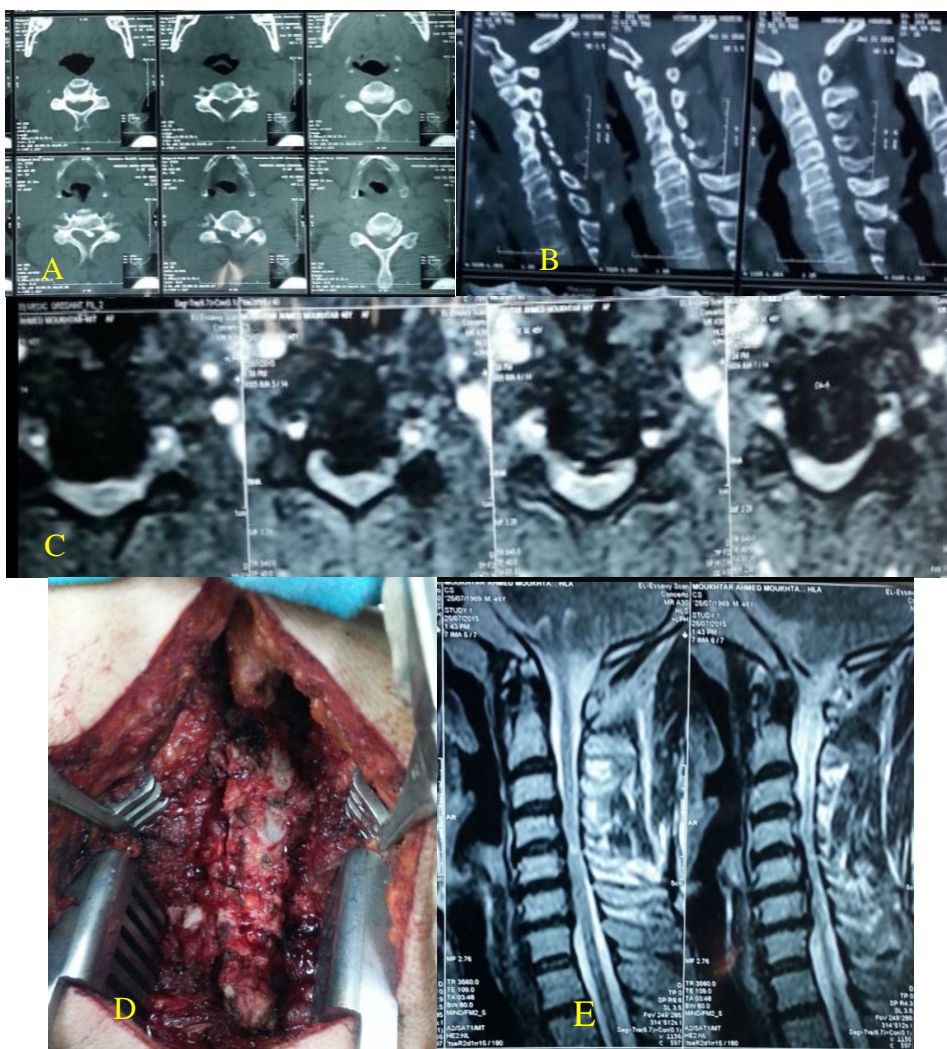

Figure (3): Male patient with cervical myelopathy and multiple level canal stenosis: Pre-operative, (A) sagittal CT scan, (B) axial CT scan, (C) axial MRI cervical, (D) sagittal MRI spine of the same patient and (E) operative view.

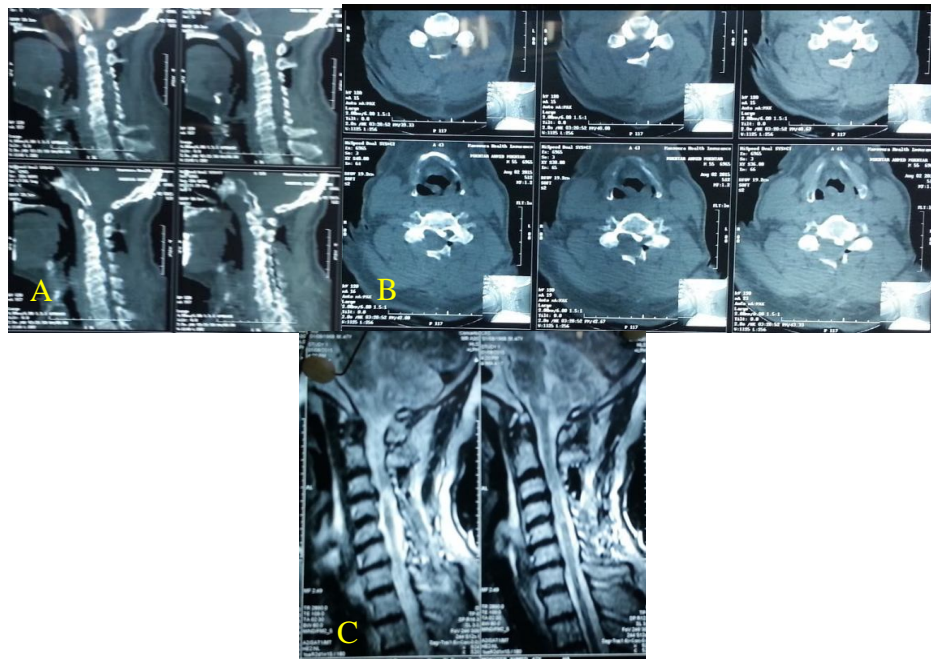


Figure (4): Post operative, with no kyphotic development, maintained lordosis and improved sagittal and axial diameter, (A) sagittal CT scan , (B) axial CT scan and (C) MRI sagittal cervical spine views.

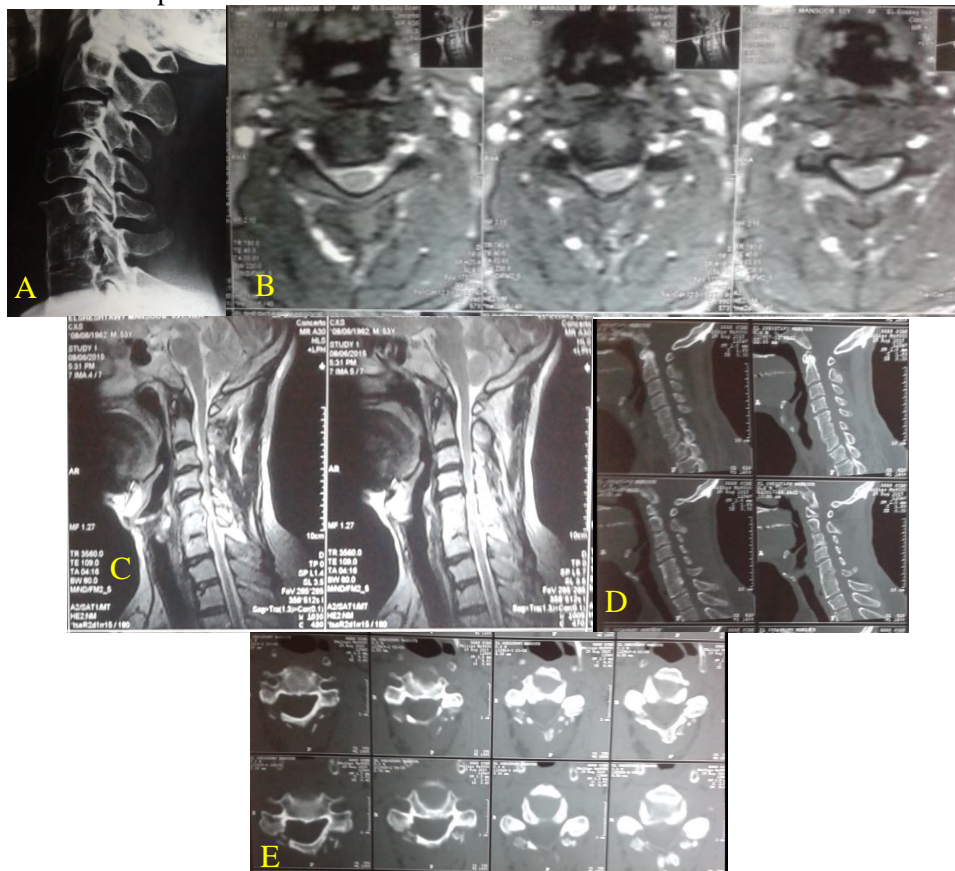


Figure (5): Male patient with cervical myelopathy and cervical multiple level canal stenosis, pre-operative A- Plain X-ray, B- Axial MRI views, C- Sagittal MRI, and post-operative , D- Sagittal CT scan with preserved lordosis, and E- Axial CT scan with widening of the cervical canal.

DISCUSSION

Multilevel cervical stenosis can be effectively treated with long-level anterior cervical decompression and fusion. Anterior procedures can directly remove anterior pathology, correct kyphosis, and stabilize unstable segments. However, in multilevel cervical stenosis myelopathy, multisegmental anterior cervical discectomy fusion (ACDF) yield increased complication rates, including dysphonia, dysphagia, construction failure, adjacent segment disease, and fusion rates lower than anterior fusion of three or less motion segments (**Yeh et al., 2015**).

The laminoplasty technique is a variant of the laminectomy, which was first described by **Hirabayashi and Satomi (1988)**, with the purpose of decompressing the spine and reducing the complications resulting from the classic laminectomy. Multiple variations on the technique have been created, but these methods share the same idea of cervical expansion with a protective dorsal element (**Jason et al., 2011**). Laminoplasty is one surgical option for cervical spondylotic myelopathy. It was developed to avoid the significant risk of complications associated with alternative surgical options such as anterior decompression and fusion and laminectomy with or without posterior fusion (**Mitsunaga et al., 2012**).

Laminoplasty represents a powerful technique for the treatment of multilevel cervical stenosis, whether resultant from

spondylosis. Certain parameters such as kyphosis, k-line positivity, and greater than 50% canal occupation ratio are predictive of less favorable outcomes after laminoplasty and should prompt the surgeon to consider ventral decompression. Laminoplasty has a significantly lower complication rate than multilevel anterior procedures. There are several technical considerations when performing laminoplasty that can minimize the risk of postoperative complications. In particular, preservation of the muscle attachments to C2 and C7 can minimize postoperative axial pain and preserve sagittal alignment (**Simpson and Rhee, 2014**).

In the present work, the mean operative time was 167 ± 31.08 minutes, mean blood loss was 403.3 ± 95.7 ml and the mean length of hospital stay was 6.7 ± 1.6 days. **Xin et al. (2015)** found shorter operation time and less intraoperative blood loss were found with laminoplasty (182 min and 608 ml by laminoplasty vs. 264 min and 986 ml by subtotal corpectomy). **Xuzhou et al. (2014)** and **Chang et al. (2015)**, also found that operation time and blood loss were apparently higher in corpectomy group compared with the laminoplasty group. This indicate that the surgical trauma in the corpectomy group and laminectomy and fusion group were obviously higher than that in the laminoplasty group. On the other hand, **Shibuya et al., (2010)** compared therapeutic outcomes of anterior subtotal corpectomy (n = 49) and posterior laminoplasty (n= 40) and found that for multilevel vertebral lesions, the

operation time was longer and intra-operative blood loss was greater by subtotal corpectomy.

In the present work, there were significant decrease in Nurick grade score after operation when compared with before operation (1.5 ± 1.18 Vs 2.8 ± 0.94) and these agree with **Jason et al. (2011)** who found that laminoplasty was associated with improvements in Nurick scores. **Mohamed et al. (2015)** compared laminoplasty and standard laminectomy without fusion in a case control study. The Nurick scores of the patients in the laminoplasty group improved by a mean of 0.96, and those patients had fewer complications than the patients in the laminectomy (without fusion) group.

In the present study, there were significant improvement of lordosis after operation when compared with before operation (10.8 ± 1.53 Vs 15.2 ± 1.5) and Cervical range of motion (ROM) (20.3 ± 2.2 Vs 26.9 ± 1.6). Laminoplasty did not increase the incidence of kyphosis. It maintains lordosis (**Highsmith et al., 2011**). **Machino et al. (2012)** and **Lao et al. (2013)** evaluated over 500 consecutive patients undergoing laminoplasty and demonstrated a paradoxical 1.8° increase in their cervical lordosis measured from C2 to C7 at final follow-up averaging 33 months post-operatively. But **Stephan et al. (2015)** noticed that a decrease in cervical range of motion after laminoplasty. This loss of motion is in the range of 17–75% but, usually, a global loss of cervical motion of approximately 50% is seen.

In the present study, there were significant increase of Japanese Orthopedic Association (JOA) score after operation when compared with before operation from 9.4 ± 1.3 to 13.7 ± 1.8 , Sagittal diameter from 11.6 ± 0.98 to 16.7 ± 1.9 and neck pain visual analog scale (VAS) from 3.1 ± 0.83 to 3.9 ± 0.79 . **Lee et al. (2014)** noticed that laminoplasty was associated with improvements in JOA scores. **Monzano et al. (2012)** and **Zhang et al. (2012)** noticed that laminoplasty have shown increases in the Japanese Orthopedic Association (JOA) by 55–65%. JOA score, with higher scores indicating better patient status and lower scores representing poorer patient status.

In this study we reported increased sagittal diameter of the spinal canal of the operated patients post-operatively. **Wang et al. (2009)** and **Stephen et al. (2015)** also reported the sagittal diameter increased with laminoplasty and found that laminoplasty did not improve or cause neck or shoulder pain. **Highsmith et al., (2011)** showed that late complications were fewer in the laminoplasty. The overall recovery rate after laminoplasties ranging from 50% to 70%.

CONCLUSION

Operative treatment of cervical spinal stenosis remains controversial. Several options are commonly used, including anterior subtotal corpectomy combined with bone graft fusion and internal fixation, anterior discectomy combined with bone graft fusion and internal fixation and posterior laminoplasty with

or without internal fixation. However, there are limitations with these options. Laminoplasty is becoming an increasingly popular treatment for multilevel cervical stenosis due to cervical spondylotic myelopathy. Laminoplasty minimizes the risk of certain complications associated with other surgical options, such as graft and fusion-related complications.

REFERENCES

1. **Chang HL, Jaebong L, James DK, Seung JH, Ki-jeong K, Tae AJ and Hyun JK. (2015):** Laminoplasty versus laminectomy and fusion for multiple level cervical myelopathy: a meta-analysis of clinical and radiological outcome. *J. Neurosurgery Spine*, 22:589-595.
2. **Gabriel L, Jacob M B and Daniel R K. (2015):** Screw Back-Out Following "Open-Door" Cervical Laminoplasty: A Review of 165. *Plates Asian Spine J.*, 9(6):849-854.
3. **Highsmith M S, Sanjay S D, Regis W H, Gerald E R and Praveen V. (2011):** Treatment of cervical stenotic myelopathy: a cost and outcome comparison of laminoplasty versus laminectomy and lateral mass fusion. *Neurosurg Spine J.*, 14:619-625.
4. **Hirabayashi K and Satomi K. (1988):** Operative procedure and results of expansive open-door laminoplasty. *Spine J.*, 13:870-876.
5. **Jason MH, Sanjay SD, Regis WH, Gerald ER and Praveren VM. (2011):** Treatment of cervical stenotic myelopathy: a cost and outcome comparison of laminoplasty versus laminectomy and lateral mass fusion. *J. Neurosurgery Spine*, 14: 619-625.
6. **Lao L, Zhong G, Li X, Qian L and Liu Z. (2013):** Laminoplasty versus laminectomy for multi-level cervical spondylotic myelopathy: a systematic review of the literature. *Orthop Surg Res J.*, 8:45-46.
7. **Lebl DR, Hughes A, Cammisa FP and O'Leary PF. (2011):** Cervical spondylotic myelopathy: Pathophysiology, clinical presentation, and treatment. *HSS J.*, 7: 170-178.
8. **Lee CH, Jahng TA, Hyun SJ, Kim KJ, Kim HJ. ((2014):** Expansive laminoplasty vs. laminectomy alone vs. laminectomy and fusion for cervical ossification of the posterior longitudinal ligament: is there a difference in the clinical or radiologic outcome? *J Spinal Disord Tech.*, 21: 121-129.
9. **Machino M, YukawaY, HidaT, Ito K, Nakashima H, Kanbara S, Morita D and Kato F. (2012):** Cervical alignment and range of motion after laminoplasty: radio-graphical data from more than 500 cases with cervical spondylotic myelopathy and a review of the literature. *Spine J.*, 37:1243-1250.
10. **Masayuki U, Kunihiko S, Taketoshi K, Ei W, Tokun M, Atsushi I and Hirokazu I. (2013):** A less-invasive cervical laminoplasty for spondylotic myelopathy that preserves the semispinalis cervicis muscles and nuchal ligament. *J Neurosurg Spine* 18:545-552.
11. **Monzano GR, Casella G, Wang MY, Vanni S, Levi AD. (2012):** A prospective, randomized trial comparing expansile cervical laminoplasty and cervical laminectomy and fusion for multilevelcervical myelopathy. *Neurosurgery J.*, 70:264-277.
12. **Mitsunaga L K, Eric O K and Munish CG. (2012):** Laminoplasty Techniques for the Treatment of Multilevel Cervical Stenosis. *Advances in Orthopedics J.*, 12:1-15.
13. **Mohamed AW, Ahmed ME and Fady MI. (2015):** Laminoplasty versus laminectomy for multi-level cervical spondylotic myelopathy: A prospective study. *World Spinal Column J.*, 6 (2): 83-91.
14. **Praveen VM, Michael GK, Paul GM, Paul AA, Michael WG, Robert FH, Langston TH, Timothy CR, Tanvir FC, Edward JV and Doniel KR. (2009):** Cervical surgical techniques for the treatment of cervical spondylotic myelopathy. *Neurosurg Spine J.* 11:130-141.

- 15. Shibuya S, Komatsubara S, Oka S, Kanda Y, Arima N and Yamamoto T. (2010):** Differences between subtotal corpectomy and laminoplasty for cervical spondylotic myelopathy. *Spinal Cord J.*, 48(3):214–220.
- 16. Simpson A K and Rhee M J. (2014):** Laminoplasty: A review of the evidence and detailed technical guide. *Semin Spine Surg j.*, 26: 141 – 147.
- 17. Stephan D, Tyler C, and John K. (2015):** Cervical laminoplasty developments and trends, 2003–2013: a systematic review. *Neurosurg Spine J.*, 10: 171-182.
- 18. Wang M C, Kreuter W, Wolfla C E, Maiman D J and deyo R A. (2009):** Trends and variations in cervical spine surgery in the United States: Medicare beneficiaries, 1992 to 2005. *Spine j.*, 34:955-961.
- 19. Xuzhou L, Shaoxiong M, Hui Z, Zhidi Z, Hehui W and Anmin J. (2014):** Anterior corpectomy versus posterior laminoplasty for multi-level cervical myelopathy: a systemic review and meta-analysis. *Eur Spine J.*, V 23(2): 362-372.
- 20. Xin-K, Xu L, Lu C, Chi-J, Dino S and Hai-Q. (2015):** Cervical open door laminoplasty technique with simple sutures and bone grafts: a single institutional study with 30 consecutive cases. *Journal of Orthopaedic Surgery and Research.*, v. 10, p.14:1-6.
- 21. Yeh K, Ru-Ping L, Ing-Ho C, Tzai-Chiu Y, Cheng-Huan P, Kuan-Lin L, Jen-Hung W and Wen-Tien W. (2015):** Laminoplasty with adjunct anterior short segment fusion for multilevel cervical myelopathy associated with local kyphosis. *Journal of the Chinese Medical Association.*, 78: 364e369.
- 22. Zhang H, Sun T, Lu S, Li Q, Yadav SK. (2012):** Comparison of effectiveness between laminoplasty and laminectomy decompression and fusion with internal fixation for cervical spondylotic myelopathy. *Journal of the Chinese Medical Association*, 26:1191–1196.

الجديد فى تقنيات إصلاح الصفيحة العظمية لمعالجة ضيق القناة الشوكية العنقية المتعدد المستويات

محمد حسام الدين أبو شهبه - هداية محمد حسن هندام - أحمد محمد طه
عبد الله محمد عبد الوهاب سلامه

قسم جراحة المخ والأعصاب - كلية الطب بنين (دمياط) - جامعة الأزهر

خلفية البحث: الهدف الأساسى من توسيع القناة الفقرارية هو تخفيف الضغط على النخاع الشوكى و لكى يتيح مجال أوسع لعمل طرق جراحية أخرى بهذه المنطقة مثل تشريح وتجميل الأم الجافية، وإزالة أورام النخاع الشوكى.

الهدف من البحث: دراسة وتقييم كفاءة وسلامة عملية توسيع القناة الفقرارية العنقية فى علاج ضيق القناة الشوكية متعدد المستويات، ومقارنته بالطرق الجراحية الأخرى.

المرضى و طرق البحث: تمت دراسة 20 مريضاً يعانون من ضيق القناة الفقرارية المتعدد، وقد أجريت لهم جراحة لتوسيع القناة الفقرارية العنقية. وقد خضع كل المرضى قبل الجراحة للفحص الإكلينيكي العام والعصبى، وعمل الأشعات التشخيصية اللازمة من أشعة عادية ومقطعية وفحص بالرنين المغناطيسى، وعمل الفحوص المعملية اللازمة.

النتائج: شملت هذه الدراسة 20 مريضاً، متوسط أعمارهم 48.9 سنة، منهم 14 رجلاً و 6 نساء، وكان يعانى 7 مرضى من إرتفاع ضغط الدم و 5 مرضى من إرتفاع السكر بالدم. وقد تحسنت الحالة الإكلينيكية للمرضى بعد الجراحة تبعاً لمقياس نيوريك والجمعية اليابانية للعظام ومقياس قدرة إحتمال المريض للألم.

الإستنتاج: أصبحت عملية توسيع القناة الفقرارية العنقية من أكثر الطرق الجراحية نجاحاً فى علاج ضيق القناة الفقرارية المتعدد المستويات والمصحوب بخشونة الفقرات العنقية، كما تقلل من خطورة التعرض لمضاعفات الطرق الجراحية الأخرى.