

CHANGES OF PERIPAPILLARY NERVE FIBER LAYER AND FOVEAL THICKNESS MEASUREMENTS BY OPTICAL COHERENCE TOMOGRAPHY AFTER PHACOEMULSIFICATION IN NON-DIABETIC NON-GLAUCOMATOUS PATIENTS WITH SENILE GRADE 1+ CATARACT

By

Mostafa F Mohammed

Ophthalmology Department, Faculty of Medicine, Al-Azhar University, Cairo, Egypt.

ABSTRACT

Background: Optical coherence tomography (OCT) is widely used by ophthalmologists for diagnosing and following retinal diseases such as diabetic retinopathy (DR), and OCT measurement of peripapillary nerve fiber layer (NFL) thickness is valuable for glaucoma screening and detection of progression. Previous studies reported that the presence of visually significant cataract can affect the quality and accuracy of NFL and foveal thickness measurements by OCT because cataract increases light scattering and absorption. The effect of age related low grade cataract on OCT measurements has not been widely investigated.

Objective: Studying the changes of peripapillary NFL and foveal thickness measurements by OCT after phacoemulsification and intraocular lens (IOL) implantation in non diabetic non glaucomatous patients with grade 1+ senile cataract.

Patients and methods: This prospective study included 20 eyes of 20 patients (12 females and 8 males) with grade 1+ senile cataract [according to world health organization (WHO) criteria for cataract grading] which permits OCT imaging with reliable signal strength (SS). Patients with chronic systemic diseases such as diabetes mellitus (DM) and uncontrolled hypertension were excluded. Patients with dense or posterior subcapsular (PSC) cataract, patients with high myopia and patients with signs or OCT findings of glaucoma or maculopathy were also excluded. Detailed personal history, medical history, and ophthalmic history were taken at base-line for all patients, and full ophthalmologic examination including refraction, best corrected visual acuity (BCVA), slit lamp examination of the anterior segment, applanation tonometry, and dilated fundus examination of the macula, disc, retinal blood vessels and retinal periphery by slit lamp biomicroscopy were done at base line examination. OCT images for peripapillary NFL and macula were taken for all participants preoperatively and after 5 weeks postoperatively at Al-Hussein University hospital using spectral OCT SLO combination imaging system (OPKO/OTI, USA).

Results: The mean (M) age was 56.65 ± 1.9 years. The M preoperative BCVA was 0.3 ± 0.1 . The M postoperative BCVA was 0.6 ± 0.1 . All preoperative and postoperative OCT images were reliable with $SS \geq 6$. The M values of participants' minimum, average and maximum NFL measurements were increased significantly after phacoemulsification. The average NFL measurement increased significantly by $9.8 \mu\text{m}$ (11%) from $89.80 \pm 6.69 \mu\text{m}$ preoperatively to $99.6 \pm 3.82 \mu\text{m}$ postoperatively. By analyzing the NFL quadrants thickness scales, there was an increase in the peripapillary NFL M measurements in all quadrants postoperatively. This increase was statistically significant in the superior, nasal and inferior quadrants, while

this increase was not statistically significant in the temporal quadrant. As regard macular OCT, the M foveal thickness increased significantly by 26.15 μm (15%) from 172.10 \pm 50.05 μm preoperatively to 198.25 \pm 27.95 μm postoperatively.

Conclusion: Peripapillary NFL and foveal thickness parameters may increase significantly after uncomplicated phacoemulsification and posterior chamber bag foldable IOL implantation. The optical effect of media opacity caused by cataract should be taken into consideration during follow up of cases by OCT such as glaucomatous and diabetic patients. Detailed general and ophthalmologic history, full ophthalmologic examination and previous investigations should be taken into consideration when patients were followed up using OCT, and any changes just as incidence of early cataract should be written in the OCT report.

Keywords: Ocular coherence tomography, nerve fiber layer, foveal thickness, cataract, signal strength.

INTRODUCTION

OCT is a well-recognized method of analyzing the in vivo retinal architecture. OCT is used for diagnosing and following retinal diseases such as DR, and is particularly useful and accurate for measuring retinal thickness (**Garcia-Martin et al., 2013**).

Significant structural retinal NFL loss occurs prior to the development of functional visual field (VF) loss. In such preperimetric disease, spectral domain OCT (SD-OCT) retinal NFL is especially useful in helping to diagnose glaucoma prior to the onset of VF loss (**Grewal and Tanna, 2013**).

SD-OCT can directly measure and quantify retinal NFL thickness by calculating the area between the internal limiting membrane and NFL border (**Leite et al., 2011**).

The retinal NFL map represents a 6 x 6 mm cube of A-scan data centered over the optic nerve (ON) in which a 3.4 mm diameter circle of NFL data is extracted to create what is referred to as the TSNIT map (temporal, superior, nasal, inferior, temporal). It is displayed as a false color scale with the thickness values referenced to a normative database. The TSNIT map displays retinal NFL thickness values by

quadrants and clock hours, and the retinal NFL peaks give a sense of the anatomic distribution of nerve fiber axons represented by the superior and inferior bundles that emanate from the ON. As regard the macula, the macular scan map is displayed using a similar color scale and divided into various pie sectors around the fovea, and the calculated sectors are compared to a normative database (**Leite et al., 2011**).

Although OCT data generally have good repeatability, factors such as the presence of cataract, the extent of pupillary dilation, and corneal dryness affect both the image quality and repeatability of subsequent OCT measurements (**Rao et al., 2014**).

When assessing the adequacy of a scan, the signal strength (SS) should always be noted. The SS, reported on a scale of 0 to 10, is defined as the averaged intensity value of the signal pixels in the OCT image. The best quality scans have signal strength greater than 8 (minimum acceptable scan > 6). Scans with SS less than 6, with eye movement or blinking artifacts within the 1.73-mm radius around the ON head, or with segmentation errors should be repeated (**Mwanza et al., 2011**).

Cataract is a common cause of media opacity that can affect the quality of diagnostic imaging devices for glaucoma like OCT in the elderly. Clear optical media will optimize both forward and back light scattering, whereas media opacity caused by cataract will increase light scattering and absorption (**Darma et al.**, 2015). Previous studies using Stratus time domain OCT reported that lens opacities may affect the NFL thickness measurements, and the NFL thickness measurement can be increased after uncomplicated cataract surgery. The increase in SS and NFL thickness measurement after cataract surgery may be the result of improved transmittance and reflectivity of the NFL boundary after removal of opacified media, rather than actual NFL thickening after cataract surgery (**Kwak et al.**, 2017).

Several studies suggest that cataract effect on OCT image seems to depend on the type and grading of cataract, with nuclear cataracts having less effect than cortical and posterior cataracts on OCT image quality (**Lee et al.**, 2010).

Gazzard et al. (2004), in a study using scanning laser polarimetry (SLP) on glaucoma patients, have shown a significant change in SLP measurements after cataract extraction, especially so in patients with posterior subcapsular cataract, and they recommended the establishment of a new baseline in glaucoma patients following cataract surgery. **Kremmer et al.** (2003) have also concluded that after cataract surgery with IOL implantation, some SLP values are altered significantly, whereas, scanning laser tomography parameters are not influenced. These findings are of clinical interest, especially in the follow-up of glaucoma patients. On the other hand, **Vetrugno et al.** (2004) have shown no statistically significant

changes as regard SLP parameters after cataract surgery.

The present work aimed to study the OCT changes as regard peripapillary NFL and foveal thickness after uncomplicated phacoemulsification and posterior chamber bag IOL implantation in non diabetic non glaucomatous patients with senile grade 1+ cataract.

PATIENTS AND METHODS

Patients' selection: This prospective non-randomized interventional study included 20 eyes of 20 patients with 1+ senile cataract (12 females and 8 males; 8 patients with nuclear sclerosis (NS) 1+ cataract, 6 patients with cortical spoking (CS) 1+ cataract and 6 patients with combined NS 1+ and anterior CS 1+ cataract). The M age was: 56.65 ± 1.9 years; range (R): 52-62 years. All patients provided informed consent prior to participation.

Exclusion criteria:

General exclusion criteria: Patients with chronic systemic diseases such as DM and uncontrolled hypertension and patients using systemic medications which may cause retinopathy such as chloroquine were excluded.

Ocular exclusion criteria: Patients with dense cataract > 1+ according to WHO criteria which may cause artifacts and reduction of the SS of images, patients with PSC cataract, patients with complicated or traumatic cataract, patients with primary open angle glaucoma, patients with OCT finding of maculopathy, patients with peripapillary chorioretinal degeneration such as high myopic patients, and patients with

marked dryness or ocular surface diseases were excluded from the study.

History taking: Detailed personal history, family history, general medical history, and detailed ophthalmic history (including history of ocular diseases, medications, investigations, laser treatment or ocular surgeries, history of using glasses and at what time of life, and history of contact lenses use) were taken at base-line for all the patients

Full ophthalmologic examination including the refraction, unaided visual acuity, BCVA; using Snellen's decimal format (Moutray et al., 2008), pupillary examination, slit lamp examination of the anterior segment, applanation tonometry, and dilated fundus examination of the macula, disc, retinal blood vessels and retinal periphery by slit lamp biomicroscopy were done at base line examination.

Operative data: All patients had uncomplicated phacoemulsification surgeries using Infinity Vision System (Alcon, USA) with posterior chamber (bag) OcuFlex foldable hydrophilic acrylic IOL implantation at El-Hussein University Hospital.

Investigations and follow up:

OCT images for peripapillary NFL and macula were taken preoperatively and 5 weeks postoperatively for all participants at El-Hussein University hospital using spectral OCT SLO combination imaging system (OPKO/OTI, USA). Any patients with posterior capsular opacification (PCO) were excluded.

Statistical analysis:

The changes of peripapillary NFL thickness in each quadrant around the

optic disc, the changes of minimum, average and maximum peripapillary NFL readings and the changes of foveal thickness for the participants were statistically analyzed using the paired t-test. The data obtained including the mean (M) and the standard deviation (SD) were used to obtain P value, and P value less than 0.05 was considered statistically significant (Franz et al., 2007).

RESULTS

The M preoperative BCVA was 0.3 ± 0.1 . The postoperative M BCVA was 0.6 ± 0.1 . The SS of all images was ≥ 6 .

By analyzing the participants TSNIT false color scales; the participants' minimum, average and maximum NFL M measurements increased significantly after phacoemulsification.

The M minimum NFL measurement increased from $44.40 \pm 4.53 \mu\text{m}$ preoperatively to $54.40 \pm 3.70 \mu\text{m}$ five weeks postoperatively (increased by 22.5% - $P < 0.0001$).

The M average NFL measurement increased from $89.80 \pm 6.69 \mu\text{m}$ preoperatively to $99.6 \pm 3.82 \mu\text{m}$ five weeks postoperatively (increased by 11% - $P < 0.0001$).

The M maximum NFL measurement increased from $144.40 \pm 18.90 \mu\text{m}$ preoperatively to $162.80 \pm 11.60 \mu\text{m}$ five weeks postoperatively (increased by 12.7% - $P < 0.0001$).

As regard the four quadrants NFL thickness scales, the changes of participants' peripapillary NFL M thickness in each quadrant were shown in the following 4 tables.

There was an increase in the peripapillary NFL thickness M measurements in all quadrants 5 weeks after phacoemulsification. This increase was statistically significant in the superior, nasal and inferior quadrants, while this increase was not statistically significant in the temporal quadrant.

By analyzing the macular false color scale, the M foveal thickness of the participants (the M thickness in the central 1000-microm diameter sector) increased from $172.10 \pm 50.05 \mu\text{m}$ preoperatively to $198.25 \pm 27.95 \mu\text{m}$ five weeks postoperatively (increased by 15 % - Table 5).

Table (1): Changes of peripapillary NFL M thickness in the temporal quadrant.

NFL parameters in the temporal quadrant	Preoperative	(5 weeks) postoperatively
(M±SD)	(73±7.73) μm	(75.20±5.78) μm
Range	(62-84) μm	(69-84) μm
P	0.1409	

Table (2): Changes of peripapillary NFL M thickness in the superior quadrant.

NFL parameters in the superior quadrant	Preoperative	(5 weeks) postoperatively
(M±SD)	(112.20±14.27) μm	(124.60±14.02) μm
Range	(100-137) μm	(108-142) μm
P	< 0.0001409	

Table (3): Changes of peripapillary NFL M thickness in the nasal quadrant.

NFL parameters in the nasal quadrant	Preoperative	(5 weeks) postoperatively
(M±SD)	(63.80 ± 9.87) μm	(78.20 ± 10.25) μm
Range	(52-77) μm	(65-89) μm
P	<0.0001	

Table (4): Changes of peripapillary NFL M thickness in the inferior quadrant.

NFL parameters in the inferior quadrant	Preoperative	(5 weeks) postoperatively
(M±SD)	(110 ± 10.70) μm	(119.60 ± 10.95) μm
Range	(100-129) μm	(108-133) μm
P	0.0020	

Table (5): Changes of M foveal thickness.

Foveal parameters	Preoperative	(5 weeks) postoperatively
(M±SD)	(172.10 ± 50.05) μm	(198.25 ± 27.95) μm
Range	(88-206) μm	(159-230) μm
P	0.0006	

Case report:

Case No. (1): 62 years old female with left 1+ nuclear cataract (NS 1+): OCT NFL images, TSNIT maps, grayscale fundus images, quadrant and clock hours maps preoperatively and 5 weeks postoperatively were displayed in figures (1) and (2):

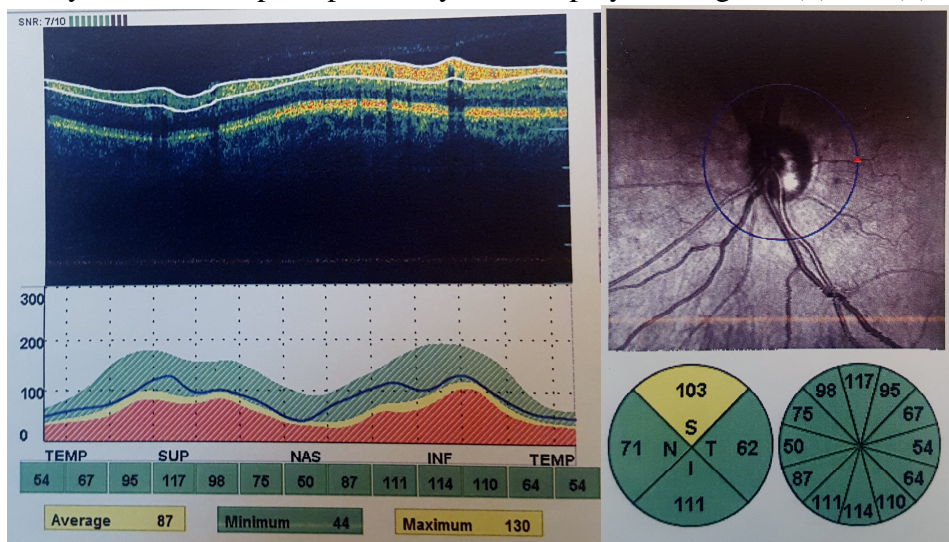


Figure (1): Preoperative OCT NFL for case No. (1). (It showed borderline average, maximum and average superior NFL measurements (< 5% compared to the normative database)

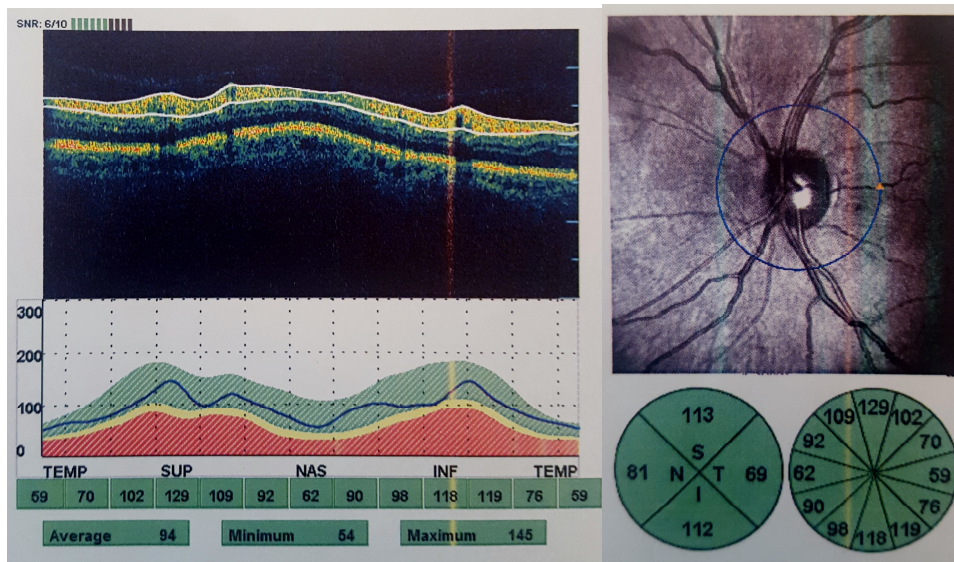


Figure (2): Postoperative OCT NFL for case no. (1): (It showed increased minimum, average, maximum, average temporal, superior, nasal and inferior NFL measurements postoperatively, and all measures were within normal limits)

Case No. (2): 58 years old female with (1+) anterior cortical and nuclear cataract (CS 1+ and NS 1+), the preoperative, post operative OCT RNFL and macular OCT were displayed in figures (3-6):

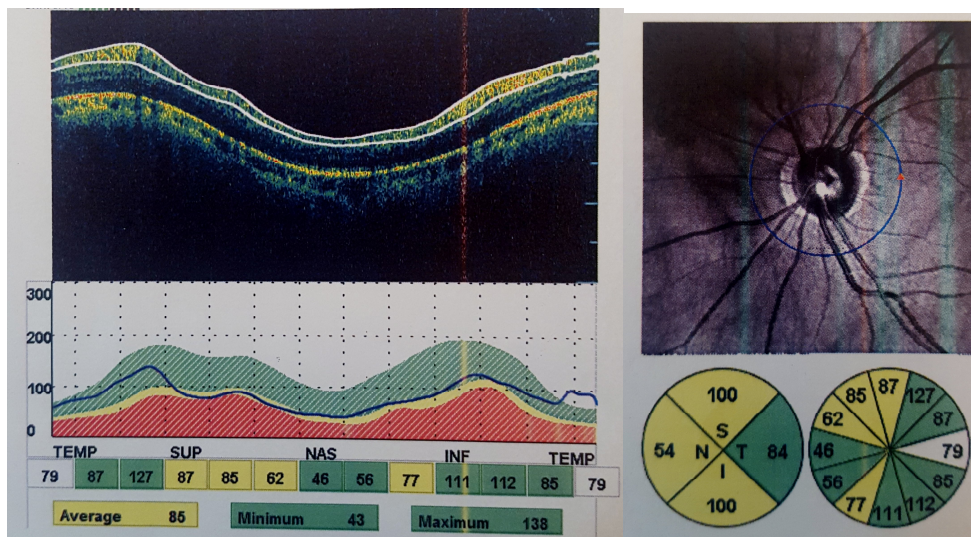


Figure (3): Preoperative OCT NFL for case No. (2): (It showed borderline average, average superior, nasal and inferior NFL measurements)

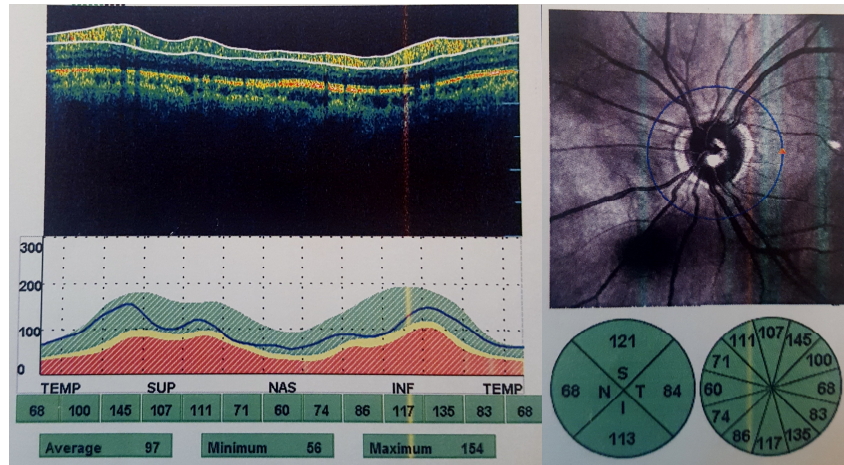


Figure (4): Postoperative OCT NFL for case No. (2): (It showed increased minimum, average, maximum, average superior, nasal and inferior NFL measurements postoperatively, and all measures were within normal limits, the average temporal NFL thickness did not change postoperatively).

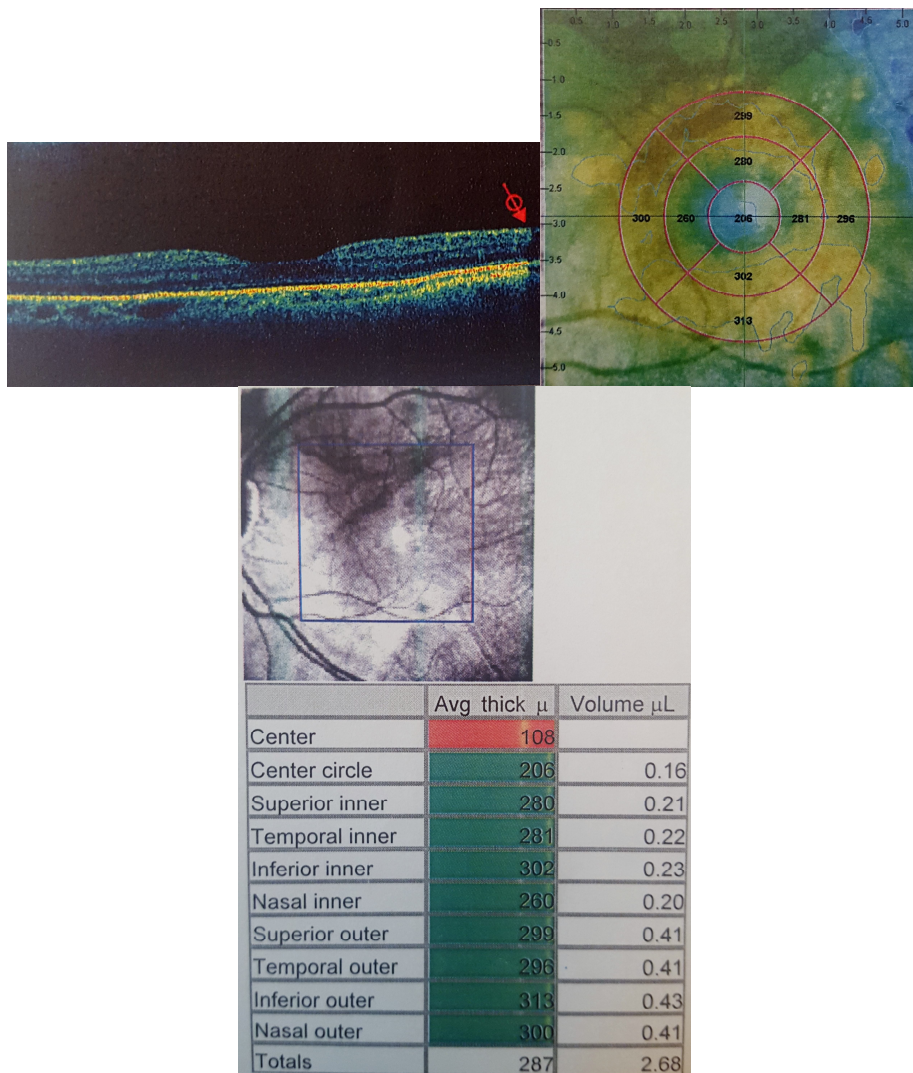


Figure (5): Preoperative macular OCT for case No. (2): (The foveal thickness was 206 μ m).

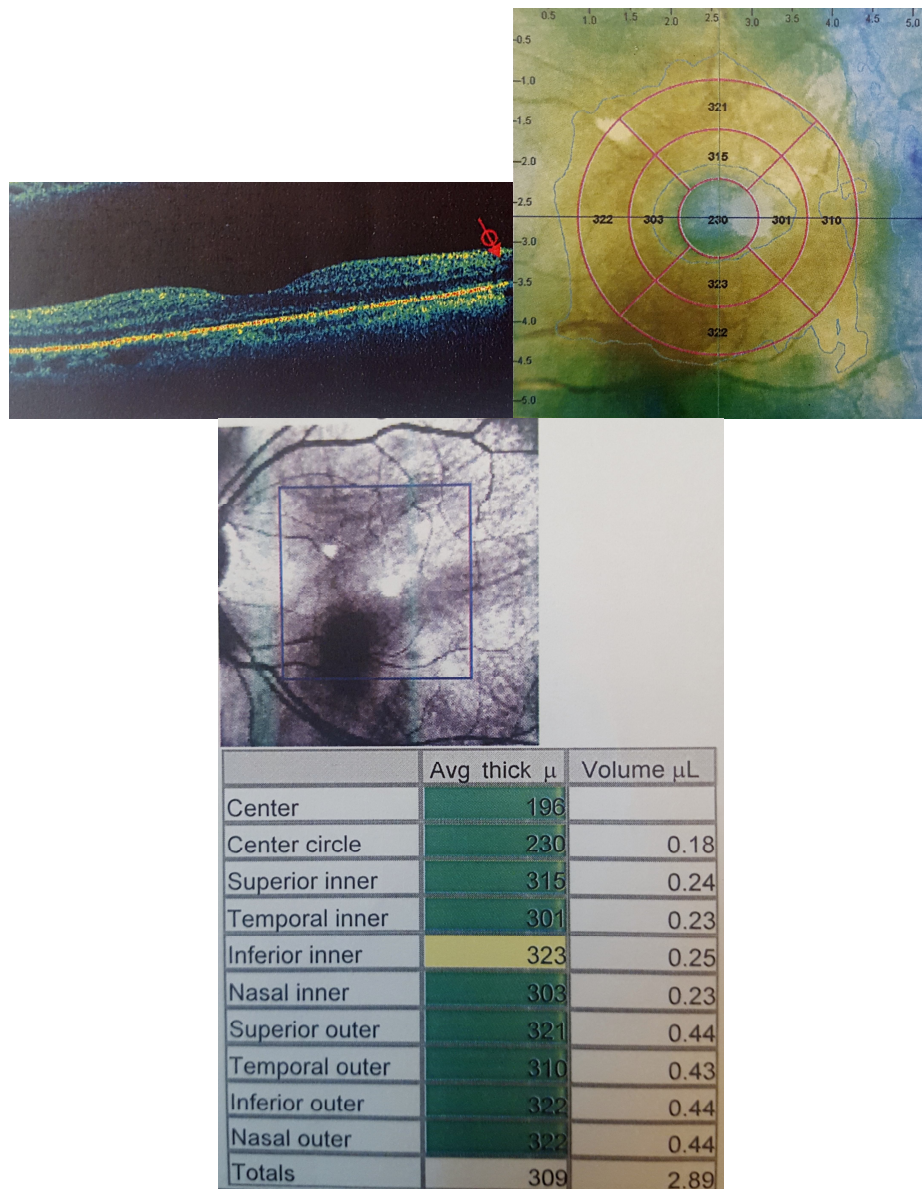


Figure (6): Postoperative macular OCT for case No. (2): (It showed increased thickness measurements in the foveal sector (230 μ m) and all surrounding macular sectors.

DISCUSSION

OCT instruments have recently become very useful for analyzing optic disc and macular disorders. OCT imaging relies on near-infrared light. Similar to its effects in fundus photography and scanning laser ophthalmoscopy, a cataract is likely to increase light scattering and degrade OCT image quality (Lathika et al., 2017).

Previous studies had evaluated the effect of cataract surgery on retinal NFL thickness parameters including different methods and subjects with conflicting results.

Collur et al. (2000), Kremmer et al. (2003), Gazzard et al. (2004), and Vetrugno et al. (2004) have evaluated the influence of visually significant cataract

on the measurement of NFL thickness using SLP in glaucoma patients undergoing phacoemulsification. **Gazzard et al.** (2004) had shown that removal of cataract resulted in greater absolute measurements of NFL thickness but ratio values were unchanged, and they concluded that SLP measurements can change significantly after cataract extraction especially in patients with PSC cataract and new baseline measurements may be required. Also, **Kremmer et al.** (2003) found that dense cataract led to an underestimation of NFL thickness. On the other hand, **Vetruigno et al.** (2004) had shown no statistically significant differences between SLP parameters before and after cataract surgery, regardless of the type of IOL implanted, and **Collur et al.** (2000) suggested that there was no change after cataract extraction.

Garcia-Martin et al. (2013) had evaluated the effect of uncomplicated phacoemulsification on macular and retinal NFL thickness using two SD-OCT instruments, Cirrus OCT and Spectralis OCT, in patients having non-insulin-dependent diabetes mellitus (NIDDM) without retinopathy and their results have shown that retinal NFL thicknesses provided by Cirrus and Spectralis OCT and macular measurements provided by Cirrus OCT increased significantly 1 month after surgery, while macular thicknesses provided by Spectralis OCT before and after surgery were not significantly different.

Opposite to the previous studies, the present study did not include diabetic or glaucomatous patients. As glaucoma is characterized by accelerated death of

retinal ganglion cells and their retinal NFL, and NIDDM predisposes patients to macular edema, diabetic retinopathy and optic nerve damage.

Results of the present study had shown that the average NFL M thickness increased by 9.8 μm (11 %) 5 weeks after uncomplicated phacoemulsification and this increase was statistically significant. This was supportive to **Kremmer et al.** (2003), **Gazzard et al.** (2004), and **Garcia-Martin et al.** (2013) results. The present study had also shown the participants' foveal M thickness increased by 26.15 μm (15%) postoperatively, and this increase was also statistically significant.

In contrast to **Kremmer et al.** (2003) and **Gazzard et al.** (2004), the present study did not include participants with dense or PSC cataract to avoid artifacts and low quality images which may affect the results reliability.

Mwanza et al. (2011) had evaluated the effect of cataract on the signal strength (SS) of OCT images and the peripapillary NFL thickness measurements using Stratus OCT scans in glaucomatous and non-glaucomatous patients, and they had used the Lens Opacities Classification System III for cataract grading. Their results had shown that there was a greater postoperative increase in retinal NFL thickness measurements in patients with lower preoperative retinal NFL measurements and SS, while eyes with preoperative SS more than 6 had no significant difference between precataract and postcataract surgery retinal NFL thickness. The present study used 2002 WHO cataract grading scale (**Thylefors et al.**, 2002), and included participants with

only 1+ cataract and images with SS more than 6, and the increase in the minimum, average and maximum peripapillary NFL M measurements postoperatively was extremely statistically significant.

Myopic eyes have thinner RNFL measurements, and can have unique distributions of RNFL bundles (Yi et al., 2017). So, participants with high myopia were excluded from the present study.

Lee et al. (2010) had concluded that cortical and PSC cataract can affect retinal NFL thickness measurements, while nuclear cataract was not found to affect SS or retinal NFL thickness measurements. The results of the present study were different. All the participants with NS 1+ had increased M peripapillary NFL thickness measurements postoperatively.

The present study involved exclusion of patients with changeable NFL and foveal parameters such as diabetic and glaucomatous patients, and exclusion of the patients with denser cataract or patients that developed postoperative PCO to gain as clear images and reliable results as possible. In addition, all patients had cataract extraction by the same phacoemulsification machine, and had the same type of implanted IOL.

The shortage points of the study included low number of the participants but it may be due to strict ocular and systemic exclusion criteria. The present work did not answer if the postoperative increase in the peripapillary NFL and foveal measurements occurred due to clearing the media after cataract extraction or due to the optical effect of IOL material. Further studies on different types of IOLs are needed.

CONCLUSION

Peripapillary NFL and foveal thickness measurements may increase significantly after uncomplicated phacoemulsification with in bag foldable IOL implantation.

The occurrence of cataract may reduce the peripapillary NFL OCT measurements. This reduction may be falsely diagnosed as glaucoma progression. So, regular slit lamp examination of the lens and optic disc, regular intraocular pressure measurement and VF assessment are very important during follow up of ocular hypertensive and glaucomatous patients.

The increased foveal measurements after phacoemulsification in diabetic patients may be falsely diagnosed as progression of diabetic maculopathy. So, postoperative slit lamp biomicroscopy, functional assessments using color vision, contrast sensitivity and Amsler's grid testing, repeated imaging by OCT and further investigations if needed such as OCT angiography are important.

The SS, the images artifacts, the patient cooperation, and any factors causing media opacity should be taken into consideration during OCT imaging, and clear images with reliable SS only can be used efficiently.

Detailed general and ophthalmological history, full ophthalmological examination and previous investigations should be taken into consideration when patients are followed up using OCT.

REFERENCES

1. Collur S, Carroll AM and Cameron BD (2000): Human lens effect on in vivo scanning laser polarimetric measurements of retinal nerve fiber layer thickness. *Ophthalmic Surg Lasers*, 31 (2): 126-30.

2. **Darma S, Kok PH, Berg TJ, Abramoff MD, Faber DJ, Hulsman CA, Zantvoord F, Mourits MP, Schlingemann RO and Verbraak FD** (2015): Optical density filters modeling media opacities cause decreased SD-OCT retinal layer thickness measurements with inter- and intra-individual variation. *Acta Ophthalmol.*, 93(4): 355-61.
3. **Franz F, Edgar E, Lang AG and Buchner A** (2007): A flexible statistical power analysis program for the social, behavioral and biomedical sciences. *Research Methods*, 39 (2): 175-91.
4. **Garcia-Martin E, Fernandez J, Gil-Arribas L, Polo V, Larrosa JM, Otin S, Fuertes I, and Pablo L** (2013): Effect of Cataract Surgery on Optical Coherence Tomography Measurements and Repeatability in Patients With Non-Insulin-Dependent Diabetes Mellitus. *Investigative Ophthalmology & Visual Science*, 54 (8): 5303-12.
5. **Gazzard G, Foster PJ, Devereux JG, Oen F, Chew PT, Khaw PT and Seah SK** (2004): Effect of cataract extraction and intraocular lens implantation on nerve fibre layer thickness measurements by scanning laser polarimeter (GDx) in glaucoma patients. *Eye*, 18 (2): 163-68.
6. **Grewal DS and Tanna AP** (2013): Diagnosis of glaucoma and detection of glaucoma progression using spectral domain optical coherence tomography. *Curr Opin Ophthalmol.*, 24 (2): 150-61.
7. **Kremmer S, Garway-Heath DF, De Cilla S, Steuhl KP and Selbach JM** (2003): Influence of cataract surgery with implantation of different intraocular lenses on scanning laser tomography and polarimetry. *Am J Ophthalmol.*, 136 (6): 1016-21.
8. **Kwak AY, Park SK and Kim CY** (2017): Analysis of changes in individual retinal layer thickness after cataract surgery using spectral-domain optical coherence tomography. *Acta Ophthalmol.*, 95(10): 1755-3768.
9. **Lathika VK, Minu SP and Charles KS** (2017): Influence of cataract on image quality and macular thickness measured using spectral domain optical coherence tomography: a prospective cohort study. *Int J Adv Med.*, 4(2):546-50.
10. **Lee DW, Kim JM and Park KH** (2010): Effect of media opacity on retinal nerve fiber layer thickness measurements by optical coherence tomography. *J Ophthalmol Vis Res.*, 5 (3): 151-57.
11. **Leite MT, Rao HL, Weinreb RN, Zangwill LM, Bowd C, Sample PA, Tafreshi A and Medeiros FA** (2011): Agreement among spectral-domain optical coherence tomography instruments for assessing retinal nerve fiber layer thickness. *Am J Ophthalmol.*, 151 (1): 85-92.
12. **Moutray TN, Williams MA and Jackson AJ** (2008): Change of visual acuity recording methods in clinical studies across the years. *Ophthalmologica*, 222 (3): 173-77.
13. **Mwanza JC, Bhorade AM and Sekhon N** (2011): Effect of cataract and its removal on signal strength and peripapillary retinal nerve fiber layer optical coherence tomography measurements. *J Glaucoma*, 20 (10): 37-43.
14. **Rao HL, Addepalli UK, Yadav RK, Choudhari NS and Senthil S** (2014): Factors affecting the ability of the spectral domain optical coherence tomography to detect photographic retinal nerve fiber layer defects. *PLOS ONE*, 9 (12): 115-16.
15. **Thylefors B, Chylack LT, Konyama K, Sasaki K, Sperduto R, Taylor HR and West S** (2002): A simplified cataract grading system. *Ophthalmic Epidemiology*, 9 (2): 83-95.
16. **Vetrugno M, Trabucco T, Sisto D and Sborgia C** (2004): Effect of cataract surgery and foldable intraocular lens implantation on retinal nerve fiber layer as measured by scanning laser polarimetry with variable corneal compensator. *Eur J Ophthalmol.*, 14 (2): 106-10.
17. **Yi Z, Jinfei Z, Da L, Wangqiang F, Haihua Z and Jianqui C** (2017): Evaluation of myopia on retinal nerve fiber layer thickness measured by Spectralis optical coherence tomography. *Exp Ther Med.*, 14(3):2716-20.

تقييم تغير قياسات سمك طبقة الألياف العصبية المحيطة بقرص العصب البصري و سمك مركز الماقولة بعد إزالة المياه البيضاء باستخدام الماسح البصري المقطعي التوافقي في الأشخاص غير المصابين بمرض السكر أو الجلوكوما

مصطفى فريد محمد

قسم طب و جراحة العين، كلية الطب، جامعة الأزهر (القاهرة – جمهورية مصر العربية)

خلفية البحث: يستخدم الماسح البصري المقطعي التوافقي على نطاق واسع لتشخيص ومتابعة أمراض الشبكية مثل اعتلال الشبكية السكري، كما يستخدم أيضاً لقياس سمك طبقة الألياف العصبية المحيطة بقرص العصب البصري مما يجعله مفيداً للتشخيص المبكر والمتابعة لمرضى الجلوكوما. وقد أثبتت الدراسات السابقة أن وجود المياه البيضاء المصحوب بتدهور ملحوظ في حدة الإبصار يسبب امتصاص و تبعثر الضوء مما يقلل من جودة ودقة قياسات سمك طبقة الألياف العصبية و سمك مركز الإبصار باستخدام الماسح البصري المقطعي التوافقي. ولم تتم دراسة تأثير المياه البيضاء من الدرجة الأولى و التي تسمح بتصوير الشبكية بدرجة وضوح مقبولة على هذه القياسات بنطاق واسع.

الهدف من البحث: تقييم التغيرات التي تحدث في قياسات الماسح البصري المقطعي التوافقي لسمك طبقة الألياف العصبية المحيطة بقرص العصب البصري وسمك مركز الماقولة بعد إزالة المياه البيضاء بتقنياتها وتذويبها باستخدام الموجات فوق الصوتية وزرع عدسة لينة في المحفظة الخلفية للعين.

المرضى وطرق البحث: أجريت الدراسة على 20 عيناً لعشرين من المرضى (12 سيدة و 8 رجال)؛ والمصابين بالمياه البيضاء العمرية من الدرجة الأولى طبقاً لمقياس منظمة الصحة العالمية بعد إستبعاد الأشخاص المصابين بالأمراض المزمنة مثل السكر وإرتفاع ضغط الدم، وكذلك استبعاد الأشخاص المصابين بعتامات شديدة لعدسة العين، كما تم أيضاً إستبعاد الأشخاص المصابين بقصر النظر الشديد والجلوكوما وإعتلال الماقولة.

وقد تم تسجيل التاريخ الشخصي والمرضي أثناء الفحص المبدئي، وتم عمل الفحص الإكلينيكي الكامل للعين متضمناً فحص حدة الإبصار بعد تصحيح عوامل الإنكسار والفحص بالمنظار الشقي وقياس ضغط العين و الفحص التفصيلي لقاع العين بعد توسيع حدقة العين، وقد تم استخدام الماسح البصري المقطعي التوافقي لقياس سمك طبقة الألياف العصبية المحيطة بقرص العصب

البصري و سمك مركز الماقولة قبل جراحة المياه البيضاء وبعد مرور خمسة أسابيع من الجراحة بمستشفى الحسين الجامعي .

النتائج: كان المتوسط العمري للمرضى: 1.9 ± 56.65 عاماً. وكان متوسط حدة الإبصار بعد التصحيح بالنظارة قبل الجراحة: 0.1 ± 0.3 ، و قد ارتفع متوسط حدة الإبصار بعد إزالة المياه البيضاء إلى 0.6 ± 0.1 . وكانت قوة إشارة صور الماسح البصري المقطعي ≤ 6 مما أعطى درجة وضوح مقبولة لجميع الصور قبل و بعد إزالة المياه البيضاء.

وكانت أهم نتائج هذه الدراسة حدوث إرتفاع إحصائي هام في قياسات الماسح البصري المقطعي التوافقي لسمك طبقة الألياف العصبية المحيطة بقرص العصب البصري وسمك مركز الماقولة عند متابعة المرضى بعد خمسة أسابيع من جراحة المياه البيضاء، فقد ارتفع متوسط قياس سمك طبقة الألياف العصبية المحيطة بقرص العصب البصري بنسبة 11% من 89.80 ± 6.69 ميكرون قبل الجراحة ليصبح 99.6 ± 3.82 ميكرون بعد جراحة المياه البيضاء، كما ارتفع متوسط قياس سمك مركز الماقولة بنسبة 15% من 172.10 ± 50.05 ميكرون قبل الجراحة ليصبح 198.25 ± 27.95 ميكرون بعد جراحة المياه البيضاء.

الاستنتاج: إن قياسات الماسح البصري المقطعي التوافقي لسمك طبقة الألياف العصبية المحيطة بقرص العصب البصري و سمك مركز الماقولة قد ترتفع بعد إزالة المياه البيضاء باستخدام الموجات فوق الصوتية وزرع عدسة لينة في المحفظة الخلفية للعين، فينبغي الأخذ بعين الإعتبار تأثير وجود المياه البيضاء في تقليل قياسات سمك طبقة الألياف العصبية وسمك مركز الإبصار أثناء المتابعة الدورية لبعض الأمراض مثل الجلوكوما و الإعتلال السكري. وفي ضوء هذه النتائج ينبغي الإهتمام بتسجيل التاريخ المرضي والفحص الإكلينيكي الشامل للعين و مقارنة الفحوصات السابقة للمرضى عند متابعتهم باستخدام الماسح البصري المقطعي التوافقي وتسجيل حدوث أي تغيرات قد تؤثر على دقة القياسات مثل حدوث المياه البيضاء.