

## EFFECT OF ESTROGEN ADMINISTRATION ON THE STRUCTURE OF TESTIS IN THE NEONATAL ALBINO RATS

By

**Sherif Mohamed Zaky, Tarek A. El-Ghamrawy and Mira Farouk Youseff\***

Departments of Anatomy and Histology\*, Faculty of Medicine,  
Cairo University.

### INTRODUCTION

Environmental contaminants with estrogenic properties increased the concern about their possible role in inducing adverse health effects. Brief exposure of rodents to high doses of natural estrogens in early life results in permanent alterations of the male reproductive organs, but the question of whether environmentally relevant doses can cause the same effects remains controversial (**Putz et al., 2001**).

Many reports in the literature demonstrated that exposure of the fetal, neonatal male rodent and/or human to exogenous estrogenic compounds (estradiol, ethinyl estradiol, or diethylstilbestrol) can cause a range of abnormalities of the reproductive system including atrophic/small testes, epididymal cysts, abnormalities of the rete testis, delayed puberty, etc. (**Arai et al., 1983; Newbold et al., 1985; Gaytan et al., 1986; Toppari et al., 1996**).

Estrogens administered to perinatal rats caused spermatogenesis impairment (**Aceitero et al., 1998**). Impairment of spermatogenesis had a short- and long-term effects linked to perinatal exposure to estrogens (**Vitale et al., 1973; McLachlan et al., 1975; Chemes et al., 1976**), although the mechanisms by which estrogens exerted this effect remain unclear (**Giusti et al., 1995**).

The aim of this study is to determine whether estrogen administered to neonatal male rats caused impairment of spermatogenesis and to determine the short- and long-term effects of this impairment. This was done through histological, morphometric and immunohistochemical assessment of the testis.

### MATERIALS AND METHODS

Forty neonatal male albino rats were used in this study. They were kept under good hygienic conditions, fed *ad libitum* and allowed free water supply. These animals were divided into control and experimental groups and each group was kept in a separate cage as follows:

**Control group** consisted of eight rats. They received subcutaneous injection of olive oil using the time schedule as the experimental rats. Two of the control rats were sacrificed with each of the experimental subgroups.

**Experimental group** consisted of thirty two rats. They were injected with estrogen (Folone ampoule, 5 mg / 1ml) (Misr Co.). The ampoule was diluted in 10 ml olive oil and the dose used for rats was 500 µg/ rat (**Tena et al., 2000**); beginning on postnatal day 2 (day of birth = day 1). Rats were subjected to subcutaneous injection on days 2, 4, 6, 8, 10, and 12 (**Sharpe et al., 1998**). This group was divided into 4 subgroups each of which consisted of eight rats and the rats were sacrificed at the age of 18, 25, 35 and 90 days.

Rats were sacrificed on days 18, 25, and 35, to study functional development of the testis in early puberty, and on day 90 to assess the final outcome of the treatment on the morphology of the testis (**Sharpe et al., 1998**).

The animals were sacrificed by a high dose of ether, then dissected and their testes were fixed in buffered formol saline and processed for paraffin sections of 5µm thickness. Sections were stained with Hx and E. for histological study (**Bancroft et al., 1996**), inhibin α Ab-1(clone R1) mouse monoclonal antibody and androgen receptors for immunohistochemical study (**Sharpe et al., 1998**) provided by Lab. vision corporation by A.M. Egypt.

Quantitative analysis of the testes using the image analyzer was done. The image analyzer consisted of an Olympus BX-40 microscope (Olympus Optical Co. Ltd., Japan), equipped with Panasonic video camera (Panasonic colour CCTV camera, Matsushita Communication Industrial Co. Ltd., Japan). The video images were then digitized using Leica Qwin software (Leica's Windows based image analysis toolkit, Leica Imaging Systems Ltd., Cambridge, England) fitted to an IBM personal computer with a colour monitor.

Sections stained with Hx. and E., inhibin α and androgen receptors (AR) were examined by the use of the image analyzer computer system using the software Leica Qwin 500 in various animal groups. The image analyzer was automatically calibrated with various objective lenses. Using the objective lens 10 i.e. at a magnification of 100, the tubular diameter (TD) (Fig.1-a) and seminiferous epithelial height (SEH) (Fig.1-b) were measured in ten fields in each specimen. Hundred readings were obtained in each specimen. TD/SEH was calculated. Mean values of TD, SEH and TD/SEH were obtained. This was repeated for all animals and the mean for each group was calculated. The mean of each group was compared with that of control group using student "t" test (**Mould, 1989**).

The Optical density of nuclear androgen receptor immunoexpression was measured in the nuclei of Sertoli cells using the grey measure menu in ten measuring frames in each specimen using an objective lens of magnification 40 i.e. at a total magnification of 400 after grey calibration. A

field was chosen (Fig.2-a) and the image was transformed into a grey image and then delineated to choose the areas exhibiting positive reactivity with accumulation of minimum and maximum grades of reactivity. The parameters chosen were the number of pixels, sum of grey and mean grey. The optical density was expressed in the form of mean grey that was obtained by the following equation

$$\text{Mean grey} = \frac{\text{No. of pixels}}{\text{Sum of grey}}$$

Optical density was measured inside small measuring frames (the positively reacting areas were measured by a blue binary colour = pixels) (Fig.2-b).

## RESULTS

### I- Histological studies

#### (a) Animals sacrificed at the age of 18 days

The seminiferous tubules of the **control group** showed the normal architecture. Both spermatogonia and primary spermatocytes were present (Fig.3-a). The tubules of the **estrogen-treated group** showed congested vessels, the cells were mostly Sertoli cells and there was excessive interstitium between the tubules (Figs. 3-b,c,d).

#### (b) Animals sacrificed at the age of 25 days

The seminiferous tubules of the **control group** showed the normal architecture. Both spermatogonia and Sertoli cells were present (Fig.4-a). The tubules of the **estrogen-treated group** showed mostly Sertoli cells, dilated rete testis, degenerated spermatocytes, apoptotic cells, degenerated Sertoli cells and normal Leydig cells (Figs. 4-b,c,d). In some specimens there were thickened basal laminae of seminiferous tubules, hypertrophied myoid cells around rete testis, hemorrhage inside the tubules, with the presence of Sertoli cells and myoid cells only in these tubules (Figs. 5-a,b,c,d).

#### (c) Animals sacrificed at the age of 35 days

The seminiferous tubules of the **control group** showed normal architecture. Spermatogonia were present in more than one layer (Fig.6-a). Some tubules of the **estrogen-treated group** were normal and others exhibited dilated wide lumina, interstitial cellular infiltration and dislodged cells. Dislodged cells were also seen in the rete testis (Figs. 6-b,c,d). Some specimens showed mast cells in the interstitial tissue, degenerated spermatogenic cells with margination of chromatin and pyknosis. The nuclei of Sertoli cells were pale with prominent nucleoli (Fig. 7-a). Most of the rete testis exhibited discrete dislodged cells while one of them showed

a mass of spermatogenic cells (Figs.7-b,c). In some specimens there were degenerated primary spermatocytes and dislodged spermatogenic cells, in others there were normal spermatocytes (Figs. 8-a,b). Few specimens exhibited primary spermatocytes with irregular outline of seminiferous tubules (Fig. 8-c).

**(d) Animals sacrificed at the age of 90 days:**

The seminiferous tubules of the **control group** showed normal architecture. Sertoli cells, spermatogonia and spermatids were present (Fig. 9-a). The tubules of the **estrogen-treated group** showed sparse spermatogenic cells with interstitial oedema. Also, multinucleated giant cells, primary spermatocytes and macrophages with brown hemosiderin granules were observed (Figs. 9-b,c).

**II- Immunohistochemical study**

**a) Inhibin  $\alpha$  stained sections**

Cross sections in the testes of control and estrogen-treated rats at the age of 18 and 90 days showed moderate cytoplasmic reaction of Sertoli cells (Figs. 10-a,b, 11-a,b). In some specimens there were few spermatogenic cells, large vacuoles of Sertoli cells and junction between their processes (Fig. 11-c).

**b) Androgen receptor stained sections**

Cross sections in the testes of control and estrogen-treated rats at the age of 18 and 90 days showed strong nuclear reaction of Sertoli cells and myoid cells (Figs. 12-a,b).

**III- Morphometric study**

**1- Tubular diameter (TD)**

**Table (1):** Mean seminiferous tubular diameter (TD in  $\mu\text{m}$ ) in control and estrogen-injected groups.

Age in days	Mean of control group $\pm$ SD	Mean of estrogen group $\pm$ SD
18	91.6 $\pm$ 8.7	76.8* $\pm$ 8.0
25	112.1 $\pm$ 17.6	81.6* $\pm$ 11.2
35	172.8 $\pm$ 23.6	94.4* $\pm$ 12.2
90	261.4 $\pm$ 37.8	173.6* $\pm$ 27.1

\* = Statistically significant ( $p \leq 0.05$ ) compared to their respective control groups.

There was a statistically significant decrease in the tubular diameter (TD) in the testes in all estrogen-treated groups compared to the control groups (Table 1).

## 2- Seminiferous epithelial height (SEH)

**Table (2):** Mean seminiferous epithelial height (SEH in  $\mu\text{m}$ ) in control and estrogen-treated groups.

Age in days	Mean of control group $\pm$ SD	Mean of estrogen group $\pm$ SD
18	32.0 $\pm$ 4.9	22.1* $\pm$ 5.2
25	39.3 $\pm$ 6.1	21.2* $\pm$ 3.8
35	52.0 $\pm$ 8.7	21.5* $\pm$ 3.5
90	74.2 $\pm$ 10.0	45.8* $\pm$ 6.2

\* = Statistically significant ( $p \leq 0.05$ ) compared to their respective control groups.

There was a statistically significant decrease in the seminiferous epithelial height (SEH) in the testes in all estrogen-treated groups compared to the control groups (Table 2).

## 3- Tubular diameter/ seminiferous epithelial height (TD/SEH)

**Table (3):** Mean tubular diameter to seminiferous epithelial height ratio in control and estrogen-treated groups.

Age in days	Mean of control group $\pm$ SD	Mean of estrogen group $\pm$ SD
18	2.9 $\pm$ 0.5	3.6* $\pm$ 0.8
25	2.9 $\pm$ 0.6	3.9* $\pm$ 0.8
35	3.4 $\pm$ 0.7	4.5* $\pm$ 0.9
90	3.5 $\pm$ 0.7	3.8* $\pm$ 0.8

\* = Statistically significant ( $p \leq 0.05$ ) compared to their respective control groups.

There was a statistically significant increase in the TD/SEH in the testes in all estrogen-treated groups compared to the control groups (Table 3).

**4- Optical density of cytoplasmic reaction of Sertoli cells in inhibin  $\alpha$  in various animal groups (mean values)**

**Table (4):** Mean optical density of cytoplasmic reaction of Sertoli cells in inhibin  $\alpha$  immunostain in control and estrogen-treated groups.

Duration:	Mean of control group $\pm$ SD	Mean of estrogen group $\pm$ SD
18	0.35 $\pm$ 0.06	0.3* $\pm$ 0.06
25	0.36 $\pm$ 0.07	0.32 $\pm$ 0.06
35	0.38 $\pm$ 0.06	0.32* $\pm$ 0.06
90	0.39 $\pm$ 0.07	0.33* $\pm$ 0.07

\* = Statistically significant ( $p \leq 0.05$ ) compared to their respective control groups.

There was a statistically significant decrease in the cytoplasmic reaction in estrogen-treated rats which were sacrificed at the ages of 18, 35 and 90 days compared to the control groups (Table 4).

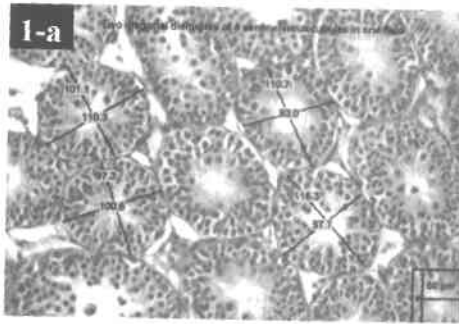
**5- Optical density of nuclear AR immune reaction in various animal groups (mean values)**

**Table (5):** Mean optical density of nuclear AR immune reaction in control and estrogen-treated groups.

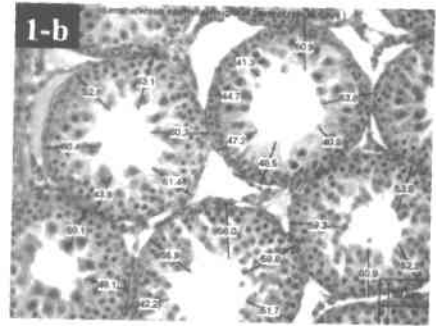
Age in days	Mean of control group $\pm$ SD	Mean of estrogen group $\pm$ SD
18	0.68 $\pm$ 0.1	0.6* $\pm$ 0.1
25	0.69 $\pm$ 0.1	0.63* $\pm$ 0.1
35	0.69 $\pm$ 0.1	0.65* $\pm$ 0.1
90	0.70 $\pm$ 0.1	0.69 $\pm$ 0.1

\* = Statistically significant ( $p \leq 0.05$ ) compared to their respective control groups.

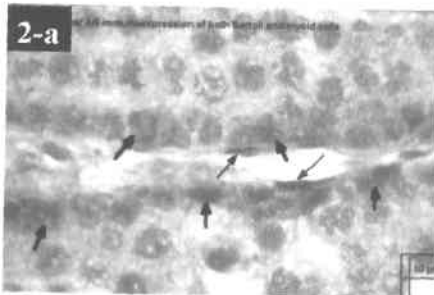
There was a statistically significant decrease in the nuclear AR immune reaction in estrogen-treated rats which were sacrificed at the ages of 18, 25 and 35 days compared to the control groups (Table 5).




**Fig. (1-a):** Photomicrograph representing the image expressed on the monitor of the image analyzer and showing the way of measurement of tubular diameters (TD). (Hx. & E.;  $\times 100$ )



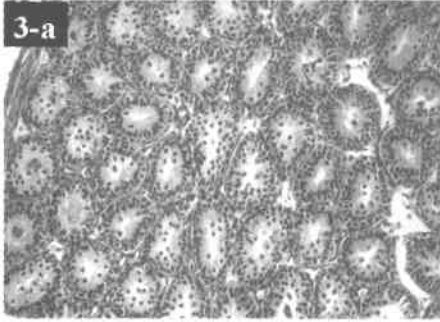
**Fig. (1-b):** Photomicrograph representing the image expressed on the monitor of the image analyzer and showing the way of measurement of seminiferous epithelial height (SEH). (Hx. & E.;  $\times 100$ )



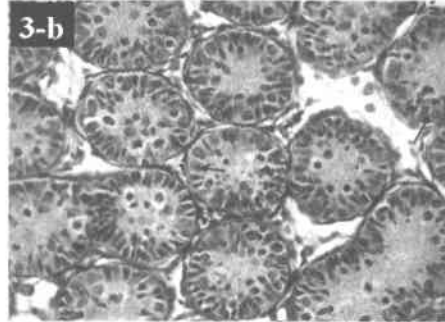
**Fig. (2-a):** Photomicrograph representing the image expressed on the monitor of the image analyzer and showing nuclear AR immunostaining of both Sertoli cells (thick arrows) and myoid cells (thin arrows). (AR immunostaining;  $\times 400$ )



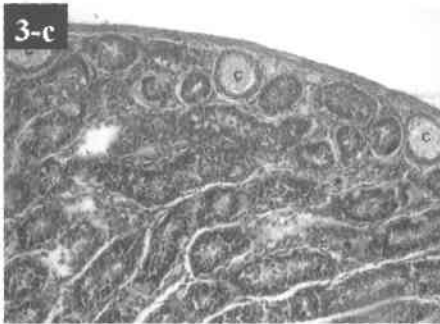
**Fig. (2-b):** Photomicrograph representing the image expressed on the monitor of the image analyzer and showing binary image of nuclear AR immunostaining masked by a blue binary colour inside small measuring frame to measure optical density. (AR immunostaining;  $\times 400$ )



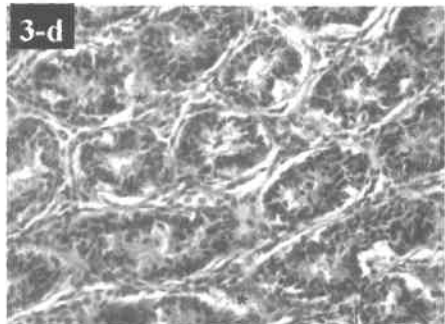
**Fig. (3-a):** Photomicrograph of cross section in the testis of a control rat at the age of 18 days showing normal architecture. Note the presence of both spermatogonia and primary spermatocytes (S1). (Hx. & E.;  $\times 200$ )



**Fig. (3-b):** Photomicrograph of cross section in the testis of an estrogen-treated rat at the age of 18 days showing mostly Sertoli cells (arrows). (Hx. & E.;  $\times 400$ )

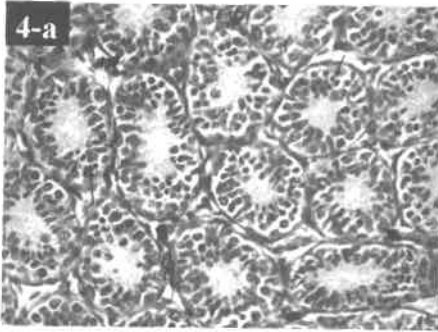


**Fig. (3-c):** Photomicrograph of cross section in the testis of an estrogen-treated rat at the age of 18 days showing congested vessels (C) and excessive interstitium (\*) between seminiferous tubules. (Hx. & E.;  $\times 200$ )

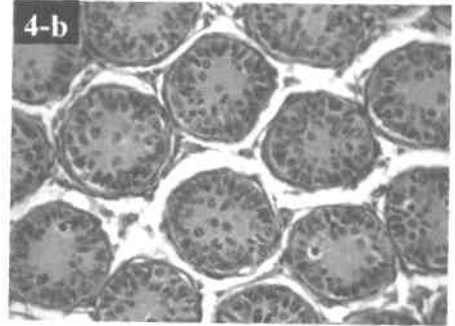


**Fig. (3-d):** Photomicrograph of cross section in the testis of an estrogen-treated rat at the age of 18 days showing excessive interstitium (\*) between seminiferous tubules. (Hx. & E.;  $\times 400$ )

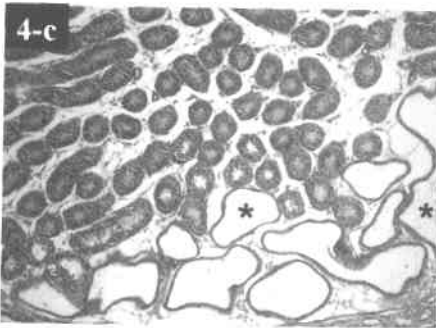




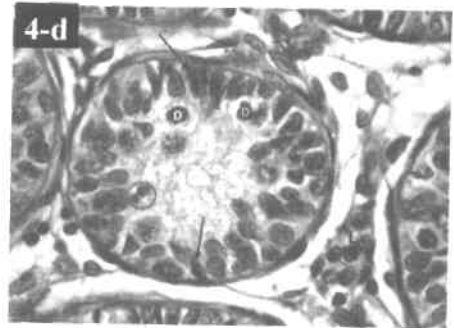
**Fig. (4-a):** Photomicrograph of cross sections of a control rat at the age of 25 days showing normal architecture. Note the presence of spermatogonia (thin arrows) and Sertoli cells (thick arrows). (Hx. & E.;  $\times 400$ )



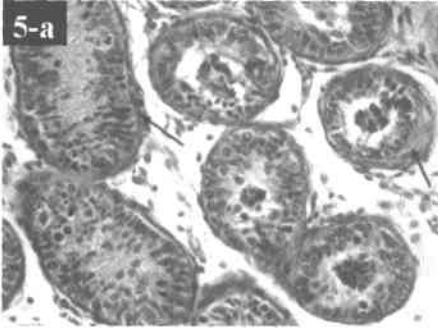
**Fig. (4-b):** Photomicrograph of cross section in the testis of an estrogen-treated rat at the age of 25 days showing mostly Sertoli cells (arrows). (Hx. & E.;  $\times 400$ )



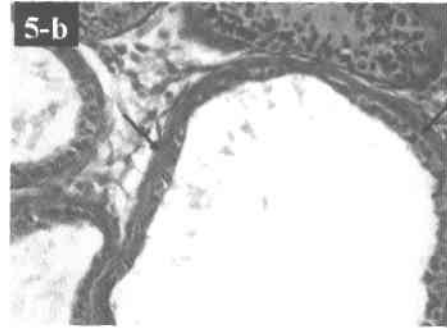
**Fig. (4-c):** Photomicrograph of cross section in the testis of an estrogen-treated rat at the age of 25 days showing dilated rete testes (\*). (Hx. & E.;  $\times 100$ )



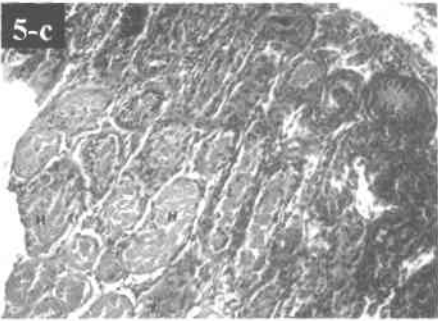
**Fig. (4-d):** Photomicrograph of cross section in the testis of an estrogen-treated rat at the age of 25 days showing degenerated spermatocytes (D), apoptotic spermatogenic cells (encircle), degenerated Sertoli cells (arrows) and normal Leydig cells (L). (Hx. & E.;  $\times 1000$ )



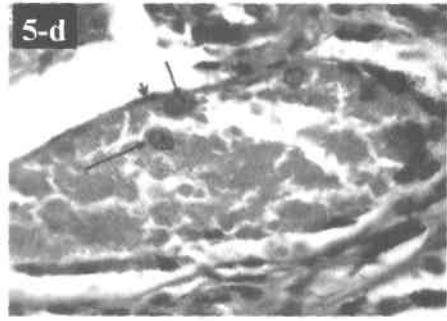
**Fig. (5-a):** Photomicrograph of cross section in the testis of an estrogen-treated rat at the age of 25 days showing thickened basal laminae of the seminiferous tubules (arrows). (Hx. & E.;  $\times 400$ )



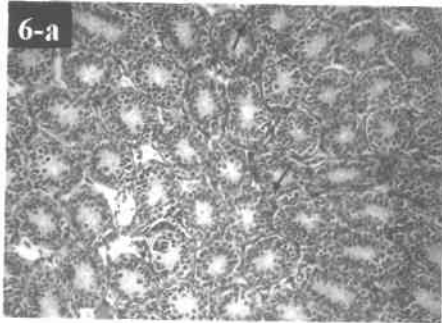
**Fig. (5-b):** Photomicrograph of cross section in the testis of an estrogen-treated rat at the age of 25 days showing hypertrophied myoid cells (arrows) around rete testis. (Hx. & E.;  $\times 400$ )



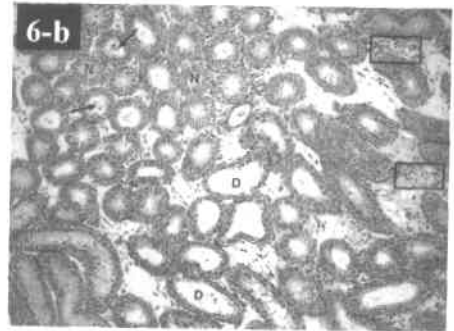
**Fig. (5-c):** Photomicrograph of cross section in the testis of an estrogen-treated rat at the age of 25 days showing hemorrhage inside the tubules (H). (Hx. & E.;  $\times 200$ )



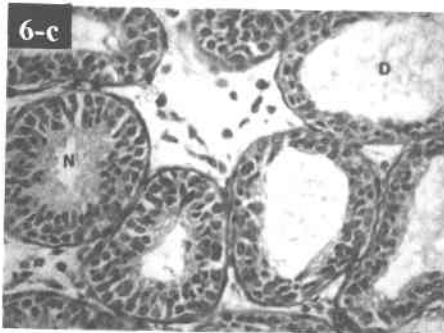
**Fig. (5-d):** Higher magnification of the previous section showing only nuclei of Sertoli cells (long arrows), myoid cells (short arrows) and hemorrhage. (Hx. & E.;  $\times 1000$ )



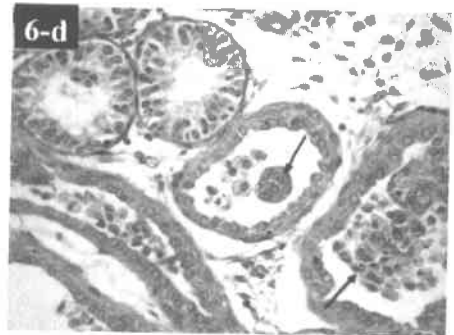
**Fig. (6-a):** Photomicrograph of cross section in the testis of a control rat at the age of 35 days showing normal architecture. Note the presence of spermatogonia in more than one layer (arrows). (Hx. & E.;  $\times 200$ )



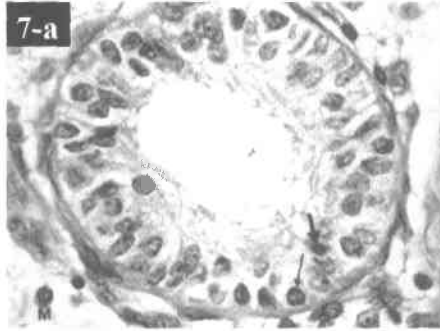
**Fig. (6-b):** Photomicrograph of cross section in the testis of an estrogen-treated rat at the age of 35 days showing some normal tubules (N), some tubules with dilated wide lumina (D), interstitial cellular infiltration (boxed areas) and dislodged cells (arrows). (Hx. & E.; 100)



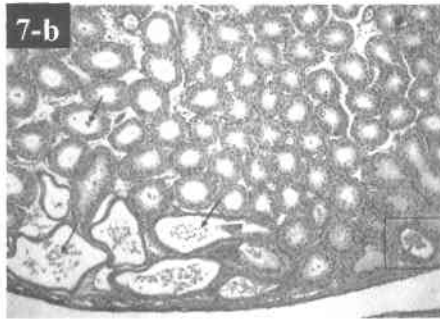
**Fig. (6-c):** Higher magnification of the previous section. Note the presence of dilated tubules (D) and normal tubules (N). (Hx. & E.; 400)



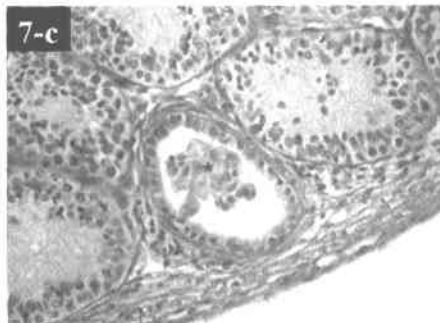
**Fig. (6-d):** Photomicrograph of cross section in the testis of an estrogen-treated rat at the age of 35 days showing normal tubules and rete testes with dislodged cells (arrows). (Hx. & E.; 400)



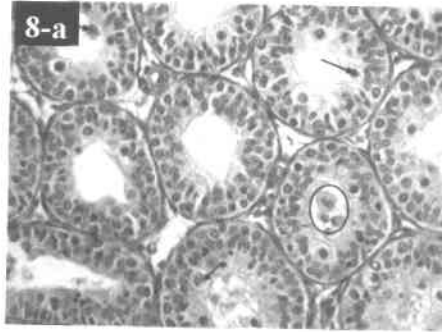
**Fig. (7-a):** Photomicrograph of cross section in the testis of an estrogen-treated rat at the age of 35 days showing mast cells in interstitial tissue (M), degenerated spermatogenic cells with margination of chromatin (thin arrow) and pyknosis (thick arrow). Note that the Sertoli cells have pale nuclei with prominent nucleoli. (Hx. & E.;  $\times 1000$ )



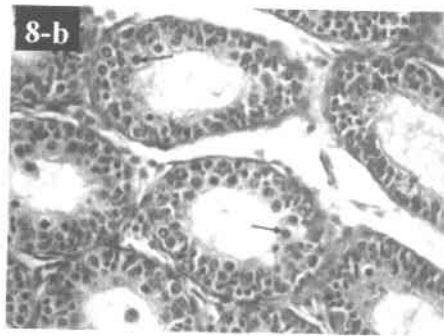
**Fig. (7-b):** Photomicrograph of cross section in the testis of an estrogen-treated rat at the age of 35 days showing most of the rete testis with discrete dislodged cells (arrows), while one of them in the boxed area shows a mass of spermatogenic cells. (Hx. & E.;  $\times 100$ )



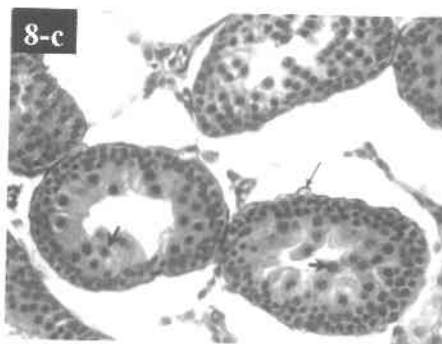
**Fig. (7-c):** Higher magnification of the boxed area in the previous figure. Note dislodged spermatogenic cells (\*). (Hx. & E.;  $\times 400$ )



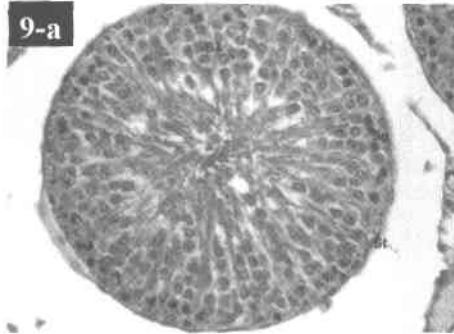
**Fig. (8-a):** Photomicrograph of cross section in the testis of an estrogen-treated rat at the age of 35 days showing degenerated primary spermatocytes (arrows) and dislodged spermatogenic cells (encircled). (Hx. & E.;  $\times 400$ )



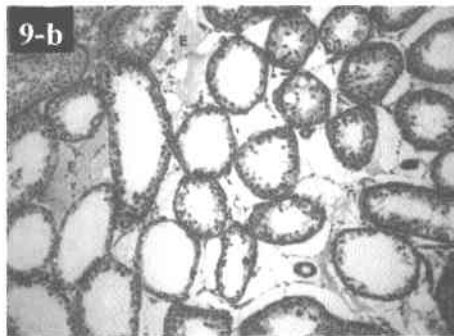
**Fig. (8-b):** Photomicrograph of cross section in the testis of an estrogen-treated rat at the age of 35 days showing normal spermatocytes (arrows). (Hx. & E.;  $\times 400$ )



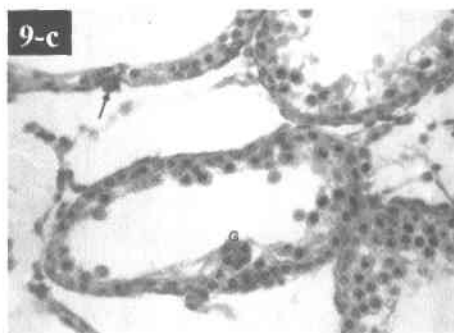
**Fig. (8-c):** Photomicrograph of cross section in the testis of an estrogen-treated rat at the age of 35 days showing irregular outline of seminiferous tubules (thin arrow). Note the presence of primary spermatocytes (thick arrows). (Hx. & E.;  $\times 400$ )



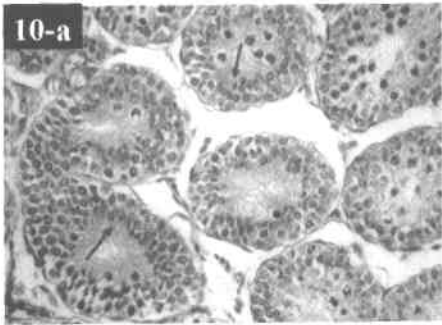
**Fig. (9-a):** Photomicrograph of cross section in the testis of a control rat at the age of 90 days showing a normal architecture. Note the presence of Sertoli cells (St), spermatogonia (Sg) and spermatids (S3). (Hx. & E.; 400)



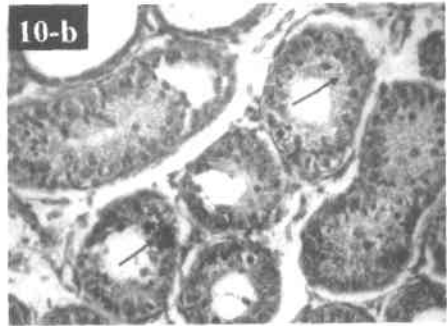
**Fig. (9-b):** Photomicrograph of cross section in the testis of an estrogen-treated rat at the age of 90 days showing sparse spermatogenic cells with interstitial oedema (E). (Hx. & E.; 100)



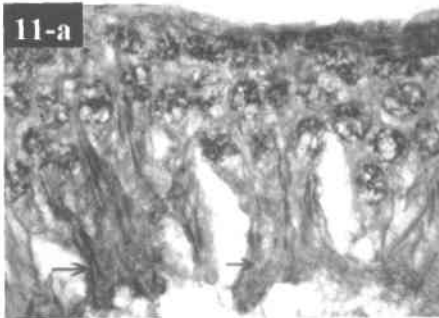
**Fig. (9-c):** Photomicrograph of cross section in the testis of an estrogen-treated rat at the age of 90 days showing multinucleated giant cells (G), primary spermatocytes and macrophage with brown hemosiderin granules (arrow). (Hx. & E.; 400)



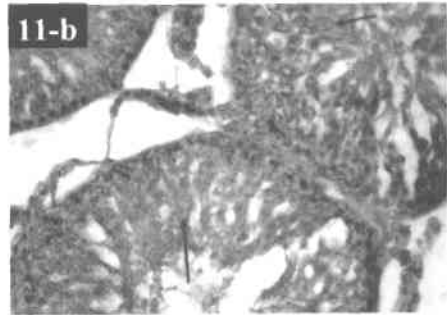
**Fig. (10-a):** Immunohistochemical labeling of cross sections in the testis of a control rat the age of 18 days showing moderate cytoplasmic reaction of Sertoli cells (arrows). (Inhibin  $\alpha$ ;  $\times 400$ )



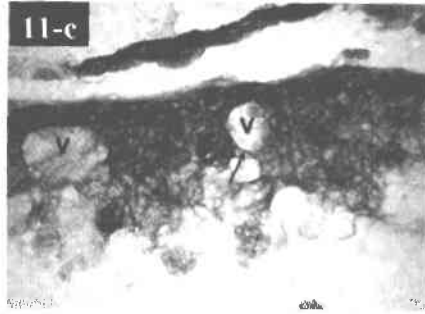
**Fig. (10-b):** Immunohistochemical labeling of cross sections in the testis of an estrogen-treated rat the age of 18 days showing moderate cytoplasmic reaction of Sertoli cells (arrows). (Inhibin  $\alpha$ ;  $\times 400$ )



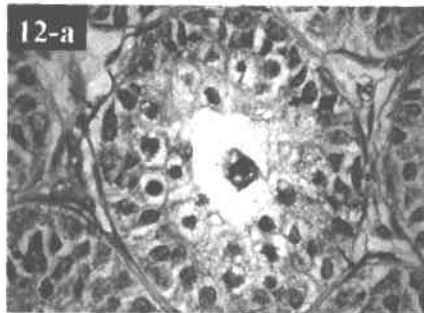
**Fig. (11-a):** Immunohistochemical labeling of cross sections in the testis of a control rat the age of 90 days showing moderate cytoplasmic reaction of Sertoli cells (arrows). (Inhibin  $\alpha$ ;  $\times 1000$ )



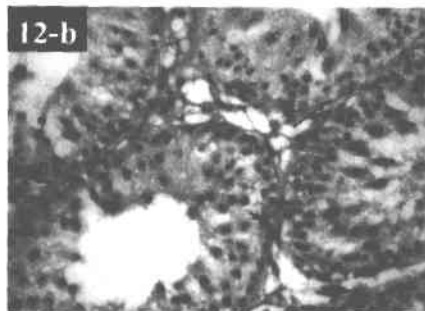
**Fig. (11-b):** Immunohistochemical labeling of cross sections in the testis of an estrogen-treated rat the age of 90 days showing moderate cytoplasmic reaction of Sertoli cells (arrows). (Inhibin  $\alpha$ ;  $\times 400$ )



**Fig. (11-c):** Immunohistochemical labeling of cross sections in the testis of a an estrogen-treated rat the age of 90 days showing moderate cytoplasmic reaction of Sertoli cells (arrows), few spermatogenic cells, large vacuoles of Sertoli cells (V) and the junction between their processes (arrow). (Inhibin  $\alpha$ ;  $\times 1000$ )



**Fig. (12-a):** Immunohistochemical labeling of cross sections in the testis of a control rat the age of 18 days showing strong nuclear reaction of Sertoli cells (short arrows) and myoid cells (long arrows). (AR immunostaining;  $\times 1000$ )



**Fig. (12-b):** Immunohistochemical labeling of cross sections in the testis of a an estrogen-treated rat the age of 90 days showing strong nuclear reaction of Sertoli cells (short arrow) and myoid cells (long arrows). (AR immunostaining;  $\times 400$ )



## DISCUSSION

Perinatal exposure of male rodents to estrogen is useful for understanding the effect of estrogen on the testes of men whose mothers received diethylstilbestrol, a potent estrogen, or who has been exposed to environmental estrogen since their early life.

Estrogen-injected rats showed a delay in the normal process of spermatogenesis at 18, 25 and 35 days of age. These differences persisted through adulthood, when the majority of estrogen-injected rats exhibited disorders of spermatogenesis whereas control rats exhibited a normal process.

In the estrogen-treated rats which were sacrificed at the age of 18 days, the seminiferous tubules showed congested vessels and there was excessive interstitium between seminiferous tubules. The congested vessels may be due to dilatation of the testicular vessels by histamine released from mast cells (**kumar et al., 2004**). The excessive interstitium occurred because estrogen stimulated the development of the stromal tissues. This explanation was supported by **Guyton and Hall (2000)** who stated that estrogens cause proliferation of the endometrial stroma, the glandular tissue of the mucosal lining of the Fallopian tube and the stromal tissue of the breast.

The presence of dominant Sertoli cells and the absence of spermatogonia might be explained by the fact that Sertoli cells were remarkably resistant to injury and were often found as the only remaining cell type in the seminiferous epithelium, when all other cells had been lost by an injurious agent. This was supported by **Creasy and Foster (1991)**.

In the estrogen-treated rats which were sacrificed at the age of 25 days, the seminiferous tubules showed mostly Sertoli cells which were apoptotic and degenerated. These degenerative changes occurred due to the injurious effect of estrogen. This was supported by **Creasy and Foster (1991)** who added that although the Sertoli cells would survive most insults, yet degenerative changes were rather easily induced.

In some specimens there were thickened basal laminae of seminiferous tubules and hypertrophied myoid cells around the rete testis which could be explained by the proliferative effect induced by estrogen. The thickening observed in the basal laminae of the degenerated seminiferous tubules of the testes might also be a secondary response by the tubules to degeneration and necrosis occurring inside them. This was supported by **Kumar et al. (2004)** who stated that arrest in the germ cells was associated with thickening of the basement membrane of the seminiferous tubules and there was a concomitant increase in the interstitial stroma.

Hemorrhage observed inside the seminiferous tubules at the age of 25 days and might be attributed to a secondary response to increased grade of severity of congestion observed in the first group.

Another histological change observed at the age of 25 days was the presence of degenerated spermatocytes. This finding beside the dominance of Sertoli cells observed in this group and in the previous group reflected the impairment of spermatogenesis as a result of either direct or indirect action of estrogen. The direct action of estrogen exposure caused a permanent impairment of spermatogenesis (Ohta and Takasugi, 1974; McLachlan et al., 1975; Ohta, 1977); and a progressive loss of germ cells leading to tubules lined by Sertoli cells only (Kind et al., 1963; Sharpe et al., 1998). The indirect action through alterations on the hypothalamic-pituitary-gonadal axis led to suppression of spermatogenesis. Long-lasting suppression of this axis might cause a persistent inhibition of spermatogenesis (Arai et al., 1983; Bellido et al., 1990; Pinilla et al., 1992). This indirect action was through a decrease in FSH secretion (Brown-Grant et al., 1975) or a decrease in testosterone secretion (Chemes et al., 1976).

Estrogen administered to neonatal rats caused dilatation of the rete testis throughout this study. It was not surprising to note that as early as day 25 of age, rete testis was dilated and some tubules nearest to it showed enlarged lumina suggesting backflow. This was supported by Russell et al., (1989) who stated that at this age tubular fluid secretion begins. Fisher et al., (1998) added that this dilatation might be a consequence of impaired fluid resorption from the efferent ducts which are established as an important site of estrogen action (West and Brenner, 1990; Hess et al., 1997). Rete testis dilation which coincided with dilated tubules and impairment of spermatogenesis was in agreement with the studies of Vitale et al. (1973) and Chemes et al. (1976).

In the estrogen-treated rats which were sacrificed on day 35, there were some normal seminiferous tubules with normal spermatocytes and some tubules with dilated wide lumina. The spermatogenic cells showed various signs of degeneration and necrosis in the form of nuclear pyknosis and chromatin margination of the nuclei (ring nuclei). This degenerative change was described by several authors in degenerating spermatids and spermatocytes in response to various injurious agents (Chapin et al., 1984; Foster et al., 1984; Dixon, 1986; Creasy and Foster, 1991).

Another histological change observed at the age of 35 days was the irregular outline of seminiferous tubules which might be explained by affection of Sertoli cells by vacuolation and degeneration. The tight junctions of the lateral processes of the Sertoli cells were destroyed leading to barrier function disruption. Also, there were interstitial cellular infiltrations

with mast cells. These cells liberate histamine and other chemical mediators which are responsible for tissue necrosis and vascular dilatation observed in the testis (**Kumar et al., 2004**).

Another finding observed at the age of 35 days was the presence of dislodged spermatogenic cells (exfoliation or sloughing of the spermatogenic cells) in the lumina of the seminiferous tubules. This change was presumably due to loss of the tenuous contact between Sertoli and germ cells as a result of impairment of Sertoli cell function. This explanation was supported by **Mitranond et al. (1979)**. **Creasy and Foster (1991)** added that retraction of lateral processes of the Sertoli cells left the germ cells in direct apposition to one another and was rapidly followed by the exfoliation of these cells into the tubular lumen and then their subsequent disappearance (germ cell depletion). The dislodged spermatogenic cells were also observed in the rete testis.

In the estrogen-treated rats which were sacrificed at the age of 90 days, the impairment of spermatogenesis was evidenced by the presence of multinucleated giant germ cells and sparse spermatogenic cells. The majority of the multinucleated giant cells mostly resulted from fusion of degenerating early spermatids and in few cases consisted of spermatocytes (**Dixon, 1986**). The formation of giant cells could be explained by the inhibition of mitosis at the stages where there were still cytoplasmic bridges between the dividing spermatids (**Cormack, 1987**).

At the age of 90 days, the estrogen-treated rats showed the presence of interstitial oedema and macrophages with brown hemosiderin granules. The oedema was mostly secondary to vasodilatation effect of histamine released from mast cells. The presence of RBCs could occur secondary to congestion which led in turn to appearance of macrophages loaded with hemosiderin granules.

There was a significant reduction in SEH and TD in the four experimental subgroups when compared with the control groups. These reductions reflected impairment of spermatogenesis which coincided with the previous histological findings.

One of the most important findings in estrogen-treated rats was that estrogen effect was evident many weeks after the last administration of estrogen. It might persist in the treated rats for several days after its last administration due to the use of olive oil as a vehicle so this could explain its action in the animal group which was sacrificed at the age of 18 days. This seems unlikely to explain the effects observed in the animal groups sacrificed at the age of 25 days and later. The effects of estrogen at these ages might therefore reflect faulty programming of reproductive development as a consequence of neonatal exposure to estrogen. This was supported by **Fisher et al. (1998)**.

It can be concluded that neonatal exposure to estrogen in rats causes impairment of spermatogenesis. This impairment has short- and long- term effects. So, it is recommended to prevent pregnant females from taking diethylstilbestrol and protect males from exposure to environmental estrogen in their early life.

### SUMMARY

This work was done on forty neonatal male albino rats divided into control group (8 rats) and four experimental subgroups (8 rats each). The experimental rats were subjected to subcutaneous injection of estrogen on days 2, 4, 6, 8, 10, and 12. The control rats received subcutaneous olive oil injection. The experimental groups were sacrificed on days 18, 25, 35 and 90.

The animals were dissected and their testes were stained with Hx. and E. stain and immunohistochemical stain for inhibin  $\alpha$  and androgen receptors. Morphometric measurements of were done.

In the first experimental subgroup which was sacrificed at the age of 18 days, the seminiferous tubules showed congested vessels and mostly Sertoli cells. There was excessive interstitium between the tubules.

In the second experimental subgroup which was sacrificed at the age of 25 days, the Sertoli cells were apoptotic and degenerated. There were degenerated spermatocytes. In addition there were thickened basal laminae of the seminiferous tubules, hypertrophied myoid cells around rete testis and hemorrhage inside the tubules. Rete testis was dilated.

In the third experimental subgroup which was sacrificed at the age of 35 days, the seminiferous tubules showed dilated wide lumina, irregular outline, dislodged spermatogenic cells and degenerated spermatogenic cells.

In the fourth experimental subgroup which was sacrificed at the age of 90 days, the seminiferous tubules showed sparse spermatogenic cells with interstitial oedema. Also, multinucleated giant cells and macrophages with brown hemosiderin granules were observed.

The four experimental subgroups showed a significant decrease in tubular diameter (TD) and seminiferous epithelial height (SEH) and increase in TD/SEH ratio. There was a significant decrease in the nuclear AR immune reaction in the Sertoli cells in experimental groups at the age of 18, 25 and 35 days and a significant decrease in the cytoplasmic reaction of Sertoli cells in inhibin  $\alpha$  immunostain in experimental groups at the age of 18, 35 and 90 days. These findings indicated a delay in maturation development of immunoexpression of the experimental groups and reflected impairment of spermatogenesis.

It is concluded that the neonatal exposure to estrogen in rats causes impairment of spermatogenesis. This impairment is a short- and long- term effect. So, it is recommended to prevent pregnant females from taking diethylstilbestrol and protect males from exposure to environmental estrogen in their early life.

## REFERENCES

1. **Aceitero, J.; Llanero, M.; Parrado, R.; Pena, E. and Lopez-Beltran ,A. (1998):** Neonatal exposure of male rats to estradiol benzoate causes rete testis dilation and backflow impairment of spermatogenesis. *The Anatomical Record*, **252**:17-33.
2. **Arai, Y.; Mori, T.; Suzuki, Y. and Bern, H.A. (1983):** Long-term effects of perinatal exposure to sex steroids and diethylstilbestrol on the reproductive system of male mammals. *Int. Rev. Cytol.*, **84**:235-268.
3. **Bancroft, J.D.; Alan, S. and Turner, D.R. (1996):** Theory and practice of histological techniques. 4<sup>th</sup> edition. Churchill Livingstone. New York, pp.129-333.
4. **Bellido, C.; Pinilla, L.; Aguilar, R.; Gaytan, F. and Aguilar, E. (1990):** Possible role of changes in post-natal gonadotropin concentration on permanent impairment of the reproductive system in neonatally estrogenized male rats. *J. Reprod. Fert.*, **90**:369-374.
5. **Brown-Grant, K.; Fink, G.; Greig, F. and Murray, M. (1975):** Altered sexual development in male rats after oestrogen administration during the neonatal period. *J. Reprod. Fert.* , **44**:25-42.
6. **Chapin, R.E.; White, R.D.; Morgan, K.T. and Bus, J.S. (1984):** Studies of lesions induced in the testes and epididymis of 344 rats. *Toxicol. Appl. Pharmacol.*, **76**:328-333.
7. **Chemes, H.E.; Podesta, E. and Rivarola, M.A. (1976):** Action of testosterone, dihydrotestosterone and 5  $\alpha$  androstane 3  $\alpha$ , 17  $\beta$  Diol on the spermatogenesis of immature rats. *Biol. Reprod.*, **14**:332-338.
8. **Cormack, D.H. (1987):** Ham's Histology, 9<sup>th</sup> edition, J.B. Lippincott Company, London, New York, pp. 651-674.
9. **Creasy, D.M. and Foster, P.M.D. (1991):** Handbook of Toxicologic Pathology. *Academic Press Inc.*, pp. 829-831.
10. **Dixon, R.L. (1986):** Toxic responses of the reproductive system. In "Casarett and Doull's Toxicology". *Macmillan, New York*, pp. 432-433.

11. Fisher, J.S.; Turner, K.J.; Eraser, H.M.; Saunders, P.; Brown, D. and Sharpe, R.M. (1998): Immunoexpression of aquaporin-1 in the efferent ducts of the rat and marmoset monkey during development, its modulation by estrogens and its possible role in fluid resorption. *Endocrinology*, **122**: 1672-1680.
12. Foster, P.M.D.; Creasy, D.M.; Foster, J.R. and Gray, T.J. (1984): Testicular toxicity produced by ethylene glycol monomethyl and monoethyl ethers in the rat. *Environ. Health Perspect.*, **57**:207-212.
13. Gaytan, F.; Pinilla, L.; Aguilar, R.; Lucena, M.C. and Paniagua, R. (1986): Effects of neonatal estrogen administration on rat testis development with particular reference to Sertoli cells. *J. Androl.*, **7**:112-121.
14. Giusti, R.M.; Iwamoto, K. and Hatch, E.E. (1995): Diethylstilbestrol revisited: a review of the long-term health effects. *Ann. Intern. Med.*, **122**: 778-788.
15. Guyton, A.C. and Hall, J.E. (2000): *Textbook of medical physiology*. 10<sup>th</sup> edition. Library of Congress, Philadelphia, Pennsylvania, pp. 934-936.
16. Hess, R.A.; Bunick, D.; Lee, K.H.; Bahr, J.; Taylor, J.A.; Korach, K.S. and Lubahn, D.B. (1997) : A role for estrogens in the male reproductive system. *Nature*, **390**:509-512.
17. Kind, F.A.; Pi, A.F. and Herrera, L.H. (1963): Effect of estradiol benzoate treatment in the newborn male rat. *Endocrinology*, **72**:966-968.
18. Kumar, K.M.; Abba, A.K. and Fausto, N. (2004): Robbins and Cotran pathological basis of disease. 7<sup>th</sup> edition. Library of congress, Philadelphia, Pennsylvania, pp.47-68, 1037-1039.
19. McLachlan, J.A.; Newbold, R.R. and Bullock, B. (1975): Reproductive tract lesions in male mice exposed prenatally to diethylstilbestrol. *Science*, **190**: 991-992.
20. Mitranond, U.; Sobhon, P.; Tosukhowong, P. and Chindnangrat, W. (1979): Cytological changes in the testis of vitamin A deficient rats. *Acta. Anat.*, **103**:159-169.
21. Mould, R.F. (1989): *Introductory Medical Statistics*. 2<sup>nd</sup> edition. Adam Hilger, Bristol and Philadelphia, pp. 17, 22 and 126.
22. Newbold, R.R.; Bullock, B.C. and McLachlan, J.A. (1985): Lesions of the rete testis in mice exposed prenatally to diethylstilbestrol. *Cane. Res.*, **45**: 5145-5150.

- 23. Ohta, Y. (1977):** Response of testis to androgen and gonadotropins in neonatally estrogenized and androgenized mice. *Endocr. J.*, **24**:287-294.
- 24. Ohta, Y. and Takasugi, N. (1974):** Ultrastructural changes in the testis of mice given neonatal injections of estrogen. *Endocr. J.*, **21**:183-190.
- 25. Pinilla, L.; Garnelo, P.; Gaytan, F. and Aguilar, E. (1992):** Hypothalamic-pituitary function in neonatally oestrogen-treated male rats. *J. Endocrinol.*, **134**: 279-287.
- 26. Putz, O.; Schwartz, C.B.; LeBlanc, G.A.; Cooper, R.L. and Prins, G.S. (2001):** Neonatal low- and high-dose exposure to estradiol benzoate in the male rat: Effects on male puberty and the reproductive tract: *Biol. Reprod.*, **65 (5)**: 1506-1517.
- 27. Russell, L.D.; Bartke, A. and Goh, J.C. (1989):** Postnatal development of the Sertoli cell barrier, tubular lumen, and cytoskeleton of Sertoli and myoid cells in the rat, and their relationship to tubular fluid secretion and flow. *Am. J. Anat.*, **184**:179-189.
- 28. Sharpe, R.M.; Atanassova, C.; McKinnell, P.; Parte, K.J.; Turner, J.S.; Fisher, J.B.; Kerr, N.P. and Groome, S. (1998):** Abnormalities in functional development of the Sertoli cells in rats treated neonatally with diethylstilbestrol: a possible role for estrogens in Sertoli cell development. *Biology of reproduction*, **59**: 1084-1094.
- 29. Tena, M.; Navarro, J.; Pinilla, L.; Gonzalez, L.C.; Huhtaniemi, I. and Aguilar, E. (2000):** Neonatal exposure to estrogen differentially alters estrogen receptor alpha and beta mRNA expression in rat testis during postnatal development: *J. Endocrinol.*, **165(2)**:345-357.
- 30. Toppari, J.; Larsen, J.C.; Christiansen, P.; Giwercman, A.; Grandjean, P.; Guillette, L.J.; Jdgou, B.; Jensen, T.K. and Jouannet, P. (1996):** Male reproductive health and environmental xenoestrogen. *Environ. Health Perspect.*, **104**:741-803.
- 31. Vitale, R.; Fawcett, D.W. and Dym, M. (1973):** The normal development of the blood-testis barrier and the effects of clomiphene and estrogen treatment. *Anat. Rec.*, **176**:333-344.
- 32. West, N.B. and Brenner, R.M. (1990):** Estrogen receptor in the ductuli efferentes, epididymis, and testis of Rhesus and Cynomolgus macaques. *Biol. Reprod.*, **42**:533-538.

## الملخص العربى

### تأثير إعطاء الأستروجين على تركيب الخصى فى

### الفئران البيضاء الحديثى الولادة

شريف محمد زكى ، طارق الغمراوى ، ميرا فاروق يوسف\*

قسم التشريح وقسم الهستولوجيا\* ، كلية الطب ، جامعة القاهرة

استخدم فى هذه الدراسة أربعون من ذكور الفأر الأبيض الحديثى الولادة قسموا إلى مجموعة ضابطة من ثمان فئران ومجموعة تجارب أعيد تقسيمها إلى أربع مجموعات صغيرة حوت كل منها على ثمان فئران ، وقد تم إعطاء كل فأر من فئران مجموعة التجارب عقار الأستروجين تحت الجلد فى اليوم الثانى والرابع والسادس والثامن والعاشر والثانى عشر ، بينما أعطى فئران المجموعة الضابطة زيت الزيتون تحت الجلد، وقد تم تشريح فئران مجموعة التجارب أيام الثامن عشر والخامس والعشرون والخامس والثلاثون والتسعون .

شرحت الفئران وتم صباغة خصى الفئران بصبغة الهيماتوكسلين والإيوسين وصبغات هبستوكيميائية مناعية: صبغة إنهيبن ألفا وصبغة مستقبلات هرمون الذكورة، وقد تمت الدراسات الشكلية القياسية .

لوحظ فى مجموعة التجارب الأولى ، والتي قد تم ذبحها فى اليوم الثامن عشر، وجود إحتقان فى الأوعية الدموية فى الحوامل المنوية ووجود خلايا سرتولى ، كما لوحظ كثرة الخلال بين الحوامل المنوية.

لوحظ فى مجموعة التجارب الثانية، والتي قد تم ذبحها فى اليوم الخامس والعشرين، وجود خلايا سرتولى ضامرة ومتلاشية ، كما كان هناك خلايا منوية ضامرة، بالإضافة لوجود تضخم فى الصفيحة القاعدية لحامل المنى وتضخم للخلايا العضلانى حول شبكة الخصية ونزيف بداخل حوامل المنى ، وإتساع شبكة الخصية.

وفى مجموعة التجارب الثالثة، والتي قد تم ذبحها فى اليوم الخامس والثلاثين، كانت الحوامل المنوية متسعة التجايف وغير منتظمة الشكل مع وجود ارتحال فى الخلايا المنوية ووجود خلايا منوية ضامرة .



وفى مجموعة التجارب الرابعة، والتي قد تم ذبحها فى اليوم التسعين، ظهر فى الحوامل المنوية خلايا منوية متناثرة مع وجود إستسقاء تخاللى بين الحوامل المنوية ، كما لوحظ وجود خلايا ضخمة عديدة النواة وبلاعم كبيرة بداخلها حبيبات الهموسيدرين . وقد لوحظ فى مجموعات التجارب الأربع وجود دلالة تناقصية فى القطر الأنبوبى والإرتفاع الطلائى لحامل المنى وزيادة فى النسبة بين القطر الأنبوبى والإرتفاع الطلائى لحامل المنى ، كما لوحظ وجود دلالة تناقصية فى مستقبلات هرمون الذكورة فى خلايا سرتولى فى مجموعات التجارب المشرحة أيام الثامن عشر والخامس والعشرون والخامس والثلاثون، ووجود دلالة تناقصية فى الحشوة التفاعلية لصبغة الإنهيبين ألفا فى خلايا سرتولى فى مجموعات التجارب المشرحة أيام الثامن عشر والخامس والثلاثون والتسعون، وقد دلت هذه النتائج على تأخر نضج النمو للتعبير المناعى فى مجموعات التجارب، وعكست هذه النتائج تلف تكون المنى.

وقد تم استنتاج أن تعرض الفئران الحديثى الولادة للإستروجين يسبب تلف تكون المنى، وهذا التلف قريب و بعيد المدى، ولهذا فقد تمت التوصية بمنع تعاطى الحوامل لهرمون الاثلى الثنائى ستلوبيستيرون ووقاية الذكور فى الفترات الأولى من حياتهم من التعرض للإستروجين الموجود فى البيئة.