

Non Hodgkin lymphoma of the cecum; case report

Mohamed Abdelaziz, Ahmed El Shabrawi, Nasser Mousa



Summary

Non-Hodgkin's lymphomas (NHLs) are heterogeneous group of malignant lymphoproliferative disorders. It is a primary malignant neoplasm of lymphoid tissue arising from the expansion of malignantly transformed lymphocytes. It is classified into two large categories; Hodgkin's lymphoma and Non-Hodgkin's lymphomas. Genetic alternations, viruses and environmental agents in addition to radiotherapy and chemotherapy are suggested as etiologic factors. Primary gastrointestinal lymphoma is very rare compared to gastrointestinal tract lymphoma arising secondary to primary nodal disease. Extra nodal lymphoma can involve any part of the gastrointestinal tract, most commonly being the stomach followed by small intestine and ileocecal region.

Keywords: *Non-Hodgkin lymphoma, diffuse large B-cell type of non-germinal center phenotype, cecum, lymphoproliferative disorders*

Medical Journal of Viral Hepatitis
(MJVH) 2019; 4 (1) - pp. 1-4

Received: 13/9/2019
Revised: 24/10/2019
Accepted: 26/10/2019
Published Online: 15/11/2019

(Mohammed Abdelaziz, Ahmed El Shabrawi, Nasser Mousa) tropical Medicine dept., Faculty of Medicine, Mansoura Univ., Egypt

* CA: Nasser mousa
mousa_medic@yahoo.com

Introduction

Two thirds of non-Hodgkin's lymphoma (NHL) and nearly all Hodgkin lymphomas present as enlarged non tender lymph node, the remaining one third of NHLs involve the extranodal sites. Extra-nodal non-Hodgkin's lymphoma (NHL) constitutes 30-40% of all cases of lymphoma¹. Gastrointestinal tract is the most frequent site of extra nodal lymphoma accounting for approximately 40% of all extra nodal lymphomas; out of these, non-Hodgkin's lymphoma comprises 4% of total cases. Primary lymphoma arising in the colon is very rare comprising only 0.2-1% of all colonic malignancy². Males are most commonly affected with peak incidence in sixth and seventh decade of life³.

Case

A fifty two-year-old female presented with intermittent vomiting, weight loss, right lower abdominal dull aching pain and bleeding per rectum. There was neither associated fever nor melena. Except for the presence of pallor, the general physical examination was normal. Abdominal examination revealed tender, hard mass in the right iliac fossa. The mass showed restricted intrinsic mobility with no movement

with respiration. Also there was no organomegaly or any other abnormal findings on both abdominal and digital rectal examination. Routine hematological and biochemical investigations were within normal limit except for the hemoglobin level, which was 8 g/dL (microcytic hypochromic anemia). Stool occult blood test was positive along with normal bone marrow aspiration. Ultrasonography of the abdomen revealed a large hypo echoic area in the right iliac fossa. Contrast enhanced computed tomography scan of the abdomen revealed gross circumferential wall thickening of cecum with average radial wall thickness of about 3 cm, and the approximate length of thickened segment was about 6 cm. Few mesenteric lymph nodes were seen in the right iliac fossa with largest one measuring 15mm×21 mm. Colonoscopy was performed that revealed ulcero-proliferative mass in caecum, fig. (1) from which multiple biopsies were taken. Histopathological examination revealed infiltration by malignant tumoral proliferation formed of diffusely arranged large cells with large nuclei, prominent nucleoli attaining perivascular location which are strong-

ly suggestive of non-Hodgkin's lymphoma, fig. (2). Immuno-histochemistry showed diffuse positivity of neoplastic cells for CD20. CD3 was positive in few scattered cells. CK was totally negative in neoplastic cells, fig. (3). CD10 was negative, BC16 was focally positive,

mum1 was diffuse positive, fig. (4). A final diagnosis of non-Hodgkin lymphoma, diffuse large B-cell type of non-germinal center phenotype was made on the basis of previously mentioned data.

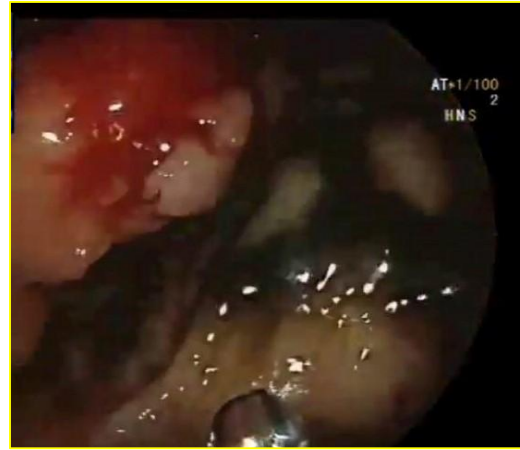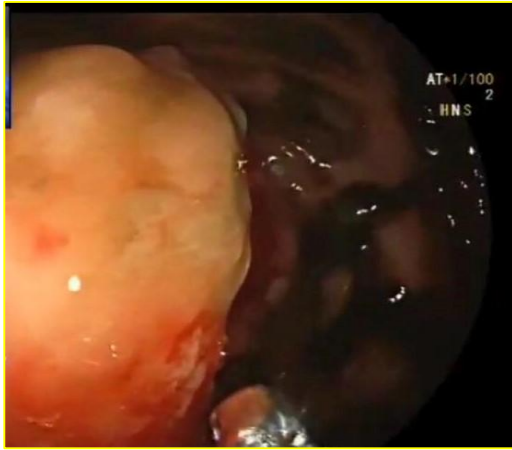


Figure (1) Ulcero-proliferative mass affecting caecum

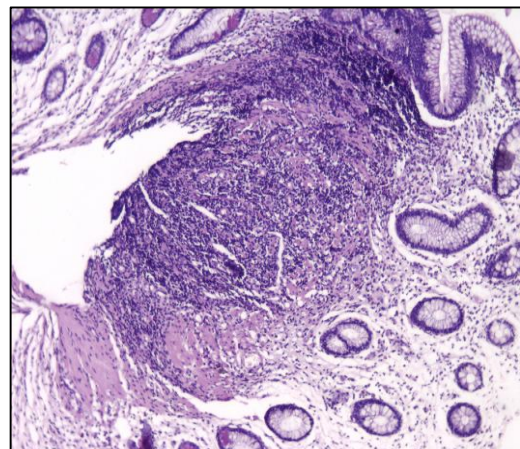
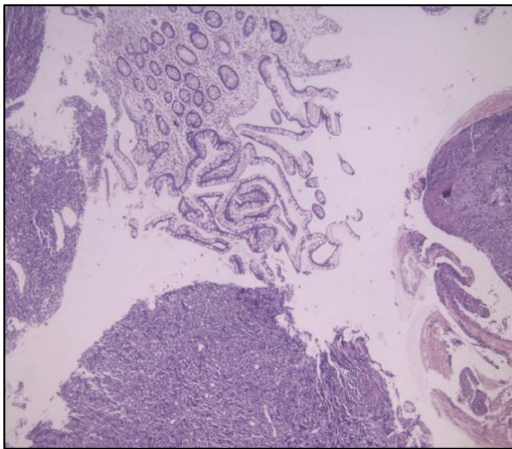


Figure (2) Submucosal lymphoid tissue stained with H&E with low and high power field

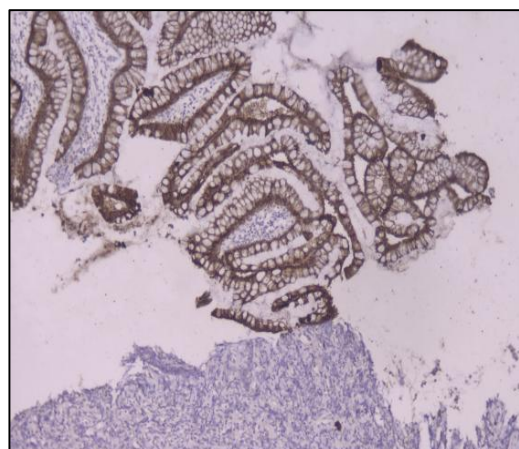
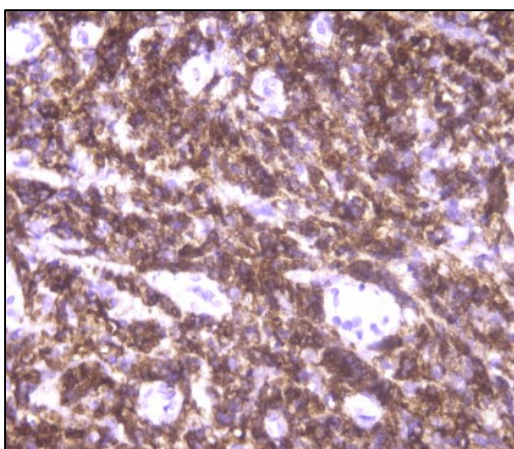


Figure (3) CK is totally negative in neoplastic cells

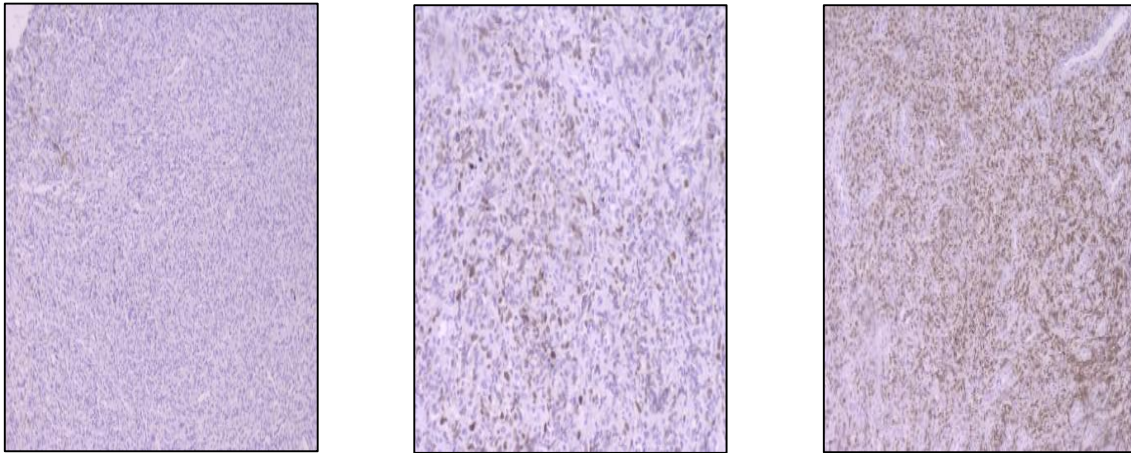


Figure (4) CD10 is negative, BCL-6 is focally positive, mum1 is diffuse positive

Discussion

Gastrointestinal lymphoma accounts for 5-10% of all non-Hodgkin's lymphoma with intestinal lymphoma contributing 15-20% of all gastrointestinal lymphoma⁴. Majority of these arise in the stomach (up to 65% of all GI lymphoma) followed by the small bowel (20-30%) with B cell lymphoma of the colon is the third commonest malignancy of the colon after carcinoma and carcinoid though its incidence is less than 0.5%³. Primary gastrointestinal malignancies are very rare in children with non-Hodgkin's lymphoma being the most common⁵. Within the colon, the involvement of caecum is the commonest, and Gonzalez et al. found caecum (60%) to be the commonest site, followed by the right (27%) and the sigmoid colon (13%)³. Diffuse large cell B lymphoma (DLBCL) is the most frequent histological subtype affecting the gastrointestinal tract and colon⁶. Primary colorectal lymphoma mainly affects older age group in the fifth to seventh decade of life with male to female ratio being (1.5 to 1)⁷. Combined modality of approach that includes surgical debulking and systemic chemotherapy is the preferred treatment. Chemotherapy includes CHOP regimen (cyclophosphamide, doxorubicin, vincristin, and prednisolone). Surgery alone can be considered as an adequate treatment for patients with low grade NHL disease that has not infiltrated beyond the submucosa⁸.

Conclusion

Primary colonic lymphoma is a rare clinical entity presenting most commonly in older age

group. DLBCL occurs as extra nodal involvement in 40% cases and is curable with modern medical treatment options. Chemotherapy represents a cornerstone in the treatment of these patients and offers an excellent chance for long term disease free survival. Taking into account the previously mentioned data, we recommend that colonic lymphoma should be considered in the differential diagnosis in patients presenting with an abdominal mass.

References

- 1- Shnitser A, Haleboua-DeMarzio D, Loren D. Primary pancreatic lymphoma presenting as acute pancreatitis. **Gastroenterol Hepatol (N Y)**. 2016; 12: 456-458.
- 2- Pandey M, Swain J, Iyer H M, Shukla M. Primary lymphoma of the colon: report of two cases and review of literature. **World J. of Surgical Oncology**. 2019; 17 (1): 18.
- 3- Gonzalez Q, Heslin M, Davila-Cervantes A, Alvarez-Tostado J, de los Monteros A, Shore G, et al. Primary colonic lymphoma. **Am Surg**. 2008; 74: 214-216
- 4- Zinzani PL, Magagnoli M, Pagliani G, Bendandi M, Gherlinzoni F, MerlaE, et al. Primary intestinal lymphoma: Clinical and therapeutic features of 32 patients. **Haematologica**. 1997; 82: 305-308.
- 5- Ladd A, Grosfeld J. Gastrointestinal tumors in children and adolescents. **Semin Pediatr Surg**. 2006; 15: 37-47.
- 6- Koch P, del Valle F, Berdel W, Willich N, Reers B, Hiddemann W, et al. Primary gastrointestinal non-Hodgkin's lymphoma:

- I. Anatomic and histologic distribution, clinical features, and survival data of 371 patients registered in the German Multi-center Study GIT NHL 01/92. **J. Clin Oncol.** 2001; 19 (18): 3861-3873.
- 7- Fan C, Changchien C, Wang J, Chen J, Hsu K, Tang R, Chiang J. Primary colorectal lymphoma. **Dis Colon Rectum.** 2000;43 (9): 1277-1282.
- 8- Tauro L, Furtado H, Aithala P, D'Souza C, George C, Vishnumoorthy S. Primary Lymphoma of the colon. **Saudi J. of Gastroenterology.** 2009; 15 (4): 279-282.