

Evaluation of Laparoscopic Combined Sleeve Gastrectomy and Mini-Gastric Bypass in Treatment of Morbid Obesity

AHMED M. AL-GHAMERY, M.Sc.; SHERIF A. SABER, M.D.; AHMED A. EL-SHOURA, M.D.;
HAMDY S. ABDALLAH, M.D. and GAMAL I. MOUSSA, M.D.

The Department of Gastrointestinal, Liver and Laparoscopic Surgery, Faculty of Medicine, Tanta University

Abstract

Background: Combined sleeve gastrectomy and MGB is a modified bariatric procedure composed of the standard procedures of sleeve gastrectomy and MGB that can be performed by laparoscopic technique. This combined procedure is still a novel technique with assumed beneficial effects based on the theory and former experiences with both techniques individually.

Aim of Study: Assessment of the efficacy of combined sleeve gastrectomy and MGB in treatment of morbidly obese patient as regard weight reduction and control of co-morbidities.

Patient and Methods: From January 2016 to January 2018, laparoscopic combined sleeve gastrectomy and MGB was performed in 20 patients at the Gastrointestinal Surgery Unit, General Surgery Department, Tanta University, Egypt.

Results: The study population included 18 females and 2 males with a mean age of 33.13 ± 7 years. The mean pre-operative Body Mass Index (BMI) was $54.13 \pm 60 \text{ kg/m}^2$. All procedures were completed laparoscopically. Comorbidities: The mean operative time was 153 ± 27.7 minutes and the mean postoperative hospital stay was 6.1 ± 5.8 days. Early complications were encountered in 4 cases (20%) including 3 port site infections (15%), staple line leakage 5 days after operation was recorded in 1 case (5%). Late complications included 6 cases (30%). Pre-operative obesity related co morbidities; hypertension in 2 cases, diabetes mellitus in 3 cases, Dyslipidaemia in 4 cases and arthralgia in 7 cases. The mean BMI 18 months after surgery was $29.23 \pm 3.4 \text{ kg/m}^2$, and the EWL% ranged between 51.45% and 98.2% with a mean of 80.68 ± 10.55 18 months after operation. Most of the co-morbidities improved or resolved; 100% for hypertension and diabetes mellitus, 75% for dyslipidemia and 71.4% for arthralgia.

Conclusion: Despite the short duration of follow-up for most of the patients, combined SG and MGB can be considered an effective surgical procedure for treatment of morbid obesity in terms of weight reduction and control of co-morbidities. A higher cost is expected for this procedure due to the larger number of cartridges used. Like other bariatric procedures, this novel procedure was attended with post-operative com-

plications mainly staple line leakage, biliary reflux, stomal ulcer, nutritional deficiencies and symptomatic gallbladder stones.

Key Words: Obesity – Sleeve gastrectomy – Mini-gastric-bypass.

Introduction

MORBID Obesity (MO) can lead to complications affecting nearly every organ system [1]. Because of their impact on the patients' quality of life, life expectancy, and healthcare finances, obesity and its related co-morbidities constitute a significant health problem worldwide [2]. A number of serious co-morbidities are associated with morbid obesity, including Type 2 Diabetes Mellitus (T2DM), dyslipidemia, hypertension, osteoarthritis, obstructive sleep apnea, and Gastroesophageal Reflux Disease (GERD). MO and its related co-morbidities are a global medical challenge and a financial burden in many affected countries [3].

Bariatric surgery is the most effective treatment of morbid obesity; not only is it a weight-reducing surgery but also a metabolic surgery. It results in excellent long-term sustained weight loss and hence in reduction of co-morbidities [3].

Combined sleeve gastrectomy and MGB is a modified bariatric procedure composed of the former standard procedures of sleeve gastrectomy and MGB that can be performed by laparoscopic technique. The potential of this combined procedure is to provide beneficial effects of both techniques to achieve better glucose control and weight loss. This combined procedure is still a novel technique with assumed beneficial effects based on the theory and former experiences with both techniques individually [4].

Correspondence to: Dr. Ahmed M. Al-Ghamery,
The Department of Gastrointestinal, Liver and Laparoscopic
Surgery, Faculty of Medicine, Tanta University

Patients and Methods

This study was conducted at the Gastrointestinal Surgery Unit, General Surgery Department, Tanta University on 20 patients suffering from morbid obesity during the period from January 2016 to January 2018. The main inclusion criteria were BMI $>40\text{kg/m}^2$ without co-morbidity or 35kg/m^2 with co-morbidity, failed previous non-surgical weight reduction trials either dietary, behavioral, physical or with drugs separately or in combination and family support and patient's willingness to comply with post-operative requirements. The exclusion criteria were mentally unstable patients, patients younger than 16 years and older than 60 years, patients suffering from endocrine disorders that can cause obesity, surgically unfit patients and those with short life expectancy as severely ill or cancer patients.

All patients were subjected to full medical history taking, clinical examination, anthropometric measurements in the form of: (Weight, height, Body Mass Index (BMI), excess BMI, waist circumference, hip circumference and waist/hip ratio), laboratory investigations and imaging investigations and evaluation of the associated co-morbidities and accurate assessment of the operative risks of the patient.

Operative technique:

Operating room setup: The patient was placed on the operating table in the supine position with both legs adducted. The laparoscopic tower was placed at the left shoulder of the patient and the anaesthetic tower at the head of the table. The surgeon and camera man stand on the patient's right side, the first and second assistant (liver retractor holder) on the patient's left side and the nurse towards the patient's feet. Table with electric motors was used to facilitate position changes. The patient was strapped well to the operating table at both the lower chest and pelvis to prevent sliding of the case.

Operative steps:

A Foley catheter was inserted to monitor the urine output and an 18-Fr Naso-Gastric (NG) tube was also inserted to decompress the stomach. Access to the abdominal cavity was achieved by using optical trocar.

Two trocars (5-12) were inserted at the right and left side of the midline about hand breadth from the xiphoid process, one (5) trocar was inserted below the right subcostal margin at anterior axillary line, one (5) trocar was inserted below the

left subcostal margin at anterior axillary line, one trocar was inserted in epigastric region for liver retraction (PretzelFlex™). The head end of the table was elevated to about 30 degree and tilted to the right side by about 10-15 degree to help the abdominal contents to fall down. The procedure starts by exploration of the abdominal cavity with particular attention to potential adhesions, length of small intestinal mesentery, checking out the position of naso-gastric tube and emptying the stomach. An opening was made in the gastro-colic ligament 4-6cm from the pylorus and devascularization of the greater curvature is performed by ultrasonic shear (Harmonic Scalpel™). A 36F bougie is inserted into the stomach trans-orally by the anaesthetist. Standard sleeve gastrectomy is performed along the bougie using the laparoscopic linear cutting stapler till reaching the angle of Hiss and the bougie is removed. A window is created in the lesser omentum close to the gastric wall at the incisura angularis. The stomach is transected at the level of incisura angularis perpendicular to the lesser curve using the laparoscopic linear cutting stapler, thus, separating the sleeved gastric pouch proximally from the pyloric antrum distally. The operating table is placed in Trendelenburg's position (the feet higher than the head by 15-30 degrees), so the transverse colon and greater omentum are retracted towards the upper abdomen exposing the ligament of Treitz. Starting from this point, 150 to 200cm (according to preoperative BMI and eating habits of the patients) of the small intestine are measured and the small intestine is mobilized in front of the colon towards the gastric pouch to create an anti-colic iso-peristaltic side-to-side loop gastro-jujunosomy using the linear stapler. A NG is inserted and the rents in the stomach and jejunum closed.

A leak test was performed using Methylene blue. A drain was inserted in the left subphrenic region. The resected part of the stomach was extracted and sent for histopathological examination.

Post-operative care:

Prophylaxis against Deep Venous Thrombosis (DVT) and pulmonary embolism was given. Respiratory exercise from the first post-operative day, associated with mucolytic, expectorant and bronchodilator if needed to prevent respiratory complications. All patients were subjected to oral gastro-graffin contrast study on the second post-operative day to exclude gastrointestinal leakage. If there was no leakage, the NG tube is removed and the patient starts clear oral fluid. Early and late complications were recorded. Patients were discharged home when they are fully ambulant, self caring,

pain free with no complications. Strict instruction was delivered to the patients before discharge.

Results

The study population included 20 patients; 18 females (80%) and 2 males (20%). Their ages ranged between 16 and 43 years with a mean of 33.13 ± 7 years. Eighteen patients (90%) were married while 2 patients (10%) were single. Regarding to surgical history, 7 patients had underwent cesarean section, appendectomy in 1 patient, laparoscopic cholecystectomy in 2 patients, and 10 patients (50%) had negative surgical history.

The pre-operative anthropometric measurements in our study included the weight which ranged between 120 and 174kg with a mean of 145.80 ± 16.38 kg. The BMI ranged between 43 and 64.4 kg/m^2 with a mean of 54.13 ± 6.05 kg/m^2 . The excess body weight ranged between 59 and 106kg with a mean 82.50 ± 15.82 . The waist/hip ratio ranged between 0.7 and 1.02 with a mean of 0.84 ± 0.08 . According to the BMI, the 20 patients were classified into 3 groups. Six patients (30%) were morbidly obese, 10 patients (50%) were super obese and 4 patients (20%) were super-super obese.

Pre-operative upper GI endoscopy was done for all patients and it revealed that 4 patients (20%) had un-complicated hiatus hernia, 8 patients (40%) had gastritis (antral or pangastritis) and received medical treatment before surgery, 2 patients (10%) had incompetent cardia and the rest of the patients had normal upper endoscopy. Pelvi-abdominal ultrasound was obtained for all patients and it revealed hepatomegaly in 9 patients (45%), splenomegaly in 3 patients (15%), fatty liver in 4 patients (20%) and 4 patients (20%) had normal study.

Obesity associated morbidities in patients included in this study: 2 patients (10%) were hypertensive and receiving antihypertensive medications, 3 patients (15%) had type 2 DM and maintained on insulin therapy, 4 patients (20%) were receiving statins for dyslipidaemia, 2 patients were asthmatic, and 7 patients (35%) were suffering from arthritis.

Operative records:

All the procedures were completed laparoscopically. The operative time ranged between 120 and 200 minutes with a mean of 153 ± 27.77 minutes. The number of cartridges used in this study ranged between 7 and 9 and the mean number was 8 cartridges.

Intra-operative complications:

Intra-operative complications were recorded in 4 patients (20%). Superficial liver tear caused by the liver retractor was encountered in 1 patient (5%) and the resulting bleeding was controlled by cautery and compression. Minimal bleeding from splenic capsule occurred in 1 patient and bleeding was controlled by compression as well. Misfiring of stapler during vertical division of the stomach to create the gastric sleeve resulting in division with no stapling and bleeding from the edges of the stomach occurred in 1 patient (5%). This adverse event was fixed by re-application of the linear stapler medial to the open edges of the gastrotomy and firing it. In the same patient, the intra-operative leak test (Methylene blue test) revealed leakage at the site of closed gastro-enterotomy and it was controlled by placing a 2nd layer of sutures. There was no operative mortality. Fig. (1).

Post-operative results:

The post-operative hospital stay ranged between 4 and 40 days with a mean of 6.60 ± 8.05 . If we exclude the one patient who developed leakage and stayed in the hospital for 40 days, the post-operative hospital stay of the remaining 19 patients will range between 4 and 10 days with a mean of 4.84 ± 1.80 . All patients in this study were subjected to oral gastrograffin contrast study the second post-operative day and no leakage was detected in any of them.

Early post-operative complications:

Early complications were encountered in 4 patients (20%). One female patient (5%) developed late staple line leakage the 7th post-operative day revealed as drainage of the oral soft meal together with staples through the abdominal drain. In this patient, leakage was confirmed by both gastrograffin study Fig. (2) and upper endoscopy and was found to be due to a tiny perforation at the most proximal end of the vertical staple-line (the site of the angle of Hiss) with controlled drainage through the abdominal drain. This patient did not develop sepsis and abdominal ultrasound examination and Computed Tomography (CT) revealed no intra-abdominal collection. This patient was treated conservatively by maintained abdominal drainage, nothing per mouth and Total Parenteral Nutrition (TPN) and the fistula closed after 1 month. It is important to note that the Gastrograffin study performed the 2nd post-operative day was normal with no leakage of the contrast. Three patients (15%) suffered from port site infection. There was no post-operative mortality in this study.

All patients were followed-up according to the planned schedule (1, 3, 6, and 12 months) and none of them escaped the follow-up (attendance was 100%). Seven patients (35%) completed the 9-months follow-up while 3 patients (15%) had completed the 12-months follow-up.

In this study, the pre-operative weight ranged between 120kg and 174kg with a mean of 145.8 ± 16.38 kg. At 1 month follow-up, the weight ranged between 100kg and 163kg with a mean of 135.4 ± 17.28 kg. At 3 months follow-up, the weight ranged between 92kg and 150kg with a mean of 123.10 ± 15.61 kg. At 6 months follow-up, it ranged between 80kg and 120kg with a mean 109.2 ± 13.13 . At 9 months follow-up, the weight ranged between 77kg and 120kg with a mean 101.45 ± 10.76 , at 1 year follow-up, the weight ranged between 72kg and 106kg with a mean 90.25 ± 9.00 . Lastly at 18 months follow-up, it ranged between 64kg and 94kg with a mean 79.65 ± 7.77 kg.

In this study, the pre-operative BMI ranged between 43kg/m^2 and 64kg/m^2 was with a mean of $54.13 \pm 6.51 \text{kg/m}^2$. At one month follow-up, BMI ranged between 38.1kg/m^2 and 56.55kg/m^2 with a mean of $49.91 \pm 6.99 \text{kg/m}^2$. At 3 months follow-up, the BMI ranged between 32.59kg/m^2 and 55.11kg/m^2 with a mean of $45.39 \pm 6.31 \text{kg/m}^2$. At 6 months follow-up, the BMI ranged between 29kg/m^2 and 48.88kg/m^2 with a mean of 40.88 ± 5.31 . At 9 months follow-up, it ranged between 28.2kg/m^2 and 46.66kg/m^2 with a mean of $37.46 \pm 4.77 \text{kg/m}^2$. At one year follow-up, it ranged between 25.6kg/m^2 and 42.22kg/m^2 . Lastly at 18 months follow-up, the BMI ranged between 20.2kg/m^2 and 34.66kg/m^2 with a mean of $29.15 \pm 3.7 \text{kg/m}^2$.

In this study, the pre-operative excess body weight ranged between 59kg and 106kg with a mean of 82.5 ± 15.82 kg. At 1 month follow-up, the EWL% ranged between 7.51% and 32.25% with a mean of 13.54 ± 5.76 . At 3 months follow-up, the EWL% ranged between 16.85% and 45.16% with a mean of 27.78 ± 7.02 %. At 6 months follow-up, it ranged between 27.18% and 69.11% with a mean of 52.63 ± 14.14 . At 9 months follow-up, the EWL% ranged between 34.95% and 80.88% with a mean of 54.95 ± 9.65 %. 12 months follow-up, the EWL% ranged between 38.8% and 92.6% with a mean of 68.96 ± 11.69 . Lastly at 18 months follow-up, the EWL% ranged between 51.45% and 98.2% with a mean of 80.68 ± 10.55 .

Effects of weight reduction on obesity related morbidities:

Most of the co-morbidities improved or resolved after surgery. The 2 patients with hypertension had

complete resolution (100%) of hypertension; one patient stopped anti-hypertensive drugs 7 months post-operatively and the other patient stopped anti-hypertensive drugs at 9 months post-operatively. Two out of the 3 patients (66.6%) with diabetes mellitus had complete resolution of diabetes and both of them stopped insulin therapy at 9th and 11th months post-operative with fair glycaemic control without medications while the remaining 1 patient (33.3%) showed improvement of glycaemic control and reduced the dose of insulin therapy. Three out of the 4 patients with dyslipidaemia (75%) showed improvement of their lipid profile and reduced the dose of Statins. Five out of 7 (71.4%) patients with arthritis showed marked improvement manifested by reduction in pain severity, improvement of their locomotor abilities and decrease joint swelling. Finally, the 2 patients with bronchial asthma showed no significant changes in their morbidities. (Table 2).

Late complications:

Late complications were reported in 6 patients (30%) in this study. Biliary reflux and stomal ulcers, proved by endoscopic examination, were encountered in three patients (15%). These patients received medical treatment in the form of proton pump inhibitor and Rebamipide with symptomatic improvement and healing of the ulcers on upper endoscopy. One patient (5%) developed clinically-significant hypocalcaemia manifested by tingling of her hands and responded well to oral calcium and Vitamin D therapy. Another patient developed iron deficiency anemia and responded well to iron therapy. One more patient (5%) suffered from symptomatic gallbladder stones and underwent laparoscopic cholecystectomy 4 months post-operatively. One patient (5%) developed renal stones.

Table (1): Anthropometric measurements.

Parameter	Minimum	Maximum	Mean \pm SD
Weight	120	174	145.80 ± 16.38
Height	150	170	164.65 ± 4.86
BMI	43	64.4	54.13 ± 6.51
EB W	59	106	82.50 ± 15.82
WC/HC	0.7	1.02	0.84 ± 0.08

Table (2): Effects of weight reduction on obesity related co-morbidities.

	No	Improved	Resolved	Unchanged
DM	3 (15%)	1	2	0
HTN	2 (10%)	0	2	0
Asthma	2 (10%)	0	0	2
Arthritis	7 (35%)	4	1	2
Dyslipidaemia	4 (20%)	3	0	1

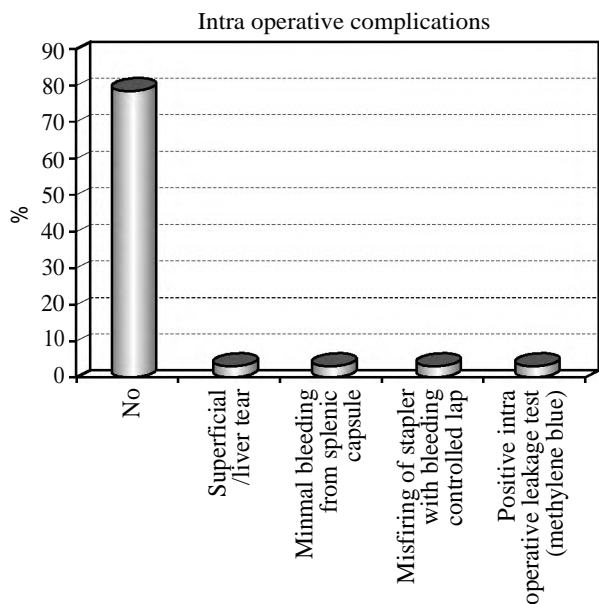


Fig. (1): Intra-operative complication.

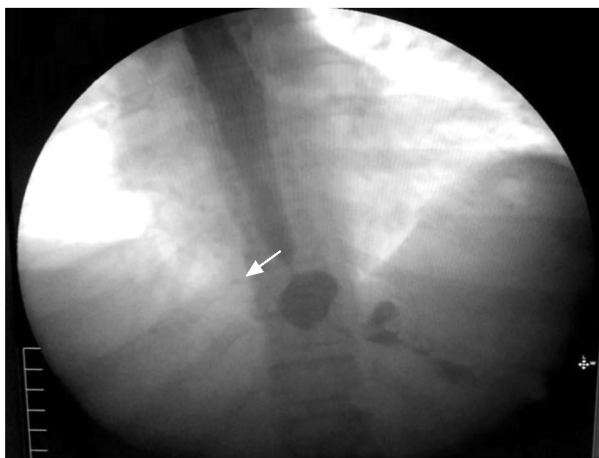

Fig. (2): Gastrograffin study revealed leakage of contrast material at GEJ.

Discussion

The aim of this study was to assess efficacy of combined SG and MGB in treatment of morbidly obese patients as regard weight reduction and reduction of co-morbidities. This study included 20 morbidly obese patients who accepted to participate in the study and signed an informed consent.

Females constituted the majority of our patients 18/20 (80%). This gender incidence was matched with that reported by El-Mahdi, 2017 (78.7%) [5]. The higher incidence of morbid obesity among females can be explained as female patients are more prone to psychosocial problems and stress conditions. Also, women may be more concerned about the cosmetic sequel of obesity, worried about marriage in married patients, delayed marriage in

non married patients, and infertility in some patients (Abo Ryia MH, 2005) [6].

The age in our study ranged between 16 and 43 years with mean of 33.13 ± 7 years. This recorded age is quite similar to most studies including that of Noun et al., 2012 where the mean age was 33.2 ± 10.2 [7].

The mean operative time was 153 ± 27 minutes ranging between 120 and 200 minutes. This outcome is quite similar to El-Shora [8], who has a mean operative time of 163.5 ± 25 minutes and it ranged from 130 to 210 minutes in his series of laparoscopic LSG. Lee et al., [9] reported his mean operative time in LMGB that was 148 ± 19 minutes. The reported operative time in our study was longer than that of other authors including Plamper et al., 2016 and Miguel A et al., [10] whose reported operative times were 81.7,86 and 52 ± 18.5 minutes respectively in laparoscopic MGB. The operative time in this study is expected to be longer than that of either LSG or MGB since the technique adopted in our study includes the techniques of both LSG and MGB.

The number of cartridges used in this study ranged between 7 and 9 with a mean of 8 cartridges. This number is much more than that recorded in most studies of LSG; Dapri G et al., [11] used 5.7 ± 0.7 cartridges. The number of cartridges in our study also was more than that used in most of studies which adopted the technique of LMGB as Disse et al., [12] who used 6 to 7 cartridges with a mean of 6.5 cartridges. The larger number of cartridges used in this study is expected as our technique includes the techniques of both LSG and MGB, implying that the cost of surgery in our study is higher than the cost of either LSG or MGB as a separate operation.

The mean hospital stay in this study was 6.60 ± 8.055 days. It ranged between 4 and 40 days, (NB. one patient had leakage from GEJ with hospital stay of 40 days). This matched with Mognol P et al., [13] who performed LSG and the mean hospital stay in his study was 7.2 days. Wang W et al., [14] in his study of LMGB had a mean hospital stay of 6 days. After exclusion of the patient who developed leakage, the mean hospital stay in our study (4.8 days) was found to be quite similar to that of many authors including Shi X et al., 2010 who performed LSG with a mean hospital stay was 4.2 days, and Kular et al., [15] who reported that the mean post-operative stay was 3 ± 1.3 days after LMGB. The mortality rate in our study was zero. This matched with the result that reported by of

Bruzzi M et al., 2015, Disse et al., 2014, and Noun R et al., 2012 who performed LMGB and the mortality rate was zero [12].

Intra-operative complications in this study were reported in 4 patients (20%). These complications included a superficial liver tear in 1 patient (5%), a minimal bleeding from splenic capsule in 1 patient (5%), misfiring of stapler during vertical division of the stomach in 1 patient (5%) and a +ve intra-operative leak test in 1 patient (5%). All these complications were controlled laparoscopically without the need for conversion to open surgery. Miguel A et al., [10] performed LMGB and the rate of intraoperative complication in his study was 2% in form of intra-abdominal bleeding that was not adequately controlled laparoscopically in two patients, perforation at GEJ by the Bougie in one patient and one incorrect gastric transection in a patient with severe cardio-esophageal inflammation; all of these patients were converted to open surgery. Neagoe RM et al., [16] reported that the rate of intraoperative complication after LSG was 3.9%. These complications included a port-related liver injury in one patient and three other patients with minor splenic lacerations, which were all successfully controlled laparoscopically.

In this study, early postoperative complications were reported in 4 patients (20%) including stable line leakage at gastro-esophageal junction was recorded in 1 patient (5%) and 3 patients suffered from port site infection (15%). Neagoe RM et al., [16] in his study of LSG reported that early complications were encountered in 6.7% of the patients and these complications were; post-operative intra-abdominal bleeding from the staple line in three patients all of them required laparoscopic re-intervention for hemostasis, two patients with superficial port-related abdominal hematoma, one patient with unexplained post-operative fever, and one patient with pneumonia. Miguel A et al., [10] reported that the early complications after LMGB developed in 16 patients (1.3%) and these complications included intra-abdominal bleeding in 9 patients, leakage in 3 patients, early small bowel obstruction in 2 patients, necrosis of the excluded anterior gastric wall in one patient and acute dilation of the excluded stomach in one patient. Yehoshua RT et al., [17] showed that high intra luminal pressure and low compliance of the sleeved stomach may be the main cause of leakage at GEJ especially in those patients who develop distal stenosis at the incisura angularis leading to poor blood flow and poor oxygenation with subsequent impaired suture line healing. One of the theoretical advantages of our new technique over standard SG is that the

loop gastrojejunostomy is postulated to decompress the sleeved stomach and decrease the intra luminal pressure with subsequent improvement of the tissue perfusion at the angle of Hiss leading to reduction in the risk of leakage. Based on the results of the current study this theoretic advantage, however, is questioned as one patient in our study developed leakage at GEJ.

Late post-operative complications were reported in 6 patients (30%) in this study. Biliary reflux and stomal ulcers were recorded in 3 patients (15%), 1 patient (5%) developed clinically-significant hypocalcaemia, 1 patient (5%) developed iron deficiency anemia, 1 patient (5%) suffered from symptomatic gallbladder stones and 1 patient (5%) developed renal stones. Jammu and Sharma [18] reported similar complications in 19.7% of their patients, and these complications included GERD in 9.4% of patients who underwent LSG versus 0.6% of patient who underwent LMGB, anemia developed in 4.9% after LMGB versus 3.5% after LSG, gall stones formations in 8.3% of LMGB group versus 4.1% after LSG group. Dumping, biliary reflux and stomal ulcer developed only in the group who underwent LMGB. Peterli R et al., [19] reported late post-operative complication which needed additional surgical intervention in 9 patients (8%) in the LSG group. These complications were in the form of: 2 patients converted to bypass due to severe GERD, 5 patients needed cholecystectomy due to newly developed symptomatic gallstones, and 2 patients suffered from insufficient weight loss, 1 patient converted to LBPD-DS and 1 patient converted to LRYGB). Bruzzi M et al., [20] reported that the late complications after LMGB were recorded in 10 patients (7.9%) and 5 of them underwent another surgery; 2 patients with intractable biliary reflux underwent successful conversion into RYGB, 2 patients developed late marginal ulcer perforations that occurred at 3 and 4 years postoperatively and were successfully managed by emergency laparotomy and 1 patient suffered from bowel obstruction 3 years post-operatively.

During the follow-up period, the achieved weight reduction produced beneficial effects on the co-morbidities that showed either resolution or improvement. In this study, 2 patients (10%) were hypertensive on anti-hypertensive medications before surgery. These 2 patients had become normotensive and stopped the antihypertensive medication after weight reduction at the 7th and 9th post-operative months, so the resolution of hypertension was 100%. This outcome matches with the results reported by D'Hondt M et al., 2011 and Boza C et

al., 2012, who reported that the resolution/ improvement of hypertension was 90.9% and 98.2% respectively after LSG, [21] while Jammu GS and Sharma [18] reported that the resolution of hypertension in LMGB group was 85.4 % of previously hypertensive patients.

In this study 3 patients (15%) were diabetic on subcutaneous insulin therapy and improvement (reduction in medication) after surgery occurred in 2 of them (66.6%). This outcome is similar to that reported by Taha O et al., 2017 who performed LMGB and the improvement of DM was reported in 85% of the diabetic patients included in his study. Our study showed a better glycemic control and a higher rate of diabetes remission than other authors who performed LSG like Jammu GS and Sharma R, 2016 and Magee C et al., 2011 who reported that the improvement of diabetes was found in 56.5% and 23% of the diabetic patients included in their studies respectively [22]. Similarly, resolution/improvement of dyslipidemia denoted as improvement of serum lipids profile and reduction of medication in this study was reported in 75% of patients with dyslipidemia included in this study, an outcome that is similar to that reported by Kular et al., [15] who had a 72% resolution/ improvement of dyslipidaemia after LSG and 90% after LMGB.

In this study the mean pre-operative excess body weight was 82.5 ± 15.82 kg, ranging between 59kg and 106kg. At 6 months follow-up, EWL% ranged between 27.18% and 69.11% with a mean of 52.63 ± 14.14 . At 12 months follow-up, the EWL% ranged between 38.81% and 92.6% with a mean of 68.58 ± 11.69 . Our results are quite similar to other authors who performed LMGB. Musella M et al., Kular et al. [23], and Piazza L et al., [24] reported the mean EWL% at 12 months post-operative and it was 70.12 ± 8.35 , 63% and 65% respectively, while Wang et al., [25] reported that EWL% at 6 months was 55.6% and at 12 months 69.3%.

There are some limitations in the current study. The main limitations include the small number of patients (20 patients), the absence of a control group and the short duration of follow-up for most of the patients. Therefore, the results of this study are considered preliminary results that are not sufficient to properly evaluate this new technique. So, we recommend conducting more studies including larger numbers of patients and longer follow-up periods in a randomized controlled design to allow proper assessment of the outcomes of this new technique.

Conclusion:

Despite the short duration of follow-up for most of the patients, combined SG and MGB can be considered an effective surgical procedure for treatment of morbid obesity in terms of weight reduction and control of co-morbidities. A higher cost is expected for this procedure due to the larger number of cartridges used. Like other bariatric procedures, this novel procedure was attended with postoperative complications mainly staple line leakage, biliary reflux, stomal ulcer, nutritional deficiencies and symptomatic gallbladder stones. A randomized controlled clinical trial on a larger numbers of patients with a longer follow-up period is strongly recommended to better assess the outcomes of this new technique.

References

- 1- CARBAJO M.A., LUQUE-DE-LEÓN E., JIMÉNEZ J.M., et al.: Laparoscopic one-anastomosis gastric bypass: Technique, results, and long-term follow-up in 1200 patients. *Obes. Surg.*, 27 (5): 1153-67, 2017.
- 2- GUSTAVO A., HIMPENS J., DHAENENS J., et al.: Long-term (11 years) outcomes in weight, patient satisfaction, comorbidities, and gastroesophageal reflux treatment after laparoscopic sleeve gastrectomy, 12: 1778-86, 2017.
- 3- LI J., LAI D. and WU D.: Laparoscopic roux-en-y gastric bypass versus laparoscopic sleeve gastrectomy to treat morbid obesity-related comorbidities. A systematic review and meta-analysis, 26: 429-42, 2016.
- 4- PETERKO A.C., MAZUL-SUNKO B., MIROSEVIC´ G., et al.: Combined sleeve gastrectomy and mini-gastric bypass in a new bariatric procedure of mini-gastric bypass and proximal sleeve gastrectomy. *Acta Clin. Croat.*, 52 (3): 316-20, 2013.
- 5- EL-MAHDI T.: Laparoscopic sleeve gastrectomy versus laparoscopic minigastric bypass for the treatment of morbid obese Patient. M.D Thesis. In general surgery, Faculty of Medicine, Tanta University, 2017.
- 6- ABO RYIA M.H.: Surgical Treatment of Morbid Obesity. Md Thesis In General Surgery, Faculty of Medicine, Tanta University, 2005.
- 7- NOUN R., SKAFF J., RIACHI E., et al.: One thousand consecutive mini-gastric bypass: Short-and long-term outcome. *Obes. Surg.*, 22: 697-703, 2012.
- 8- EL-SHORA A.A.: Evaluation of Sleeve Gastrectomy in Treatment of Morbid Obesity. M.D. thesis, Discussion, p.: 129, 2013.
- 9- LEE S. and GALLAGHER D.: Assessment methods in human body composition. *Curr. Opin. Clin. Nutr. Metab. Care*, 11 (5): 566-72, 2008.
- 10- MIGUEL A., CARBAJO, ENRIQUE L., et al.: Laparoscopic one-anastomosis gastric bypass: technique, results, and long-term follow-up in 1200 Patients, 27: 1153-67, 2017.

- 11- DAPRI G., CADIÈRE G., HIMPENS J., et al.: Reinforcing the Staple Line During Laparoscopic Sleeve Gastrectomy. Prospective randomized clinical study comparing three different techniques. *Obes. Surg.*, 20 (4): 462-7, 2010.
- 12- DISSE A., PASQUER P., ESPALIEU G., et al.: Greater Weight Loss with the Omega Loop Bypass Compared to the Roux-en-Y Gastric Bypass: A Comparative Study, 24, (6): 841-6, 2014.
- 13- MOGNOL P., CHOSIDOW D. and MARMUSE J.P.: Laparoscopic sleeve gastrectomy as an initial bariatric operation for high-risk patients: Initial results in 10 Patients pp. 1030-3, 2005.
- 14- WANG W., WEI P.L., LEE Y.C., et al.: Short-term results of laparoscopic mini-gastric bypass, pp. 648-54, 2005.
- 15- KULAR K.S., MANCHANDA N. and RUTLEDGE R.: Analysis of the five-year outcomes of sleeve gastrectomy and mini-gastric bypass: A report from Indian subcontinent. *Obes. Surg.*, 24: 1724-8, 2014.
- 16- NEAGOE R.M., MURESA M., BANCU S., et al.: Results of laparoscopic sleeve gastrectomy 5-year follow-up study in an eastern european emerging bariatric center, 983-9, 2017.
- 17- YEHOSHUA R.T., EIDELMAN L.A., STEIN M., et al.: Laparoscopic sleeve gastrectomy-volume and pressure assessment. *Obes. Surg.*, 18 (9): 1083-8, 2008.
- 18- JAMMU G.S. and SHARMA R.: A 7-year clinical audit of 1107 cases comparing sleeve gastrectomy, Roux-En-Y gastric bypass, and mini-gastric bypass, to determine an effective and safe bariatric and metabolic procedure. *Obese. Surg.*, 26: 926-32, 2016.
- 19- PETERLI R., WÖLNERHANSEN B. and VETTER D.: Laparoscopic sleeve gastrectomy versus roux-y-gastric bypass for morbid obesity-3-year outcomes of the prospective randomized swiss multicenter bypass or sleeve study, 466-73, 2017.
- 20- BRUZZI M., RAU C., VORON T., et al.: Single anastomosis or mini-gastric bypass. Long term results and quality of life after a 5-year follow-up. *Surg. Obes. Relat. Dis.*, 11: 321-6, 2015.
- 21- BOZA C., SALINAS J., SALGADO N., et al.: Laparoscopic sleeve gastrectomy as a stand-alone procedure for morbid obesity. Report of 1,000 cases and 3-year follow-up. *Obes. Surg.*, 22: 866-71, 2012.
- 22- MAGEE C., BARRY J., ARUMUGASAMY M., et al.: Laparoscopic sleeve gastrectomy for high-risk patients. weight loss and comorbidity improvement-short-term results. *Obes. Surg.*, 21: 547-50, 2011.
- 23- MUSELLA M., SUSAN A., GRECO F., et al.: The laparoscopic mini-gastric bypass: The Italian experience. Outcomes from 974 consecutive cases in a multicenter review. *Surg. Endosc.*, 28: 156-63, 2014.
- 24- PIAZZA L., FERRARA F., LEANZA S., et al.: Laparoscopic mini-gastric bypass: Short-term single-institute experience. *Updates Surg.*, 63 (4): 239-42, 2011.
- 25- WANG W., WEI P.L., LEE Y.C., et al.: Short-term results of laparoscopic mini-gastric bypass, pp. 648-54, 2005.

تقييم الجمع بين عمليتي الاستئصال الكمي للمعدة وتحويل المسار المصغر للمعدة باستخدام منظار البطن الجراحي في علاج السمنة المفرطة

مقدمة البحث: لقد أجريت هذه الدراسة في وحدة الجهاز الهضمي والمناظير بقسم الجراحة العامة-مستشفى طنطا الجامعي في الفترة بين شهر يناير عام ٢٠١٦ حتى شهر يناير عام ٢٠١٨.

شملت الدراسة عشرين مريضا يعانون من السمنة المفرطة يتم تسجيل دخولهم بقسم الجراحة خلال فترة البحث وخضعوا لعملية تكميم المعدة مع تحويل المسار المصغر للمعدة باستخدام المنظار الجراحي.

شملت الدراسة المرضى الذين توافرت فيهم الشروط الآتية:

- ١- أن يكون مؤشر كتلة الجسم يساوي أو أكبر من ٤٠ كجم/م^٢.
- ٢- أن يكون مؤشر كتلة الجسم أكبر من ٣٥ كجم/م^٢ مصاحبا لمضاعفات السمنة المفرطة المتوقع تحسنها مع النزول في الوزن.
- ٣- الفئة العمرية بين سن ١٦ و ٦٠ عاما.
- ٤- المرضى الذين فشلوا في إنقاص الوزن بالطرق التقليدية.

إستبعاد:

- ١- الذين لم تتحمل حالاتهم الطبية بناء على فحص ما قبل العملية الخضوع للجراحة.
- ٢- الذين يعانون من حالات نفسية.
- ٣- الذين يعانون من السمنة الثانوية نتيجة لإضطراب هرموني أو غيره.
- ٤- الذين يعانون من أمراض كبدية في مراحلها الأخيرة والذين يعانون من أورام سرطانية منتشرة.
- ٥- الذين يعانون من تضخم بالطحال.

هدف الدراسة: تقييم الجمع بين عمليتي تكميم المعدة وتحويل المسار المصغر باستخدام منظار البطن الجراحي في علاج السمنة المفرطة والمشاكل المرضية المصاحبة للسمنة.

المرضى وطرق البحث: شملت الدراسة عشرين مريضا تراوحت أعمارهم من ١٦ إلى ٤٣ سنة مع متوسط عمري (٧±٣٣.١٣) وإشتملت الدراسة على ١٨ سيدة ورجلان.

وكان متوسط الوزن بين المرضى الذين شملتهم الدراسة ١٦٠.٣٨ ± ١٤٥.٨٠ كجم وتراوحت الأوزان من ١٢٠ كجم إلى ١٧٤ كجم، كان متوسط مؤشر كتلة الجسم ٤٠.١٣ ± ٦٠.٥١ كجم/م^٢ وتراوح من ٤٣ إلى ٦٤.٤ كجم/م^٢ ومتوسط الوزن الزائد ٨٢.٥٠ ± ١٥.٨٢ كجم تراوح من ٥٩ إلى ١٠٦ كجم.

وجد في المرضى الذين شملهم البحث عدد كبير من المضاعفات المصاحبة للسمنة المفرطة مثل:

إلتهاب المفاصل وصعوبة بالحركة (٣٥٪) وإرتفاع نسبة الدهون بالدم (٢٠٪) وحساسية الصدر (١٠٪) وإرتفاع ضغط الدم (١٠٪) ومرض السكري من النوع الثاني (١٥٪).

وقد تم عمل منظار تشخيصي على المرئ والمعدة والإثنى عشر لتشخيص حالات إلتهاب المعدة والإثنى عشر وعلاجها قبل الجراحة وتشخيص حالات الإرتجاع الحامضي بالمرئ وحالات الفتق بالحجاب الحاجز.

تم إجراء جميع الحالات بالمنظار الجراحي ولم يتم الجوء للفتح الجراحي في أى منها، كان من أهم المضاعفات التي حدثت أثناء العملية حدوث نزيف من المعدة نتيجة حدوث خطأ في الدباسة تم إصلاحه باستخدام المنظار الجراحي. أما أهم المضاعفات التي حدثت مبكرا بعد العملية حدوث تسريب عند إلتقاء المرئ بالمعدة تم علاجه تحفظيا.

قد أظهرت هذه الدراسة تغيرا ملحوظا في معدل فقدان الوزن للمرضى عن طريق قياس وزن الجسم (كجم) ومؤشر كتلة الجسم (كجم/م^٢) ومتوسط النسبة المئوية للنقص بالوزن الزائد على مدار فترات المتابعة.

ولقد حدث تحسن ملحوظ وشفاء في المضاعفات المصاحبة للسمنة المفرطة لدى المرضى الذين شملتهم الدراسة بعد فقدانهم للوزن الزائد، خصوصا فيما يتعلق بإرتفاع ضغط الدم ومرض السكري من النوع الثاني.

تؤيد هذه الدراسة النتائج المسجلة في العديد من الدراسات الأخرى في أن الجراحة هي الطريقة الفعالة الوحيدة لإنقاص الوزن في حالات السمنة المفرطة، والحفاظ على جزء كبير من الوزن المفقود بعد الجراحة لفترات معقولة.

ولكى تكون الدراسة أكثر فاعلية وفائدة ننصح بإجراء دراسات أخرى على عدد أكبر ممن الحالات وفترات متابعة أطول.