

Endoscopic Resection of Breast Fibroadenoma

MOHAMED A. SHENASHEN, M.Sc.; WALEED Y. EL-SHERPINY, M.D.; MOHAMED A. MLEES, M.D.; AHMED A. DARWISH, M.D. and MAGDY M. EL-GENDY, M.D.

The Department of General Surgery, Faculty of Medicine, Tanta University, Egypt

Abstract

Background: Surgical excision was the definitive procedure performed for symptomatic benign breast tumors to alleviate anxiety regarding potential for growth or malignancy as well as physical discomfort. However, the efficacy and safety of endoscopic removal of benign breast disease is still a matter of debate.

Aim of the Study: The aim of this study is to evaluate feasibility, safety and cosmetic results of endoscopic excision of fibroadenoma of the breast.

Patients and Methods: A total of 10 patients underwent endoscopic fibroadenoma excision between June 2016 and August 2017 at General Surgery Department in Tanta University Hospital. Patients with recurrent fibroadenoma, multiple swelling or suspicious breast masses were excluded. Cosmetic results, cancer incidence (histopathological surprise), complication rates, and post-operative pain were evaluated.

Results: Detailed location of fibroadenoma were in the upper outer quadrant of the breast (n=4, 40%), central supra-areolar lesion (n=3, 30%), and the same presentation for upper inner, lower outer and lower inner lesions (n=1, 10%). Conversion to open technique occurred in two patients (20%). Cosmetic results were excellent in 7 patients (87.5%) and good in one patient (12.5%). Post-operative pain was mild in seven patients (70%) and moderate in three patients (30%). We observed no intra operative bleeding or nerve injury. Subcutaneous emphysema occurred in 3 patients (30%). There was no post-operative seroma, hematoma, wound infection, skin burn nor breast deformity in all cases.

Conclusion: Endoscopic resection of breast fibroadenoma is safe and technically simple and is associated with an excellent cosmetic results and a low incidence of complications. Furthermore, it seems to be the optimal procedure, when surgery for benign breast disease is indicated, as endoscopic breast surgery has the advantages of elimination of scars from breast and avoid excess injury of breast tissue.

Key Words: Endoscopic resection – Fibroadenoma – Breast.

Introduction

BENIGN breast diseases is one of the most common diseases in the females of any society. It is a group of breast diseases which is troublesome to the patient but is not cancer, nor do they progress to cancer. Up to 30% of women suffer from some benign breast disorders and this compels them to seek treatment [1]. The most common benign breast tumor is fibroadenoma, which is discovered in 67-94% of all biopsies in women under the age of 20 and is identified in 10% of all women in their lifetimes [2,3]. Triple assessment, which includes clinical examination, imaging and histopathology is the main method of approach in the diagnosis of breast diseases [4-6].

Surgical excision is the definitive procedure performed for symptomatic benign breast tumors to alleviate anxiety regarding potential for growth or malignancy as well as physical discomfort [7]. Endoscopic procedures have spread rapidly in various fields of surgery since the 1980s, and several procedures have already been widely established as standard operations in plastic surgery. Minimally invasive surgery has seduced the patient and the surgeon alike. It has advanced due to its appeal of low morbidity, early resumption of normal routine and better aesthetic results. Aesthetics is of paramount importance to any woman, especially when parts such as the breast must be treated. Endoscopic resection of fibroadenoma by creating a subcutaneous space maintained with continuous insufflation with carbon dioxide through the use of small axillary incisions that provides an anatomically contiguous area for creating access while preserving a scar-free breast. The axilla, an ana-

Abbreviations:

FNAC: Fine Needle Aspiration Cytology.
VAS : Visual Analogue Scale.

Correspondence to: Dr. Mohamed A. Shenashen,
[E-Mail: dr.shenashenmohamed@gmail.com](mailto:dr.shenashenmohamed@gmail.com)

tomically contiguous space, provides surgical access to the breast [8-10].

Patients and Methods

A total of 10 patients underwent endoscopic fibroadenoma excision between June 2016 and August 2017 at General Surgery Department in Tanta University Hospital. Informed consent was taken for the operation and inclusion in this study after detailed description. Approval by the local ethical committee was obtained before initiating this study.

Age, site, size, marital state, menstrual state, pre-operative assessment, nerve injury, and subcutaneous emphysema, rates of other post-operative complications, final pathology, post-operative pain and cosmetic results were analyzed. Patients with recurrent fibroadenoma, multiple swelling or suspicious breast masses were excluded from the study.

Pre-operative assessment:

Clinical assessments in all patients that include mass site, size and lymph node status (axillary, supra and infra clavicular). Imaging investigations in the form of Breast ultrasound to assess the lump site, size, number and Mammography in patients over 35 years if indicated (suspicious mass, positive family history of breast cancer). histopathological investigations in the form of Fine Needle Aspiration Cytology (FNAC).

Surgical procedure:

The patient was placed in the supine position with the ipsilateral upper limb abducted and extended so that the arm lay on the side of the patient's head. The side scheduled for surgery was elevated with a sand bag under the ipsilateral scapular region, and the operating table was tilted up by 20 to 30 degree. The fibroadenoma was located and fixed with a 22G spinal needle.

A 10 mm port was introduced in the mid axillary line at a level just opposite to the nipple then was advanced towards the breast, remaining superficial to the muscles of the anterior axillary fold. The advance towards the breast was guided by palpation of the trocar in the subcutaneous plane. From the periphery of the breast tissue, the trocar was guided toward the area of the fibroadenoma, which was stabilized by the left hand of the surgeon. The breast tissue was entered for about 2 to 3cm. The trocar was then removed. The sheath was connected to the gas for insufflation, and the 10-mm 30 degree scope was introduced. The space for access to the

site and for working around the fibroadenoma was achieved by sweeping or darting movements of the telescope through the avascular loose areolar tissue.

Once an adequate space had been created, two other 5mm ports were made; two finger breadths above and below the 10mm port. Dissection all around the fibroadenoma was performed with the use of monopolar electrocautry until it became totally free from the surrounding tissue. A small fibroadenoma was guided towards the 5-mm port where it could be squeezed out of the skin incision. If the fibroadenoma was large, it was guided toward the 10-mm port. The telescope was removed and changed to the 5-mm 30_ telescope, which was introduced through any 5-mm port. The fibroadenoma was grasped by the extractor introduced into the 10-mm port. The extractor is gently withdrawn with a simultaneous push on the fibroadenoma by the left hand. The 10-mm trocar was then withdrawn like a sleeve over the extractor. The tip of extractor was brought up to the skin incision then fibroadenoma was incised in a bag in the subcutaneous space and was then taken out of the breast piecemeal.

The space subjected to surgery was examined for any bleeding. Dissection along avascular planes ensures the absence of bleeding. Once the hemostasis was confirmed, gas deflation was performed, and the ports were taken out. No drains were used. The axillary port sites were sutured using prolene 3/0 simple suture and compression bandage was applied to the breast Figs. (1-7).

Post-operative management:

The patients were allowed to drink two hours after surgery and they were given augmented penicillin antibiotic (amoxicillin-clavulanic acid) one gram tablet every twelve hours and oral analgesic if needed. The breast was assessed the next morning for any evidence of bleeding from the port sites, bogginess in the area subjected to surgery, skin ecchymosis, or clinical evidence of injury to the axillary structure before discharge. The patient was discharged from the hospital on the second post-operative day. Augmented penicillin antibiotic (amoxicillin-clavulanic acid) one gram tablet every twelve hours was taken for four days and oral analgesic when needed. Post-operative pain was assessed using Visual Analogue Scale (VAS) [11].

Follow-up:

The patients were followed in the outpatient clinic and the sutures were removed one week post-operative. The patients then were advised to

resume normal Activity, Bath, Commitment, Diet, Exercise, and Fun (ABCDEF).

Then the patients followed-up monthly for six months. During their follow-up visits they have

been assessed in terms of pain, comfort level and cosmetic satisfaction about the scars using harvard scale introduced by Jay Harris in 1979. It classifies cosmetic results in four classes: Excellent; good; fair; poor.

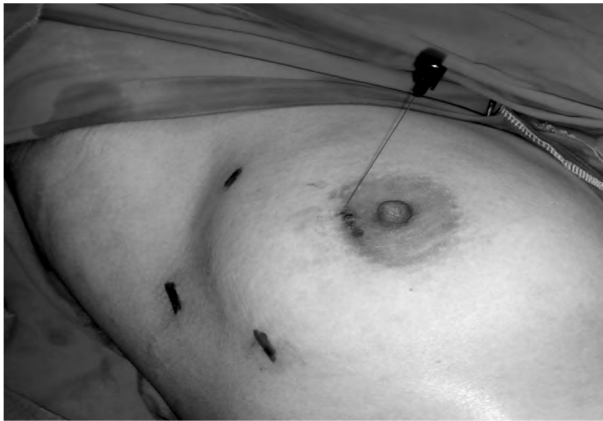

Fig. (1): Locating and fixing the mass with a22G spinal needle.

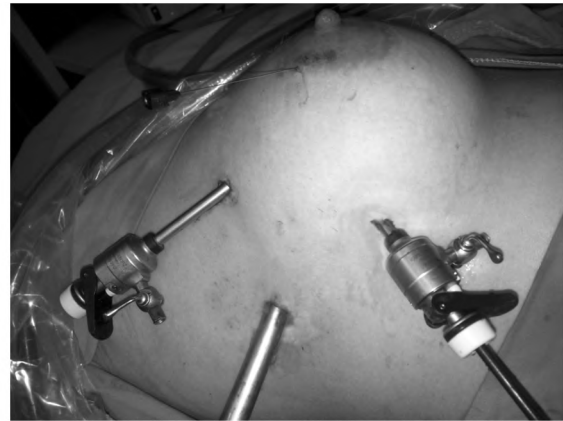

Fig. (2): Port placement.

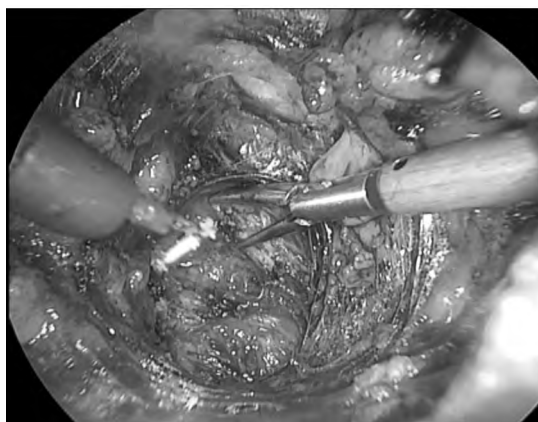


Fig. (3): Creating space for access to the site and for working around the fibroadenoma by sweeping or darting movements of the telescope through the avascular loose areolar tissue.

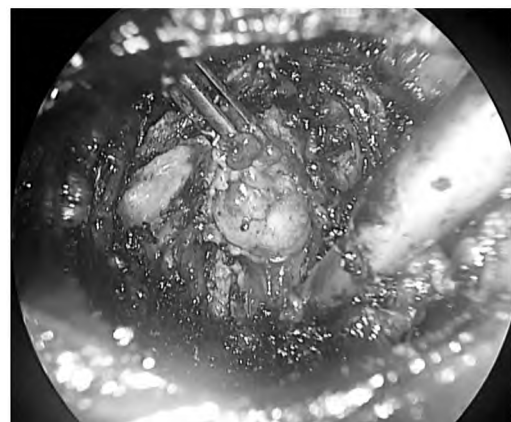


Fig. (4): Dissection around fibroadenoma.

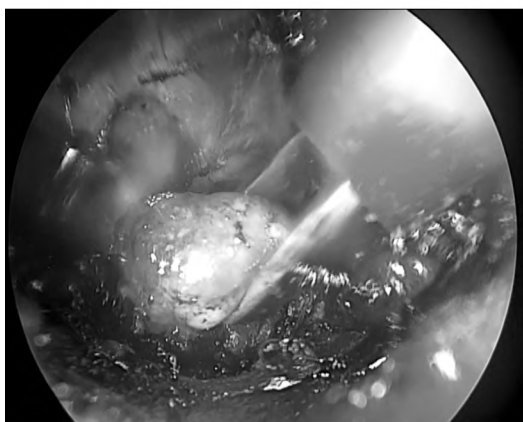


Fig. (5): Holding the dissected fibroadenoma by the extractor.

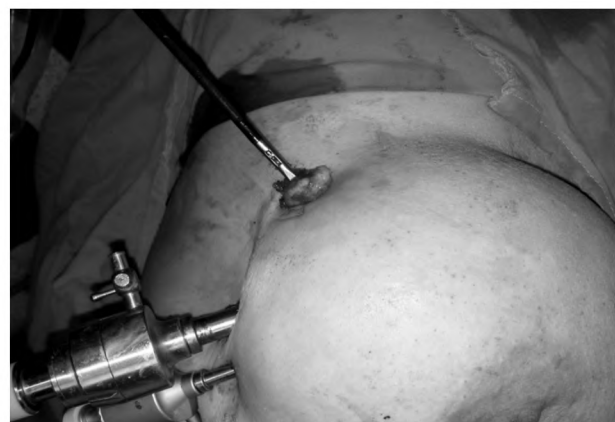

Fig. (6): A small fibroadenoma is guided towards the 5-mm port where it could be squeezed out the skin incision.

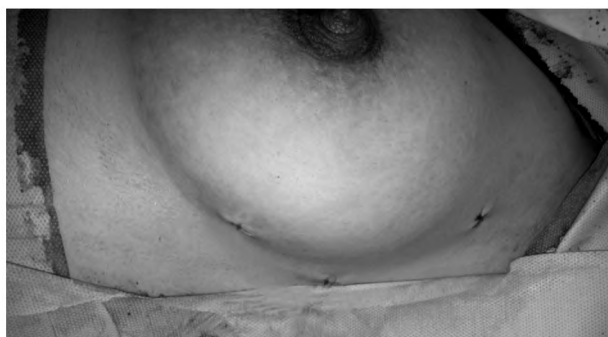

Fig. (7): Suturing the port sites.

Table (1): Harvard scale to assess cosmetic outcome [12].

Harvard/NSABP/RTOG Breast Cosmesis Grading Scale	
1- Excellent	When compared to the untreated breast, there is minimal or no difference in the size or shape of the treated breast. The way the breast feels (its texture) is the same or slightly different. There may be thickening, scar tissue, or fluid accumulation within the breast, but not enough to change the appearance.
2- Good	There is a slight difference in the size or shape of the treated breast as compared to the opposite breast or the original appearance of the treated breast. There may be some mild reddening or darkening of the breast. The thickening or scar tissue within the breast causes only a mild change in the shape or size.
3- Fair	Obvious difference in the size and shape of the treated breast. This change involves one-quarter or less of the breast. There can be moderate thickening or scar tissue of the skin and the breast, and there may be obvious color changes.
4- Poor	Marked change in the appearance of the treated breast involving more than one-quarter of the breast tissue. The skin changes may be obvious and detract from the appearance of the breast. Severe scarring and thickening of the breast, which clearly alters the appearance of the breast, may be found

NSABP: National Surgical Adjuvant Breast and Bowel Project.
RTOG : Radiation Therapy Oncology Group.

Results

Between June 2016 and August 2017; 10 patients with breast fibroadenoma underwent endoscopic fibroadenoma excision. Of these, 2 patients (20%) were single and 8 (80%) were married. The mean age of patients was 32.1 ± 8.8 (range 20-49) years. Of the 10 patients, 3 (30%) were post-menopausal and 7 (70%) were pre-menopausal (Table 2).

Table (2): Social characteristics of all studied patients.

Characteristics	(n=10) n. (%)
<i>Age (in years):</i>	
Mean \pm S.D	32.1 \pm 8.8
Range	20-49
<i>Marital status:</i>	
Single	2 (20.0%)
Married	8 (80.0%)
<i>Menopausal status:</i>	
Post-menopause	3 (30.0%)
Pre-menopause	7 (70.0%)

The right side fibroadenoma represented 70% of the patient and the left side represented 30% of them. As regard the site of fibroadenoma, the upper lesions represented 60%, lower lesions represented 20%, and the retro areolar lesions represented 20%. The fibroadenoma size ranged from 1.36 to 8 with a mean of 3.75cm (Table 3).

Table (3): Clinical characteristics of fibroadenoma.

Characteristics	(n=10) n. (%)
<i>Side:</i>	
Right	7 (70.0%)
Left	3 (30.0%)
<i>Site:</i>	
Upper	6 (60.0%)
Lower	2 (20.0%)
Retro areolar	2 (20.0%)
<i>Size (in cm):</i>	
Mean \pm S.D	3.75
Range	1.36-8

Detailed location of fibroadenoma was in the upper outer quadrant in 4 patients (40%), central supra-areolar lesion in 3 patients (30%), and the same presentation for upper inner, lower outer and lower inner lesions (10% each).

Pre-operative ultrasound was done for all cases showing that a well-defined oval shaped lesion in 8 patients and two lesions were lobulated hypoechoic with minute cystic degeneration with no calcifications. Pre-operative mammography was done in two patients only who were aged more than 35 years with suspicious findings on ultrasound, one patient had a well-defined mass, and one patient had irregular shaped soft tissue mass suggesting a benign nature of the mass (Table 4).

Fine Needle Aspiration Cytology (FNAC) was done for all patients. In 50% of the studied cases it showed sheets and groups of ductal epithelial cells surrounded with stromal proliferation suggesting fibroadenoma with no malignancy nor

dysplasia. Three patients had fibroadenoma with cellular dysplasia. Two patient had dysplastic ductal cell with fibroadenosis. However histopathological examination after excision revealed that infiltrating ductal carcinoma in one case (Table 5).

The operative time ranged from 32-90 minutes with a mean time of 58.4 ± 19.9 minutes.

Intra operative complications are described in (Table 5): Subcutaneous emphysema occurred in 3 patients (30%) and conversion to open technique occurred in 2 patients (20%) due to increased subcutaneous emphysema endanger the air way. There was no intra operative bleeding nor nerve injury.

There was no post-operative seroma, hematoma, wound infection, skin burn nor breast deformity in all cases.

Table (4): Pre-operative radiological finding.

Pre-operative investigation	(n=10)
<i>Pre-operative ultrasound:</i>	
Well-defined	9 (90.0%)
Heterogenous	2 (20.0%)
<i>Pre-operative mammography:</i>	
Not done	8 (80.0%)
Well defined mass	1 (10.0%)
Irregular shaped soft tissue mass	1 (10.0%)

Table (5): FNAC of the study patients.

FNAC	(n=10)
Fibroadenoma and no dysplasia	5 (50%)
Fibroadenoma with cellular dysplasia	3 (30.0%)
Dysplastic ductal cell with fibroadenosis	2 (20.0%)

Post-operative pain was assessed using Visual Analogue Scale (VAS) [11] showing that seven patients (70%) had mild post-operative pain required oral analgesia (diclofenac sodium 25mg tablet two times a day in the first post-operative day, and three patients (30%) had moderate post-operative pain required increased the dose to 50mg twice daily for three days (Table 6).

Table (6): Intra operative complications after endoscopic fibroadenoma excision.

Complications	(n=10)
Intra operative bleeding	0 (0.0%)
Subcutaneous emphysema	3 (30.0%)
Nerve injury	0 (0.0%)
Conversion to open technique	2 (20.0%)

Post-operative histopathology was stromal proliferation surrounding multiple benign proliferative ductal cells and epithelial cells consistent with fibroadenoma in nine patients (90%) while only one patient representing 10% of the histopathology was infiltrating ductal carcinoma grade III (pseudo medullary type). She was subjected to breast conservative surgery (Table 7).

The duration of hospital stay was 24 hours in seven patients (70%) and 48 hours in 3 patients (30%) until complete resolution of subcutaneous emphysema.

Table (7): Post-operative pain assessment.

Post-operative pain	(n=10)
No pain	0 (0.0%)
Mild pain	7 (70.0%)
Moderate pain	3 (30.0%)
Severe pain	0 (0.0%)

Table (8): Post-operative histopathology.

Histopathology	(n=10)
• Consistent with fibroadenoma	9 (90%)
• Infiltrating ductal carcinoma grade 3 (Pseudo medullary type)	1 (10.0%)

Patients' satisfaction about the scar six months post-operative was assed using Harvard scale [12]. It shows that seven out of eight patients (87.5%) (as we exclude the two open cases) considered the scar excellent while only one patient (12.5%) considered it good due to hypertrophic scar that was managed with local steroids injection Figs. (8, 9).

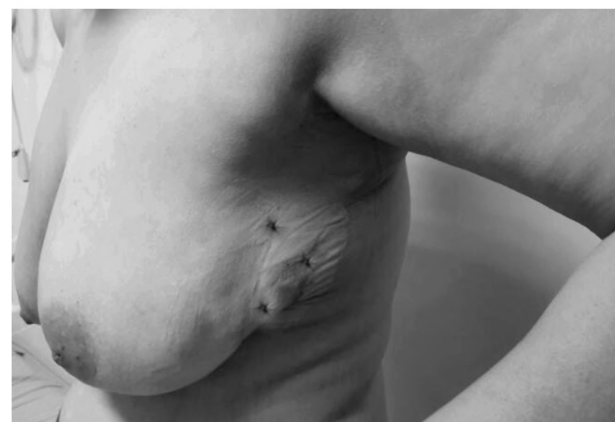

Fig. (8): Post-operative image after one week of a resected fibroadenoma in the upper inner quadrant of left breast showing three stitches in the port sites.

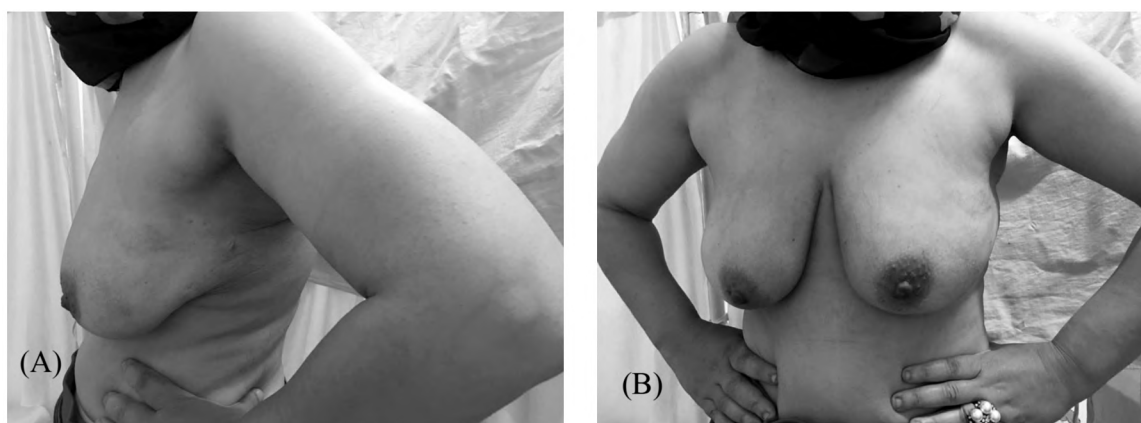


Fig. (9): A post-operative follow-up picture of the same previous patient six months post-operative lateral (A) and A-P (B) view; there is no visible scar at the port sites.

Discussion

Given the nonmalignant nature of fibroadenomas and other benign breast lesions, an important goal in treatment should be cosmesis. Currently, the accepted definitive treatment of surgical excision results in scar formation and potential for keloids, as well as breast volume loss and potential for nipple areolar distortion or displacement [13].

However, novel clinical experiences have been published describing new minimally invasive techniques with promising outcomes and cosmesis. These minimally invasive techniques include endoscopic lumpectomy, vacuum assisted percutaneous excisional biopsy, and percutaneous thermoablation with radiofrequency, laser, or cryotherapy [14].

Endoscopic techniques were developed in East Asia for the removal of breast tumors, both benign and malignant. The use of endoscopy for breast surgery was first performed by plastic surgeons to evaluate for breast implant rupture or leakage of silicone [15-17].

Kitamura reported the first use of endoscopic surgery for removal of benign breast tumors using trans-axillary approach while Osanai et al., reported a similar technique, but with an extensive dissection of the retro mammary space. They also reported the need to take care of perforator vessels [18,19].

In our technique, we dissected only along the avascular planes. Space was created only for the area subjected to surgery and not for the entire retro mammary dissection. Lumps in all quadrants of the breast could be excised. Any risk of insult to the axilla was avoided by limiting the dissection superficial to the anterior axillary fold. This was substantiated by the absence of any axillary or upper limb morbidity.

The present study included 10 female patients who were scheduled for endoscopic fibroadenoma excision. The patient's age ranged from 20 to 49 years with a mean age of 35 years. This agrees with the results of the study done by Kitamura and colleagues 2001, [18] which was conducted on 36 female patients with a mean age of 32.6 years old with a range from 18 to 47 years old. And also agree with the study done by Agrawal and colleagues 2008, [9] which was conducted on 14 female patients with a mean age of 35.78 with a range from 19 to 44. In comparison with another study done by Kitamura and colleagues 1998, [10] which was conducted on 6 female patients their age ranged between 16 to 34 years old with a mean of 22.5 years.

In our study; regarding the marital status; 8 out of 10 patients (80%) were married and 2 were single. This is coincide with the study done by Agrawal and colleagues 2008, [9] which reported that 9 out of 14 patients (65%) were married and 5 were single, while the study done by Kitamura and colleagues 1998, [10] reported that all 6 patients included in the study were unmarried.

In the present study; 7 patients reported right side fibroadenoma and only 3 patients reported left side fibroadenoma, despite Kitamura and colleagues 2001, [10] reported that 5 patients had left side fibroadenoma and only one patient had right side fibroadenoma.

In the current study; the size of the fibroadenoma ranged from 1.36cm to 8cm with a mean of 3.75cm. This agrees with Kitamura and colleagues 2001, [18] in which the size of the fibroadenoma ranged from 2.5cm to 11cm with a mean of 3.6cm and also agrees with the study done by Kitamura and colleagues 1998, [10] in which the size of the

fibroadenoma size ranged from 4cm to 6.5cm with a mean of 5.25cm.

In our study; the most common quadrant of the fibroadenoma is the upper outer quadrant (4 patients) 40%. This agrees with the study carried out by Agrawal and colleagues 2008, [9] which reported the presence of fibroadenoma in all breast quadrants with a percentage of 44% to upper outer fibroadenoma (8 out of 18 fibroadenoma).

In the current study; pre-operative Fine Needle Aspiration Cytology (FNAC) was done for all patients. It revealed that; 5 patients had fibroadenoma with no dysplasia, 3 patients had fibroadenoma with cellular dysplasia and 2 patients had dysplastic ductal cell with fibroadenosis. This agrees with Kitamura and colleagues 1998, [10] who reported that 5 patients had fibroadenoma and one patient had intra ductal papilloma. While in the study of Kitamura and colleagues 2001, [18] pre-operative Fine Needle Aspiration Cytology (FNAC) showed that 32 patients had fibroadenoma, 2 had granuloma, 2 had intra-ductal papilloma and only one patient had hamartoma.

In the current study; the operative time ranged from 32 to 90 minutes with a mean of 58.4 minutes. This agrees with the study done by Agrawal and colleagues 2008, [9] with an operative time ranged from 40 to 110 minutes with a mean of 66.78 minutes. While Kitamura and colleagues 1998, [10] reported the operative time from 2.5 to 6 hours with a mean of 3 hours and 12 minutes and also disagree with Kitamura and colleagues 2001, [18] who reported operative time ranged from 55 minutes to 6 hours and 5 minutes with a mean of 2 hours and 27 minutes.

In the present study; we reported the conversion of endoscopic technique into open technique in 2 cases due to increased subcutaneous emphysema to a level that endanger the air way while neither of Agrawal colleagues 2008, [9] Kitamura and colleagues 2001, [18] nor Kitamura and colleagues 1998, [10] reported any conversion rate.

In the current study; subcutaneous emphysema had occurred in 3 patients. This agrees with Kitamura and colleagues 1998, [10] who reported subcutaneous emphysema in one case and also agree with Kitamura and colleagues 2001, [18] who reported subcutaneous emphysema extending to the neck due to excessive carbon dioxide gas inflation in one case. While Agrawal and colleagues 2008, [9] reported that; there was no surgical emphysema in their studied patients.

In the present study; there is no skin burn reported at any case. This agrees with the study done by Agrawal and colleagues 2008, [9] in which there was no reported cases of skin burn. While Kitamura and colleagues 1998, [10] reported skin burn in one case since the fibroadenoma was located just below the skin with severe adhesion and also Kitamura and colleagues 2001, [18] reported skin burn in one case.

In the current study; as regard skin ecchymosis and subcutaneous bleeding; it wasn't reported at any of our study patients. This agrees with Agrawal and colleagues 2008, [9] while Kitamura and colleagues 1998, [10] reported subcutaneous bleeding and skin ecchymosis in all cases that disappear 7 days post-operative.

In the current study; there was no nerve injury as any risk of insult to the axilla was averted by limiting the dissection superficial to the anterior axillary fold. This was substantiated by the absence of any axillary or upper limb morbidity. This agrees with Kitamura and colleagues 1998, [10] Kitamura and colleagues 2001, [18] and Agrawal and colleagues 2008, [9] who reported the absence of axillary nerve injury at any of operated cases.

In the present study; there was no intra-operative bleeding nor wound infection. The same results were reported by Kitamura and colleagues 2001, [18] and Agrawal and colleagues 2008, [9].

In the present study; post-operative pain was mild and the use of Non-Steroidal Anti-Inflammatory Drugs (NSAD) in the form of diclofenac sodium was sufficient and that agree with Agrawal and colleagues 2008, [9] who reported insignificant pain with the use of paracetamol tablets for only two days post-operative.

In the current study; the post-operative histopathology consistent with fibroadenoma in nine patients (90%) and infiltrating ductal carcinoma in one patient (10%). This disagrees with Agrawal and colleagues 2008, [9] who reported no malignancy in any of the lumps excised.

In the present study; seven patients discharged from hospital in the second post-operative day and three patients discharged in the third post-operative day until resolution of the subcutaneous emphysema. This agree with Kitamura and colleagues 1998, [10] who reported that; the hospital stay was 3 days in two patients and four patients were discharged after one post-operative day. While Agrawal and colleagues 2008, [9] reported that all patients were discharged on the same day.

In the current study; as regard patients' satisfaction about the scar and after exclusion of the two cases that converted to open technique, all patients appreciated the absence of a cut on the breast. 7 patients exhibit excellent result while only one patient exhibits good result. This agrees with Agrawal and colleagues 2008, [9] who reported that all patients were satisfied and visibly happy with the operation, and also agree with Kitamura and colleagues 1998, [10] who reported that; all patients were satisfied with the size and position of the scars and also agrees with Kitamura and colleagues 2001, [18] who reported that; all patients were extremely satisfied with the cosmetic results of the procedure.

Conclusion:

Endoscopic trans-axillary excision of fibroadenoma of the breast is an easy, safe and feasible technique; it has excellent cosmetic outcomes with high patient's satisfaction as scars on the breast were avoided. The operative time is comparable to conventional technique without increasing risk of complication. We now believe endoscopic extirpation is one of the best options to treat a benign breast mass. We recommend performing further studies with larger population scale and longer follow-up to confirm and support the results.

References

- 1- YADAVA S.S., BISHWAS N.C. and KIDWAI M.: Pattern of breast diseases in breast lump; J.N.G.M.C., Jan., 3: 49-51, 2003.
- 2- LAUFER M.R. and GOLDSTEIN D.P.: The breast: Examination and lesions. In: Emans S.J., Laufer M.R., Goldstein D.P. eds. Pediatric & Adolescent Gynecology. 5th ed. Philadelphia: Lippincott Williams & Wilkins, 729-59, 2005.
- 3- SMITH B.L.: FIBROADENOMAS. IN: HARRIS J.R., HELLMAN S., HENDERSON I.C., et al.: eds. Breast diseases. 2nd ed. Philadelphia: Lippincott, 34-7, 1991.
- 4- PHILLIPO L. CHALYA, MANGE MANYAMA, PETER F. RAMBAU, et al.: Clinicopathological pattern of benign breast diseases among female patients at a tertiary health institution in Tanzania Tanzania Journal of Health Research Volume 18, Number 1, January, 2016.
- 5- SRIVATSAVA A. and DHAR A.: Benign Breast Disease: A neglected entity. Recent Advances in Surgery, 10: 175-201, 2006.
- 6- HUGHES L.E., MANSEL R.E. and WEBSTER D.J.T.: The approach to diagnosis and assessment of benign breast lumps. Benign Disorders and Diseases of the Breast Concepts and Clinical Management, 2nd edn. London: WB Saunders, 35, 2005.
- 7- DIXON J.M., DOBIE V., LAMB J., et al.: Assessment of the acceptability of conservative management of fibroadenoma of the breast. Br. J. Surg., 83: 264-5, 1996.
- 8- APONTE-RUEDA, MARÍA EUGENIA, SAADE CÁRDENAS, et al.: Endoscopic Breast Surgery Applied To Benign Tumors Cirurgia Endoscópica de Mama Aplicada a Tumores Benignos. Bras. J. Video-Sur., V. 3, N. 4: 186-90, 2010.
- 9- AGARWAL B., AGARWAL S., GUPTA M., et al.: Transaxillary endoscopic excision of benign breast lumps: A new technique. Surg. Endosc., 22: 407-10, Doi: 10.1007/s00464-007-9435-1, 2008.
- 10- KITAMURA K., HASHIZUME M., KATAOKA A., et al.: Transaxillary approach for the endoscopic extirpation of benign breast tumors. Surg. Laparos. and Endosc., 8: 277-9, 1998.
- 11- HAWKER, GILLIAN A., MIAN S., et al.: "Measures of adult pain: Visual analog scale for pain (vas pain), numeric rating scale for pain (nrs pain), mcgill pain questionnaire (mpq), short-form mcgill pain questionnaire (sf-mpq), chronic pain grade scale (cpgs), short form-36 bodily pain scale (sf-36 bps), and measure of intermittent and constant osteoarthritis pain (icoap)". Arthritis care & research 63.S11, 2011.
- 12- TROMBETTA M., JULIAN T.B., KIM Y., WERTS E.D. and PARDA D.: The allegheny general modification of the Harvard Breast Cosmesis Scale for the retreated breast. Oncology (Williston Park), 23 (11): 954-6, 2009.
- 13- ANDERSON B.O., MASETTI R. and SILVERSTEIN M.J.: Oncoplastic approaches to partial mastectomy: An overview of volumedisplacement techniques. Lancet Oncol., 6: 145-57, 2005.
- 14- LAKOMA, ANNA and EUGENE S. KIM: "Minimally invasive surgical management of benign breast lesions." Gland. Surgery, 3.2: 142, 2014.
- 15- KOMPATSCHER P.: Endoscopic capsulotomy of capsular contracture after breast augmentation: A very challenging therapeutic approach. Plast. Reconstr. Surg., 90: 1125-6, 1992.
- 16- DOWDEN R.V. and ANAIN S.: Endoscopic implant evaluation and capsulotomy. Plast. Reconstr. Surg., 91: 283-7, 1993.
- 17- COLON G.A. and D'AMORE T.F.: Mammoscopy: The endoscopic intracapsular evaluation of mammary prostheses. Plast. Reconstr. Surg., 91: 382-3, 1993.
- 18- KITAMURA K., INOUE H., ISHIDA M., et al.: Endoscopic extirpation of benign breast tumors using an extramammary approach. Am. J. Surg., 181: 211-4, 2001.
- 19- OSANAI T., NIHEI Z., ICHIKAWA W., et al.: Endoscopic resection of benign breast tumours. Surg. Laparos and Endosc. Perctan. Tech., 12: 100-03, 2002.

إستئصال أورام الثدي الغدية-الليفية بواسطة المنظار الجراحى

تعتبر أمراض الثدي الحميدة واحدة من أشهر الأمراض التى تصيب السيدات فى أى مجتمع حيث أن بالرغم من كونها ليست أمراض خبيثة ولكن يعانى أكثر من ٣٠٪ من السيدات من مثل هذه الأمراض خلال فترات حياتهم والتى تجبرهم على البحث عن علاج لها. ويستخدم حاليا المنظار الجراحى لإستئصال الأورام الغدية-الليفية.

أجريت هذه الدراسة على ١٠ مرضى من الإناث كن يعانين من أورام الثدي الغدية الليفية بوحدة جراحة الأورام بقسم الجراحة العامة، مستشفى طنطا الجامعى فى الفترة من يونيو ٢٠١٦ إلى أغسطس ٢٠١٧.

تراوح عمر المرضى من ٢٠ إلى ٤٩ عاما وكان ٨ من المرضى متزوجات بينما المريضتين الأخرتين غير متزوجات. وبدراسة الأماكن التى يتواجد بها الورم الغدى الليفى بالثدى وجد أنه أكثر إنتشارا بالربع العلوى الخارجى بنسبة ٤٠٪. وترواحت مدة إجراء الجراحة من ٣٢ دقيقة إلى ٩٠ دقيقة. وعند تقييم المضاعفات الناتجة من إستخدام المنظار الجراحى لإستئصال أورام الثدي الغدية الليفية وجد أنه حدوث تجمع هوائى تحت الجلد كانت أكبر المضاعفات الناتجة عن العملية بنسبة حوالى ٣٠٪. وعند تقييم النتائج الجمالية للجراحة وجد أنه ٨٧.٥٪ من المرضى يجدون أن النتائج ممتازة فى حين يجد ال ١٢.٥٪ الباقين النتائج جيدة.

إن إستئصال الأورام الغدية الليفية بواسطة المنظار الجراحى هى طريقة سهلة، آمنة وذو نتائج جمالية ممتازة مع رضا كامل لجميع المرضى حيث أن وقت إجراء الجراحة يقارب نفس الوقت المستخدم فى الطرق التقليدية، مع عدم حدوث مضاعفات. حيث نوصى بإستخدام هذه الطريقة لإستئصال أورام الثدي الحميدة. ونحن بحاجة إلى إجراء المزيد من الدراسات على عدد أكبر من المرضى ومدة متابعة أطول لدعم نتائج هذه الدراسة.