

Effect Of Hepatic Diseases On Serum Protein Electrophoresis In Goats

Sahar A Abou El-Waffa

Veterinary Clinic, Faculty of Vet.Med., Assiut University, Assiut, Egypt.

ABSTRACT

This study was carried out to show the effect of some liver affections on blood serum proteins in goats using cellulose acetate scanning electrophoresis.

Twenty four blood samples were collected from male goats (10 – 12 months old) showed emaciation, lack of appetite, poor growth and edema . in addition to 10 healthy age matching male goats as a control group.

After slaughtering, examined goats were classified according to gross pathological investigation of liver affections into 3 groups as following:

Group (I) : consisted of 10 goats and suffered from Chronic cholangio-hepatitis was characterized by localized partially fibrous peri-hepatitis with slightly fibrosed bile ducts and the gall bladder was enlarged. Biochemical analysis showed an elevation in total proteins , β -region and total globulins , reduction in albumin and ratio of albumin to globulin

Group (II) : consisted of 7 goats and suffered from liver abscesses which ranged from lemon to orange in size, either embedded or raised from the hepatic surface with hemorrhagic surroundings. Biochemical analysis showed an elevation in α -, β - and γ -region and total globulins , reduction in of albumin to globulin ratio .

Group (III): consisted of 7 goats and suffered from liver cirrhosis ,the liver had lobulated irregular surface, pale and firm with enlarged fibroses gall bladder. Biochemical analysis showed an elevation in total globulins , reduction in total proteins , albumin, α - , β -region and ratio of albumin to globulin .

It can be concluded that the electrophoretic pattern of serum protein is changed according to the type of liver disease. Also, goats in which the liver can synthesize serum albumin, α and / or β -globulins have a probable fairly good prognosis as it represents chronic cholangio-hepatitis or hepatic abscesses. On the other hand, those with reduced albumin, α and β -globulins as in liver cirrhosis, the prognosis is probably poor.

INTRODUCTION

The concentration of serum proteins reflects the health status because they are nutritive, and they are carrier and transport component for most of the plasma constituents , in addition to their function in body defenses (1). Majority of plasmatic proteins is synthesized in hepatocytes, with albumin representing their largest quantitative part (2).

Except for albumin (protein), all plasmatic proteins are glycoproteins. Individual protein fractions, or blood serum proteins, have

different functions and their identification are used also as a diagnostic tool (3). Many of these proteins are the so-called acute phase proteins (4). Individually, α -globulin fraction consisted mainly of α 1-antitrypsin, α 1-acid glycoprotein, α 1- lipoproteins, α 2-lipoproteins, α 2-macroglobulin, ceruloplasmin, haptoglobin and serum amyloid A. β -region is subfractionated into β 2-lipoprotein, ferritin, C-reactive protein, fibrinogen, transferrin and some immunoglobulins. γ -Globulin represents immunoglobulins A, G, M and E (1,3- 6).

From a clinical perspective, the evaluation of plasma proteins is used for monitoring clinical progress and as a disease marker (7). These proteins can react in response to disturbances in animal's homeostasis caused by infection or tissue injury (5) and their variations may indicate that tissue damage has occurred at the time when there are no clinical signs of the process in question (6).

The frequency and nature of liver diseases vary with species, breed, age, environment, diet and geographical localities, diagnostic liver profile often provides sensitive and specific values in assessing severity of liver diseases, monitoring the pathophysiological mechanisms essential for successful treatment and screening of individuals to be at risk of the disease (8).

The assay of these proteins is a useful diagnostic tool for some inflammatory reactions (3,6, 9) and for detection of hepatic diseases in dogs (10) and cows (11), but little is known on goats. Therefore, the present study was undertaken to evaluate the efficacy of blood serum protein electrophoretogram by using titan III cellulose acetate plate in goat liver diseases in comparison with gross pathological investigations of the liver.

MATERIALS AND METHODS

Animals and sampling: male goats (10–12 months old) admitted for slaughtering at slaughtering points in Assiut City were clinically examined for signs of hepatic affections including emaciation, lack of appetite, poor growth and edema appeared on some affected goats

Blood samples for serum separation were collected from suspected cases. During post-mortem examinations, livers of these animals were thoroughly examined for distinct gross lesions.

The investigations revealed various liver affections in 24 cases. The corresponding

labeled blood samples were classified according to the gross pathological findings into 3 groups as described (12). Namely, these groups were chronic cholangio-hepatitis (10 goats), hepatic abscess (7 goats) and hepatic cirrhosis (7 goats). In addition, 10 blood samples were obtained from healthy age matching male goats and used as a control group.

Biochemical analysis: Biuret reaction was used for determination of total protein (13). Protein electrophoretogram was carried out by using titan III cellulose acetate plate at pH 8.8 at ionic strength of 0.067, stained by Ponceau S stain and scanned by autodensitometer (Helena Laboratories) at absorption peak of 525 nm (13) and manufacture instructions). The absolute value of each fraction (g/dl) was calculated from its relative percent at the integrator scale on the scan depending on the total protein value of the sample (13).

Statistical analysis

Data were analyzed using the packaged SPSS program for Windows Version 18.0.1 (SPSS Inc., Chicago, IL.). Differences between groups were determined by the one way analysis of variance (ANOVA) followed by means of pairwise multiple comparison procedures (when significant F test was found) using Duncan's new multiple range test. Data were presented as mean \pm standard error (SE). Significance level was set at $P < 0.05$.

RESULTS

Clinical findings

No specific clinical signs appeared on the liver affected goats. Emaciation, lack of appetite, poor growth and edema appeared on some affected goats specially those with hepatic cirrhosis.

Gross findings of the liver

Examined goats were classified according to gross pathological investigation of liver affections into 3 groups as

Group (I): consisted of 10 goats and suffered from Chronic cholangio-hepatitis was characterized by localized partially fibrous peri-hepatitis with slightly fibrosed bile ducts and the gall bladder was enlarged.

Group (II) : consisted of 7 goats and suffered from liver abscesses ranged from lemon to orange in size, either embedded or raised from the hepatic surface with hemorrhagic surroundings.

Group (III): consisted of 7 goats and suffered from liver cirrhosis and characterized by hepatic fibrosis, and the liver had lobulated irregular surface, pale and firm with enlarged fibrosed gall bladder.

Biochemical findings

Cellulose acetate scanning electrophoresis of blood serum proteins of the investigated goats are presented in Photogram (1). It illustrates the different fractionation patterns of blood serum proteins in various liver affections in addition to control goats. The absolute values of these fractions are presented in Table (1).

Albumin

The mean values of serum albumin in cases of chronic cholangio-hepatitis and hepatic abscess were insignificantly differed than the mean values of control animals. Animals with hepatic cirrhosis showed significant reduction ($P < 0.001$) in the mean values of serum albumin if compared with other affected groups.

Globulins

α -globulin: The trend of α -globulin differs with the nature of hepatic affection. Its mean value was quietly increased in cases of hepatic abscess ($P < 0.01$) and it was normal in chronic cholangio-hepatitis ($P > 0.05$). It was at its lowest level in cases of hepatic cirrhosis ($P < 0.01$) compared with other groups.

β -globulin: The mean value of β -globulin was significantly elevated ($P < 0.05$) in goats with chronic cholangio-hepatitis and hepatic abscess, but it markedly reduced ($P < 0.01$) in cases of hepatic cirrhosis in comparison with normal animals.

γ -globulin: The mean value of γ -globulin was markedly increased ($P < 0.05$) in group with hepatic abscess when compared with the control one, but it did not significantly change ($P > 0.05$) in groups affected by chronic cholangio-hepatitis and hepatic cirrhosis.

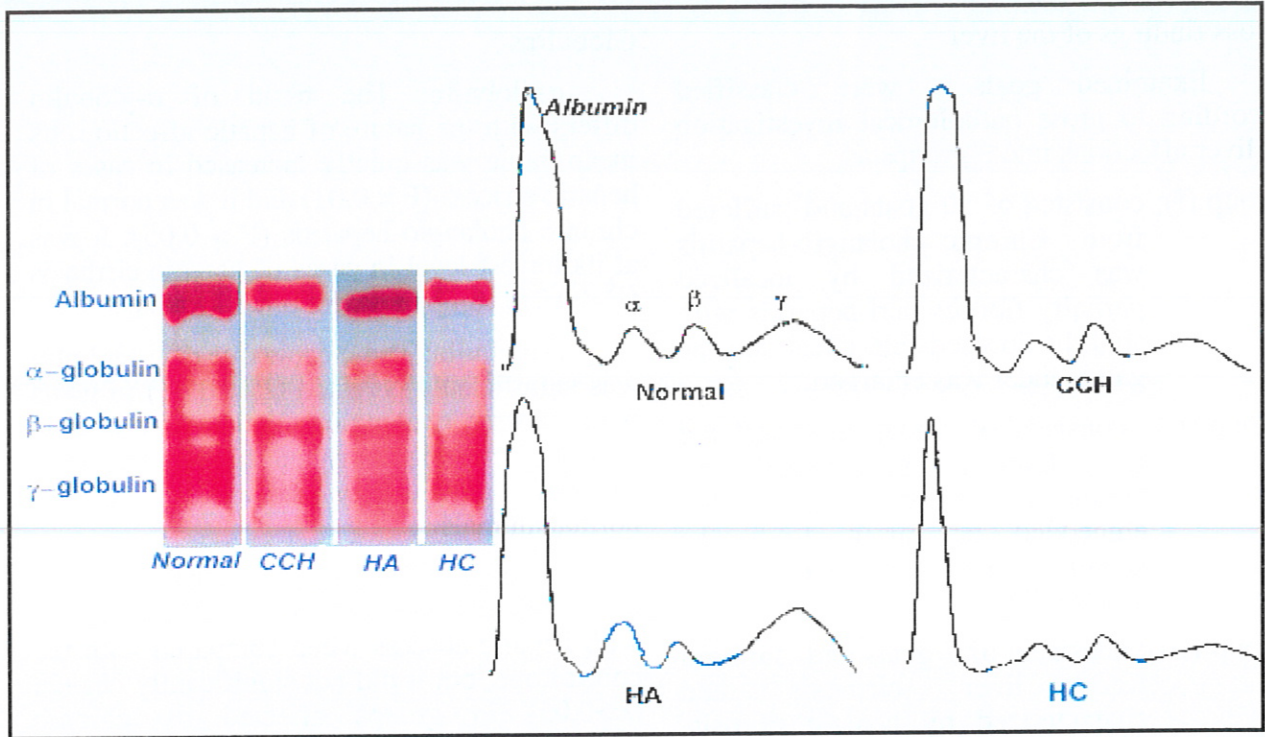
Total globulins: Mean values of serum total globulin significantly increased in cases of chronic cholangio-hepatitis ($P < 0.05$) and hepatic abscess ($P < 0.01$), but the value did not change in cases of hepatic cirrhosis if compared by control group.

Albumin/globulin ratio (A/G)

A/G showed significant reduction in groups of goats with hepatic abscess ($P < 0.001$) and hepatic cirrhosis ($P < 0.001$), but it did not change significantly in CCH cases as it illustrated in Table (1)

Total proteins

The mean values of total serum proteins showed insignificant increase in goats with chronic cholangio-hepatitis ($P > 0.05$). Goats with hepatic abscess showed marked elevation ($P < 0.05$) while those with hepatic cirrhosis showed a significant reduction ($P < 0.001$) in the mean value of total proteins if compared by control animals.



Photogram 1. Goat blood serum protein electrophoretic pattern on cellulose acetate plate. A model cases for: Normal liver, chronic cholangiohepatitis (CCH), hepatic abscess (HA) and hepatic cirrhosis (HC).

Table 1. Mean values \pm SE of blood serum proteins and cellulose acetate protein fractions (g/l) in liver affections of goats

	Normal liver (N = 10)	Chronic cholangio-hepatitis (N = 10)	Hepatic abscess (N = 7)	Hepatic cirrhosis (N = 7)
T. proteins (g/l)	69.1 \pm 6.3 ^a	70.9 \pm 7.1 ^a	76.2 \pm 5.5 ^b	49.5 \pm 3.7 ^c
Albumin (g/l)	33.1 \pm 4.2 ^a	31.5 \pm 5.4 ^a	30.2 \pm 2.7 ^a	15.9 \pm 2.9 ^b
α -Globulin (g/l)	9.3 \pm 1.5 ^a	9.1 \pm 0.16 ^a	12.5 \pm 1.9 ^b	7.2 \pm 1.7 ^c
β -Globulin (g/l)	7.8 \pm 0.9 ^a	10.1 \pm 1.5 ^b	9.9 \pm 1.4 ^b	5.9 \pm 0.9 ^c
γ -Globulin (g/l)	18.9 \pm 2.1 ^a	20.2 \pm 1.4 ^{ab}	23.6 \pm 2.1 ^b	20.5 \pm 1.9 ^{ab}
T. globulin (g/l)	36.0 \pm 3.4 ^a	39.4 \pm 2.5 ^b	46.0 \pm 3.9 ^c	33.6 \pm 2.1 ^a
A / G	0.92 \pm 0.16 ^a	0.80 \pm 0.13 ^a	0.66 \pm 0.11 ^b	0.47 \pm 0.09 ^c

Values in the same protein category with unlike descriptive superscript letters a,b,c, are significantly different at $P < 0.05$.

DISCUSSION

The clinical findings and the gross lesions appeared on the liver of the affected goats are in accordance with those previously recorded by (21).

The normal values of total serum protein and the normal absolute values of electrophoretic patterns in normal goats in the current study concur with the previous normal results cited by (14-20).

Hypoalbuminaemia in liver diseases may be reversible or irreversible. A switch in the production of protein by the liver towards the increased synthesis of positive acute phase proteins causes reversible decrease in the synthesis of albumin and concomitantly a negative case of acute phase hypoalbuminaemia is induced (7). In addition, ascites and increased capillary permeability with a concomitant redistribution of albumin in the third space may explain the induced moderate hypoalbuminaemia in cases of acute hepatitis (21). In the current study, serum albumin levels were normal in cases of chronic cholangio-hepatitis and hepatic abscess in goats. (8) reported that the liver has great functional reserve and only 25-30 % of normal liver function is considered sufficient to maintain normal concentration of serum albumin, which may confirm our results. In animals with terminal liver disease (cirrhosis), the concentration of albumin was nearly halved (15.9 ± 2.9 g/l) if compared with the normal value (33.1 ± 4.2 g/l) which reflect the severe impairment liver function and the inability of the liver to synthesize this protein fraction.

α -Globulin consists mainly of α_1 -antitrypsin, α_1 -acid glycoprotein, α_2 -macroglobulin, serum amyloid A and haptoglobin. These individual proteins were shown to increase as acute phase proteins (APP) during acute inflammatory diseases in cattle and other species (4,6, 9, 22, 23).

A similar increase was observed in goats in the present investigation, particularly in individuals with hepatic abscess. In goats with liver cirrhosis, the mean value of α -globulin

was reduced and lost near a quarter of its value indicating the impairment liver function and the inability of the liver to synthesize this protein fraction.

In addition to β_2 -lipoprotein, serum β -globulin consists mainly of positive APP (ferritin and complement component) which increase in acute inflammation and negative APP, transferrin which decreases in acute inflammation (1). In despite, both these positive and negative APP in this fraction might increase in acute and chronic liver affections (3). Similar trend was observed in the behavior of β -globulin in the present study. It was noticed that the mean value of β -globulin increased in all forms of liver affections except cases with liver cirrhosis in which β -globulin was reduced and lost third its value if compared with healthy animals. It is suggested that the severe reduction in serum albumin, α and β -globulin levels is probably irreversible as a result of impairment liver function and may reflect the disturbances in hepatocytes secretion and the inability of the liver to synthesize the protein components of these fractions.

The mean value of γ -globulin concentration in this study was quietly normal in all forms of hepatic diseases except in liver abscess. This fraction is consists mainly of immunoglobulins. The synthesis of γ -globulin is not hepatic origin but as a result of the respond of B cells to antigenic stimuli in the liver with the proliferation of plasma cells to produce specific immunoglobulin (1). The hyper γ -globulinemia in animals with hepatic abscess may reflect the more intense antigenic response generated.

Concomitantly, the behavior of albumin and globulin fractions resulted in variations in the mean values of total globulin, A/G and total proteins in different forms of hepatic diseases. The obtained results coincide with those reported for cattle and other species (1,4, 24).

Signs of hepatic failure often do not develop until 70% or more of the functional capacity of the liver is lost and recovery is

possible because of the unique capacity of the liver to regenerate (8). Irrespective of clinical signs and the values of serum total protein, albumin, and total globulin, which may be normal, increased or decreased during various liver affections, it is suggested that the values of α and β -globulin may be prognostic. Individuals in which the liver can synthesize serum proteins of α and or β -region may have a fairly good prognosis. (21) pointed out that acute hepatitis, hepatic necrosis, chronic cholangio-hepatitis or hepatic abscess are ready to be cured after appropriated tentative and ancillary treatments. On the other hand, it appeared that goats affected by liver cirrhosis depend on hepatic residue with reduced α and β -globulin. Treatment of such cases is hopeless, so that α and β -globulin values in such cases indicate poor prognosis.

The present results showed that the simple scanning electrophoresis of serum proteins is a useful and complement test in the diagnosis and can be a valuable test for prognosis of hepatic diseases in goats.

REFERENCES

1. **Kaneko JJ (1997):** Serum Proteins and Dysproteinemia, In: J. J. Kaneko, J.W. Harvey and M. L. Bruss (eds) Clinical Biochemistry of Domestic Animals . 5th Ed (Academic Press, London) 117 – 138.
2. **Elmaouhoub A, Dudas J and Ramadori G (2007):** Kinetics of albumin- and alpha-fetoprotein-production during rat liver development. Histochem Cell Biol 128: 431-443.
3. **Thomas, J S (2000a):** Overview of plasma proteins. In: B.F. Feldman, J.G. Zinkl and N.C. Jain (eds), Schalm's Veterinary Hematology, 5th Ed., (Lippincott Williams & Wilkins, Philadelphia and Baltimore). pp 891-898.
4. **Thomas JS(2000b):** Protein Electrophoresis. In Schalm's Veterinary Hematology. 5th Ed. Feldman, B. F; Zinkl, J.G. and Jain, N.C., Lippincott Williams & Wilkins, Philadelphia, Baltimore. pp. 899-903.
5. **Thompson D, Milford-Ward A and Whicher J T (1992):** The value of acute phase protein measurement in clinical practice. Ann. Clin. Biochem. 29: 123-131.
6. **Gruys E, Obwolo MJ and Toussaint M J M (1994):** Diagnostic significance of the major acute phase proteins in veterinary clinical chemistry: a review. Veterinary Bulletin, 64, 1009-1018.
7. **Eckersall P D (2000):** Recent advances and future prospects for the use of acute phase proteins as markers of disease in animals. Revue Med. Vet. 151: 577-584.
8. **Tenant BC (1997):** Hepatic function. In Clinical biochemistry of domestic animals. 5th ed. Kaneko, J. J; Harvey, J. W. and Bruss, M. L., Academic press, London.
9. **Horadagoda N U, Knox K M, Gibbs H A, Reid S W, Horadagoda A, Edwards S E R and Eckersall PD (1999):** Acute phase proteins in cattle: discrimination between acute and chronic inflammation. Veterinary Record, 144, 437-441.
10. **Sevelius E and Andersson M (1995):** Serum protein electrophoresis as a prognostic marker of chronic liver disease in dogs. Vet.Rec, 137: 663-667.
11. **Nakagawa H, Yamamoto O, Okawa S, Higuchi H, Watanabe A and Katoh N (1997):** Detection of serum haptoglobin by enzyme-linked immunosorbent assay in cows with fatty liver. Research in Veterinary Science, 62: 137-141.
12. **Jones TC, Hunt RD and King NW (1997):** Veterinary Pathology, 6th ed., Williams & Wilkins, Baltimore, Philadelphia, London. PP. 1232.
13. **Henry RJ, Cannon DC and Winkelman J W (1974):** Clinical Chemistry. Principles and Techniques. Harper and Row, Hagerstown MD.

14. **Castro A, Dhindsa DS, Hoversland AS and Metcalfe J (1977):** Serum proteins and protein electrophoretic pattern in normal pygmy goats. *Am J Vet Res.* 38(5):665-667.
15. **Mbassa GK and Poulsen JS (1993):** Reference ranges for clinical chemical values in Danish Landrace goats. *Small Rumin. Res.* 2: 133-142.
16. **Alberghina DI, Casella S, Vazzana I, Ferrantelli V, Giannetto C and Piccione G (2010):** Analysis of serum proteins in clinically healthy goats (*Capra hircus*) using agarose gel electrophoresis. *Vet Clin. Pathol.* ; 39 (3):317-321.
17. **Pollastry VAD, Ana CDS, Silvia MMA and Bito SB (2010):** Serum Protein Electrophoretic Profile of Goats Infected with *Haemonchus contortus*., *Journal of Animal and Veterinary Advances*, 9: 1603-1606 .
18. **Lenka J, Leoš Pavlata, Eubica Mišurová, Jaroslav Filípek, Alena Pechová, and Rudolf Dvořák (2011):** Levels of protein fractions in blood serum of periparturient goats. *Acta Vet. Brno*, 80: 185-190.
19. **Giuseppe P, Vanessa Messina, Claudia Giannetto; Stefania Casella, Anna Assenza and Francesco Fazio (2011):** Seasonal variations of the serum proteins in sheep and goats (Short Communication). *Archiv Tierzucht.*, 54: 399-405.
20. **Esmailnejad B, Tavassoli MI, Asri-Rezaei S, Dalir-Naghadeh B, Mardani K Farhagh-pajouh F and Abtahi SM (2013):** Serum protein alterations in goats naturally infected with *Babesia ovis*. *Iranian Journal of Veterinary Research*, Shiraz University, 2013, 14 ,(2).
21. **Radostits OM, Gay CC, Hinchcliff K W and Constable PD (2007):** *Veterinary Medicine*, 10th Ed. (saunders Elsevier , Edinburgh, London, New York Philadelphia, St Louis Sydney Toronto).
22. **Smith BI, Donovan GA, Risco CA, Young, CR and Stanker LH (1998):** Serum haptoglobin concentrations in Holstein dairy cattle with toxic puerperal metritis. *Veterinary Record*, 142, 83-85.
23. **Karreman HG, Wentink GH and Wensing Th (2000):** Using serum amyloid A to screen dairy cows for sub-clinical inflammation. *Veterinary Quarterly.*, 22, 175-178.
24. **Johnston JK and Morris DD (1996):** Alterations in blood proteins. In Smith, B. P. *Large Animal Internal Medicine*, 2nd Ed. Mosby, Year Book Inc. St. Louis.

الملخص العربي

تأثير أمراض الكبد على نمط التحليل الكهربائي لبروتينات مصلى الدم فى الماعز

سحر أحمد ابوالوفا

المستشفى البيطرى التعليمى - كلية الطب البيطرى - جامعة اسبوط

أجريت هذه الدراسة لتقييم تأثير بعض أمراض الكبد على نمط التحليل الكهربائي لبروتينات مصلى الدم باستخدام أسيتات السليولوز فى الماعز.

تم تجميع ٢٤ عينة دم من ذكور الماعز (عمر ١٠-١٢ شهر) قبل الذبح عليها اعراض ضعف عام وهزال شديد واوديميا فى بعض الحالات وقسمت طبقا لإصابات الكبد بعد الذبح إلى ٣ مجموعات بالإضافة إلى ١٠ عينات دم تم أخذها من ذكور الماعز مطابقة فى العمر كمجموعة ضابطة.

المجموعة الاولى : مكونة من ١٠ ماعز وكانت تعاني من فى التهاب القنوات المرارية المزمن تليف جزئى فى القنوات المرارية وتضخم فى الحويصلة المرارية. أظهرت النتائج التحاليل زيادة فى كل من البروتين الكلى و بيوتا جلوبيولين و الجلوبيولين الكلى . كما أوضحت النتائج نقص فى منطقة الألبومين و فى نسبة الألبومين الى الجلوبيولين .

المجموعة الثانية : مكونة من ٧ ماعز وكانت تعاني من خراج الكبد مختلفة الأحجام ومحاطة بمناطق نزفية . . أظهرت نتائج التحليل الكهربائي زيادة فى الفا وبيتا وجاما جلوبيولين و الجلوبيولين الكلى، و نقص فى نسبة الألبومين الى الجلوبيولين .

المجموعة الثالثة : مكونة من ٧ ماعز وكانت تعاني من تليف الكبد حيث كان لون الكبد شاحبا ، وجود التليف نتج عنه عدم انتظام سطح الكبد بالإضافة الى تضخم وتليف الحويصلة المرارية . أظهرت نتائج التحليل الكهربائي زيادة فى الجلوبيولين الكلى . كما أوضحت النتائج نقص فى قيم البروتين الكلى و الألبومين و الفا وبيتا جلوبيولين و فى نسبة الألبومين الى الجلوبيولين .

يمكن أن نستنتج أن نمط التحليل الكهربائي لبروتينات مصلى الدم تختلف باختلاف نوع المرض فى الكبد. أيضا إمكانية استخدام قيم كل من الألفا وبيتا جلوبيولين كقيم تشخيصية ومنذرة. فالحيوانات التي يكون بها الكبد قادرا على تخليق بروتينات ألفا وبيتا توحى بتنبؤات حسنة كما فى حالات التهاب القنوات المرارية المزمن أو خراج الكبد ومن ناحية أخرى فإن الحيوانات التي بها نقص فى الألبومين والألفا وبيتا جلوبيولين فأنها توحى بتنبؤات سيئة كما فى حالات تليف الكبد .