

Journal of Food and Dairy Sciences

Journal homepage: www.jfds.mans.edu.eg
Available online at: www.jfds.journals.ekb.eg

Protective Effect of Selenium Nanoparticles against Acrylamide-Induced Hepatotoxicity in Albino Rats

Ghada Khiralla*



National Organization for Drug Control and Research (NODCAR), 6-7, AboHazem Street, Pyramids, PO Box 29, Giza, Egypt



ABSTRACT

Selenium nanoparticles have received wide attention due to their importance in nutrition compared to other forms of selenium used in food fortification. In the present study, chitosan-stabilized selenium nanoparticles (Ch-SeNPs) were prepared, characterized and evaluated for their hepatoprotective effect against acrylamide-induced hepatotoxicity in albino rats. According to TEM and Zetasizer analysis, the size of Ch-SeNPs produced in the present study were ranged from 18 to 55 nm with average of 22 nm. Acrylamide treatment led to elevation of the studied biochemical parameters of liver including total protein, albumin, globulin, alkaline phosphatase, aspartate aminotransferase and alanine aminotransferase. Intake of Ch-SeNPs either 15 days prior to or simultaneously with the treatment with acrylamide led to enhance the biochemical parameters to be near the normal range. Same trend was obtained when rats were fed on sodium selenite, but Ch-SeNPs were more closely related to control group (untreated). The histopathological structure examination of rat liver emphasized the obtained biochemical results. The obtained results confirmed that, the intake of Ch-SeNPs 15 days before treatment by acrylamide had significant (< 0.05) protective effect against liver injury compared to the intake of these nanoparticles along with acrylamide.

Keywords: Selenium nanoparticles, Sodium selenite, Hepatotoxicity, acrylamide

INTRODUCTION

Selenium is an essential trace element of many biological systems including enzymatic reactions. Because of its protective potential against the reactive oxygen species (RSO), selenium has an important role for reducing chronic disease risks such as cancer neurodegenerative disease and hepatotoxicity (Khan *et al.*, 2012; Teodor *et al.*, 2011). Moreover, several studies have demonstrated that selenium play an important role for improving the clinical symptoms of many diseases such as hypertension, coronary heart disease and hepatitis B and C (Ju *et al.*, 2017; Peresadina *et al.*, 2004; Zeng and Combs, 2008). Since the 1950s, the important nutritional role of selenium has been known for organisms, especially in plant and animal nutrition. Moreover, selenium intake has been reported to improve lipid metabolism, anticoagulation and antioxidant status (Peresadina *et al.*, 2004; Teodor *et al.*, 2011). Selenium, being an essential element of enzyme like glutathione peroxidase (GPx) and other seleno-chemical compounds, can improve the chemotherapeutic potential by working as a functional group of redox center and protecting the tissues from cellular damage by ROS (Menon *et al.*, 2018). On the other hand, Zhang *et al.* (2010) had mentioned that, at least one third of the 25 selenium proteins in humans display antioxidant activity, but it is also known that selenium metabolites accelerate the types of ROS. Symptoms of selenium toxicity (called selenosis) include gastrointestinal disorders, alopecia, fatigue, and irritability. These symptoms appear at doses of about 2,400 μg / day (Navarro-Alarcon and Cabrera-Vique, 2008).

Due to the high toxicity of the selenium element, the zero-oxidation state (Se⁰) is of great interest because of its low toxicity and high availability (Zhai *et al.*, 2017). At

present, Se⁰ nanoparticles (SeNPs) are of great importance in the field of medicine because of their promising properties and excellent bioactivities, where they showed substantial impact as anticancer, non-toxic and biocompatible operators compared to the other selenium forms such as selenite (SeO₃-2) and selenate (SeO₄-2) compounds (Menon *et al.*, 2018). Protective effect of SeNPs against cyclophosphamide induced hepatotoxicity and genotoxicity in Swiss albino mice have been previously demonstrated (Bhattacharjee *et al.*, 2014). Since SeNPs are unstable and rapidly becoming inactive, great efforts have been conducted to ensure the stability of SeNPs using chitosan with different molecular weight. In this respect, selenite has been successfully encapsulated into chitosan/triphosphate nanoparticles, which displayed improved antioxidant activities *in vitro* (Luo *et al.*, 2010). Also, selenium has been encapsulated in chitosan nanoparticles to improve selenium availability and protects animal cells from selenium-induced DNA damage response (Zhang *et al.*, 2011). Moreover, the chitosan-stabilized SeNPs displayed a lower toxicity, enhanced antioxidant capacities during 30-day storage and perform their antioxidant effects in mice models (Zhai *et al.*, 2017). Moreover, Bai *et al.* (2017) demonstrated the protection effect of selenium nanoparticles-loaded chitosan/citrate complex against oxidative stress and hepatotoxicity in d-gal-induced liver injury.

Several studies have indicated the intensive presence of acrylamide (ACR) in foods exposed to high temperatures, particularly starchy foods such as potatoes, cereals and bakery products (Riboldi *et al.*, 2014; Surdyk *et al.*, 2004; Tareke *et al.*, 2002). ACR is well-known neurotoxicant that induced several biochemical, hematological, and behavioral alterations experimental animals (Lebda *et al.*, 2015). Several efforts have been made to reduce the negative

* Corresponding author.
E-mail address: gkhiralla@yahoo.com
DOI: 10.21608/jfds.2019.60768

effects of acrylamide in foods by reducing acrylamide formation during food processing and/or by using certain food additives (Krishnakumar and Visvanathan, 2014; Lebda *et al.*, 2015). Therefore, the present study was designed to investigate the ameliorative effect of chitosan-stabilized SeNPs on hepatotoxicity of acrylamide in the experimental albino rats.

MATERIAL AND METHODS

Materials

Chemicals

All chemicals were purchased from Sigma-Aldrich, Germany. The diagnostic biochemical kits were obtained from Bio Diagnostic Company, Al-Dokki, Giza, Egypt.

Methods

Synthesis of chitosan-stabilized selenium nanoparticles

Chitosan-stabilized selenium nanoparticles (Ch-SeNPs) were prepared according to the method described by Bai *et al.* (2008). Briefly, an aqueous chitosan acrylamide solution was prepared at a concentration of 0.5% (w/v). Ten milliliters of this solution were mixed with 7.5 mL of ascorbic acid (0.23 M) and 5 mL of acetic acid (2.4 M); then, 0.25 mL of sodium selenite (0.51 M) was slowly added into the mixture. During the reaction, the change in the color of the mixture from colorless to reddish-orange indicates the formation of selenium nanoparticles. Finally, the solution was diluted to 50 mL using distilled water to obtain a final concentration of 200 mg/L of Ch-SeNPs.

Characterization of Ch-SeNPs

The formation of Ch-SeNPs was primary observed by visual examination of the solution in the test-tubes for color changes. For determining size and morphology of Ch-SeNPs, Transmission Electron Microscopic (TEM) analysis Ch-SeNPs was carried out at an accelerating voltage of 200 kV (Techni 20, Philips, Holland). The size distribution of the dispersed particles was measured using a Zetasizer Nano ZS7.11 (Malvern Instruments Ltd., Malvern, UK). Ch-SeNPs were dispersed in deionized water and mixed thoroughly via vortexing and sonication. Samples were measured at 25 µg/mL (Khiralla and El-Deeb, 2015).

Animals and Treatments

Thirty-six adult male rats (120 - 150 ± 5 g, 10 weeks of age) were obtained from the National Organization for Drug Control and Research (NODCAR), Giza, Egypt. Rats were housed in separate stainless-steel cages under controlled conditions at constant temperature (24 °C). After acclimation period (15 days) rats were divided into six groups ($n=6$) and fed on basal diet (10 % casein, 10 % corn oil, 5% cellulose, 1 % vitamin mixture, 4 % salt mixture, 70% corn starch (Lana Peter and Pearson, 1971) during the experimental period. All treatments were given orally using stomach tube.

Untreated group (G1); fed on basal diet and given 1 mL distilled water/ day during the experimental period. Acrylamide treated group (G2,); treated with acrylamide only at a dose of 20 mg/ Kg b.w. selenium- acrylamide jointly treated group (G3); treated with selenium selenite and acrylamide solutions simultaneously at a dose of 20 µg/ Kg b.w. and 20 mg/ Kg b.w., respectively during the experimental period. Sodium selenite pretreated group (G4); treated with selenium selenite at dose of 20 µg/ Kg b.w. for 15 days prior to acrylamide treatment and then continued along with acrylamide (20 mg/ Kg b.w.) for 30 days. Ch-SeNPs acrylamide jointly treated group (G5); treated with

Ch-SeNPs and acrylamide were simultaneously at a dose of 0.2 and 20 mg/ Kg b.w., respectively. Ch-SeNPs pretreated group (G6); treated with Ch-SeNPs at dose of 0.2 mg / Kg b.w. for 15 days prior to acrylamide treatment and then continued along with acrylamide (20 mg/ Kg b.w.) for 30 days.

Serum biochemical parameters

Blood serum samples were collected in clean centrifuge tubes. Samples were collected from the eye plexuses of the animals at the beginning and end of the experimental period by fine capillary glass tubes. The serum was separated after centrifugation for 10 minutes at 3000 rpm (1500 xg) and kept at -20 ° C until analysis (Young, 1995). The biochemical parameters including total protein (TP), albumin, alkaline phosphatase (ALP), alanine aminotransferase (ALT; EC 2.6.1.2) and aspartate aminotransferase (AST; EC 2.6.1.1) were estimated by test reagent kits (Biodiagnostics, Egypt).

Histopathological Assessment

After the autopsy of rats, liver samples were taken from different groups and then fixed in a 10% normal saline solution for 24 hours. The stabilized samples were washed in tap water and then dehydrated in serial dilutions of alcohol (methyl, ethyl and absolute ethyl). Specimens were cleared in xylene and embedded in paraffin at 56 °C in hot air oven for 24 h. Paraffin was poured onto the samples to form blocks, which are dried, then placed at 56 ° C in a hot air oven for 24 hours. The blocks are cut into slices 4 microns thick by sledge microtome. The obtained tissue sections were collected on glass slides, deparaffinized, stained by hematoxylin & eosin stain for routine examination through the light electric microscope (Banchroft *et al.*, 1996).

Statistical Analysis

All biochemical parameters collected from six animals ($n= 6$) were presented as mean values ± SD. Data were analyzed with SAS software (SAS Institute, Cary, N.C.) using SAS analysis of variance (PROC ANOVA). Significant differences between means were determined by Tukey's multiple range test ($P = 0.05$).

RESULTS AND DISCUSSION

Characterization of Chitosan stabilized selenium nanoparticles

The change in color is one of the visual signs of the formation of nanoparticles in the chemical solutions. As shown in Fig. 1.




Fig. 1. The visualization of colour changes as a result of Ch-SeNPs formation.

A color change from colorless to orange-red of elemental selenium (Se⁰) was demonstrated in the tube 1.

However, tube 2 displayed the colorless solution before preparing nanoparticles. This notice has been confirmed previously by Khiralla and El-Deeb(2015), where they mentioned that the first signs of nanoparticles formation being the transformation of the solution from transparent to red.

As shown in TME, the Ch-SeNPs prepared in the present work were spherical and monodispersed with diameter average of 18-55 nm (Fig. 2, A). The dynamic light scattering (DLS) results indicated that all the particles are nano-sized with average diameters of 22 nm (Fig. 2, B), (Zare *et al.*, 2013).

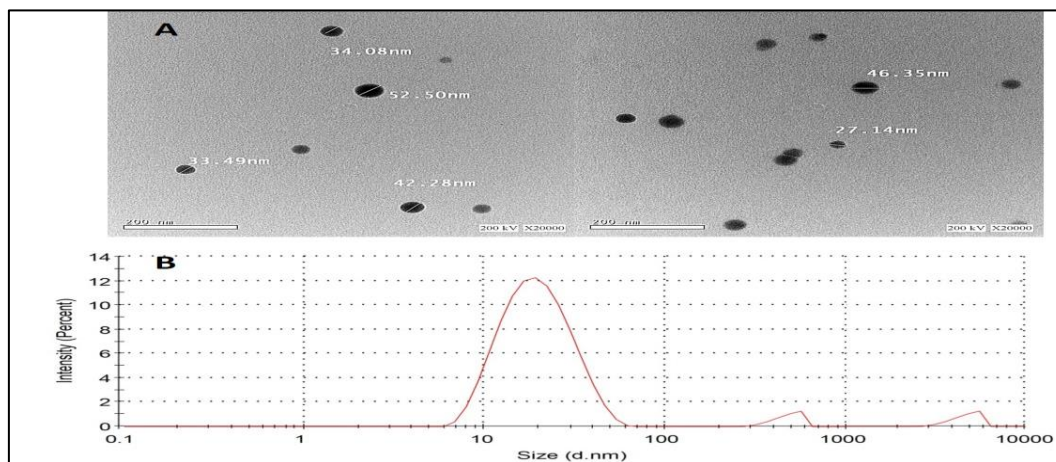


Fig. 2. Size distribution analysis by dynamic light scattering (DLS) and shape of Ch-SeNPs as shown by TEM (A) and Zetasizer (B).

Biological evaluation of hepatoprotective effect of Ch-SeNPs

Biochemical Assay

There was a significant decrease in total protein as a result of the treatment of acrylamide where the recorded total protein reduced from 7.4 to 4.8 g/dL. Moreover, the decrease in globulin was more than the decrease in albumin, which led to an increase in the ratio of albumin to globulin (A/G ratio) due to the treatment of rats with acrylamide (Table 1). There was an improvement in the values of total protein, albumin and globulin as a result of the intake of selenium or nanoparticles in the diet of rats.

Table 1. Total protein, Albumin, globulin* and A.G (g/dL) of male albino rat serum fed on different selenium and nano- selenium solutions

Rat Group	Total protein	Albumin	Globulin	A/G Ratio
G1	7.4±0.4 ^a	4.5±0.2 ^a	2.9±0.2 ^a	1.5±0.1 ^b
G2	4.8±0.6 ^c	2.9±0.1 ^b	1.9±0.2 ^b	2.0±0.1 ^a
G3	7.1±0.5 ^a	3.8±0.1 ^a	3.3±0.1 ^a	1.2±0.2 ^b
G4	7.2±0.5 ^a	4.2±0.3 ^a	3.0±0.1 ^a	1.4±0.1 ^b
G5	6.1±0.3 ^b	3.9±0.1 ^a	2.2±0.1 ^a	1.7±0.1 ^a
G6	7.2±0.2 ^a	4.6±0.2 ^a	2.6±0.1 ^a	1.8±0.2 ^a
Normal range**	5.2-7.1	3.4-4.8	1.5-2.5	

* Data were represented as mean ±SD. G1: Positive control fed on basil diet only, G2: Negative control fed on basil diet and acrylamide, G3: fed on Se solution and acrylamide simultaneously, G4: fed on Se Solution 15 days prior to acrylamide treatment and then continued along with acrylamide for 30 days. G5: fed on Ch-SeNPs and acrylamide simultaneously, G6:- fed on Ch-SeNPs. 15 days prior to acrylamide treatment and then continued along with acrylamide for 30 days.

** Normal range of biochemical parameters in rats according to Giknis and Clifford (2008)

The total protein and albumin values returned to normal range in rats of all groups except group G2, which was treated with acrylamide only. The best group that approached the control group at the end of the experiment was the group treated with nano-selenium 15 days prior to the start of acrylamide treatment. Zhang *et al.* (2011) mention in their recommendations that, selenium nanoparticles have a

significant effect in reducing toxicity on living cells and thus improve the performance of cell functions.

Serum liver functions, including ALT, AST and ALP, of male albino rats fed on different selenium selenite and Ch-SeNPs solutions were presented in Table 2.

Table 2. Serum liver function* of male albino rats fed on different selenium and nano- selenium solutions

Rat Group	ALT (U/ml)	AST (U/ml)	ALP (IU/L)
G1	40 ±4 ^d	123 ±9 ^d	120 ±3 ^d
G2	87 ±4 ^a	201 ±12 ^a	190 ±6 ^a
G3	68 ±5 ^b	162 ±10 ^b	160 ±2 ^b
G4	51 ±6 ^c	139 ±8 ^c	146 ±4 ^c
G5	64 ±3 ^b	161 ±9 ^b	160 ±6 ^b
G6	44 ±3 ^d	132 ±7 ^c	124 ±4 ^d
Normal range**	18 - 45	74 - 143	62 - 230

* Data were represented as mean ±SD. G1: Positive control fed on basil diet only, G2: Negative control fed on basil diet and acrylamide, G3: fed on Se solution and acrylamide simultaneously, G4: fed on Se Solution 15 days prior to acrylamide treatment and then continued along with acrylamide for 30 days. G5: fed on Ch-SeNPs and acrylamide simultaneously, G6:- fed on Ch-SeNPs. 15 days prior to acrylamide treatment and then continued along with acrylamide for 30 days.

** Normal range of biochemical parameters in rats according to Giknis and Clifford (2008)

All tested parameters of the control group (G1) were in the normal range of rats. An increase in these parameters was recorded as a result of the acrylamide treatment (G2). There was significant improvement in the ALT, AST and ALP values when rats were treated with selenium selenite or Ch-SeNPs simultaneously with acrylamide (G3 and G5, respectively). Further reduction in liver functions was detected in G4 and G6 due to pretreatment 15 days before acrylamide treatment with selenium selenite or Ch-SeNPs, respectively. The treatment of rats with Ch-SeNPs prior to acrylamide (G6) could be considered as the best treatment for maintaining the ALT, AST and ALP values to be near the control rats (G1) and in the normal range of rats (Table 2). In this respect, Wang *et al.* (2013) study showed improved liver properties using

nanoparticles to reduce liver enzyme loss in the hepatic cytoplasm into the blood and reach normal levels of enzymes in the blood.

Histopathological Assessment

The prepared Ch-SeNPs were biologically evaluated for its protective effect against acrylamide induced liver diseases. Optical micrographs of rate livers fed on Ch-SeNPs or selenium selenite were presented in Fig. 3. Rats in control group (G1) demonstrated normal histological structures of hepatic tissue including central veins (White closed arrow), portal tracts (White open arrow), sinusoids and apparent intact hepatocytes. Treatment with acrylamide (G2) led to pericentral vacuolar degeneration of hepatocytes (Black closed arrow) with

many hepatocytes showing pyknotic nuclei, many dilated and congested blood vessels (star) and periportal inflammatory cells infiltration (Black open arrow).

Selenium- acrylamide jointly treated group (G3) showed periportal inflammatory cells infiltrations (Black open arrow), many activated kupffer cells and lymphocytic infiltrations (dashed arrow), few scattered degenerated hepatocytes were observed (black arrow). Selenium selenite pretreated group (G4) showed diffuse vacuolar degeneration of hepatocytes with pyknotic nuclei (arrow), mild periportal inflammatory cells infiltrations were recorded (Black open arrow). On the other hand, Ch-SeNPs- acrylamide jointly treated group (G5) demonstrated many congested, dilated blood vessels (star).

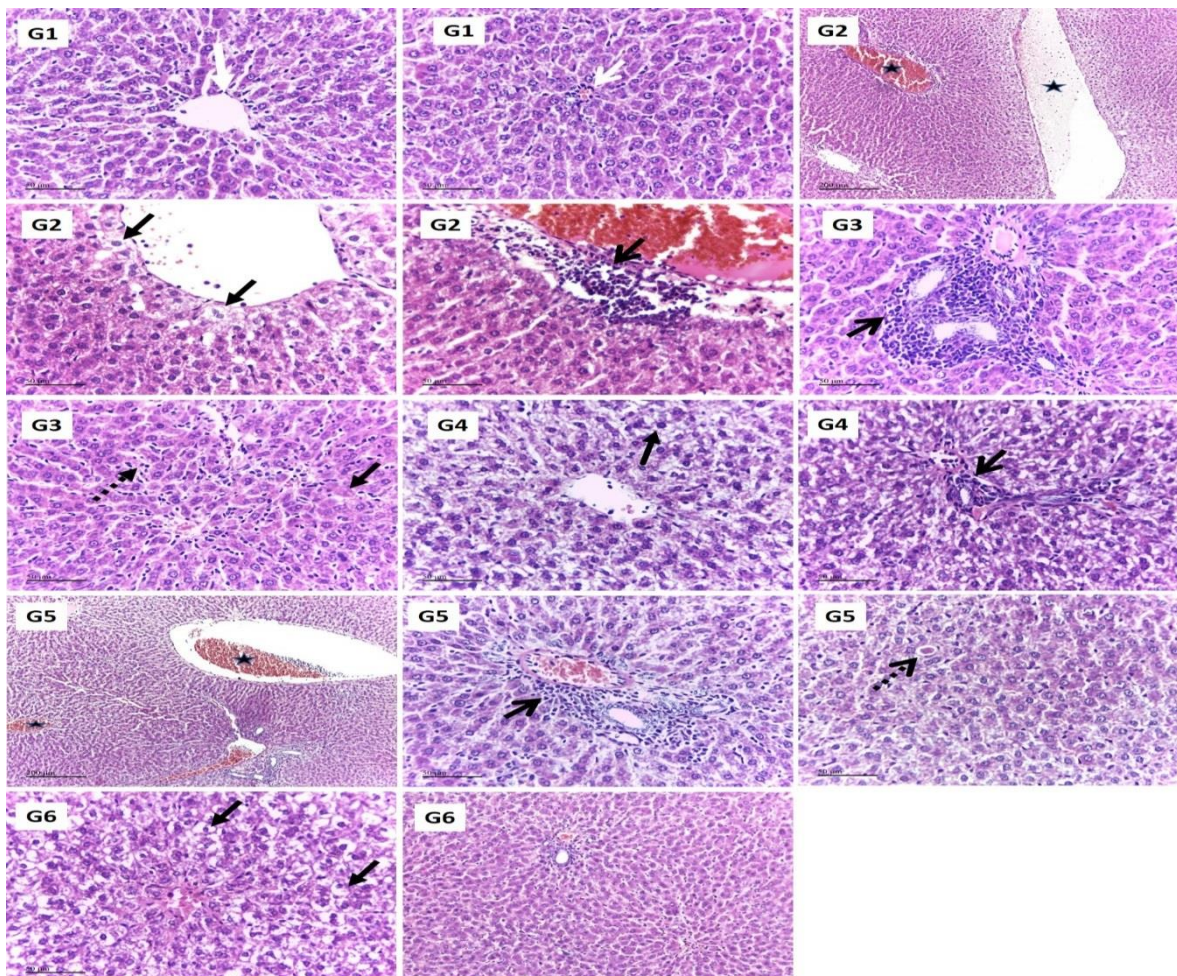


Fig. 3. The representative histological photomicrographs of the liver fed on Ch-SeNPs or selenium selenite. H&A stain 300x magnification.

Mild periportal inflammatory cells infiltrations (Black open arrow). Many activated kupffer cells (dashed arrow), scattered hepatocytes showed necrobiotic changes and single cell apoptosis (dashed open arrow). Ch-SeNPs pretreated group (G6) showed histological structures near to the appearance of the normal hepatic tissue. However, diffuse vacuolar degeneration of hepatocytes with pyknotic nuclei (arrow) with more extensive lesion were observed in pericentral zones.

In general, the obtained histological examination affirms that treatment with sodium selenite cannot completely prevent hepatotoxicity in experimental rats. On the other hand, treatment with Ch-SeNPs has resulted in significant liver protection, especially when it was

administered to rats for 15 days prior to acrylamide treatment. This finding could be explain by those mention by (Bhattacharjee et al., 2014), who indicated that, pretreatment with nano selenium leads to the maintenance of liver cell membranes and protection from oxidative stress.

CONCLUSION

Selenite in the form of sodium selenite was confirmed as a trace element for protecting rats from liver diseases induced by acrylamide. Chitosan-stabilized selenium nanoparticles (Ch-SeNPs) showed hepatoprotective effect better than those of sodium selenite.

Pretreatment of rats with Ch-SeNPs 15 days prior to induce liver injury using acrylamide led to improve the protective potential of the produced nanoparticles.

REFERENCES

- Bai, K., Hong, B., Hong, Z., Sun, J., and Wang, C. (2017). Selenium nanoparticles-loaded chitosan/citrate complex and its protection against oxidative stress in D-galactose-induced aging mice. *Journal of nanobiotechnology*, 15(1), 92-92.
- Bai, Y., Wang, Y., Zhou, Y., Li, W., and Zheng, W. (2008). Modification and modulation of saccharides on elemental selenium nanoparticles in liquid phase. *Materials Letters*, 62(15), 2311-2314.
- Banchroft, J. D., Stevens, A., and Turner, D. R. (1996). *Theory and practice of histological techniques*: Churchill Livingstone, New York, London, San Francisco, Tokyo.
- Bhattacharjee, A., Basu, A., Ghosh, P., Biswas, J., and Bhattacharya, S. (2014). Protective effect of Selenium nanoparticle against cyclophosphamide induced hepatotoxicity and genotoxicity in Swiss albino mice. *J Biomater Appl*, 29(2), 303-317.
- Giknis, M., and Clifford, C. (2008). *Clinical laboratory parameters for Crl: Wi(Han) rats* Wilmington, MA
- Ju, W., Li, X., Li, Z., Wu, G. R., Fu, X. F., Yang, X. M., Zhang, X. Q., and Gao, X. B. (2017). The effect of selenium supplementation on coronary heart disease: A systematic review and meta-analysis of randomized controlled trials. *J Trace Elem Med Biol*, 44, 8-16.
- Khan, M. S., Dilawar, S., Ali, I., and Rauf, N. (2012). The possible role of selenium concentration in hepatitis B and C patients. *Saudi journal of gastroenterology : official journal of the Saudi Gastroenterology Association*, 18(2), 106-110.
- Khiralla, G. M., and El-Deeb, B. A. (2015). Antimicrobial and antibiofilm effects of selenium nanoparticles on some foodborne pathogens. *LWT - Food Science and Technology*, 63(2), 1001-1007.
- Krishnakumar, T., and Visvanathan, R. (2014). Acrylamide in Food Products: A Review. *J Food Process Technol* 5, 344.
- Lana Peter, W., and Pearson, A. G. (1971). *Dietary Requirement in Laboratory Animals and Practice*: Academic Press, London and New York.
- Lebda, M. A., Gad, S. B., and Rashed, R. R. (2015). The effect of lipoic acid on acrylamide-induced neuropathy in rats with reference to biochemical, hematological, and behavioral alterations. *Pharm Biol*, 53(8), 1207-1213.
- Luo, Y., Zhang, B., Cheng, W.-H., and Wang, Q. (2010). Preparation, characterization and evaluation of selenium-loaded chitosan/TPP nanoparticles with or without zein coating. *Carbohydrate Polymers*, 82(3), 942-951.
- Menon, S., Ks, S. D., R, S., S, R., and S, V. K. (2018). Selenium nanoparticles: A potent chemotherapeutic agent and an elucidation of its mechanism. *Colloids and Surfaces B: Biointerfaces*, 170, 280-292.
- Navarro-Alarcon, M., and Cabrera-Vique, C. (2008). Selenium in food and the human body: a review. *Sci Total Environ*, 400(1-3), 115-141.
- Peresadina, V. R., Dmitrievskaia, M. N., Mal'tsev, G., Pogozheva, A. V., and Vasil'ev, A. V. (2004). [The use of nutritional antioxidants for the correction of metabolic disorders of cardiovascular patients]. *Vopr Pitan*, 73(3), 3-6.
- Riboldi, B. P., Vinhas, Á. M., and Moreira, J. D. (2014). Risks of dietary acrylamide exposure: A systematic review. *Food Chemistry*, 157, 310-322.
- Surdyk, N., Rosén, J., Andersson, R., and Åman, P. (2004). Effects of Asparagine, Fructose, and Baking Conditions on Acrylamide Content in Yeast-Leavened Wheat Bread. *Journal of Agricultural and Food Chemistry*, 52(7), 2047-2051.
- Tareke, E., Rydberg, P., Karlsson, P., Eriksson, S., and Tomqvist, M. (2002). Analysis of acrylamide, a carcinogen formed in heated foodstuffs. *J Agric Food Chem*, 50(17), 4998-5006.
- Teodor, V., Cuciureanu, M., Filip, C., Zamosteanu, N., and Cuciureanu, R. (2011). Protective effects of selenium on acrylamide toxicity in the liver of the rat. Effects on the oxidative stress. *Rev Med Chir Soc Med Nat Iasi*, 115(2), 612-618.
- Wang, Y., Chen, Z., Ba, T., Pu, J., Chen, T., Song, Y., Gu, Y., Qian, Q., Xu, Y., Xiang, K., Wang, H., and Jia, G. (2013). Susceptibility of young and adult rats to the oral toxicity of titanium dioxide nanoparticles. *Small*, 9(9-10), 1742-1752.
- Young, D. S. (1995). *Effects of Drugs on Clinical Laboratory Test* (4 ed.). AACCC Press, Washington.
- Zare, B., Babaie, S., Setayesh, N., and Shahverdi, A. R. (2013). Isolation and characterization of a fungus for extracellular synthesis of small selenium nanoparticles. *Nanomedicine Journal*, 1(1), 13-19.
- Zeng, H., and Combs, G. F. (2008). Selenium as an anticancer nutrient: roles in cell proliferation and tumor cell invasion. *The Journal of Nutritional Biochemistry*, 19(1), 1-7.
- Zhai, X., Zhang, C., Zhao, G., Stoll, S., Ren, F., and Leng, X. (2017). Antioxidant capacities of the selenium nanoparticles stabilized by chitosan. *Journal of Nanobiotechnology*, 15(1), 4.
- Zhang, S., Luo, Y., Zeng, H., Wang, Q., Tian, F., Song, J., and Cheng, W. H. (2011). Encapsulation of selenium in chitosan nanoparticles improves selenium availability and protects cells from selenium-induced DNA damage response. *J Nutr Biochem*, 22(12), 1137-1142.
- Zhang, S., Rocourt, C., and Cheng, W. H. (2010). Selenoproteins and the aging brain. *Mech Ageing Dev*, 131(4), 253-260.

التأثير الوقائي لجزيئات نانو السيلينيوم ضد السمية الكبدية المستحثة بالاكريلاميد في جرزان التجارب عادة محمود خير الله الهيئة القومية للرقابة والبحوث الدوائية

تعتبر جزيئات نانو السيلينيوم أفضل من جزيئات السليوم وذلك في تدعيم الاغذية . وقد تم في هذه الدراسة تحضير وتوصيف جزيئات نانو السيلينيوم وكذلك تقييم قدرتها علي تقليل التأثير الضار للمعاملة بالاكريلاميد علي وظائف الكبد في جرزان التجارب. تراوحت حجم جزيئات نانو السيلينيوم المحضرة بين ١٨ - ٥٥ نانومتر بمتوسط حجم ٢٢ نانومتر وذلك باستخدام أجهزة TEM, Zetasizer. أنت المعاملة بالاكريلاميد الي رفع القياسات البيوكيميائية الخاصة بالكبد وهي البروتين الكلي - الالبيومين - الجلوبيولين - الفوسفاتيد القلوي - ALT - AST . وادي إعطاء جزيئات نانو السيلينيوم المحملة علي الشيتوزان لمدة ١٥ يوم قبل المعاملة بالاكريلاميد وكذلك إعطاء جزيئات نانو السيلينيوم المحملة علي الشيتوزان بالتزامن مع المعاملة بالاكريلاميد الي تحسين الخصائص البيوكيميائية محل الدراسة واقترب قيمتها من القياسات الطبيعية وذلك عند مقارنة هذه المجموعات بالمجموعة المعطاة جزيئات السيلينيوم. حيث كانت نتائج المجموعة المعطاة جزيئات نانو السيلينيوم المحملة علي الشيتوزان اقرب الي المجموعة الضابطة (غير المعاملة بالاكريلاميد) مقارنة بالمجموعة المعاملة بجزيئات السيلينيوم. اتفقت نتائج الهستولوجي لانسجة الكبد مع نتائج

Ghada Khiralla

الخصائص البيوكيميائية محل الدراسة. وقد أظهرت المجموعة التي أعطت جزيئات نانو السلينيوم المحملة علي الشيتوزان قبل المعاملة بالاكريلاميد ب ١٥ يوم نتائج افضل في الهستولوجي وذلك عند مقارنتها بالمجموعة التي أعطت جزيئات نانو السلينيوم المحملة علي الشيتوزان بالتزامن مع المعاملة بالاكريلاميد.