

## EVALUATION OF PROPELLER PERFORATOR FLAPS IN LEG RECONSTRUCTION

By

**Abd El Monem Hussain Hota, Ahmed Sabry Ahmed Hassan,  
Samy Abd El Sattar Eleowa, Essam Ali Mohammed Taman,  
Moustafa Sayed Ahmed Meki  
and Mohammed Swilem Mohammed Ibrahim**

Department of Plastic Surgery, Al-Azhar Faculty of Medicine

### ABSTRACT

**Background:** Reconstruction of defects in the leg with exposed tendons, bone, and/or other tissues continues to be challenging and they generally need flap coverage. Evolution in flap surgery has enabled fasciocutaneous, adipofascial and superthin flaps to be harvested for the purpose of reconstruction, thereby minimizing morbidity from muscle inclusion into the flap.

**Objective:** A prospective study for patients of 6-54 years old with leg defects and evaluation of perforator (propeller) flaps for reconstruction of defects in the leg.

**Patients and methods:** This study includes twenty patients with leg defects who came to Al Azhar University Hospitals asking for leg reconstruction during the period from Oct 2014 to Sep 2016. All patients were operated under spinal anesthesia. Perforators were identified and traced to major limb vessel, and skin paddle was designed around the perforator. Skin paddle was then rotated into the defect of the leg.

**Results:** All the patients tolerated the procedure well. There was only one case of epidermal loss and one case had partial loss. Two flaps initially underwent distal congestion but, however, improved on day three post-operatively. One case developed bleeding postoperatively and controlled and one case had delayed wound healing. However, the remainder of the flaps survived and wound healed completely.

**Conclusion:** The use of propeller flaps to cover defects of the leg showed satisfactory results as regards flap viability and providing a suitable coverage of various defects.

**Key words:** Perforator flaps, leg reconstruction.

### INTRODUCTION

The axial pattern flaps based on axial blood supply, improve the quality of results, but with the sacrifice of a main artery (**Koshima et al., 2003**)

The term of propeller perforator flap, was used by **Hallock (2006)** for the first time to define a perforator flap based on a skeletonized perforator vessel and rotated 180 degrees.

The ultimate definition and terminology of propeller perforator flaps was adopted by an Advisory Panel of the First Tokyo Meeting on Perforator and Propeller Flaps (**Pignatti et al., 2011**)

According to this consensus, a propeller perforator flap is designed as a skin island with two paddles which can be of the same dimensions or with a larger and a

smaller one, the demarcation limit between them being the perforator vessel. To be a propeller flap, it has to rotate around the perforator vessel for at least 90 to 180 degrees (**Ramesh et al., 2013**)

The aim of the present work was to evaluate the reconstruction of the defect in the leg by flaps.

## PATIENTS AND METHODS

This study includes twenty patients with leg defects who came to Al- Azhar University Hospitals asking for leg reconstruction in the period from Oct 2014 to Sep 2016. Full history, local and general examination and complete investigations were applied for the patients.

Patient counseling by explanation for the patient the nature of surgery, postoperative care and possible complication, written consents and photography were done.

Perforators were marked preoperatively with an 8 MHz hand held Doppler device. Perforator vessels were identified by its unidirectional pulsatile flow. The ideal perforator as pivot point was chosen according to the larger and nearer to the defect.

The flap was able to be rotated in a clockwise or counter-clockwise direction, function of the angle between the proximal long axis of the flap and the defect, and attention was paid to choose the right rotational direction to avoid kinking of the vessels. The donor site did not be closed under tension to avoid compressing the source vessel, and swelling of the distal leg.

Dressing was provided with an open window to observe the flap, especially the flap-tip. A below knee-to-toe plaster-of-paris or back-slab was applied, if there has been a skin graft applied directly to the muscle of the proximal leg or if it was necessary to keep pressure off the flap.

This usually was applied to the peroneal based flap used to cover defects on the lateral malleolus. The patient's leg is kept slightly elevated on one pillow, and a bed cradle was used to decrease the edema, venous congestion and keep any heavy blankets from putting pressure on the injured leg.

**Statistical analysis:** Data management and analysis were performed using Statistical Package for Social Sciences (SPSS) version 21. All results were expressed as means  $\pm$  standard deviation. Significance was considered at  $P < 0.05$ .

## RESULTS

Twenty patients with different sites of leg defects were the subject of this study with age 6-54 mean  $32.8 \pm 17.33$  SD, intraoperative time 2.5-5 hours (mean)  $3.75 \pm 1.32$ , defect size  $4 \times 2.5$ - $20 \times 12$  (mean)  $9.55 \times 6.37 \pm 4.01 \times 2.66$  and flap size  $8 \times 5$ - $32 \times 15$  (mean)  $13.60 \times 8.25 \pm 5.63 \times 2.88$  as in table (1). 10 cases out of 20 were flaps based on the perforators of the posterior tibial artery, 3 flaps were based on perforators of the anterior tibial artery and 7 flaps were based on perforators of the peroneal artery as in Fig (2).

All flaps were designed as propeller flaps that were rotated from  $90^\circ$  to  $180^\circ$ . The donor site was closed by split thickness grafts in 16 (80%) cases and 2 (10%) cases in which the donor site was

partially primarily closed with the rest grafted and 2 (10%) flaps was completely primarily closed. Out of the 20 flaps, 14 (70%) healed uneventfully, 6 (30%) cases were complicated as in table (2).

Out of the 10 flaps based on PTA, 7 cases (70%) healed uneventfully, 3 (30%) cases were complicated, out of the 7 flaps based on PA, 5 cases (71.5%) healed uneventfully, 2 (28.5%) cases were complicated and out of the 3 flaps based on ATA, 2 cases (66.6%) healed uneventfully, 1 (33.3%) cases were complicated.

One case (5%) had loss of the distal 2 cm of the flap, but no further surgical intervention was necessary except advancement. Another one case had superficial sloughing with healthy granulation tissue underneath that was covered after 3 weeks by split thickness skin graft.

Two cases (10%) had congestion in the 1<sup>st</sup> six hours postoperative they had to be reset and left insito for ten days then propelled to the defect again. There is one case (5%) that had bleeding postoperative and entered the operating theater again to control the bleeding with no further necessary intervention. There is also one flap (5%) that had delayed healing which had done after 3 weeks beside one flap that had wound dehiscence which needed to be sutured again after four weeks

According to the site of defect, 14 (70%) came with lower 1/3 defect, 4 (20%) came with middle 1/3 and 2 (10%) came with upper 1/3 as in Fig (3).

Male to Female were 15 (75%):5 (25%).

Regarding the etiology Road Traffic Accidents was 17 (85%), Post Burn Ulcers was 2 (10%) and Chronic Non Healing Ulcers was 1 (5%) as in Fig (1).

**Table (1):** Range and average for each of age, intra-operative time defect and flap sizes.

Item	Range	mean	SD
Age (years)	6-54	32.8	13.77
Intra-operative time (hours)	2.5- 5	3.75	1.32
Defect size (cm)	4x2.5-20x12	9.55x6.37	4.01x2.66
Flap size (cm)	8x5-32x15	13.60x8.25	5.63x2.88

Data were presented as mean, SD or number (%) by SPSS.

**Table (2):** Donor site closure and complications

Donor site		n=20 (%)
Donor site closure	grafted	1 (80)
	Partial 1ry closed+grafting	2 (10)
	complete 1ry closed	2 (10)
Donor site complication	Partial loss of the graft	1 (5)
	No complication	19 (95)

Data were presented as mean, SD or number (%) by SPSS.

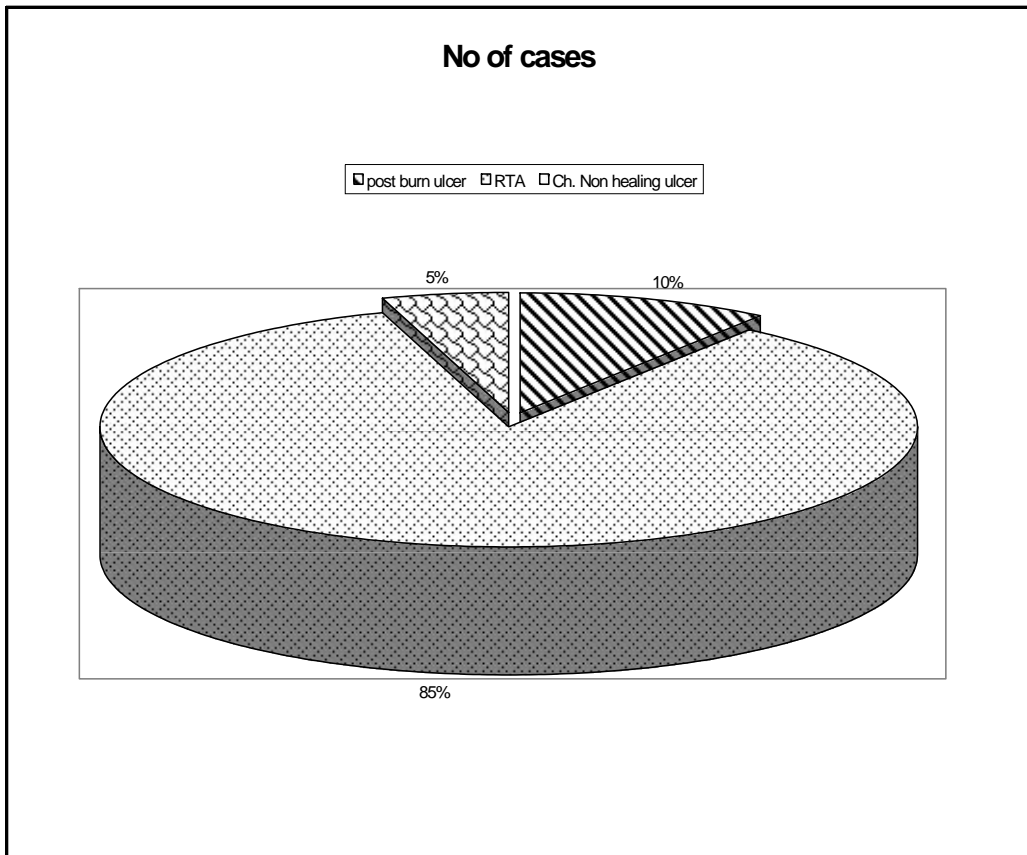


Figure (1): Pie chart of the causes of leg defects

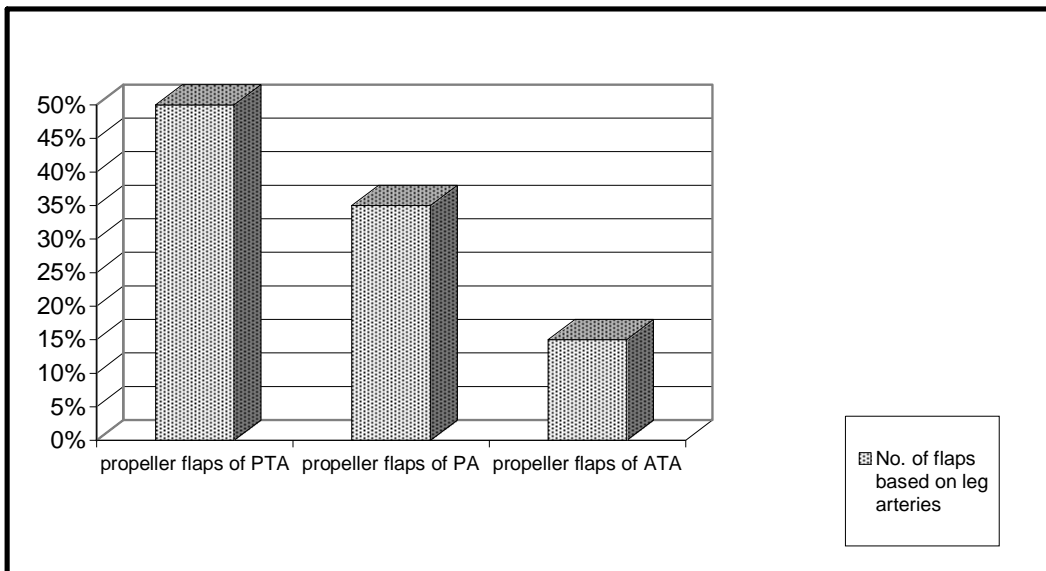
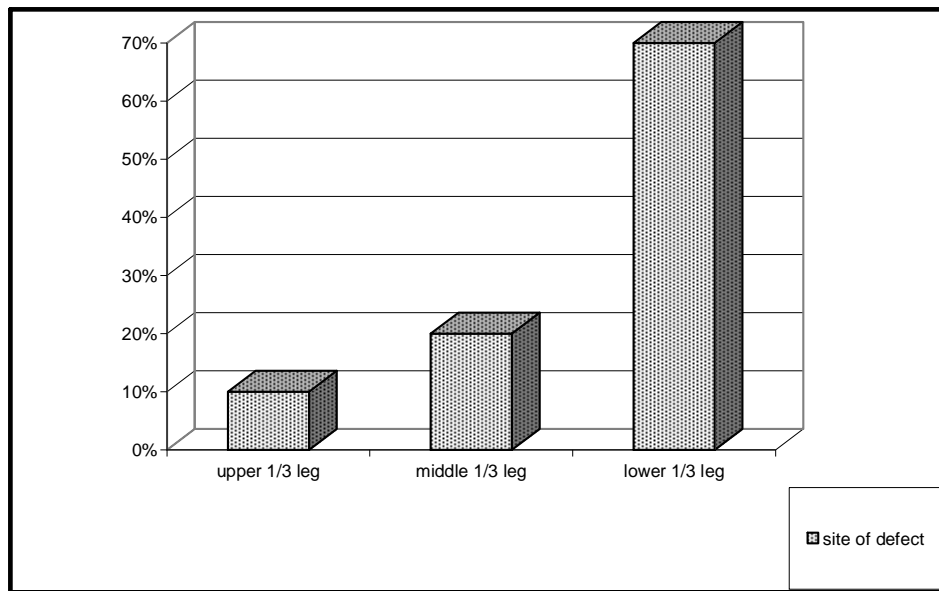


Fig (2)The number of propeller perforator flap based on leg arteries.



**Fig (3) The number of cases in relation to the site of the defect in the leg**

## DISCUSSION

In the current work, perforator flaps have been used to cover defects in 20 cases over the leg. Defects over the medial and lateral malleoli were also covered by perforator flaps. Flaps based on the posterior tibial artery up to 20 x 14 cm were safely elevated on a single perforator. Rotation of up to 180° was allowed as long as the flap based on a single perforator, with adequate dissection of the fascia surrounding the perforator to allow free rotation of the flap. Similarly, flaps can be raised along the antero lateral aspect of the leg based on perforators of the anterior tibial artery and the peroneal artery (Coman et al., 2014).

The pivot point should base on the distal perforators because it allows more healthy skin proximally to be Included in the flap to cover distal soft tissue defect

Although there is no definite limitation on the size of the flap that can be harvested (Francisco et al., 2014), it was noted that the septocutaneous vessels from the peroneal artery can Supply a skin paddle of up to 22-25 cm long and 10-14 cm wide.

We attempted to extend the length of the Flap beyond 25 cm, we have succeeded to reach up to 32cm long and 15 cm wide with no complication. The reliability of the propeller flap is dependent not only on the length of the flap, but also the pedicle size and rotation angle. According to the anatomical studies, the average perforator length from to the peroneal artery is 3.7-5.4 cm, and the diameter of the perforator vein is around 0.8 mm (Francisco et al., 2014).

Advocate that the chosen perforator should be at least 0.5-0.8 mm in diameter and 30 mm in length. Therefore, we

usually try to mobilize the entire perforator segment to obtain longer length for less strain on the vessels.

This will also allow for easier rotation and inseting. Propeller flaps based on the peroneal artery allow the surgeon to make the initial incision from either the medial or lateral side, depending on the patient's position. From the initial incision, the most reliable perforator can be selected under direct visualization, and the flap design can be modified as needed based on the location of the chosen perforator. Usually one perforator is adequate to supply the entire flap.

The lateral leg, which is mainly perfused by a number of branches from the peroneal artery, is one of the most suitable areas for harvesting perforator flaps (**Francisco et al., 2014**).

In addition, the prevalence of vascular abnormalities in the leg has been studied, and the peroneal artery is least likely to have atherosclerosis.

The maximum flap size that safely be based on a single perforator is still a matter of debate, and may lead to partial flap loss with ischemia of the edges. Larger flaps can be raised on the medial side of the leg compared with the anterolateral aspect. This is due to the fact that perforators arising from the posterior tibial artery, although small in number, are of larger diameter than those from the anterior tibial and peroneal arteries, where the converse holds (**Quaba and Quaba, 2006**).

There are many reports that have described the anatomy of the perforator vessels of the leg, but perforators and their

vascular territory are highly complex and variable.

Many anatomical studies were performed to assess the number and caliber of the perforators as seen in the peroneal artery, for example Schusterman et al. made 80 cadaver dissections and found an average 3.74 cutaneous perforators from the peroneal artery; Yoshimura et al. first described the peroneal flap, they found 4.8 cutaneous branches.

These vessels tended to be musculocutaneous in the proximal one third of the lower leg and septocutaneous in the distal one third of the lower leg (**Hallock, 2013**).

The perforators predominate in the 13 to 18 cm interval, so they are most frequently found in the middle third of the fibula, and there is a constant perforator at 5 cm proximally to lateral malleolus (**Masia et al., 2008**).

Anatomical studies of the septocutaneous vessels of the leg showed a perforator that is consistently the lowest one, proximal to the medial malleolus. The largest perforators are those located in the middle two quarters of the lower leg, therefore free posterior tibial perforator-based flaps are reliable, relatively large, thin, making them useful without sacrificing the posterior tibial artery. For the anterior tibial artery a number of perforators between 6 and 9 were found, with a lesser caliber than for posterior tibial artery perforators, with a greater number of septocutaneous perforators than musculocutaneous (**Hallock, 2013**).

Also known from other anatomical studies, the anterior tibial artery gives an average of  $6 \pm 3$  perforators to supply the

skin over the anterior compartment of the leg. They are both musculocutaneous and septocutaneous; however the musculocutaneous perforators have a short course within the muscle before reaching the overlying integument (**Lu et al., 2015**).

The perforators of the posterior tibial artery were found in a study to be mostly septocutaneous and also with the largest caliber and approximately constant location. Their dissection was easier than for the perforators of the peroneal or anterior tibial artery due to their large caliber and also location in the intermuscular septa, it is known that posterior tibial artery supplies 10% of the integument of the lower extremity:  $- 337 \pm 111 \text{ cm}^2$ . It supplies the tibia in addition to the soleus, flexor digitorum longus and tibialis posterior muscles and throughout its course it supplies an average of  $10 \pm 4$  perforators to the skin.

Usually there is a row of four to five septocutaneous perforators that emerge from the intermuscular septum between the soleus and flexor digitorum longus that supply the overlying integument (**Chunlin et al., 2015**).

There are certain well known complications and effects of these surgeries involving propeller flaps. The venous congestion of the tip or of the entire flap is the most common complication, and is due to the insufficient flow in the perforator pedicle, either because of an inadequate selection of the perforator, or because of an insufficient dissection and clearing of the vascular pedicle, especially around the vein (**Alexandru, 2012**).

Very rarely it happens to lose the entire flap, and from this point of view, in some cases is better to choose a local perforator flap, rather than a free flap. If a free flap is lost, everything is lost, while generally in a local perforator flap only

the superficial part is lost, which means that the flap did its' job of covering the denuded anatomical elements. After debridement, the remaining part of the flap generally granulates very fast, and can be grafted. If signs of congestion or ischemia are observed intraoperatively, a venous microsurgical anastomosis or the derotation of the flap in its original position can be attempted. If the vascular problems appear only postoperatively, the flap sometimes can be saved by removing the stitches, performing incisions, applying local heparinization or using leeches (**Alexandru, 2012**).

Handheld Doppler signals were easily identified with high sensitivity and positive predictive values when this instrument was used to identify perforators larger than 0.4 mm in diameter. It also was able to pick up signals from perforators smaller than 0.4 mm, but had unacceptably high false-positive result. The accuracy of handheld Doppler may reach up to 91.9 %, especially in gastrocnemius perforators.

Doppler is inexpensive and portable, and its user friendly nature has made it a very useful and common tool for the planning of perforator flaps. A handheld Doppler can demonstrate the direction of blood flow, but fails to determine the size of the vessel or its flow volume (**Kareem et al., 2012**).

Accuracy of the color duplex is superior to that of the handheld Doppler, making its use mandatory for areas in which anatomic variation is common and in which the course of the perforators can be affected by several other factors. Color duplex also is capable of delineating the size of the vessel and flow volume. However, the results of the color duplex are dependent on the operator, who is expected to have some knowledge and familiarity with the skin perforators. The

lack of resources and expertise can restrict color duplex availability as well as its use (Khan and Miller, 2007).

### CONCLUSION

The use of propeller flaps to cover defects of the leg showed satisfactory results as regards flap viability and providing a suitable coverage of various defects. The use of hand held Doppler proved satisfactory in pre operative delineation of the perforators. The safe angle of rotation of the flaps varied from 90° and 180°. The use of propeller flaps proved to be effective procedure in the armamentarium of leg reconstruction field and decreasing the donor site defect and complication.

### REFERENCES

- Alexandru V (2012):** Propeller Perforator Flaps in Distal Lower Leg: Evolution and Clinical Applications: Arch Plast Surg., 39:94-105.
- Chunlin H, Shimin C and Jian L (2015):** Surgical Atlas of Perforator flaps, a microsurgical dissection technique. Pbl: Springer Dordrecht Heidelberg, London.
- Coman C, Enescu, Iacob I, Hupkens P and Spauwen H (2014):** perforators of the calf arteries :anatomical study. Modern Medicine, 21 (3): 170-175.
- D'Arpa S, Cordova A, Pignatti M and Moschella F (2011):** Freestyle pedicled perforator flaps: safety, prevention of complications, and management based on 85 consecutive cases: *Plastic and Reconstructive Surgery*, 128(4):892–906.
- Francisco D, Franco D and Bianca D Fumiaki S, Aiko K and Haruaki S (2014):** Use of local muscle flaps to cover leg bone exposures. J Rev. Col. Bras. Cir., 41(6):715-730, 865-870.
- Hallock GG (2006):** The propeller flap version of the adductor muscle perforator flap for coverage of ischial or trochanteric pressure sores, Ann Plast Surg., 56:540 –542.
- Hallock GG (2013):**The complete nomenclature of combined perforator flap. Plast reconstr Surg., 127:1720-1729.
- Kareem A, El shahat A and Abou-Gamrah S Gilbert, Scott F and Sunderland MA (2012):** Color Duplex Assessment of 4th and 5th Internal Mammary Artery Perforators: The Pedicles of the Medially Based Lower Pole Breast Flaps. Plastic Surgery Department, Radiology Department, and General Surgery Department, Faculty of Medicine, Ain Shams University, Abbassia, Cairo, Egypt
- Khan UD and Miller J G (2007):** Reliability of Handheld Doppler in Planning Local Perforator–Based Flaps for Extremities: Aesth Plast Surg., 31:521–525
- Koshima I, Inagawa K and Urushibawa K (2003):** Paraumbilical perforator flap without deep inferior epigastric vessels: Plast Reconstr Surg., 102:1052e7
- Lecours C, Saint-Cyr M and Wong C (2010):** Freestyle pedicle perforator flaps: clinical results and vascular anatomy: Plast Reconstr Surg., 126:1589–1603
- Lu T C, Lin C H, Hou C, Chang S, Lin J and Song D (2015):** Versatility of the pedicled peroneal artery perforator flaps for soft-tissue coverage of the lower leg and foot defects. J Plast Reconstr Aesthet Surg., 45(2):30-55
- Masia J, Larran'aga J and Clavero J A (2008):** The value of the multidetector row computed tomography for the preoperative planning of deep inferior epigastric artery perforator flap: our experience in 162 cases. Ann Plast Surg., 60(1):29-36.
- Pignatti M, Ogawa R and Hallock G (2011):** The "Tokyo" consensus on propeller flaps: Plast Reconstr Surg., 127(2):716-722.
- Quaba S and Quaba P (2006):** Pedicled perforator flaps for the lower limb: Seminar Plast Surg., 20:103-11.
- Ramesh I, Mohd S and Normala N (2013):** Propeller Flaps in Lower Limb Reconstruction: Case Series: Anaplastology, 2161-1173.
- Wei FC and Mardini S (2004):** Free-style free flaps. Plast Reconstr Surg., 114:910-916.



## تقييم الشرائح المروحية المعتمدة علي الشريان الثاقب في إعادة بناء الساق

عبد المنعم حسين حوتة - أحمد صبري احمد حسن - سامي عبد الستار عليوة - عصام علي محمد  
طمان - مصطفى سيد أحمد مكي - محمد سويلم محمد إبراهيم

قسم جراحة التجميل - جامعة الأزهر

**خلفية البحث:** إعادة بناء الانسجة السطحية لجلد الساق والقدم من المعوقات الصعبة ، وخاصة مع الأوتار المكشوفة والعظام أو الأنسجة الأخرى. و لا يزال التحدي الأصعب في جراحة التجميل والإصلاح. ولقد تم استخدام الشرائح ذات النمط المحوري من قبل ذلك علي أساس إمدادات الدم المحوري لتحسين نوعية النتائج، ولكن مع التضحية بالشريان الرئيسي.

**الهدف من البحث:** دراسة مستقبلية للمرضى من 6 سنوات وحتى 54 سنة الذين يعانون من عيوب الساق وتقييم الشرائح المروحية المعتمدة علي الشريان الثاقب في إعادة بناء الساق.

**المرضى وطرق البحث:** تشمل هذه الدراسة عشرين مريضاً يعانون من عيوب الساق والذين كانوا قد حضروا الي قسم جراحة التجميل بجامعة الأزهر يطلبون إعادة الإعمار الساق خلال الفترة من أكتوبر 2014 إلى سبتمبر 2016 وقد تم وضع جميع المرضى تحت التخدير الشوكي اثناء إجراء هذه الجراحة.

**النتائج:** بعد الموافقة الكتابية من المرضى و إجراء الجراحة، كانت النتائج كالتالي: هناك حالة واحدة فقط من فقدان سطحي بالجلد، وأخرى من فقدان جزئي للجزء البعيد من الشريحة الجلدية. وهناك إثنين من اللوحات خضعتا في البداية للإزدحام القاصي . ومع ذلك، تحسنت على مدى ثلاثة أيام بعد العملية. وهناك حالة واحدة تعرضت لنزيف ما بعد العمل الجراحي، وتمت السيطرة عليها بالإضافة إلي اخري والتي تأخرت في إلتئام الجرح. ومع ذلك، نجا ما تبقى من اللوحات والتأمت الجراح بطريقة كاملة.

**الإستنتاج:** أظهر استخدام اللوحات المروحية لتغطية عيوب الساق نتائج مرضية فيما يتعلق بجذوى هذه الشرائح المعتمدة علي الشريان الثاقب وتوفير تغطية مناسبة من العيوب المختلفة.