

HEMOSPRAY IN THE TREATMENT OF UPPER GASTROINTESTINAL TRACT BLEEDING

By

Mohammed A Abomera

General Surgery Department, Al-Azhar Faculty of Medicine

ABSTRACT

Background: Upper gastrointestinal (GIT) bleeding remains one of the most important emergencies. It has been widely accepted that the first-line treatment for acute upper GIT bleeding, especially peptic ulcer bleeding, is endoscopic hemostasis. Endotherapy for upper gastrointestinal bleeding can be challenging. Hemospray is a novel hemostatic agent for the treatment of upper gastrointestinal bleeding.

Objective: Report initial experience of hemospray use in treatment of upper GIT bleeding.

Patients and Methods: The present study included twenty-five patients with acute GIT bleeding originating from variceal or non-variceal sources. Hemospray was endoscopically applied when active bleeding occurs; and outcome was measured.

Results: success rate was achieved in 92.0% of cases with no unwanted side effects. Patients showed stable postoperative hemodynamics and needs no further intervention.

Conclusion: hemospray appears to allow safe and effective control of upper gastrointestinal bleeding

Keywords: upper Gastro-intestinal bleeding; varices; Ulcer; hemospary

INTRODUCTION

Gastrointestinal bleeding is one of the most important emergencies in gastroenterology. Although mortality is decreased, the rate is still high, at 5% - 10% in patients with peptic ulcer bleeding, about 15% in those with variceal hemorrhage, and 11%–14% in a population based series all causes (Nahon et al., 2012).

It has been widely accepted that the first-line treatment for acute upper gastrointestinal bleeding, especially peptic ulcer bleeding, is endoscopic hemostasis. It is currently recognized to be an effective procedure for the reduction of the rate of rebleeding, the need for surgery and mortality (Pedroto et al., 2012).

The most commonly used modalities are epinephrine injection, thermal coagulation using heater probe or monopolar probe and mechanical hemostasis using hemoclips, frequently applied as a combination therapy. They are highly effective, with overall success rates of 85%–95% in controlling hemorrhage. However, some 5%–10% of the patients still experience recurrence of bleeding after the initial hemostasis with combined endoscopic therapy (Sung et al., 2011). Endotherapy for upper gastrointestinal bleeding can be challenging. Bleeding may occur from sites that are difficult to approach, such as the posterior duodenal wall or the upper region of the lesser gastric curvature, and this may make it hard to place hemoclips or apply

adequate pressure with coagulation probes or lesions can be large and actively bleeding, which makes it difficult to visualize and treat (**Weusten and Bergman, 2011**). In such cases, a higher level of technical expertise is often required. A simple and effective method of endoscopic hemostasis would have a significant impact on the treatment of active gastrointestinal bleeding. An ideal endoscopic hemostasis device would be one that does not require a direct contact with the bleeding point and one that does not cause further tissue damage that may result in more severe bleeding (**Sung et al., 2011**).

Hemospray (Cook Medical, Winston-Salem, NC) is a hemostatic powder developed for non-variceal upper gastrointestinal bleeding (NVUGIB) control. The powder is sprayed toward the source of bleeding via a catheter passed through the accessory channel of an endoscope. Hemospray is thought to cause hemostasis by sealing injured blood vessels and activation of platelets and the intrinsic coagulation pathway. Hemospray has been shown to be safe and effective in achieving hemostasis in bleeding peptic ulcers in a prospective clinical study and several further case series have described the use of hemospray in other non-variceal causes of gastrointestinal bleeding (**Smith et al., 2014**).

Hemospray is an inorganic powder not absorbed or metabolized by mucosal tissue. When in contact with blood, its adhesive properties result in a physical barrier that covers the bleeding site. The Hemospray barrier is stable because of the effect of accumulation of clotting factors, and consequently the bleeding point is not

exposed to acid, allowing the healing process to continue. Neither luminal nor systemic side effects have been reported with the product (**Rapat et al., 2016**).

When the powder comes into contact with moisture in the GI tract, it becomes cohesive and adhesive, forming a stable mechanical barrier that adheres to and covers the bleeding site to achieve hemostasis. The covering formed by the powder separates from the intestinal wall and is naturally eliminated from the GI tract (**Sung et al., 2011**). Advantages of hemospray is that, it does not require very precise targeting such as application of bipolar electrocoagulation; its coverage of a large surface area; and the procedure is quick and can, therefore, be completed rapidly in frail, elderly patients with few adverse events (**Iacucci, 2014**). Five cases of the use of hemospray in the successful treatment of UGIB secondary to gastroduodenal malignancies have also been described (**Chen et al., 2010**), as well as 2 case reports of successful treatment of gastric variceal bleeding (**Holster et al., 2012 and Stanley et al., 2013**).

Here we presented our initial experience of hemospray use in treatment of upper GIT bleeding.

PATIENTS AND METHODS

The present study included twenty-five patients with suspected upper gastrointestinal bleeding (variceal and non-variceal). The procedure was explained to all patients and their informed consent was obtained. The local ethics committee of Surgery Department; Al-Azhar University (Damietta) approved the study protocol.

If liver diseases were diagnosed, the severity of liver cirrhosis was done by Child's Pugh classification as stated with **Cholongitas et al. (2005)**. The score employs five clinical measures of liver disease. Each measure is scored 1-3, with 3 indicating most severe derangement. Total bilirubin (1 if < 2; 2 if 2-3; and 3 if >3mg/dl); serum albumin (1 if > 3.5; 2 if 2.8 -3.5 and 3 if < 2.8g/dl); INR (1 if < 1.7; 2 if 1.7-2.3; and 3 if > 2.3); ascites (1 if none, 2 if mild and 3 if moderate to severe); and hepatic encephalopathy (1 if none; 2 if grade I-II (or suppressed with medication) and 3 if grade III-IV (or refractory). Disease severity is Child's class A if patient points 5-6; Class B if 7-9 and class C if 10-15.

Hemostatic powder (TC-325) produced by (Hemospray; Cook Medical, Winston-Salem, NC). It is a granular, mineral, non-absorbable powder used for the management of arterial wounds.

The most novel endoscopic hemostatic technology is TC-325. It contains no human or animal proteins or botanicals and has no known allergens. TC-325 is a highly absorptive compound with a multimodal mechanism of action. When put in contact with moisture (eg, blood or tissue) in the GI tract, the powder becomes cohesive and adhesive. As a result, TC-325 forms a mechanical barrier that adheres to and covers the bleeding site, achieving very rapid hemostasis, usually within seconds. After approximately 24 to 72 hours (the exact lag time remains unknown but could be shorter), the adherent layer subsequently sloughs off into the lumen from the mucosal wall and is completely eliminated from the GI tract (**Sung et al., 2011**).

Hemospray delivery system (Figure 1):

It consists of a syringe containing the Hemospray powder (21 g per syringe), a delivery catheter that is inserted into the working channel of the endoscope, and an introducer handle with a built-in CO₂ canister to propel the Hemospray powder out of the catheter.

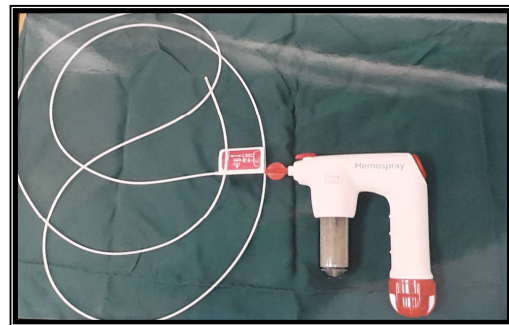


Figure (1): Hemospray delivery system

Endoscopic procedure

All endoscopies were performed within 12 hours after admission for a first episode of bleeding. The hemostatic powder was applied after identification of a bleeding site located in the esophagus or at the GE junction, stomach or duodenum, by a standard protocol. The standard protocol is as the following: in cases of variceal bleeding, the catheter located at the level of the cardia and the powder delivered by a noncontact delivery approach, over the distal 15 cm of the esophagus), while slowly pulling back the endoscope. Application within the proximal 5 cm of the esophagus always avoided. Hemospray was then delivered in short spray bursts (for 1–2 seconds) until hemostasis was controlled. Once bleeding was controlled after first application, the bleeding site was observed for 3 minutes under endoscopy. Then, hemospray was reapplied again – if bleeding was recurred during this 3-minute observation period–until hemostasis was achieved again

(second application). Again, the site was observed for another 3 minutes, and if bleeding was recurred, it is considered as a treatment failure (early treatment failure); it did not occur in any patient (Figure 2, 3).

In cases of variceal bleeding (6 patients 24%), the catheter located at the level of the cardia and the powder delivered by a noncontact delivery approach, over the distal 15 cm of the esophagus), while slowly pulling back the endoscope. Application within the proximal 5 cm of the esophagus always avoided. Hemospray delivery was the same like non-

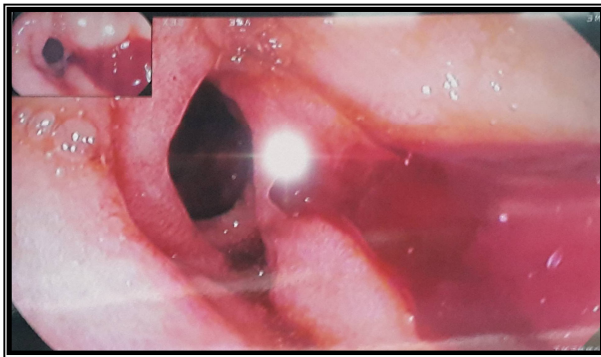


Figure (2): Endoscopic view showed bleeding gastric ulcer.

Statistical analysis of data: The collected data were organized, tabulated and statistically analyzed using Microsoft Office Excell® 2010. The numerical data were presented as mean and standard deviations, while categorical data were presented as relative frequency and percent distribution. For qualitative data and quantitative data, Chi square (X^2) and student (t) test were used respectively. P value < 0.05 was considered significant.

RESULTS

As regard to age, it ranged from 42 to 65 with a mean of 55.96 ± 5.84 years where males represented 68.0% of all cases.

variceal bleeding. If there was early treatment failure, a shift to other hemostatic procedures, such as variceal ligation which occurred in two patients (8%). A late treatment failure was defined as recurrent bleeding within the first 24 hours after hemospray application. All patients were kept under close observation and monitored for 24 hours, with continuous infusion of somatostatin and the hospital's standard of care. Patients were monitored by preoperative and six hours after endoscopy with hemoglobin and blood pressure. Patients were followed up for the next two weeks.

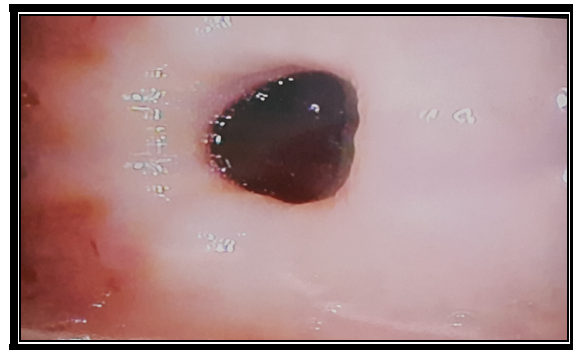


Figure (3): Ulcer after hemospray injection.

There were 6 patients (24%) presented by bleeding esophageal varices and 19 patients (76%) presented by bleeding peptic ulcer. In cases of esophageal varices there were 4 patients Child C (16%) and 2 patients Child A (8%). In cases of peptic ulcer, there were 11 patients (32%) with gastric ulcer and 8 patients (32%) with duodenal ulcer. The majority of patients were presented by hematemesis (80%), and the rest presented by melena (20%); 28% needed blood transfusion before endoscopy (1.28 ± 0.48 units); 12% needed blood transfusion in first day after endoscopy (1.33 ± 0.57 units). The mean hemoglobin concentra-

tion before endo-scopy was 9.26±1.73 g/dl. After endoscopy, it was 8.81±0.99 g/dl. Blood pressure increased after endoscopy (111±7 / 71.0±6 mmHg) compared to 102±9 / 66±5 mmHg before endoscopy.

In cases of bleeding peptic ulcer, hemospray was applied once in all patients, and success rate was 100%. In cases of bleeding esophageal varices,

hemospray was applied successfully once in 50% and twice in 50% of patients. Two patients did not stop bleeding after second application of hemospray (failure rate 33.3%) and treated with band ligation. So the success rate in cases of bleeding esophageal varices was 66.7%.

The success rate in all cases (variceal and peptic ulcer bleeding) was 92% and failure rate was 8% (Table 1).

Table (1): Patients characteristics and results of the studied cases

Variable	Statistics	Chi-Sqaure/t-test	
		X ² /t	P value
Age (years); mean±SD; range	55.96±5.84; (42-65)		
Sex: male/female (no,%)	17/8 (68%/32%)	3.24	>0.05 NS
Child's Pugh classification; A/B/C (n,%)	0/9/16(0.0%/36.0%/64.0%)	1.96	>0.05 NS
Presentation (n, %)			
Hematemesis	20(80.0%)		<0.01
Hematemesis with melena	5 (20.0%)	9.0	S
Blood transfusion before endoscopy (n, %)	7 (28.0%)	2.0	
Blood transfusion after endoscopy	3 (12.0%)		> 0.05 (NS)
Number of units before: mean±SD; range	1.28±0.48; (1-2)		>0.05
Number of units after: mean±SD; range	1.33±0.57; (1-2)	0.14	NS
Hemoglobin before endoscopy; mean± SD; range	9.26±1.73 (6.3-11.0)		>0.05
Hemoglobin after endoscopy; mean± SD; range	8.81±0.99 (7.20- 10.40)	0.41	NS
Blood pressure before endoscopy; mean± SD; range	102±9/66±5		
Blood pressure after endoscopy; mean± SD; range	111±7/70±6		
Number of hemosprary (1/2); no, %	22/3 (88.0% / 12.0%)	14.44	<0.001 S
Outcome (success/failure); no, %	23/2 (92.0% / 8.0%)	17.64	<0.001 S

DISCUSSION

Endoscopy plays a pivotal role in the management of upper GI bleeding, allowing diagnosis, risk stratification and treatment. Endoscopic hemostatic therapy is the basis of treatment in patients with active bleeding or with endoscopic features that predict an increased risk of

further hemorrhage (**Bustamante-Balén and Plumé, 2014**).

Hemospray is hemostatic powder that had been added to endoscopic maneuvers to treat GI bleeding. They are intended to control active bleeding by delivering a substance over the bleeding site using a catheter. Perhaps the main advantage of

this technology is that less precision is needed, allowing for treatment of lesions with difficult access and refractory to standard therapy (**Giday et al., 2013**).

Recently, hemospray has been proposed as a novel way of producing endoscopic hemostasis for active gastrointestinal bleeding, mostly for ulcer bleeding. To date, the study of hemospray in tumor bleeding is limited as results have not focused on this particular patient group (**Chen et al., 2015**).

In the present study, we reported our initial experience of hemospray use in management of upper GIT bleeding (variceal and non-variceal). The success rate in the present study was 92.0. This result adds to previous studies proved the efficacy of hemospray.

This powder is initially tested in animal models. **Giday et al. (2011)** conducted a randomized controlled trial on 10 pigs allocated to treatment with TC-325 or sham after surgical creation of an arterial bleeding from a gastroepiploic vessel opened up to the gastric lumen. The endpoint of their study was the proportion of animals in which hemostasis was achieved at 1 h. In the treatment group, acute hemostasis was achieved in the whole group with no re-bleeding in the first 6 h compared to 0% of animals in the sham group. Mean time to hemostasis was 13.8 min. The same group, in a study designed to identify local and systemic secondary effects following endoscopic application of TC-325, showed no local or regional particulate effects and no distance embolic effects (**Giday et al., 2013**). In addition, a recent European multicenter study has shown no secondary effects when using TC-325 for a variety of

indications, including peptic ulcers, vascular lesions, malignancies and post-therapeutic bleedings (**Smith et al., 2014**). In the present study, we also registered no systemic or local effects of the hemospray.

In a case report, **Fujita (2012)** was the first to report usage of hemospray in treatment of variceal bleeding not responding to standard treatment. She was a 79-year-old female presented with a 3-day history of melena. By history she had hepatosplenomegaly complicated by portal hypertension and ascites. At presentation she had a blood pressure of 80/40 mmHg with a pulse rate of 90bpm with peripheral cyanosis. In anticipation of a variceal hemorrhage, standard administration of an antibiotic (norfloxacin 400 mg twice daily) and vasopressor drugs (octreotide) was initiated. Fluid and packed cell administration was restricted to stabilize vital signs. Upper gastrointestinal endoscopy was performed and revealed that, in the distal esophagus, small varices without bleeding stigmata were seen, but in the gastric fundus, a profusely bleeding varix of 8 mm was observed. Next, in three consecutive injections, a total volume of 2.6 ml HistoAcryl™ with lipiodol was injected. However, hemostasis could not be achieved and hemodynamic instability ensued. Rescue treatment with TIPS was considered, but not pursued given her cardiac condition. Instead of injecting more HistoAcryl™, the author decided to apply Hemospray and sprayed approximately 10g covering the entire bleeding varix. Persistent hemostasis was confirmed after 5min of visual inspection. The patient received standard post-endoscopic care and went home. No

rebleeding occurred at follow-up at day 7 and 30.

Going with results of the present work, TC-325 has been used in cases of both esophageal and gastric bleeding with good short-term results (**Holster et al., 2012; Ibrahim et al., 2013 and Stanley et al., 2013**). **Smith et al. (2014)** controlled acute bleeding from severe portal hypertensive gastropathy in 3 patients. However, it is only able to control the initial bleeding and cannot prevent further bleeding.

Regarding mechanism of action of hemospray, **Stanley et al. (2013)** reported that, the powder has three mechanisms of action. Physically, the powder forms a mechanical barrier over the bleeding site. It is absorbent and acts as a serum separator, thus increasing the concentration of clotting factors. It is also electrostatic due to its negative charge. Finally, the powder activates the intrinsic clotting cascade. Hemospray is approved in some regions of the world, including Canada, HongKong, France, and several European countries for upper gastrointestinal bleeding.

In short, from results of the present study, we can conclude that, hemospray appears to allow safe control of upper GIT bleeding. However, its long-term results must be studied before its use on a wide scale. Now, it at least can be used as an emergency measure to stop active bleeding until other definitive interventions with proven efficacy established.

REFERENCES

- Bustamante-Balén M and Plumé G (2014):** Role of hemostatic powders in the endoscopic management of gastrointestinal bleeding. *World J Gastrointest Pathophysiol*, 5(3): 284-292
- Chen YI, Barkun A and Nolan S (2015):** Hemostatic powder TC-325 in the management of upper and lower gastrointestinal bleeding: a two-year experience at a single institution. *Endoscopy*, 47: 167-171
- Chen Y-I, Barkun AN, Soulellis C, Mayrand S and Ghali P (2010):** Use of the endoscopically applied hemostatic powder TC-325 in cancer-related upper GI hemorrhage: preliminary experience. *Gastrointest Endosc*, 72:817-824.
- Cholongitas E, Papatheodoridis GV and Vangeli M (2005):** Systematic review: The MELD -should it replace Child-Pugh's classification for assessing prognosis in cirrhosis? *Alimentary Pharmacology & Therapeutics*, 22: 1079-89
- Fujita T (2012):** Controlling gastric variceal bleeding with endoscopically applied hemostatic powder (Hemospray™). *Journal of Hepatology* 57: 1391-1402.
- Giday SA, Kim Y, Krishnamurthy DM, Hutcheon D, Okolo PI and Kalloo AN (2011):** Long-term randomized controlled trial of a novel nanopowder hemostatic agent (TC-325) for control of severe arterial upper gastrointestinal bleeding in a porcine model. *Endoscopy*, 43: 296-299
- Giday S, Van Alstine W and Van Vleet J (2013):** Safety analysis of a hemostatic powder in a porcine model of acute severe gastric bleeding. *Dig Dis Sci*, 58: 3422-3428
- Holster IL, Poley JW and Tjwa ET (2012):** Controlling gastric variceal bleeding with endoscopically applied hemostatic powder (Hemospray™). *J Hepatol*, 57: 1397-1398
- Iacucci M (2014):** Hemostatic spray—a welcome addition to the armamentarium against gastrointestinal bleeding. *Can J Gastroenterol Hepatol*, 28 (2): 71.
- Ibrahim M, El-Mikkawy A, Mostafa I and Devière J (2013):** Endoscopic treatment of acute variceal hemorrhage by using hemostatic powder TC-325: a prospective pilot study. *Gastrointest Endosc*; 78: 769-773

- 11. Nahon S, Hagège H, Latrive JP, Rosa I, Denis J and Pariente A (2012):** Epidemiological and prognostic factors involved in upper gastrointestinal bleeding: results of a French prospective multicenter study. *Endoscopy*, 44: 998-1006.
- 12. Pedroto I, Dinis-Ribeiro M and Ponchon T (2012):** Is timely endoscopy the answer for cost-effective management of acute upper gastrointestinal bleeding? *Endoscopy*, 44: 721-722.
- 13. Rapat P, Piyapan P and Rungsun R (2016):** The efficacy of hemospray in patients with upper gastrointestinal bleeding from tumor. *Endosc Int Open*, 4(9): E933-E936.
- 14. Smith LA, Morris AJ and Stanley AJ (2014):** The use of hemospray in portal hypertensive bleeding; a case series. *Journal of Hepatology*, 60:457-460.
- 15. Stanley AJ, Smith LA and Morris AJ (2013):** Use of hemostatic powder (Hemospray TM) in the management of refractory gastric variceal hemorrhage. *Endoscopy*, 45: E86-E87.
- 16. Sung JJ, Luo D, Wu JC, Ching JY, Chan FK and Lau JY (2011):** Early experience of the safety and effectiveness of hemospray in achieving hemostasis in patients with acute peptic ulcer bleeding. *Endoscopy*, 43 (4): 291-295.
- 17. Weusten B and Bergman JJ (2011):** A hemostatic spray: the easy way out for upper gastrointestinal bleeding. *Endoscopy*, 43: 343-344.

الهيموسبراي في علاج نزيف الجهاز الهضمي العلوي

محمد السيد محمد أبو ميرة

قسم الجراحة العامة – كلية طب الأزهر (دمياط)

خلفية البحث: يمثل نزيف الجهاز الهضمي العلوي واحدا من أهم حالات الطوارئ. ومن المتفق عليه أن إيقاف النزيف عن طريق منظار الجهاز الهضمي العلوي يمثل الخط الأول للعلاج وخصوصا لقرحة المعدة والاثني عشر النازفة. وعلاج نزيف الجهاز الهضمي العلوي بالمنظار يعتبر من التحديات. هيموسبراي يمثل مثبط (موقف) جديد للنزيف وذلك لعلاج نزيف الجهاز الهضمي العلوي.

الهدف من البحث: تقرير للخبرة المبدئية في فعالية استخدام مادة الهيموسبراي في إيقاف نزيف الجهاز الهضمي العلوي.

المرضي وطرق البحث: تضمن هذا البحث 25 مريضا يعانون من نزيف الجهاز الهضمي العلوي الناتج عن دوالي وغيرها. وتم استخدام مادة الهيموسبراي عن طريق منظار الجهاز الهضمي العلوي وتم قياس النتائج.

النتائج: نسبة النجاح في إيقاف النزيف 92% بدون آثار جانبية وكانت حالة المرضى مستقرة بعد العملية ولم يحتاجوا أي تدخل آخر.

الإستنتاج: تعتبر مادة الهيموسبراي آمنة وفعالة في إيقاف نزيف الجهاز الهضمي العلوي.