



Effect of Plasma Rich in Growth Factors IntraArticular Injection in Management of Patients with Internal Derangement of TMJ Using CT Guided Puncture versus Conventional Technique

Amany N Elkholy^{1*}, Nahed A Abd El-Moniem², Suzan A Hassan³, Ashraf M Enite⁴

Codex : 52/1910

azhardentj@azhar.edu.eg

http://adjg.journals.ekb.eg

DOI: 10.21608/adjg.2019.7899.1119

ABSTRACT

Purpose: To evaluate effect of PRGF intra articular injection in patients with internal derangement of TMJ using CT guided versus conventional puncture technique. **Materials and methods:** Twenty patients with internal derangement without improvement by conservative treatment were divided into two groups: Group I: ten patients underwent arthrocentesis followed by PRGF injection using conventional puncture by anatomical landmarks. Group II: ten patients underwent arthrocentesis followed by PRGF injection using landmark and confirmed by CT. All patients were assessed preoperatively and postoperatively at 1week, 3 and 6 months for pain level, maximum interincisal opening, lateral, protrusive movements, joint tenderness and disk position with MRI after 6 months. **Results:** In both groups, all clinical variables showed statistical significant discrepancy postoperatively, the discrepancy between both groups was not statistically significant and MRI showed no statistical significant change in disc position. **Conclusion:** CT confirmed accurate position and depth within TMJ upper compartment in different views, allowed correction with less puncture trials and decreased learning curve of TMJ puncture but it is expensive, time consuming and not available in clinics. Anatomical landmarks is easy and representable method for TMJ puncture but blind technique and needs skill. Single injection of PRGF found efficient in the treatment of internal derangement of TMJ.

KEYWORDS

PRGF, CT, arthrocentesis,
TMJ internal derangement.

INTRODUCTION

Internal derangement is the most common disorder of TMJ^(1,2). It is an intra articular condition which is a disturbance in the normal relationship

• Paper extracted from Master thesis titles “Effect of plasma rich in growth factors intra articular injection in management of patients with internal derangement of TMJ using CT guided puncture versus conventional technique”

1. *Dentist at Ministry of Health, Egypt. Email: amanyelkholy96@yahoo.com
2. Lecturer of Oral and Maxillofacial Surgery, Faculty of Dental Medicine for Girls, Al-Azhar University in Cairo.
3. Professor of Oral and Maxillofacial Surgery, Faculty of Dental Medicine for Girls, Al-Azhar University in Cairo.
4. Professor of Radiology, Faculty of Medicine for Grils, Al-Azhar University in Cairo.

between the articular disc of the TMJ, the articular eminence and the condyle⁽¹⁾. Patients often suffer from pain, joint sounds, limitation in mouth opening and deviation of the mandible toward the affected side during opening⁽³⁾. Nonsurgical therapy as soft diet, rest, heat, nonsteroidal antiinflammatory drugs, muscle relaxants⁽⁴⁾, occusal splints and physical therapy can be used successfully with most patients^(4,5). More invasive interventions such as arthrocentesis, arthroscopy⁽¹⁾, disc repositioning, discectomy and modified condylotomy⁽⁵⁾ may need to patients who do not respond to nonsurgical therapy.

Arthrocentesis is less invasive procedure^(6,7) that consists of washing the upper compartment of the TMJ⁽⁸⁾ with physiological saline or Ringer's lactate^(7,9) to release adhesions and remove intra articular inflammatory mediators⁽⁷⁾. There are different landmarks used for the entry of the needles for TMJ arthrocentesis: Nitzan landmarks: 10 mm anterior, 2 mm below the mid tragus on the canthus tragus line and 20 mm anterior, 10 mm below⁽¹⁰⁾, Laskin landmarks⁽¹¹⁾: the first needle is inserted at the same point described before⁽¹⁰⁾ and the second one placed 3 to 4 mm in front of the first one in the posterior recess.

The anatomy of the TMJ is complex and injection into the TMJ can be dangerous because of the nearness of facial nervous and vascular structures⁽¹²⁾ and may cause complications like facial nerve injury, penetration of the middle cranial fossa or irreversible changes to the TMJ itself⁽¹³⁾. Imaging guided puncture techniques for the TMJ include radiographic fluoroscopy, interventional computed tomography (CT), magnetic resonance imaging (MRI) and ultrasonography⁽¹⁴⁾.

PRGF Endoret is an autologous biologic therapy using the patient's own plasma, platelet derived growth factors and endogenous fibrin scaffold for regenerative purposes⁽¹⁵⁾. It does not include leukocytes and has more platelet concentration than in normal blood⁽¹⁶⁾. It polymerizes in situ into a three

dimensional fibrin scaffold once it is activated⁽¹⁷⁾ and this fibrin scaffold has main properties: (i) heparan sulfate binding domains that may sequester and then release heparin binding growth factors including PDGF, FGF, HGF, and VEGF (ii) cell adhesion that contribute to cell survival⁽¹⁸⁾⁽¹⁹⁾. It has several bioactive mediators as TGF- β , PDGF, VEGF, FGF, EGF, IGF-1, HGF, BMPs, BDNF, histamine, serotonin, calcium. ATP/ADP, IGF-1, HGF, prothrombin, fibrinogen and fibronectin⁽²⁰⁾.

MATERIALS & METHODS

Randomized prospective clinical trial was performed on twenty patients with internal derangement without improvement by conservative treatment. The diagnosis was made on the basis of Research Diagnostic Criteria for Temporomandibular Disorders (RDC/TMD) and confirmed by the findings of magnetic resonance images (MRI). They were divided into equal groups:

Group I: Ten patients with seventeen joints underwent arthrocentesis followed by PRGF injection using conventional puncture technique (CPT) by anatomical landmarks.

Group II: Ten patients with thirteen joints underwent arthrocentesis followed by PRGF injection using landmark and confirmed by CT (IGPT).

Inclusion criteria were as follows: Patients who did not respond to previous conservative treatment, complained from TMJ pain accompanied by joint sounds or limited mouth opening, impeded lateral movement and did not undergo previous arthrocentesis and injection.

Exclusion criteria were as follows: TMJ hypermobility, degenerative changes in TMJ, who responded to conservative therapy within three months, who with previous TMJ surgery, joint fractures and taking anticoagulation treatment, NSAIDs within 48 hours preoperatively.

Preoperative patient assessment:

- A) **Patient questionnaire** included all details recorded by examiner including personal data, chief complaint, past dental and medical history.
- B) **Clinical examination:** Assessment of pain was done on Visual Analogue Scale (VAS). Then Maximum Interincisal Opening (MIO), lateral jaw movements and protrusive movement were measured in millimeters by graduated ruler. Also presence of joint tenderness was assessed by palpation.
- C) **MRI outcome variable:** Disk position is in normal position or anteriorly displaced with or without reduction
- D) **Conservative treatment** for 3 months: NSAIDs, muscle relaxant for 3 weeks, physiotherapy program, thermal therapy ,exercise therapy and anterior repositioning splint was worn at night during sleep and as much as possible during day time.

Operative Procedures

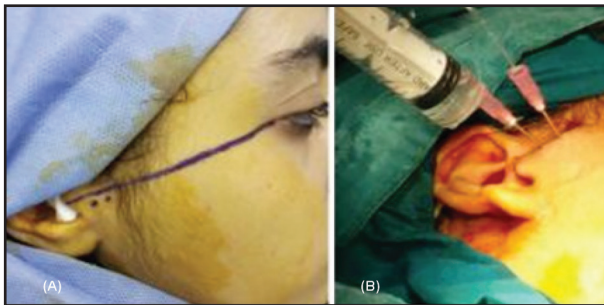
1. **PRGF preparation** :16 ml of peripheral blood was extracted from the antecubital vein then divided equally into 2 falcon tubes containing sodium citrate (3.8 %) as anticoagulant. The tubes were placed in the 800D centrifuge in a balanced manner in an even number. The centrifuge was set on 3200 rpm for 8 minutes. Once the blood was centrifuged, PRGF was aspirated carefully under a sterile condition. Only 2ml (buffy coat) above the red erythrocytes from each tube was picked up and the leukocytes was avoided. Then PRGF was placed in a glass tube and activated by adding 2ml calcium chloride ⁽¹⁵⁾.
2. **Premedication:** Unictam 1.5 mg vial (ampicillin, sulbactam, MUP) was administered intravenously immediately before procedure.
3. **Anaesthesia:** The preauricular area was prepared with antiseptic solution betadine and auriculotemporal nerve block was given.

4. **Arthrocentesis:** Holmlund–Hellsing Line⁽²¹⁾ was drawn(a line from the lateral canthus of the eye to the central point on the tragus). Laskin points (point A) (point D)⁽¹¹⁾ was used, the external auditory meatus was blocked with cotton and a sterile bite block was placed on contralateral dental arch to keep mouth open and allow the condyle moving downward forward to create a triangular depression in front of the tragus to facilitate the approach to the upper TMJ compartment. 18 gauge needle was then inserted at A point into superior joint space and directed medially and superiorly. 2ml of ringer lactate was injected to distend the superior joint space, the needle was confirmed in when back pressure in the syringe was felt. Then the second needle was inserted in the distended compartment at D point. The joint was washed with 100 ml ringer lactate. After arthrocentesis was finished the second needle was removed and 2ml of fresh prepared PRGF was injected then the first needle was removed and gentle manipulation of the jaw was done in vertical, protrusive and lateral movement to break any adhesion, free the disc and restore mandibular movement.

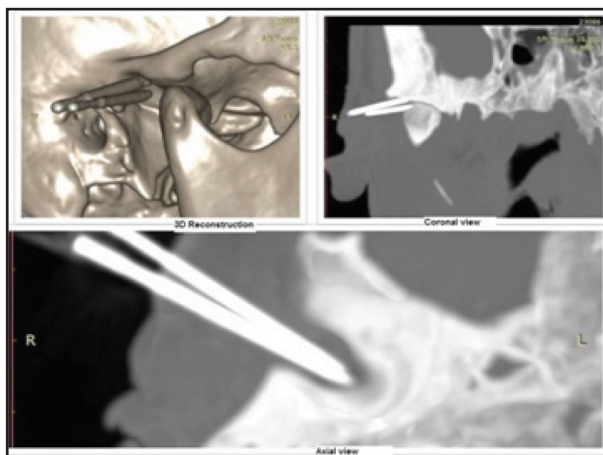
Group II**Multi slice CT imaging protocol:**

The patient lay in supine position on the CT table and was instructed not to move or swallow. The scan started at the level of inferior orbital margin and ended at the level of tip of the chin. The external auditory canals were included in the scan area. Slice thickness and slice interval for acquisition were 0.5-1 mm. After insertion of the first needle, a confirmatory axial cut was performed in multi slice mode to confirm the position of needle in the superior joint space. If the tip of the needle was in the joint space below the imaginary line between the lateral aspect of articular eminence and lateral

aspect of post glenoid process beneath roof of the glenoid fossa, the needle position was acceptable while when needle tip was outside these margins, it was an unacceptable position. The second was then placed at D point. Accurate placement was confirmed by sagittal, coronal and 3D reconstruction.



Figure(1) Both needles inside joint space in different views



Figure(2) Photograph showing:
A) Laskin points B) arthrocentesis

Postoperative instructions

1. Medications: Panadol tab every 8hours for 3days (Paracetamol).
2. Ice packs application for 24hours postoperatively then hot packs for 4days 4 times daily.
3. Soft diet and exercises of range of movement for first week.
4. Dental hygiene maintained using soft tooth brush.

Follow up phase

Patients were asked to return for follow up after one week, one month, three months and six months for clinical evaluation of pain level, MIO, lateral, protrusive movements, joint tenderness and disk position with MRI after 6 months.

Statistical analysis was then performed using a commercially available software program (SPSS 19; SPSS, Chicago, IL, USA). Qualitative data e.g frequency of tenderness was compared using chi square test. Values of pain score in different observations showed a non-parametric distribution and were compared within the same group using Friedman test. Mann Whiney U test was used to compare both groups.

RESULTS

The study included 20 patients, with 30 treated joints. Patients were 18 females (90%) and 2 males (10%).

In both group, pain score gradually decreased postoperatively. Friedman test showed that this discrepancy was extremely statistically significant ($P < 0.0001$), that the discrepancy between both groups was not statistically significant. It decreased from 8.40 to 5.20, 2.10, 1.50, and 1.00 in group I and from 8.5 to 3.9, 1.3, 1.0, and 0.7 in group II. The discrepancy between both groups was not statistically significant with only higher mean value was recorded in conventional group at first week.

MIO in both groups gradually increased post-operatively. ANOVA test revealed that this discrepancy was extremely statistically significant ($P < 0.0001$). The discrepancy between both groups was not statistically significant (Table 1).

Table (1) Comparison of MIO between conventional and CT groups in different observations (independent t test)

Time	Conventional		CT		t	P
	Mean	Std. Dev	Mean	Std. Dev		
Pre-operative	27.2	2.098	29.40	2.59	2.08	0.051ns
One week	35.50	3.206	35.00	2.91	0.36	0.72ns
One month	38.8	2.573	38.60	3.66	0.14	0.89ns
3 months	41.0	3.432	40.70	3.83	0.18	0.86ns
Six months	43.0	4.472	42.40	4.43	0.30	0.77ns

Significance level $P < 0.05$, ns=non-significant

In both groups, frequency of tenderness gradually decreased post-operatively, was completely absent after 1, 3 or 6 months pre-operatively, this was extremely statistically significant discrepancy from preoperative ($P < 0.0001$). It decreased from (100%) to (70%), 0, 0, 0 in group I and from 100% to 40%, 0, 0, 0 in group II period and the discrepancy between both groups was not statistically significant with only a higher incidence of tenderness in the conventional group at one week.

In both groups lateral movement towards unaffected side gradually increased post-operatively, this discrepancy was extremely statistically significant from preoperative ($P < 0.0001$). It increased from 7.4 to 7.4, 9.0, 10.1, and 10.1 in group I and from 8.20 to 8.70, 9.70, 10.40, 10.90 in group II and the discrepancy between both groups was not statistically significant and protrusive movement showed gradual increase post operatively in both groups through follow up period. It increased from 7.40 to 8.10, 9.1, 9.9, and 10.6 in group I and from 5.50 to 6.20, 7.10, 7.90, and 8.80 in group II. This discrepancy between both groups was extremely statistically significant ($P < 0.0001$). Preoperatively, a slightly higher mean value was recorded in conventional group, with a statistically significant discrepancy ($p = 0.007$). Postoperatively, a significantly higher mean value was recorded in conventional group at 1 week ($p = 0.009$), 1 month

($p = 0.013$), 3 months ($p = 0.012$) and 6 months ($p = 0.035$).

MRI outcome

After six months, no change in disc position was found in both groups. After one year, 10 joints were followed up through our study; five joints in each group and we found disc position was normal in 80% of conventional group, in comparison to 60% of CT group. Chi square test showed that this difference was not statistically significant ($p = 0.21$).

DISCUSSION

PRGF was used in present study, as it a biologic mediators released by the platelets⁽¹⁵⁾ and completely endogenous. It has growth factors which enhance rapid neoangiogenesis to repair the damaged tissues and chemiotaxis for the macrophages and the fibroblasts which differentiate and mature to heal the inflamed and damaged tissues. It also has hepatocyte growth factor which eliminates pain and its action leads to the neoangiogenesis induced from the presence of heparin liberated by the mastocytes present in the damaged tissues⁽²²⁾. It is prepared by single spin technique and the leukocyte content is removed to evade the proinflammatory effects of the proteases and acid hydroxylases contained in neutrophils which is necessary in the treatment of

the musculoskeletal system because their presence might not yield the optimal anabolic environment for disease treatment⁽²³⁾⁽²⁴⁾. It is associated with an absence or reduction in postsurgical inflammation⁽²⁵⁾ and this was agreed with many authors^(15,26-29). PRGF treatment (single spin) versus leukocyte enriched PRP prepared by double centrifugation was used in patients with knee OA and PRGF injections led to a statistically significant improvement in all the scores at every follow up and leukocytes enriched PRP induced more significant adverse events as pain and swelling⁽³⁰⁾.

All patients in our study underwent arthrocentesis to prepare joint to receive the maximum effect of PRGF as it eliminates chemical inflammatory mediators in the synovial fluid^(8,31,32) and decreases the level of inflammatory cytokines, degraded proteins⁽³³⁾ and arachidonic acid metabolites⁽³⁴⁾. It also increases mandibular mobility by eliminating the negative pressure within the joint⁽³⁵⁾ and breaking down joint adhesions⁽³¹⁾ by the hydraulic pressure created by the irrigation⁽³⁶⁾.

Laskin⁽¹¹⁾ anatomical landmark for TMJ puncture was used in our study for all cases as it is much easier, access to the anterior recess of TMJ is not essential and the entire joint did not need to be visualized during arthrocentesis versus arthroscopy.

Imaging guidance is useful during puncture to allow verification of delivery of medication into the joint and to decrease the possible dangerous complications^(37,38). CT gives good bony anatomical details^(14,39) and gives reassurance for the operator regarding tip position and helps with needle tip optimization⁽¹⁴⁾.

CT was used in our study to confirm accurate position, angulation, depth of the needles inside the joint in different views with less puncture trials and verification of delivery of medication into the joint. We used single injection of PRGF as many authors used it in the treatment of internal derangement^(26,27).

Statistical analysis of demographic data showed higher prevalence in females which agrees with many studies^(26,40,41). Statistical analysis of pain on VAS showed gradual decrease post-operatively through follow up period in both groups and this discrepancy was extremely statistically significant ($P < 0.0001$). It decreased from 8.40 to 5.20, 2.10, 1.50, 1.00 in group I and from 8.5 to 3.9, 1.3, 1.0, 0.7 in group II.

Statistical analysis of frequency of tenderness showed gradual decrease postoperatively in both groups through follow up period and was completely absent after 1, 3 or 6 months. This discrepancy was statistically significant, it decreased from (100%) to (70%), 0 in group I and from 100% to 40%, 0 in group II period. The discrepancy between both groups was not statistically significant with only higher mean value recorded in conventional group at first week due to less puncture trails in CT group as there is strong relationship between postoperative pain and TMJ puncture as TMJ puncture itself can cause temporary synovial and soft tissue inflammation and this is in agreement with another study⁽¹³⁾.

Statistical analysis of the maximum mouth opening showed gradual increase in both groups through follow up period, this discrepancy was extremely statistically significant ($P < 0.0001$). It increased from 27.2 to 35.50, 38.8, 41.0, 43.0 in group I and from 29.40 to 35.00, 38.60, 40.70, 42.2 in group II. The discrepancy between both groups was not statistically significant and this agreed with another study⁽¹³⁾.

In spite of improvement in all scores of clinical outcomes through follow up period in both groups, MRI showed no statistical significant change in MRI disc position at 6 months and this is agreement with many authors^(42,43). On the other hand five cases with ten joints followed up for one year through our study and found change in MRI disc position so we recommend MRI follow up at one year and this agreed with many authors^(44,45).

CONCLUSION

From this study it was concluded that; CT confirmed, assured accurate position, angle and depth within upper cavity in different views and allowed correction with less puncture trials which affect early postoperative outcomes as pain and tenderness. It decreased learning curve of TMJ puncture for beginners to achieve skill with ease imagination for TMJ cavity but it is expensive ,time consuming and not available in clinics. Anatomical landmarks is easy and representable method for TMJ puncture, but it is a blind technique and needs skill. Single injection of PRGF was found efficient and safe in the treatment of internal derangement of TMJ. It showed significant gradual improvement in all scores through follow up.

REFERENCES

- Al-Moraissi EA. Arthroscopy versus arthrocentesis in the management of internal derangement of the temporomandibular joint : a systematic review and. *Int J Oral Maxillofac Surg*. 2014; 44:104-12.
- Dupuy-Bonafé I, Picot MC, Maldonado IL, Lachiche V, Granier I, Bonafé A. Internal derangement of the temporomandibular joint: Is there still a place for ultrasound? *Oral Surg Oral Med Oral Pathol Oral Radiol*.2012;113:832-40.
- Gauer RL, Semidey MJ. Diagnosis and treatment of temporomandibular disorders. *Am Fam Physician*. 2015; 91:378-86.
- Aiken A, Bouloux G, Hudgins P. MR Imaging of the Temporomandibular Joint. *Magn Reson Imaging Clin N Am*. 2012;20:397-412.
- Ungor C, Atasoy ĀKT, Taskesen ĀF. Long-Term Outcome of Arthrocentesis Plus Hyaluronic Acid Injection in Patients With Wilkes Stage II and III Temporomandibular Joint Internal Derangement. *J Craniofac Surg*. 2015;26:2104-8.
- Jamot SR, Khan ZA, Khan TU, Waraich RA, Farooq M. Arthocentesis for temporomandibular joint pain dysfunction syndrome. *Ayub Med Coll Abbottabad*.2017;29(1):54-57.
- Monje-Gil F, Nitzan D, González-García R. Temporomandibular joint arthrocentesis. Review of the literature. *Medicina Oral, Patología Oral y Cirugía Bucal*. 2012;17: 575-81.
- Neeli AS, Umarani M. Arthrocentesis for the Treatment of Internal Derangement of the Temporomandibular Joint. *J. Maxillofac Oral Surg* . 2011;9:350-4.
- Malik AH. Internal derangement of temporomandibular joint : role of arthrocentesis with steroid. 2014;1:29-32.
- Nitzan DW, Dolwick MF, Martinez GA. Temporomandibular Joint Arthrocentesis: *J Oral Maxillofac Surg*.1991; 49:1163-7.
- Carvajal WA, Laskin DM. Long-term evaluation of arthrocentesis for the treatment of internal derangements of the temporomandibular joint. *J Oral Maxillofac Surg*. 2000;58:852-5.
- Cahill AM, Baskin KM, Kaye RD, Arabshahi B, Cron RQ, Dewitt EM, et al. CT-guided percutaneous steroid injection for management of inflammatory arthropathy of the temporomandibular joint in children. *Am J Roentgenol*. 2007;188:182-6.
- Matsumoto K, Bjørnland T, Kai Y, Honda M, Yonehara Y, Honda K. An image-guided technique for puncture of the superior temporomandibular joint cavity: Clinical comparison with the conventional puncture technique. *Oral Surg, Oral Med Oral Pathol Oral Radiol Endodonto*. 2011;111:641-8.
- Parra DA, Chan M, Krishnamurthy G, Spiegel L, Amaral JG, Temple MJ, et al. Use and accuracy of US guidance for image-guided injections of the temporomandibular joints in children with arthritis. *Pediatr Radiol*. 2010; 40:1498-504.
- Giacomello M, Giacomello A, Mortellaro C, Gallesio G, Mozzati M. Temporomandibular joint disorders treated with articular injection: the effectiveness of plasma rich in growth factors-Endoret. *J Craniofac Surg*. 2015;26:709-13.
16. Torul D, Bereket MC, Onger ME, Altun G. Comparison of the Regenerative Effects of Platelet-Rich Fibrin and Plasma Rich in Growth Factors on Injured Peripheral Nerve: An Experimental Study. *J Oral Maxillofac Surg*. 2018;76:1-12.
- Anitua E, Orive G. Endogenous regenerative technology using plasma- and platelet-derived growth factors. *J Control Release*. 2012;157:317-20.
- Martino MM, Briquez PS, Ranga A, Lutolf MP, Hubbell JA. Heparin-binding domain of fibrin(ogen) binds growth factors and promotes tissue repair when incorporated within a synthetic matrix. *Proc Natl Acad Sci*. 2013; 110:4563-8.

19. Borselli C, Storrie H, Benesch-Lee F, Shvartsman D, Cezar C, Lichtman JW, et al. Functional muscle regeneration with combined delivery of angiogenesis and myogenesis factors. *Proc Natl Acad Sci.* 2010; 107:3287-92.
20. Anitua E, Prado R, Azkargorta M, Rodriguez-Suárez E, Iloro I, Casado-Vela J, et al. High-throughput proteomic characterization of plasma rich in growth factors (PRGF-Endoret)-derived fibrin clot interactome. *J Tissue Eng Regen Med.* 2015;9:E1-12.
21. Holmlund A, Hellsing G. Arthroscopy of the temporomandibular joint. An autopsy study. *Int J Oral Surg.* 1985;14:169-75.
22. Powell RJ, Goodney P, Mendelsohn FO, Moen EK, Annex BH. Safety and efficacy of patient specific intramuscular injection of HGF plasmid gene therapy on limb perfusion and wound healing in patients with ischemic lower extremity ulceration: Results of the HGF-0205 trial. *J Vasc Surg.* 2010;52:1525-30.
23. McCarrel TM, Minas T, Fortier LA. Optimization of leukocyte concentration in platelet-rich plasma for the treatment of tendinopathy. *J Bone Jt Surg - Ser A.* 2012 ;94:1-8.
24. Anitua E, Sánchez M, Orive G, Padilla S. A biological therapy to osteoarthritis treatment using platelet-rich plasma. *Expert Opin Biol Ther.* 2013;13:1161-72.
25. Mozzati M, Gallesio G, Arata V, Pol R, Scoletta M. Platelet-rich therapies in the treatment of intravenous bisphosphonate-related osteonecrosis of the jaw: A report of 32 cases. *Oral Oncol.* 2012; 48:469-74.
26. Sanromán FJ, Ferro FM, López CA, Bua AJ, López A. Does injection of plasma rich in growth factors after temporomandibular joint arthroscopy improve outcomes in patients with Wilkes stage IV internal derangement? A randomized prospective clinical study. *Int J Oral Maxillofac Surg.* 2016;45:828-35.
27. Ferro FM, Sanromán FJ, Carrión BA, López CA, Betancourt LA, Bua AJ, et al. Comparison of intra-articular injection of plasma rich in growth factors versus hyaluronic acid following arthroscopy in the treatment of temporomandibular dysfunction: A randomised prospective stud. *J Cranio Maxillo Facial Surg.* 2017; 45:449-454.
28. Sánchez M, Fiz N, Azofra J, Usabiaga J, Aduriz Recalde E, Garcia Gutierrez A, et al. A randomized clinical trial evaluating plasma rich in growth factors (PRGF-Endoret) versus hyaluronic acid in the short-term treatment of symptomatic knee osteoarthritis. *Arthrosc - J Arthrosc Relat Surg.* 2012;28:1070-8.
29. Seijas R, Padilla S, Ph D, Orive G, et al. Comparison of Intra-Articular Injections of Plasma Rich in Growth Factors (PRGF-Endoret) Versus Durolane Hyaluronic Acid in the Treatment of Patients With Symptomatic Osteoarthritis: A Randomized Controlled Trial. *Arthrosc J Arthrosc Relat Surg.* 2013;29:1635-43.
30. Filardo G, Kon E, Pereira Ruiz MT, Vaccaro F, Guitaldi R, Di Martino A, et al. Platelet-rich plasma intra-articular injections for cartilage degeneration and osteoarthritis: Single- versus double-spinning approach. *Knee Surgery, Sport Traumatol Arthrosc.* 2012;20:2082-91.
31. Şentürk MF, Yazıcı T, Gülşen U. Techniques and modifications for TMJ arthrocentesis : a literature review. *CRANIO.* 2017;9634:1-9.
32. Abdullah SN, Ragab HR. Comparative study of arthrocentesis with or without using piroxicam in the management of temporomandibular joint. 2015;40:160-5.
33. McCain JP, Hossameldin RH, Srouji S, Maher A. Arthroscopic discopexy is effective in managing temporomandibular joint internal derangement in patients with wilkes stage II and III. *J Oral Maxillofac Surg.* 2015;73:391-401.
34. Nishimura M, Segami N, Kaneyama K, Sato J, Fujimura K. Comparison of Cytokine Level in Synovial Fluid between Successful and Unsuccessful Cases in Arthrocentesis of the Temporomandibular Joint. *J Oral Maxillofac Surg.* 2004; 62:284-7.
35. Kaneyama K, Segami N, Nishimura M, Sato J, Fujimura K, Yoshimura H. The ideal lavage volume for removing bradykinin, interleukin-6, and protein from the temporomandibular joint by arthrocentesis. *J Oral Maxillofac Surg.* 2004;62:657-61.
36. Grossmann E, Guilherme P, Pasqual V, Poluha RL, Cristina L, Iwaki V, et al. Single-Needle Arthrocentesis with Upper Compartment Distension versus Conventional Two-Needle Arthrocentesis : Randomized Clinical Trial. *Pain Res Manag* 2017; 2017:2435263
37. Soh E, Li W, Ong KO, Chen W, Bautista D. Image-guided versus blind corticosteroid injections in adults with shoulder pain : A systematic review. *BMC Musculoskelet Disord.* 2011;12:137.
38. Sivri MB, Ozkan Y, Pekiner FN, Gocmen G. Comparison of ultrasound-guided and conventional arthrocentesis of the temporomandibular joint. *Br J Oral Maxillofac Surg.* 2016;54:677-81.

39. Habibi S, Ellis J, Strike H, Ramanan A V. Safety and efficacy of US-guided CS injection into temporomandibular joints in children with active JIA. *Rheumatology*. 2012;51:874-7.
40. Wieckiewicz M, Grychowska N, Wojciechowski K, Pelc A, Augustyniak M, Sleboda A, et al. Prevalence and correlation between TMD based on RDC/TMD diagnoses, oral parafunctions and psychoemotional stress in Polish University students. *Biomed Res Int*. 2014;2014:472346.
41. Zwiri AMA, Al-omiri MK. Prevalence of temporomandibular joint disorder among North Saudi University students. *Cranio* 2015;34:176-81.
42. Riu G De, Stimolo M, Meloni SM, Soma D, Pisano M, Sembronio S, et al. Arthrocentesis and Temporomandibular Joint Disorders : Clinical and Radiological Results of a Prospective Study. *Int J Dent* 2013;2013. 790648.
43. Aktas I, Yalcin S, Sencer S. Intra-articular injection of tenoxicam following temporomandibular joint arthrocentesis: a pilot study. *Int J Oral Maxillofac Surg*. 2010;39:440-5.
44. Cai XY, Jin JM, Yang C. Changes in disc position, disc length, and condylar height in the temporomandibular joint with anterior disc displacement: A longitudinal retrospective magnetic resonance imaging study. *J Oral Maxillofac Surg*. 2011;69:340-6.
45. Lee S, Yoon H. MRI Findings of Patients With Temporomandibular Joint Internal Derangement : Before and After Performance of Arthrocentesis and Stabilization Splint. *YJOMS*. 2009;67:314-7.