

THE EVALUATION OF PROTECTIVE ROLE OF GARLIC EXTRACT AND VITAMIN C AGAINST SUBCHRONIC TOXICITY OF CYPERMETHRIN INSECTICIDES ON THE LIVER AND KIDNEYS OF ADULT ALBINO RATS

Dalia M. Amin; Hany A. Meleka; Nadraa K. Ali and Mahmoud W. Emara *

Forensic Medicine and Clinical Toxicology and Pathology Departments*

Faculty of Medicine – Zagazig University – Egypt

ABSTRACT

Introduction: Cypermethrin toxicity has been a subject of extensive studies because of its world widespread distribution. The major source of cypermethrin in the human body is through intake of food and water. **Aim of the Work:** This work was performed to study the protective role of garlic extract and vitamins C on the toxic effects of cypermethrin on the liver and kidneys of adult albino rats. **Materials and Methods:** This study was carried out on 126 adult albino rats for 12 weeks and gavaged 6 days / weeks. The rats were divided into 7 groups each of 18 rats; Group I (control group), Group II (garlic extract group): each rat was gavaged orally with 500 mg/kg vitamin C dissolved in (1 ml) distilled water once daily and Group III (vitamin C group): each rat was gavaged orally with 20 mg/kg vitamin C dissolved in (1 ml) distilled water once daily. Group IV (cypermethrin group): Each rat was gavaged orally with 32.5 mg/kg in (1 ml) distilled water once daily. Group V (Cypermethrin and garlic extract group): Each rat was gavaged orally with in the previous dose once daily. Group VI (Cypermethrin and vitamin C group): Each rat was gavaged orally with cypermethrin and vitamin C in the previous doses once daily. Group VII (Cypermethrin, vitamin C and garlic extract group): Each rat was gavaged orally with cypermethrin, garlic extract and vitamin C in the previous doses. **Results:** there was a significant increase in the mean values of AST, ALT, ALP, urea and creatinine in cypermethrin treated group when compared with control group (I). Upon supplementation with garlic extract or vitamin C alone or combined to cypermethrin treated rats there was a significant decrease in the mean values of AST, ALT, ALP, urea and creatinine, when compared with cypermethrin treated group. Microscopic examination of cypermethrin treated groups of liver revealed vacuolated hepatocytes, focal necrosis, and aggregates of inflammatory cells, dilated congested central vein, enlarged portal tract with dilated congested blood vessels and bile duct proliferation, areas of hemorrhage and disturbed hepatic lobular architecture. Microscopic examination of cypermethrin treated groups of kidneys revealed congestion and hemorrhage; dilated tortuous tubules lined by vacuolated epithelium and destructed renal corpuscles with wide Bowman's space. Immunohistochemical examination for detection of BAX protein in hepatic and renal tissues showed strong positive brown reaction in cypermethrin treated group when compared with control group (I) showed negative reaction. Upon supplementation with garlic extract or vitamin C alone or combined to cypermethrin treated rats there was a significant improvement with moderate to faint brown reaction respectively. **Conclusion:** Cypermethrin toxicity induced liver and kidneys damage in adult albino rats, and concomitant administration of either garlic extract or vitamin C or both was efficient in protecting liver and renal tissues.

Recommendation: it is recommended to increase public awareness regarding the health impact of cypermethrin and the protective role of garlic extract or vitamins C on its toxicities.

Key Words: Cypermethrin; liver; kidneys; hepatotoxicity; nephrototoxicity; oxidative stress; garlic extract and vitamin C.

Corresponding author: Dr. Dalia Amin

Email: Daliaamin013@gmail.com

Mobile: 01141452918

INTRODUCTION

Pesticide poisoning is an important cause of morbidity and mortality in developing countries. Every year there are three million cases of severe poisoning and 220,000 deaths. The toxicity of pyrethroid insecticides to mammalian animals has received much

attention in recent years because they have a widespread use in agriculture, domestic and veterinary applications and also the animals exposed to these insecticides exhibit changes in their physiologic activities beside other pathologic changes (Abdel-Rahim et al., 2009).

Synthetic pyrethroids comprise more than 1000 powerful broad spectrum insecticides and they are environmentally compatible due to their moderate persistence, low volatility and poor aqueous mobility in soil. They represent approximately one fourth of the worldwide insecticide market due to their high efficacy and enhanced stability. Cypermethrin belongs to the group of pyrethroids, classified by the world health organization as class II, moderately hazardous insecticides (**Rodriguez et al., 2009**).

Cypermethrin is the most widely used type II synthetic pyrethroid pesticide. Consistent with its lipophilic nature, cypermethrin has been accumulated in body fat, skin, brain, liver, kidneys, adrenals, testicles and ovaries. The cypermethrin toxicity is due to interaction with sodium channels in the nerve cells, making these channels in open configuration, thus generating repeated nerve impulses in the affected organs (**Kakko et al., 2008**).

Chemoprevention against oxidative stress can be obtained by the administration of one or more chemical entities, either as individual drugs or as naturally occurring dietary constituents such as vitamin C and garlic extract providing anti-oxidant cellular protection against cellular membrane oxidative toxicity derived from cypermethrin administration (**Wilson, 2004**).

The aim of this study was to demonstrate some changes in livers and kidneys of adult albino rats intoxicated sub chronically with cypermethrin and to evaluate the possible protective role of garlic extract and vitamin C supplementation against these changes.

I- Material:

- 1) **Cypermethrin**. It was purchased from Sigma Chemical Co. (St Louis, Mo, USA). It was provided in a white powder form.
- 2) **Garlic extract**: It was purchased from SEKOM Herbal Company marketed as yellowish powder.
- 3) **Vitamin C**: In the form of white powder manufactured by EPICO pharmaceutical company, Egypt.

4) Distilled water: All the previous material were dissolved in this distilled water.

5) Detection kit:

The primary antibodies for the specific localization of BAX receptors in frozen sections, as well as, in formalin fixed and paraffin embedded tissue. They were delivered from Medco Pharma Trade Egypt (Ab-4(6A7), Code no. (Ms-714-Po).

6) Animals:

This study was carried on 126 adult albino rats, each weighing 150-200 gm. The animals were obtained from Animal House of the Faculty of Veterinary Medicine, Zagazig University. The study had been designed in the Faculty of Medicine, Zagazig University.

Study design:

The study was done for 3 months and the rats were divided into 7 groups each of 18 rats:-
- Group I (control group): Each rat received only regular diet and distilled water to determine the basic values of performance. These rats were left without intervention to measure the basic parameters.

-Group II (Garlic extract (G) group): Each rat was gavaged orally with 500 mg/kg body weight garlic extract dissolved in 1ml of distilled water once daily 6 days/ week (**Singh et al., 2008**).

- Group III (Vitamin C (C) group): Each rat was gavaged orally with 20 mg/kg body weight vitamin C dissolved in 1 ml of distilled water once daily 6 days/ week (**Khan and Sinha, 2008**).

- Group IV (cypermethrin (CYP) group): Each rat was gavaged orally with 32.5 mg/kg body weight (1/20 of LD50) of cypermethrin dissolved in 1ml of distilled water once daily 6 days/ week. **Grayson (2012)** reported Ld50 650mg/kg.

-Group V (Cypermethrin and garlic extract (CYP-G) group): Each rat was gavaged orally with (500mg/kg body weight garlic extract) 15min before (32.5 mg/kg body weight cypermethrin) once daily 6 days/ week.

-Group VI (Cypermethrin and vitamin C (CYP-C) group): Each rat was gavaged orally with (20 mg/kg body weight vitamin C 15 min

before oral gavage with (32.5 mg/kg body weight cypermethrin) once daily 6 days/ week .

-Group VII (Cypermethrin, vitamin C and garlic extract (CYP-G-C) group): Each rat was gavaged orally with (20 mg/kg body weight vitamin C+ 500 mg/kg body weight garlic extract 15 min before oral gavage with + 32.5 mg/kg body weight cypermethrin) once daily 6 days/ week.

II- Methods:

At the end of 12th week of the study period, rats from each group were subjected to blood sample collection from the retro-orbital plexuses. The blood samples will be used for estimating the following tests Liver function tests {serum aspartame aminotransferase (AST), serum alanine aminotransferase (ALT) and alkaline phosphatase (ALP)}, kidney function tests (urea and creatinine). Then the anesthetized rats were sacrificed & specimens from the liver and kidneys were taken for histopathological study.

(A) Liver enzymes:

Serum Alanine aminotransferase (ALT), Serum Aspartate aminotransferase (AST) and Serum Alkaline phosphatase (ALP) (IU/L): These enzymes were assayed as (Reitman and Frankel, 1957).

(B) Kidney functions:

(i) Blood Urea Nitrogen (BUN) (mg/dL): (Kaplan, 1965).

(ii) Serum creatinine (mg/dL): (Popper et al., 1937).

(C) Histopathological study by H & E:

The liver and kidneys specimens were routinely processed and sectioned at 4-5 μ m thickness. The obtained sections were stained by Haematoxylin and Eosin (H&E) according to Horobin and Bancroft (1998) then examined by light microscope.

(D) Immunohistochemical staining:

A mouse monoclonal antibody of IgG immunoglobulin type, designed for the specific localization of BAX receptors in frozen sections, as well as, in formalin fixed and paraffin embedded tissue. They were delivered from Medco Pharma Trade Egypt (Ab-4(6A7),

Code no. (Ms-714-Po). The sensitive universal immunostaining kit contained the following reagent and material (Shimizu et al., 2014).

(E) Statistical analysis:

The results were analyzed by ANOVA-test: for comparison of means of different groups (Dean et al., 2004).

Results:

(A) Biochemical results:

The biochemical findings of control groups were within normal values, in addition there were non significant difference in the levels of all tested biochemical parameters between control group (I) , garlic extract group (II) and vitamin C group (III), so we used group (I) for comparison with other treated groups (Tables 1 & 6).

There were highly significant differences in groups by (ANOVA) study ($P < 0.001$) as regard (alanine aminotransferase (ALT), aspartate aminotransferase (AST) and Alkaline phosphatase (ALP) values (Table 2).

The least significant difference (LSD) of (ALT, AST & ALP) among groups I, CYP (IV), G + CYP (V), C + CYP (VI) and G + C+CYP (VII) revealed that there was highly significant elevation in (ALT, AST & ALP) level in all groups when compared with control group (I) ($P < 0.001$). There was highly significant elevation in ALT in group CYP (IV) when compared with other groups of the study ($P < 0.001$). There was no significant difference in (ALT, AST & ALP) value between groups G+ CYP(V) and C + CYP (VI) groups G+ C+CYP(VII) ($P > 0.05$) (Table 3, 4, 5) (Fig. 1).

There were highly significant differences in groups by (ANOVA) study ($P < 0.05$) as regard Blood urea nitrogen (BUN) and Serum creatinine (Creat) (Table 7).

The least significant difference (LSD) of blood urea nitrogen (BUN & Creat) among control group (I), CYP (IV), G + CYP (V), C + CYP (VI) and G + C+CYP (VII) revealed that there was highly significant elevation in (BUN & Creat) level in all groups when compared with control group (I) of the study ($P < 0.001$). There was highly significant elevation in BUN in group CYP (IV) when

compared with other groups of the study ($P < 0.001$). There was no significant difference in BUN value between groups G+ CYP(V) and C + CYP (VI) and G+ C+ CYP (VII) ($P > 0.05$) (Table 8, 9) (Fig. 2,3).

(B) Histopathological study:

(1) Histopathological changes of the liver:

Light microscopic examination of H&E stained sections from the livers of the control groups (Groups I, II and III) revealed that; the liver showed multiple polygonal classic hepatic lobules with tightly packed cords of hepatocytes radiating from central veins toward the periphery of the lobules where the portal area is noticed. It contains the pre terminal branches of the portal vein, hepatic artery, and bile duct. Polygonal hepatocytes with rounded vesicular nuclei and acidophilic cytoplasm. Some cells are binucleated. Blood sinusoids and their lining of endothelial and kupffer cells are observed between hepatocyte cords (Fig. 4)

In cypermethrin treated group the sections showed disturbed hepatic lobular architecture with hepatocytes showed vacuolated cytoplasm, focal necrosis, aggregates of chronic inflammatory cells, dilated congested central vein, enlarged portal tract with dilated congested blood vessels, bile duct proliferation and areas of hemorrhage (Fig. 5).

Examination of H&E stained sections of the liver specimens of the rats treated with garlic extract or vitamin C alone showed partial improvement of the changes that occurred after cypermethrin administration with almost normal lobular architecture and normal hepatocytes with average sized nuclei (Fig. 6).

While microscopic examination of the liver specimens of the rats treated with combined garlic extract and vitamin C showed near complete improvement of the changes that occurred after cypermethrin administration with almost normal lobular architecture. Congested blood vessels still present (Fig. 7).

Immunohistochemistry examination for detection of BAX protein apoptotic markers that appears as a cytoplasmic reaction brown in color. The stained sections from the livers of

the groups I, II and III showed no immunoreactivity within hepatocytes. Central vein (CV) and sinusoids (S) were noticed (Fig. 8).

In cypermethrin treated group the sections showed most hepatocytes with granular strong +ve brown reaction within cytoplasm (arrows) around central vein (CV) (Fig. 9).

Examination of sections of the liver specimens of the rats treated with garlic extract or vitamin C alone showed little restoration of the normal cellular structure. Most hepatocytes had granular nucleus and granular moderate brown reaction within cytoplasm (arrows) around central vein (CV) (Fig. 10).

While microscopic examination of the liver specimens of the rats treated with combined garlic extract and vitamin C showed restoration of the normal cellular structure. Most hepatocytes had granular nucleus and granular faint brown reaction within cytoplasm (arrows) around central vein (CV) (Fig. 11).

(2) Histopathological changes of the kidneys:

Light microscopic examination of H&E stained sections from the kidneys of the control groups (Groups I, II and III) revealed that; the kidneys showed normal cortex, medulla, interstitial tissue and blood vessels all over the period of the study. The cortex is formed of malpighian renal corpuscles which are formed of tuft of capillaries (Glomerulus) surrounded by Bowman's capsule. Proximal and distal tubules were normal; medulla was mostly formed of loop of Henle and collecting tubules (Fig. 12).

In cypermethrin treated group the sections showed congestion and hemorrhage, dilated tortuous tubules lined by vacuolated epithelium and destructed renal corpuscles with wide Bowman's space (Fig. 13).

Examination of H&E stained sections of the kidney specimens of the rats treated with garlic extract or vitamin C alone showed partial improvement of the changes that occurred after cypermethrin administration with showed minor congestion, dilated tortuous tubules lined by vacuolated epithelium, and shrinkage renal

corpuses with wide Bowman's space (**Fig. 14**).

While microscopic examination of the kidney specimens of the rats treated with combined garlic extract and vitamin C showed near complete improvement of the changes that occurred after cypermethrin administration almost normal glomeruli. Congested blood vessels still present. It showed fewer distorted Glomeruli and Bowman's capsule, and fewer vacuolar spaces (**Fig. 15**).

Immunohistochemistry examination for detection of BAX protein apoptotic markers revealed that stained sections from the kidneys of the control groups (Groups I, II and III) showed no immunoreactivity within nephrocytes. Glomeruli (G) and tubules (T) are noticed (**Fig. 16**).

In cypermethrin treated group the sections showed a nephrocyte showing granular strong +ve brown reaction within cytoplasm of most nephrocytes (arrows) glomeruli (G) and tubules (T) are noticed (**Fig. 17**).

Examination of sections of the kidney specimens of the rats treated with garlic extract or vitamin C alone showing little restoration of the normal cellular structure. The nephrocyte has granular nucleus and granular moderate brown reaction within cytoplasm of most nephrocytes (arrows) around glomeruli (G) and tubules (T) are noticed (**Fig. 18**).

While microscopic examination of the kidney specimens of the rats treated with combined garlic extract and vitamin C showing restoration of the normal cellular structure. The nephrocyte has granular nucleus and granular faint brown reaction within cytoplasm of most nephrocytes (arrows) around glomeruli (G) and tubules (T) are noticed (**Fig. 19**).

Table (1): A statistical comparison between control group "I", (G) group "II" and (C) group "III" as regard mean values of liver enzymes (ALT, AST and ALP) after 12 weeks in adult albino rats by ANOVA test.

| | Control (I) | Garlic extract (II) | Vitamin C (III) | F | P |
|-----------|----------------|---------------------|-----------------|-------|--------|
| | Mean \pm SD | | | | |
| | 12 weeks | | | | |
| ALT (U/L) | 24.5 \pm 1.5 | 24 \pm 3.4 | 29 \pm 5.3 | 3.25 | 0.067# |
| AST (U/L) | 43.3 \pm 7.9 | 44.1 \pm 5.8 | 40 \pm 6.3 | 0.626 | 0.548# |
| ALP (U/L) | 60 \pm 4.1 | 57 \pm 4 | 55.7 \pm 3.3 | 2 | 0.169# |

SD = Standard Deviation.
$p > 0.05$ = non significant

Table (2): A statistical comparison between control group “I” and treated group CYP “IV”, CYP+G “V”, CYP +C“VI”, CYP+G+C “VII” as regard mean values of liver enzymes (ALT, AST and ALP) after 12 weeks adult albino rats along the period of the study by ANOVA test.

| | Control | CYP | CYP-G | CYP-C | CYP-G-C | F | P |
|-----------------------|------------------|----------------------|---------------------|--------------------|--------------------|--------|----------|
| | (I) | (IV) | (V) | (VI) | (VII) | | |
| Mean ± SD 12 weeks | | | | | | | |
| ALT (U/L) | 24.5 ± 1.5 | 97.33 ± 6.71 | 30.50 ± 6.15 | 26.00 ± 1.75 | 23.83 ± 5.91 | 187.91 | <0.001** |
| AST (U/L) | 43.3 ± 7.9 | 145.50 ± 32.52 | 47.00 ± 4.00 | 55.66 ± 8.84 | 40.66 ± 9.83 | 30.60 | <0.001** |
| ALP (U/L) | 60 ± 4.1 | 586.66 ± 83.10 | 74.16 ± 14.74 | 75.66 ± 8.82 | 60.50 ± 9.35 | 175.84 | <0.001** |

SD = Standard Deviation.

** = highly significant.

CYP= cypermethrin.

G= garlic extract.

C= vitamin C .

Table (3): Least significance difference (LSD) among the control (I), (CYP) IV, (CYP+ G) V, (CYP+ C) VI and (CYP+ G+ C) VII groups as regard alanine aminotransferase enzyme ALT values after 12 weeks of the study.

| ALT (IU/L) | I | (CYP) IV | V(CYP-G) | VI(CYP-C) | VII(CYP-G-C) |
|---------------|-----------------------|--------------------|--------------------|--------------------|--------------------|
| | Mean ± SD 12 weeks | | | | |
| | 24.5 ± 1.5 | 97.33 ± 6.71 | 30.50 ± 6.15 | 26.00 ± 1.75 | 23.83 ± 5.91 |
| I | | 0.00** | 0.43# | 0.14# | 0.79# |
| IV | | | 0.00** | 0.00** | 0.00** |
| V | | | | 0.11# | 0.08# |
| VI | | | | | 0.40# |

** = highly significant (P<0.001).

#= Non-significance (P>0.05).

CYP= cypermethrin.

G= garlic extract.

C= vitamin C.

Table (4): Least significance difference (LSD) among the control (I), (CYP) IV, (CYP+ G) V, (CYP+ C) VI and (CYP+ G+ C) VII groups as regard aspartate aminotransferase enzyme AST values after 12 weeks of the study.

| AST (IU/L) | I | (CYP) IV | V(CYP-G) | VI(CYP-C) | VII(CYP-G-C) |
|---------------|---------------------------|--------------------------|------------------------|------------------------|------------------------|
| | Mean \pm SD 12 weeks | | | | |
| | 43.3 \pm 7.9 | 145.50 \pm 32.52 | 47.00 \pm 4.00 | 55.66 \pm 8.84 | 40.66 \pm 9.83 |
| I | | 0.00** | 0.33# | 0.29# | 0.61# |
| IV | | | 0.00** | 0.00** | 0.00** |
| V | | | | 0.054# | 0.17# |
| VI | | | | | 0.19# |

** = highly significant (P<0.001).

#= Non-significance (P>0.05).

CYP= cypermethrin.

G= garlic extract.

C= vitamin C.

Table (5): Least significance difference (LSD) among the control (I), (CYP) IV, (CYP+ G) V, (CYP+ C) VI and (CYP+ G+ C) VII groups as regard alkaline phosphatase enzyme ALP values after 12 weeks of the study.

| ALP (IU/L) | I | (CYP) IV | V(CYP-G) | VI(CYP-C) | VII(CYP-G-C) |
|---------------|---------------------------|--------------------------|-------------------------|------------------------|------------------------|
| | Mean \pm SD 12 weeks | | | | |
| | 60 \pm 4.1 | 586.66 \pm 83.10 | 74.16 \pm 14.74 | 75.66 \pm 8.82 | 60.50 \pm 9.35 |
| I | | 0.00** | 0.47# | 0.30# | 0.50# |
| IV | | | 0.00** | 0.00** | 0.00** |
| V | | | | 0.83# | 0.08# |
| VI | | | | | 0.16# |

** = highly significant (P<0.001).

#= Non-significance (P>0.05).

CYP= cypermethrin.

G= garlic extract.
C= vitamin C .

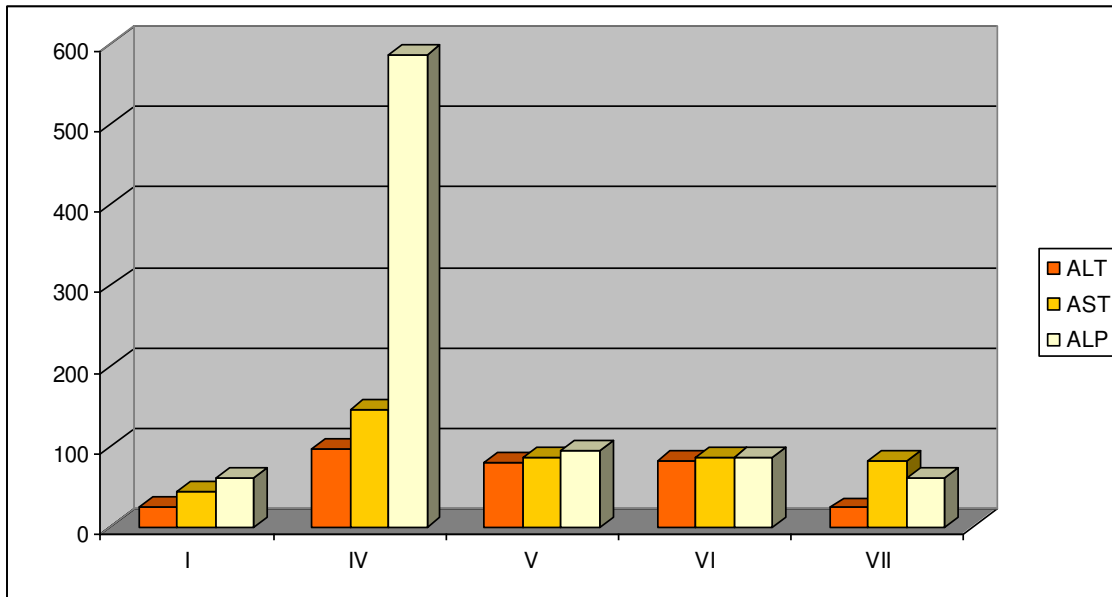


Fig. (1): Bar chart showing comparative magnitude of mean values of liver enzymes (ALT, AST & ALP) at different groups control group (I), cypermethrin treated group (IV), garlic extract & cypermethrin group (V), vitamin C & cypermethrin group (VI) and garlic extract & vitamin C and cypermethrin group (VII) after 12 weeks of the study.

Table (6): A statistical comparison between control group "I", G group "II" and C group III as regard mean values of kidney function (BUN & serum creatinine) after 12 weeks in adult albino rats by ANOVA test.

| | Control (I) | Garlic extract (II) | Vitamin C (III) | F | P |
|---------------------------------|---------------------------|---------------------|-----------------|-------|--------|
| | Mean \pm SD 12 weeks | | | | |
| BUN (mg/dl) | 16.5 \pm 1.5 | 16.1 \pm 1.4 | 16 \pm 1.04 | 0.238 | 0.791# |
| serum creatinine (mg/dl) | 0.43 \pm 1.77 | 0.46 \pm 1.9 | 0.47 \pm 1.01 | 0.001 | 0.999# |

SD = Standard Deviation.
$p > 0.05$ = non significant

Table (7): Statistical comparison among the control (I), cypermethrin (IV/CYP), cypermethrin and garlic extract (V/ CYP-G), cypermethrin and vitamin C (VI/CYP- C) and cypermethrin , garlic extract and vitamin C (CYP- G- C) groups as regard blood urea nitrogen and serum creatinine levels along the periods of the study by ANOVA test.

| | Control (I) | CYP (IV) | CYP- G (V) | CYP- C (VI) | CYP -G-C (VII) | F | P |
|-------------------------------------|-------------------|--------------------|--------------------|--------------------|----------------------|-------|----------|
| | Mean ± SD | | | | | | |
| | 12 weeks | | | | | | |
| BUN (mg/dl) | 16.5 ± 1.5 | 68.16 ± 9.53 | 17.33 ± 3.07 | 29.00 ± 5.09 | 26.50 ± 1.76 | 91.11 | <0.001** |
| Serum creatinine (mg/dl) | 0.43 ± 1.77 | 0.70 ± 3.12 | 0.31 ± 0.07 | 0.23 ± 1.08 | 0.18 ± 1.07 | 39.96 | <0.001** |

SD = Standard Deviation.

** = highly significant.

CYP= cypermethrin.

G= garlic extract.

C= vitamin C.

Table (8): Least significance difference (LSD) among the control (I), (CYP) IV, (CYP- G) V, (CYP- C) VI and (CYP-G - C) VII groups as regard BUN values after 12 weeks of the study.

| BUN (mg/dL) | I | (CYP) IV | V(CYP-G) | VI(CYP-C) | VII(CYP- G-C) |
|----------------|------------|--------------------|--------------------|--------------------|--------------------|
| | Mean ± SD | | | | |
| | 12 weeks | | | | |
| | 16.5 ± 1.5 | 68.16 ± 9.53 | 17.33 ± 3.07 | 29.00 ± 5.09 | 26.50 ± 1.76 |
| I | | 0.00** | 0.56# | 0.27# | 0.31# |
| IV | | | 0.00** | 0.00** | 0.00** |
| V | | | | 0.50# | 0.57# |
| VI | | | | | 0.28# |

** = highly significant (P<0.001)

#= Non-significance (P>0.05).

CYP= cypermethrin.

G= garlic extract.

C= vitamin C.

Table (9): Least significance difference (LSD) among the control (I), (CYP) IV, (CYP-G) V, (CYP- C) VI and (CYP- G - C) VII groups as regard serum creatinine values after 12 weeks of the study.

| Serum creatinine (mg/dL) | I | (CYP) IV | V(CYP-G) | VI(CYP-C) | VII(CYP-G-C) |
|-----------------------------|---------------------------|-----------------------|-----------------------|-----------------------|-----------------------|
| | Mean \pm SD 12 weeks | | | | |
| | 0.43 \pm 1.77 | 0.70 \pm 3.12 | 0.31 \pm 0.07 | 0.23 \pm 1.08 | 0.18 \pm 1.07 |
| I | | 0.00** | 0.87# | 0.81# | 0.73# |
| IV | | | 0.00** | 0.00** | 0.00** |
| V | | | | 0.86# | 0.77# |
| VI | | | | | 0.93# |

** = highly significant (P<0.001)

#= Non-significance (P>0.05)

CYP= cypermethrin.

G= garlic extract.

C= vitamin C.

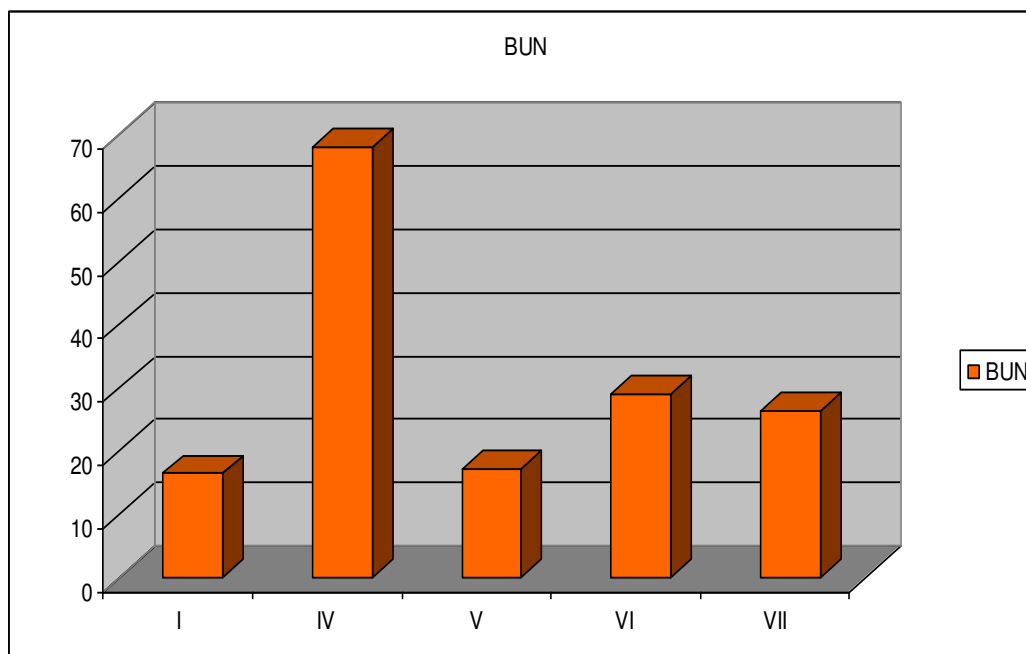


Fig. (2): Bar chart showing comparative magnitude of mean values of kidney functions (BUN) at different groups in control group (I), cypermethrin treated group (IV), garlic extract & cypermethrin group (V), vitamin C & cypermethrin group (VI) and garlic extract & vitamin C and cypermethrin group (VII) after 12 weeks of the study.

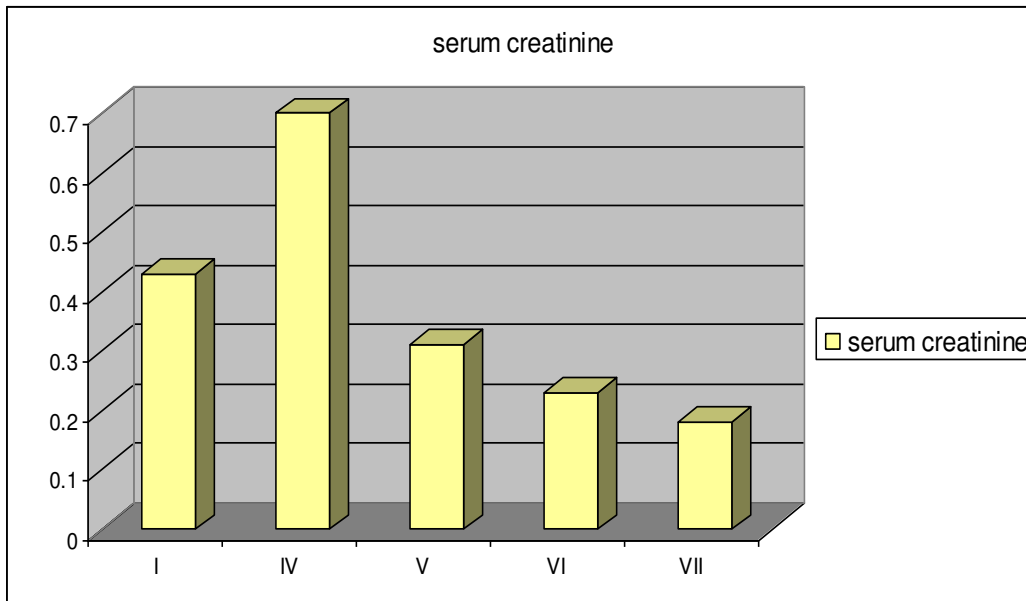


Fig. (3): Bar chart showing comparative magnitude of mean values of kidney functions (serum creatinine) at different groups in control group (I) ,cypermethrin treated group (IV) , garlic extract & cypermethrin group (V), vitamin C & cypermethrin group (VI) and garlic extract &vitamin C and cypermethrin group (VII) after 12 weeks of the study.

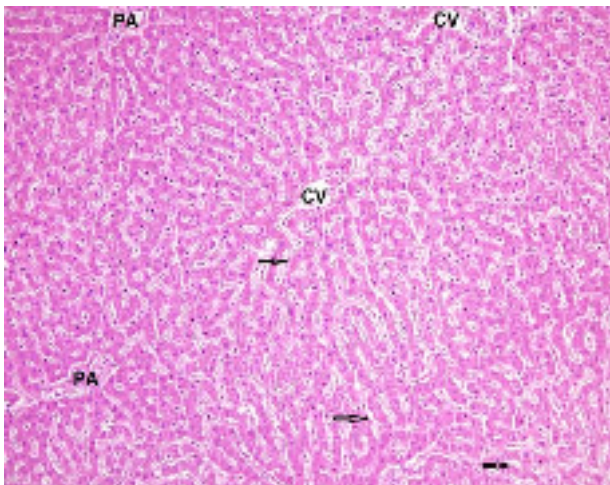


Fig (4): A photomicrograph of a section of liver of control adult albino rat showing a hexagonal hepatic lobule, consisting of cords of hepatocytes radiating from the central vein (CV) toward portal area (PA) kupffer cells (arrows) (H&E X 200).

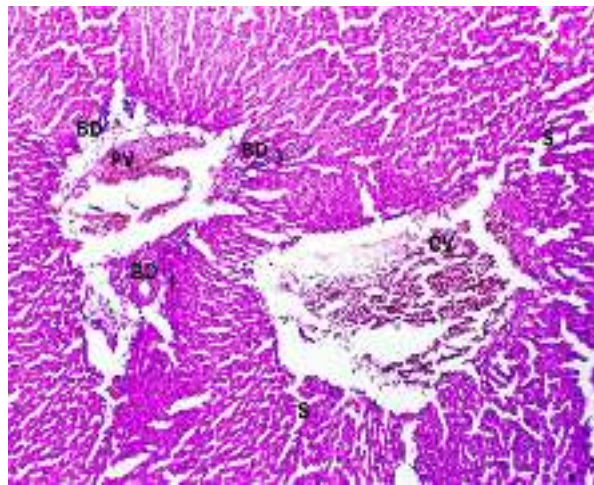


Fig (5): A photomicrograph of a section of liver from adult albino rat orally gavaged by 32.5 mg/kg cypermethrin daily for 12 weeks showing distorted liver architecture severely congested central vein (CV), mononuclear inflammatory cellular infiltration (I) of portal area, dilated congested portal vein (PV) and proliferated bile ducts (BD) with dilated sinusoids (S) (H&E X 200).

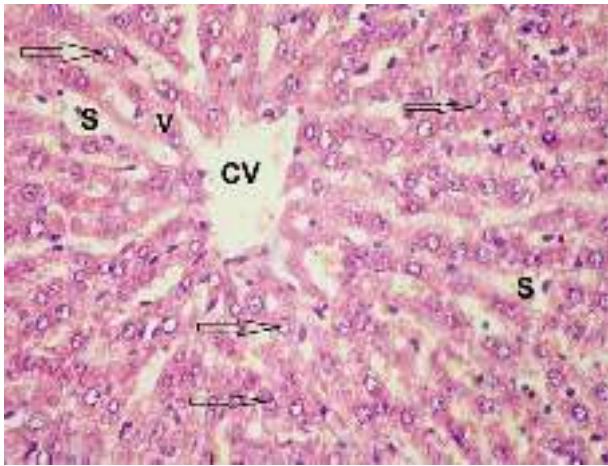


Fig (6): A photomicrograph of a section of liver from adult albino rat orally gavaged by 32.5 mg/kg cypermethrin followed by 20 mg/kg vitamin C daily for 12 weeks showing pericentral hepatocytes radiating from the central vein (CV) with vesicular nuclei (arrow) and granular cytoplasm. Few hepatocytes (V) are still vacuolated. Blood sinusoids (S) are also noticed (H&E X 400).

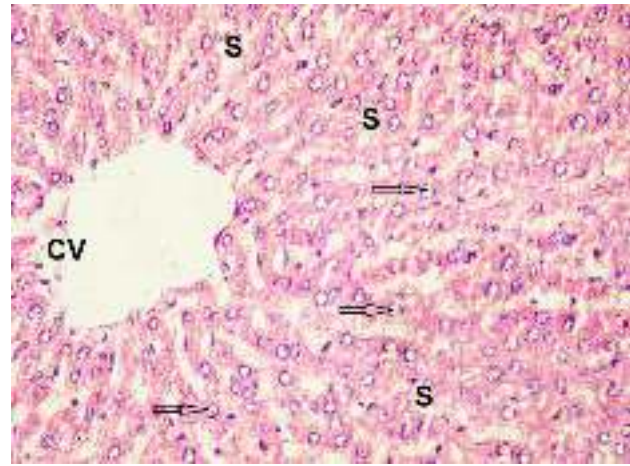


Fig (7): A photomicrograph of a section of liver from adult albino rat orally gavaged by 32.5 mg/kg cypermethrin followed by 500mg/kg garlic extract and 20 mg/kg vitamin C daily for 12 weeks showing pericentral hepatocytes with vesicular nuclei (arrow) and granular cytoplasm radiating from dilated central vein (CV). Blood sinusoids (S) are also noticed (H&E X 400).

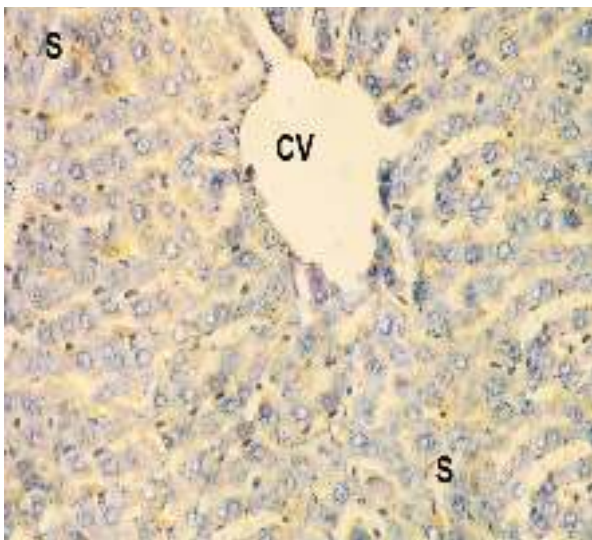


Fig (8): A photomicrograph of a section of liver of negative control adult albino rat showing no immunoreactivity within hepatocytes. Central vein (CV) and sinusoids (S) are noticed. (BAX immunostaining X 400).

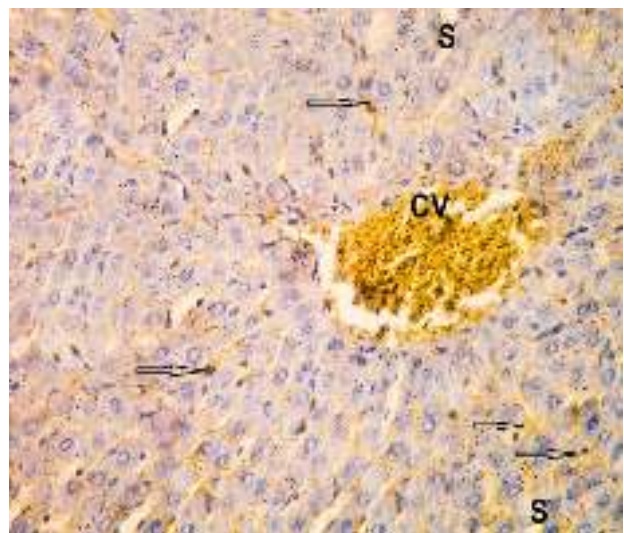


Fig (9): A photomicrograph of a section of liver from adult albino rat orally gavaged by 32.5mg/kg cypermethrin daily for 12 weeks showing granular strong +ve brown reaction within cytoplasm of most hepatocytes (arrows) around central vein (CV) and sinusoids (S) are noticed (BAX immunostaining X 400).

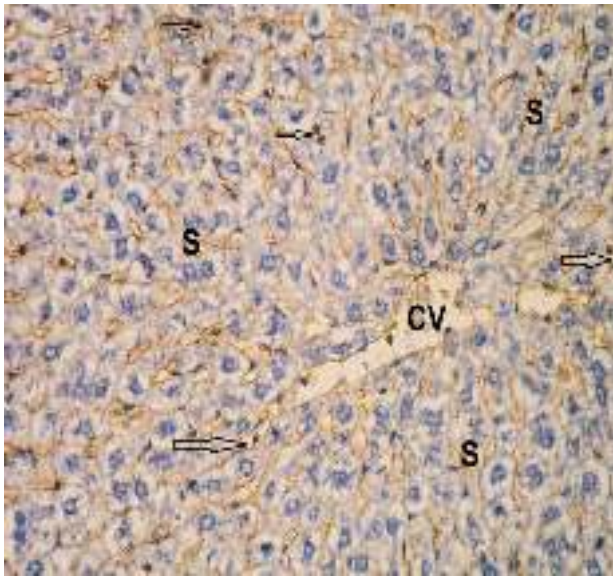


Fig (10): A photomicrograph of a section of liver from adult albino rat orally gavaged by 32.5 mg/kg cypermethrin followed by 20mg/kg vitamin C daily for 12 weeks showing granular faint +ve brown reaction within cytoplasm of most hepatocytes (arrows) around central vein (CV) and sinusoids (S) are noticed (BAX immunostaining X 400).

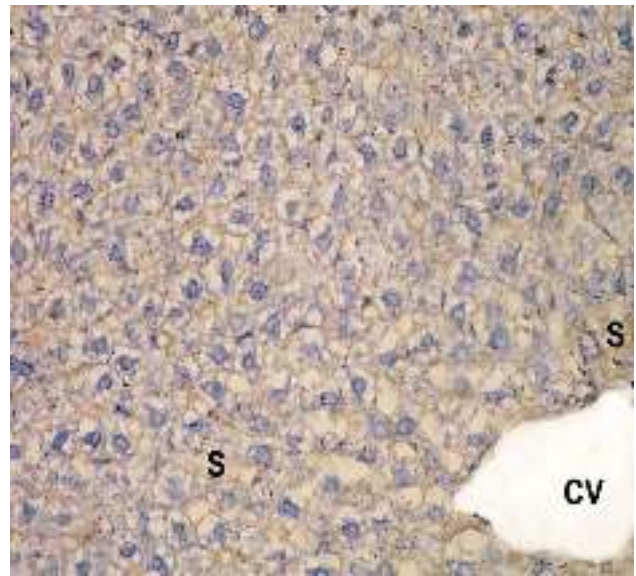


Fig (11): A photomicrograph of a section of liver from adult albino rat orally gavaged by 32.5 mg/kg cypermethrin followed by 500mg/kg garlic extract and 20mg/kg vitamin C once daily for 12 weeks showing -ve reaction within cytoplasm of most hepatocytes around central vein (CV) (BAX immunostaining X 400).

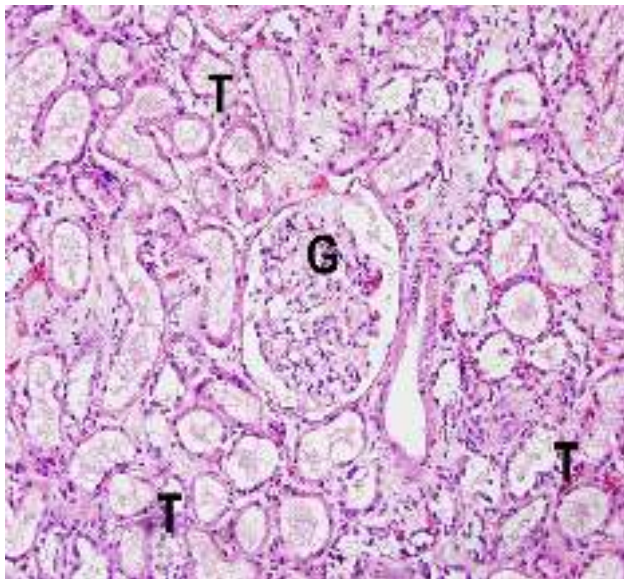


Fig. (12): A photomicrograph of a section in the kidney of adult albino rat from the negative control group showing normal kidney structure, the glomeruli (G) and tubules (T) appears normal (H & E x 200)

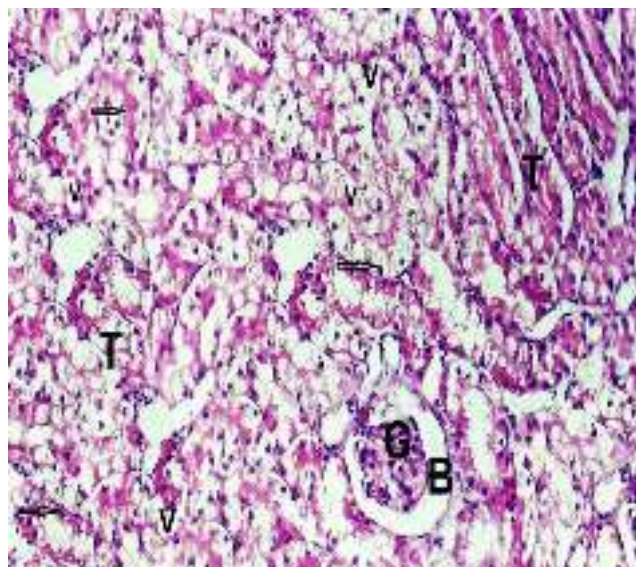


Fig. (13): A photomicrograph of a section in the kidney of adult albino rat orally gavaged by 32.5 mg/kg cypermethrin daily for 12 weeks showing shrunken glomeruli (G) with wide Bowman's space (B), associated with dilated tortuous tubules (T) lined with vacuolated epithelium (V) with apoptotic nuclei (arrows) (H&E x 400.)

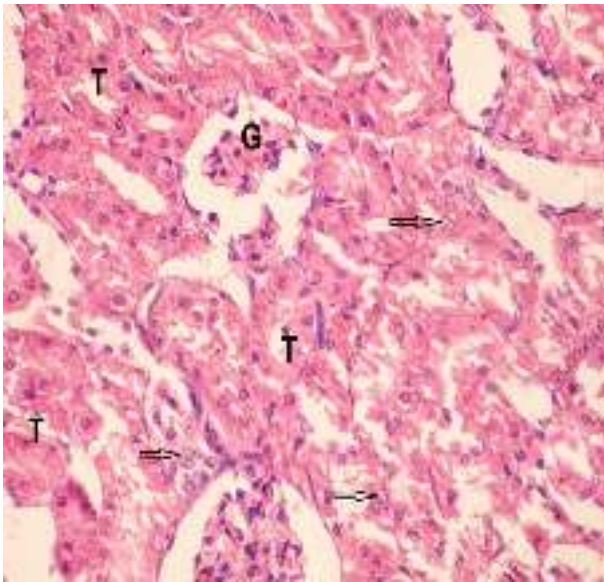


Fig. (14): A photomicrograph of a section of kidney from adult albino rat orally gavaged by 32.5 mg/kg cypermethrin followed by 20mg/kg vitamin C same result for that administrated 500mg/kg garlic extract after cypermethrin daily for 12 weeks showing shrunken glomeruli (G) dilation of tubules (T) with vesicular nuclei (arrow) (H&E X 400).

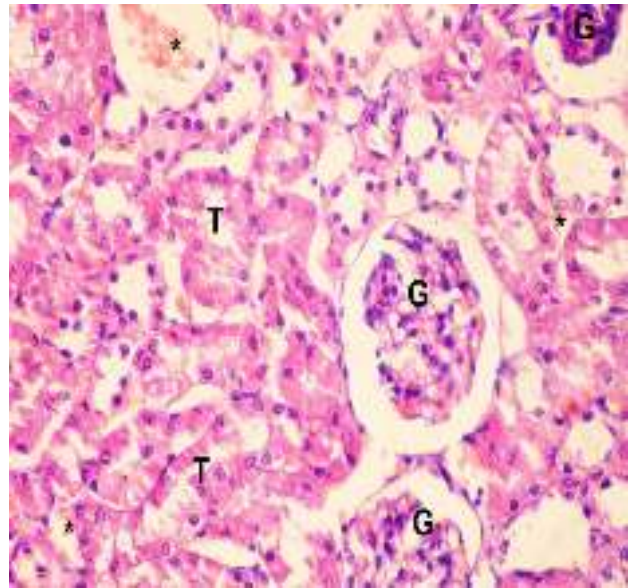


Fig. (15): A photomicrograph of a section of kidney from adult albino rat orally gavaged by 32.5 mg/kg cypermethrin followed by 500 mg/kg garlic extract and 20 mg/kg vitamin C daily for 12 weeks showing venous congestion (*) and slightly shrunken glomeruli (G) with tubules are noticed (T) (H&E X 400).

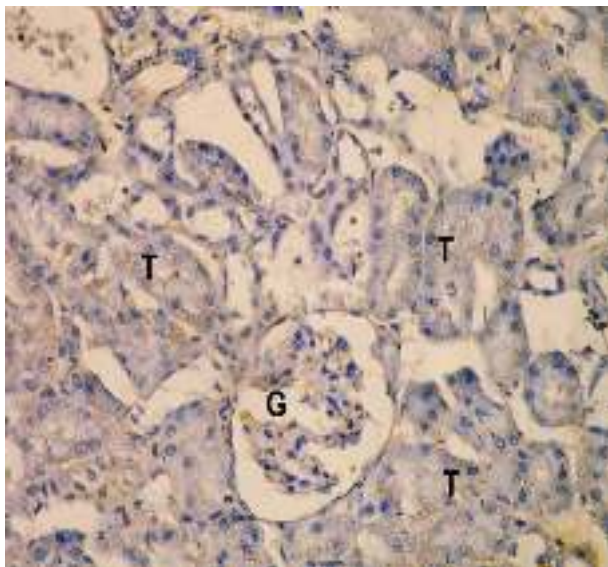


Fig. (16): A photomicrograph of a section of kidney of negative control adult albino rat showing no immunoreactivity within glomerular (G) and tubular (T) cells (BAX immunostaining X 400).

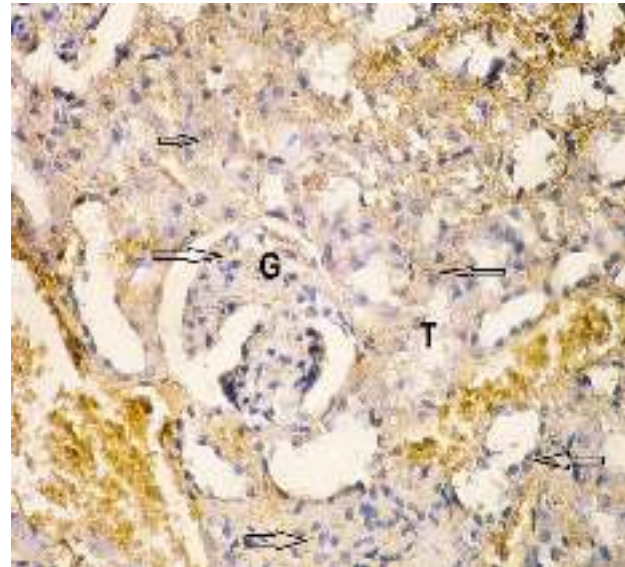


Fig. (17): A photomicrograph of a section of kidney from adult albino rat orally gavaged by 32.5 mg/kg cypermethrin daily for 12 weeks showing granular strong +ve brown reaction within cytoplasm of most glomerular (G) and tubular (T) cells (arrows) (BAX immunostaining X 400).

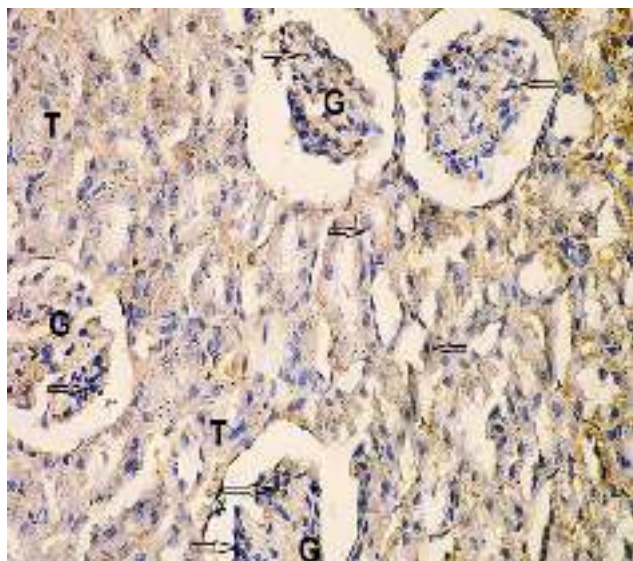


Fig. (18): A photomicrograph of a section of kidney from adult albino rat orally gavaged by 32.5 mg/kg cypermethrin followed by 20 mg/kg vitamin C after cypermethrin daily for 12 weeks showing granular moderate +ve brown reaction within cytoplasm of most of glomerular (G) and tubular (T) cells (arrows) (BAX immunostaining X 400).

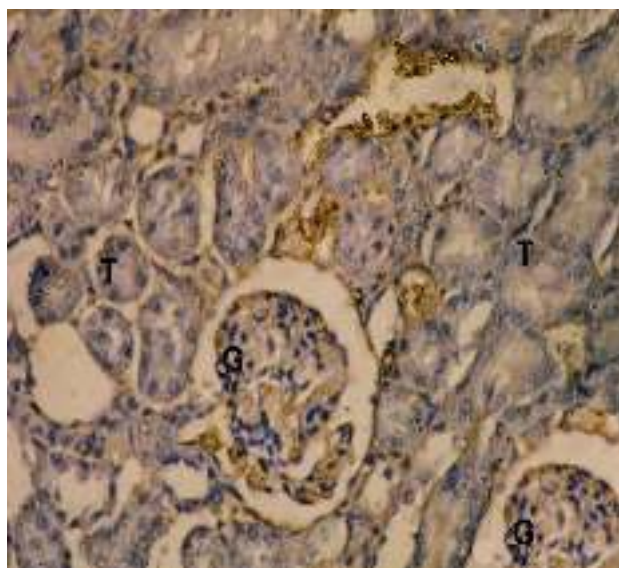


Fig. (19): A photomicrograph of a section of kidney from adult albino rat orally gavaged by 32.5 mg/kg cypermethrin followed by 500 mg/kg garlic extract and 20 mg/kg vitamin C daily for 12 weeks showing -ve reaction within cytoplasm of most glomeruli (G) around tubules (T) (BAX immunostaining X 400).

DISCUSSION

The cypermethrin incorporation to humans takes place via drinking water, food, with a minor contribution from the air causing various health problems in man. It is easily degraded on soil and plants but can be effective for weeks when applied to indoor inert surfaces. Exposure to sunlight, water and oxygen will accelerate its decomposition. Cypermethrin is highly toxic to fish, bees and aquatic insects, according to the National Pesticides Telecommunications Network (NPTN) (NPTN, 2009).

(A) Hepatotoxicity:

In the present study, there was a significant increase in liver enzymes (AST, ALT and ALP) mean values in cypermethrin treated group as compared to their corresponding values in control group. These results confirmed by obvious histopathological changes in the general architecture of the liver stained with H&E associated with periportal inflammatory cells infiltration, blood vessels

dilatation and congestion. The most striking histological feature was vacuolar degeneration in the cytoplasm of hepatocytes, pyknotic nuclei and infiltration with mononuclear leukocytes. Bile duct proliferation was observed. Also immunohistochemical staining for detection of BAX protein (apoptotic marker) in hepatic tissues appear as cytoplasmic strong brown reaction.

These results also reported by **Yanpallewar et al. (2003); Choudhary et al. (2003) and Nair et al. (2011)** who stated that high serum concentrations of ALT, AST and ALP indicated cellular leakage due to disintegration of cell membrane in liver. The increase in transaminase activities is probably due to the cypermethrin-induced pathological changes in liver and is an indication of liver damage.

Further more, liver is a prime organ associated with xenobiotic metabolism (**Hinton and Grasso 2000**). Perhaps, production of metabolically toxic intermediates capable of

causing hepatocellular damage occurs during processing of cypermethrin in liver, causing respective leakage of these enzymes in blood (**Bhushan et al., 2010**).

The histopathological changes in the liver of rats exposed to cypermethrin obtained also by **El-Toukhy and Girgis (2003)** and **Grewal et al. (2010a)** in the form of necrotic areas in hepatocytes, cell swelling, cytoplasmic hypertrophy and intracytoplasmic vacuoles were seen.

These histopathological changes explained by that cypermethrin induced oxidative stress in various organs such as liver and kidneys (**Grewal et al., 2010b**).

Khan et al. (2009) who stated that, pathologic changes in hepatocytes due to cypermethrin can be related to its inhibitory effect on total adenine triphosphate activity in the hepatocytes disturbing active transport of Na⁺, K⁺ and Ca²⁺ ions, thus injuring hepatocytes.

The cytoplasmic vacuolization that were observed in hepatocytes of cypermethrin treated animals is due to accumulation of ions and water in cytosol. Massive accumulation of fluids in the vacuoles may finally lead to cell lysis (**Gores et al., 2000**). These vacuoles are due to the free radicals that facilitate the release of lysosomal enzymes into the cytosol with subsequent oxidation of the protein architecture of the cells causing their fragmentation (**Kulisz et al., 2002**).

Azeez et al. (2011) and **Jin et al. (2011)** stated that the observed vascular dilatation may represent an adaptive process as an attempt to overcome oxygen deficiency. The cypermethrin exposure producing induction of hepatic oxidative stress is responsible for many deleterious effects in cell, including DNA damage and the alteration of gene expression related to apoptosis in adult albino rats.

The BAX protein suppresses the ability of Bcl-2, which enhances cell survival by inhibiting apoptosis induced under various circumstances (**Oltvai et al., 1993**).

The DNA contents increase in most of the tissues in response to cypermethrin exposure. This is due to activation of some dormant regulating factors controlling DNA synthesis. The drastic increase in the level of DNA in liver in response to the cypermethrin might be due to increased thymidine uptake in the hepatic DNA, as reported by **Holbrook (2008)**.

In the present study, upon the administration of garlic with cypermethrin in group (V) and vitamin C with cypermethrin in group (VI) or together with cypermethrin in group (VII) result in improvement of the enzyme levels a significant improvement in histopathological changes; almost normal lobular architecture and normal hepatocytes with average sized nuclei except of few central veins and sinusoids that showed congestion. The immunohistochemistry examination showed hepatocyte with faint to negative immuno-reactivity when compared with cypermethrin treated group (IV)

These findings are reported by **El-Banna et al. (2009)** who stated that antioxidant garlic extract and vitamin C prevent the accumulation of toxins within the cell and promote the production of energy improvement of antioxidants enzymes levels with reduced Thiobarbituric acid-reactive substances (TBARS) levels which promotes the apoptosis.

However, hepa-toprotective effect of vitamin C tends to increase synergistically when co administered with other agents precisely antioxidants and the administration of garlic and vitamin C can modulate the oxidative stress and improve the antioxidant system through the direct cytoprotective effect of garlic extract constituents; diallyldisulphide, allyl propyl disulphide, allicin and diallyltrisulphide by modulating lipid peroxidation and enhancing antioxidant status in the liver and blood (**Mirunalini et al., 2004; Pari et al., 2007; Hassan et al., 2010** and **Assayed et al., 2010**).

Free radicals, known to cause oxidative stress, can be prevented or reduced by dietary natural antioxidants through their capacity to

scavenge these products. Garlic extract or vitamin C may protect lipids and lipoproteins in cellular membranes against this oxidative damage, thus may prevent certain types of hepatic cellular damage (Aruoma, 2008).

Sushma and Devasena (2010) also reported increased oxidative stress (MDA, thiobarbituric acid reactive substances, or "oxidation index") in erythrocytes, livers, or kidneys caused by cypermethrin exposure.

(B) nephrotoxicity:

In the present study, there was a significant increase in BUN and serum creatinine mean values in cypermethrin treated group as compared to their corresponding values in control group (I). This confirmed by obvious changes microscopic examination of the kidney shows hemorrhages in renal tubules, different stages of degeneration, cast deposition and increased urinary spaces were observed. Also immunohistochemical staining for detection of BAX protein (apoptotic marker) in renal tissues appear as cytoplasmic strong brown reaction.

The increased blood urea concentration in rats treated with cypermethrin are also obtained by Yousef et al. (2003) who recorded that cypermethrin induced increase in urea level observed may be due to its effect on liver function, as urea is the end product of protein catabolism and conversion of ammonia to urea because of increased synthesis of enzyme involved in urea production is more efficient.

An increase in serum creatinine was recorded in cypermethrin-treated rats by Sakr et al. (2001) and Abu-El-Zahab et al., (2003).

Creatinine is more specific to kidneys since renal damage is the only significant parameter that increases serum creatinine in mammals (Garba et al., 2007). Like many other waste products of metabolism, most (> 75%) of the creatinine is removed from the body through glomerular filtration and the rest (<25%) through tubular secretion (Ravel, 2005). The increased serum concentrations of creatinine thus might be a result of alteration in these two mechanisms. Urea is also excreted by

kidneys, so impaired kidney function causes diminished ability to excrete urea from the blood into urine (Aslam et al., 2010).

The histopathological changes in the kidney agree with those published by Khan, (2008) in cypermethrin treated rabbits.

Due to various degenerative changes in the kidneys caused by cypermethrin, epithelial cells are detached from the tubular basement membranes. When detached epithelial cells are mixed with leaked proteins, the resultant mixture appears in the form of epithelial casts (Khan et al., 2009).

While, the pathological changes in kidney make sure that cypermethrin a hyperactivity and detoxication and the dilated cortical tubules due to the filling with protein casts, as the same with (Khan et al., 2003).

Sangha et al. (2011) reported these histological examination of kidney of cypermethrin -intoxicated birds revealed many alterations such as tubular degeneration, atrophy of glomeruli, hyperemia in glomeruli with focal area of necrosis and cytoplasmic vacuolation, cloudy swelling of the cells this is similar to (Ullah et al., 2006) in rabbits and (Grewal et al., 2010b) in mice. Cypermethrin induced oxidative stress, food and water intake of cypermethrin intoxicated changes in cell morphology and tissue injury (El-Demerdash, 2011) in animals. The oxidative stress indicates diminished ability of the kidneys to filter these waste products from the blood.

Braun et al. (2008) found that the kidney of cypermethrin treated adult albino rat showing apoptotic nucleus and +ve brown cytoplasmic reaction in cypermethrin treated rats. The protein level of the protective Bcl-2 was decreased, whereas BAX was increased, indicating that the protective activity of Bcl-2 might have been further reduced by up-regulation of the endogenous inhibitor (BAX). The family Bcl2 prevents apoptosis by inhibiting the generation or action of reactive oxygen species (Hockenberget al., 2013).

The antioxidants combination of vitamin C and garlic extract prevent the dysregulation of Bcl-2 and BAX. Recent findings

demonstrate the activation of several proteases such as cysteine proteases and aspartic proteases in the apoptotic signal transduction pathway. The activation of one of these proteases possibly may also account for the decreased Bcl-2 protein levels. This study suggests that lipopolysaccharide induced apoptosis is mediated by oxidative stress and leads to a reduction of the endogenous protection potential of the cells by disturbance of the balance between Bcl-2 and BAX (**Enari et al., 1996**).

In the present study, upon the administration of garlic with cypermethrin in group (V) and vitamin C with cypermethrin in group (VI) or together with cypermethrin in group (VII) result in a significant decrease in the mean values of BUN and serum creatinine level a significant improvement in histopathological changes; negative immunoreactivity when compared with cypermethrin treated group (IV).

The use of natural antioxidants for curing pesticide induced kidney toxicity or injury is being studied extensively. It exhibited concentration-dependent inhibitory effects on hydroxyl radical, hydrogen peroxide, reducing oxidative stress and lipid peroxidation. Cypermethrin induces oxidative stress as well as alter the defense mechanisms of detoxification and scavenging enzymes producing cytotoxic changes through generation of ROS (**Rasoul et al., 2012**).

Banerjee et al. (2009) observed morphological improvement in the kidney of rats following administration of garlic extract and vitamin C as slight degeneration, few vacuolar spaces, few merging of distal convoluted tubules, and slight distortion of cells and basement membrane indicating significant reduction in the severity of damage caused by cypermethrin.

It can be concluded that subchronic exposure to cypermethrin is hepatotoxic and nephrotoxic. Concomitant administration of garlic extract or vitamin C with cypermethrin protect liver and kidneys from cypermethrin's

induced injury & both together are more protectors than each of them alone.

Recommendations:

Improvement of health education programs for the purpose of increasing public awareness regarding the health impact of cypermethrin and their sources, reading the label on consumer products and instructing farmers and workers about the handling of cypermethrin and using the simplest hygienic and protective measures Administration of garlic extract or vitamins C may be of immense prophylactic and therapeutic values in exposed individuals.

REFERENCES

1. Abdel-Rahim, A.A.; Bdel-Rahim G.A.; Fayed S.A. and Mahmoud, G.I. (2009): Antioxidant Diet as Protective Agents Against Biochemical Perturbation Effects induced by Cypermethrin on Lipids and Protein Fractions as Well as Kidneys Function of Blood Rat. *Australian Journal of Basic and Applied Sciences*; 3(1): 267-276.
2. Abu-El-Zahab, H.S.; Amr, M.M.; Awadallah, R.; Abdel- Aal, W.E. and El-khyat, Z.A. (2003): Physiological and histopathological studies on term inhalation of adult albino rats to pyrethroids III. *Journal of Egyptian Zoology*; 11(1):311-334
3. Aruoma, O.I. (2008): Free radicals, oxidative stress and anti oxidants in human health and diseases. *American Journal of Oil Chemistry*; 75: 199-212.
4. Aslam, F.; Khan, A.; Khan, M.Z.; Sharaf, S. Gul, S.T. and Saleemi, M.K. (2010): Toxicopathological changes induced by cypermethrin in broiler chicks: Their attenuation with Vitamin E and selenium. *Experimental Toxicology and Pathology*; 62: 441-450.
5. Azeez, O. H.; Mahmood, M. B. and Hassan, J. S. (2011): Effect of nitrate poisoning on some biochemical parameters in rats. *Iraqi Journal of Veterinary Sciences*; 25(2): 47-50.
6. Banerjee, S.K.; Maulik, M.; Manchanda, S.K.; Dinda, A.K.; Das, T.K. and Maulik, S.C. (2009): Garlic-induced alteration in rat

- liver and kidney morphology. *Food Chemistry and Toxicology*; 39 (8):793–797.
7. Bhushan, B.; Saxena, N. and Saxena, P.N. (2010): Beta-cyfluthrin induced histochemical alteration in the liver of the albino rat. *Scandinavian Journal of Laboratory Animal Science*; 37: 61–66.
 8. Braun, H.E.; Surgeoner, G.A.; Stanek, J. and Mongi W.E. (2008): Efficacy and dissipation of permethrin for the control of the northern fowl mite in hens. *Canadian Journal of Veterinary Research*; 22(9): 291-294.
 9. Choudhary, N.; Sharma, M.; Verma, P. and Joshi, S. C. (2003): Hepato and nephrotoxicity in rat exposed to endosulfan. *Journal of Environmental Biology*; 24: 305-308.
 10. Dean, R.T.; Fu, S.; Stocker, R. and Davies, M.J. (2004): Biochemistry and pathology of radicalmediated protein oxidation. *Biochemistry Journal*; 324: 1–18.
 11. El-Banna Sabah, G.; Attia Ahmed, M. Hafez Afaf, M. and El-Kazaz Sara, M. (2009): Effect of garlic consumption on blood lipid and oxidant/antioxidant parameters in rat males exposed to chlorpyrifos. *Slovakian Journal of Animal Science*; 42 (3):111 – 117.
 12. El-Demerdash, F. M.; Yousef, M. I. and Al-Salhen, K. S. (2003): Protective effects of isoflavone on some biochemical parameters affected by cypermethrin in male rabbit. *Journal of Environmental Science and Health*; 38: 365- 378.
 13. El-Toukhy, M. A. and Girgis, R. S., (2003): In vivo and in vitro studies on the effect of Larvin and cypermethrin on adenosine triphosphatase activity of male rats. *Journal of Environmental Science and Health*; 28 (5): 599- 619.
 14. Enari, A.; Martinz-Larranaga, M.R. and Fernandez-Cruz, M.L. (1996): Effect of flumethrin on hepatic drug metabolizing enzymes and antipyrine disposition in rats. *Toxicology and Applied Pharmacology*; 141: 8–16.
 15. Garba, S.H.; Adelaiye, A.B. and Mshelia, L.Y. (2007): Histopathological and biochemical changes in the rats' kidney following exposure to a pyrethroid based mosquito coil. *Journal of Applied Science and Residues*; 3: 1788–1793.
 16. Grayson, B.T. (2012): Diagnosis and Treatment of Human Poisoning. *Pesticides Science*; 13(2): 522-526.
 17. Grewal, K.K.; Sandhu, G.S.; Kaur, R.; Brar, R.S. and Sandhu, A. (2010a): Toxic impacts of cypermethrin on behavior and histology of certain tissues of albino rats. *International Toxicology*; 17(2): 94-98.
 18. Grewal, A.J.; Connors, T.A.; Hoellinger, H. and Nam, N.-H. (2010b): The relationship between the pharmacokinetics of intravenous cismethrin and bioresmethrin and their mammalian toxicity. *Pesticide Biochemistry and Physiology*; 13: 281–293.
 19. Gores, R.; Monetti, C.; Vigetti, D.; Bosisio, S.; Fortaner, S.; Sabbioni, E.; Bernardini, G. and Prati, M. (2000): Arsenic toxicity and HSP70 expression in *Xenopus laevis* embryos. *Alternative of Laboratory Animal*; 30:597–603.
 20. Hassan, H. A.; Hafez, H. S. and Zeghebar, F. E. (2010): Garlic oil as a modulating agent for oxidative stress and neurotoxicity induced by sodium nitrite in male albino rats. *Food and Chemical Toxicology*; 48: 1980–1985.
 21. Hinton R.H. and Grasoo, P. (2000): Hepatotoxicity: In General and Applied Toxicology. (Ballantyne B., Marrs T. and Syversen T., Eds.), Grove's Dictionaries Inc., New York, pp. 853-892.
 22. Hockenberg, M.W.; Artiss, J.D.; Strandbergh, D.R. and Zak, B. (2013): A peroxidase-coupled method for the colorimetric determination of serum triglycerides. *Clinical Chemistry*; 29: 538–542.
 23. Holbrook, D.J. (2008): Effects of toxicants on nucleic acid and protein metabolism. In: Introduction to biochemical toxicology. (Hodgson E., and Guthrie F.E., Eds.), Blackwell Scientific Publications, Oxford, pp.261–284.
 24. Horobin, R.W. and Bancroft, J.D. (1998): Hematoxylin and eosin as an oversight stain. In: Troubleshooting histology stains, (1st ed.). Churchill Livingstone Press, San Francisco, pp. 88- 93.
 25. Jin, Y.; Zheng, S.; Pu, Y.; Shu, L.; Sun, L.; Liu, W. and Fu, Z. (2011):

- Cypermethrin has the potential to induce hepatic oxidative stress, DNA damage and apoptosis in adult zebrafish (*Danio rerio*). *Journal of Environmental Biology*; 12(1): 18–20
26. Kakko, T.; Toimela, H. and Tahti, Y. (2008): The synaptosomal membrane bound ATPase as a target for the neurotoxic effects of pyrethroids, permethrin and cypermethrin. *Chemosphere*; 51: 475–480.
27. Kaplan, A. (1965): Urea nitrogen and urinary ammonium. In: Standard methods of clinical chemistry. (Meitez E., Ed.). (5th ed.). Academic press, New York, pp. 245-256.
28. Khan, A. (2008): Cypermethrin induced anaemia in male rabbits. *Pakistan Veterinary Journal*; 29(4): 191-195.
29. Khan, A.; Faridi, H.; Ali, M.; Khan, M.; Siddique, I.; Hussain, I. and Ahmad, M. (2009a): Effects of cypermethrin on some clinico-hematobiochemical and pathological parameters in male dwarf goats (*Capra hircus*). *Exposure and Toxicology and Pathology*; 61: 151–160.
30. Khan, W.A.; Khan, M.Z.; Khan, A. and Hussain, I. (2009b): Pathological effects of aflatoxin and their amelioration by vitamin E in White Leghorn layers. *Pakistan Veterinary Journal*; 30: 155–162.
31. Khan, P.K. and Sinha, S.P. (2008): Impact of higher doses of vitamin-C in modulating pesticide genotoxicity. *Teratoglogy and Carcinogenesis Mutagen*; 14: 75–181.
32. Khan, P.K.; Khan, M.Z. and Sinha, S.P. (2003): Antimutagenic efficacy of higher doses of vitamin C. *Mutation Residues*; 298 (3): 157–161.
33. Kulisz, A.; Chen, N.; Chandel, N. S.; Shao, Z. and Schumacker, P. T. (2002): Mitochondrial ROS initiate phosphorylation of p38 MAP kinase during hypoxia in cardiomyocytes. *American Journal of Physiology and Lung Cell Molecular Physiology*; 282(6): 1324-1329.
34. Mirunalini, S.; Kumaraguruparan, R.; Subapriya, R. and Nagini, S. (2004): Garlic Oil Enhances Hepatic and Blood Antioxidants During Hamster Buccal Pouch Carcinogenesis. *Pharmaceutical Biology*; 42 (3): 240–245.
35. Nair, R.R.; Abraham, M.J.; Lalithakunjamma, C.R.; Nair, N.D. and Aravindakshan, C.M. (2011): A pathomorphological study of the sublethal toxicity of cypermethrin in Sprague Dawley rats. *International Journal of Nutrition Pharmacology and Neurological Disease*; 1: 179–183.
36. National Pesticides Telecommunications Network (NPTN), (2009): US EPA Office of Pesticide Programs Oregon State University 333 Weniger Hall Corvallis, OR 97331-6502800-858-7378 <http://nptn.orst.edu>.
37. Oltavai, M.; Casida, S. and Pleil, J. D. (1993): Human blood and environmental media screening method for pesticides and polychlorinated biphenyl compounds using liquid extraction and gas chromatography-mass spectrometry analysis. *Journal of Chromatography B*; 769: 155-167.
38. Pari, L.; Murugavel, P.; Sitasawad, S.L. and Kumar, K.S. (2007): Cytoprotective and antioxidant role of diallyltetrasulfide on cadmium induced renal injury: an in vivo and in vitro study. *Life Science*; 7:50–658.
39. Popper, H.; Paglia, D.E. and Valentine W.N. (1937): studies on the quantitative and qualitative characterization of erythrocytes glutathione peroxidase. *Journal of Laboratory Clinical Medicine*; 70: 58- 169.
40. Ravel, A. (2005): Electron ionization gas chromatography-mass spectrometric determination of residues of thirteen pyrethroid insecticides in whole blood. *Journal of Chromatography B*; 802: 371–376.
41. Reitman, S. and Frankel (1957): A colorimetric method for the determination of serum glutamic oxalacetic and glutamic pyruvic transaminases. *American Journal of Clinical Pathology*; 28(1) 56- 63.
42. Rodriguez, H.; Tamayo, C.; Inostroza, J.; Soto, C.; Bustos-Obregon, E. and Paniagua, R. (2009): Cypermethrin Effects on The Adult Mice Seminal Glands. *Ecotoxicology and Environmental Safety*; 7: 658-662.
43. Sakr, S.A.; Maharan, H.A. and Okdah, Y.A. (2001): Renal lesions induced by pyrethroid inhalation in albino rat. *Online Journal of Biology and Science*; 1:1066-1068.

44. Sangha, G.K.; Kaur, K. and Khera, K.S. (2013): Cypermethrin induced pathological and biochemical changes in reproductive organs of female rats. *Journal of Environmental Biology*; 34: 99–105.
45. Singh, V.K.; Dixit, P. and Saxena, P.N. (2008): Cybil induced hepatobiochemical changes in wistar rats. *Journal of Environmental Biology*; 26: 725–727.
46. Shimuzu, I.; Maqbool, I. and Jehanzeb, K. (2014): Pesticides residues. *Journal of Pakistan Medical Association*; 57(12):588.
47. Ullah, M.S.; Ahmad, M.; Ahmad, N.; Khan M.Z. and Ahmad, A. (2006): Toxic effects of cypermethrin in female rabbits. *Pakistan Veterinary Journal*; 26(4): 193-196.
48. Yousef, M.I.; Abbassy, M.S. and Yacout, M.H.M. (2003): Assessment of cypermethrin and dimethoate toxicity in Barki sheep: Biochemical and histological changes and tissue residues. *Egyptian Journal of Animal Production*; 36 (1): 25–41.

تقييم الدور الوقائي لمستخلص الثوم وفيتامين (ج) ضد التأثير السام دون المزمّن للمبيد الحشري السايبرميثرين على الكبد والكلية
في جردان التجارب البيضاء البالغة

داليا محمد أمين فرج – هاني عزيز مليكه – نادرة قنديل علي – محمود وحيد عمارة *

أقسام الطب الشرعي والسموم الإكلينيكية والباثولوجي*

كلية الطب البشري- جامعة الزقازيق- مصر

مقدمة البحث: تخضع سمية السايبرميثرين للدراسات المستفيضة بسبب التوزيع على نطاق واسع على مستوى العالم. ويعتبر المصدر الرئيسي للسايبرميثرين في الجسم البشري من خلال تناول الغذاء والماء. **هدف البحث:** يجري هذا البحث لدراسة تأثير إعطاء فيتامين (ج) ومستخلص الثوم على الآثار السمية للاستخدام المتكرر لمادة السايبرميثرين على الكبد والكلية للجرذان البيضاء البالغة **طريقة البحث:** أجرى البحث على عدد ١٢٦ من ذكور الجرذان البيضاء البالغة مقسمة الى ٧ مجموعات كلا منها يحتوى على ١٨ جرذ تم حقنها ٦ ايام فى الاسبوع كما يلي: المجموعة الاولى (المجموعة الضابطة): لم يتم اعطائها أى علاج. المجموعة الثانية (مجموعة مستخلص الثوم): سوف يتم اعطاء كل جرذ (٥٠٠مجم / كجم) من مستخلص الثوم مذاب فى (١ مل) من الماء المقطر عن طريق الفم مرة واحدة يوميا. المجموعة الثالثة (مجموعة فيتامين ج): سوف يتم اعطاء كل جرذ (٢٠مجم/ كجم) من فيتامين ج مذاب فى (١ مل) من الماء المقطر عن طريق الفم مرة واحدة يوميا. المجموعة الرابعة (مجموعة السايبرميثرين) : سوف يتم اعطاء كل جرذ (٣٢,٥ مجم / كجم) من السايبرميثرين مذاب فى (١ مل) من المياة المقطرة عن طريق الفم مرة واحدة يوميا. المجموعة الخامسة (مجموعة السايبرميثرين ومستخلص الثوم) : سوف يتم اعطاء كل جرذ (٣٢,٥ مجم / كجم من السايبرميثرين+ ٥٠٠ مجم/ كجم مستخلص الثوم) عن طريق الفم مرة واحدة يوميا. المجموعة السادسة (مجموعة السايبرميثرين و فيتامين ج): سوف يتم اعطاء كل جرذ (٣٢,٥ مجم / كجم من السايبرميثرين+ ٢٠ مجم/ كجم من فيتامين ج) عن طريق الفم مرة واحدة يوميا. المجموعة السابعة (مجموعة السايبرميثرين و فيتامين ج ومستخلص الثوم): سوف يتم اعطاء كل جرذ (٣٢,٥ مجم / كجم من السايبرميثرين+ ٥٠٠مجم/ كجم مستخلص الثوم+ ٢٠ مجم/ كجم من فيتامين ج) عن طريق الفم مرة واحدة يوميا. ومن هذه الدراسة تم إستنتاج ما يلي: . وفي نهاية الاسبوع الثاني عشر من الدراسة تم استخدام جردان كل المجموعات لدراسة انزيمات الكبد الكيميائية ووظائف بالدم و فحص الكبد والكلية بالميكروسكوب الضوئي. **النتائج:** أوضحت الدراسة الكيميائية وجود إرتفاعاً ذا دلالة إحصائية في مستوى إنزيمات الكبد (أنزيم ألانين أمينو ترانسفيراز و أنزيم الأسبرتيت أمينو ترانسفيراز والالكلين فوسفاتيز)، (اليوريا والكرياتنين). كما أسفرت النتائج لكل من مجموعة السايبرميثرين و مستخلص الثوم و مجموعة السايبرميثرين و فيتامين ج و مجموعة السايبرميثرين و مستخلص الثوم و فيتامين ج معا عن إنخفاض ذي دلالة إحصائية في مستوى إنزيمات الكبد (أنزيم ألانين أمينو ترانسفيراز & أنزيم الأسبرتيت أمينو ترانسفيراز والالكلين فوسفاتيز) اليوريا والكرياتنين. أوضح الفحص المجهرى باستخدام صبغة الهيماتوكسلين والأبوسين لشرائح الكبد للجرذان البيضاء فى مجموعة السايبرميثرين وجود تغيرات هستوباثولوجية واضحة أشتملت على آثار ضارة بالكلية وقد كانت هذه التغيرات فى صورة الانكماش او التدمير الكامل للكبيبات وفجوات سيتوبلازمية وأنوية غامقة اللون فى خلايا الكبد. ولوحظ وجود اتساع و احتقان فى الشعيرات الدموية، ونزيف دموى وتسلل خلوي وتخلل دهنى فى خلايا الكبد وأوضح الفحص المجهرى باستخدام صبغة الهيماتوكسلين والأبوسين لشرائح الكلى للجرذان البيضاء فى مجموعة السايبرميثرين وجود تغيرات هستوباثولوجية واضحة أشتملت على آثار ضارة بالكلية وقد كانت هذه التغيرات فى صورة الانكماش او التدمير الكامل للكبيبات وفجوات سيتوبلازمية وأنوية غامقة اللون فى خلايا الكلى وجود اتساع و احتقان فى الشعيرات الدموية فى الكبيبات، وتفجى فى الخلايا ومجالات نزيف دموى بين الأنابيب وتسلل خلوي وتخلل دهنى فى النسيج الخلالى. . وأظهر الفحص المناعى للكشف عن الباكس بروتين فى أنسجة الكبد والكلية تفاعل إيجابي قوي فى مجموعة السايبرميثرين مقارنة مع مجموعة اكنترول التى أظهرت رد فعل سلبي. اما بالنسبة المجموعة المعطاة مستخلص الثوم أو فيتامين ج أو كلاهما مع السايبرميثرين فقد احتفظت بتركيب الكبد والكلية الطبيعى حيث بدت تقريبا مثل المجموعة الضابطة فى كل التحضيرات الهستولوجية السابقة بصبغة الهيماتوكسلين والأبوسين وبالصبغة الهستولوجية المناعى لمستقبلات الباكس بروتين بالمجهر الضوئى.

التوصيات : حيث أنه إتضح من نتائج هذه الدراسة ان السايبرميثرين له تأثير سمي واضح على كبد كلى الجرذان البيضاء البالغة مع إمكانية التحسن الجزئي مع الإمداد بمستخلص الثوم أو فيتامين (ج) أو كلاهما وكذلك كعلاج جانبي من الآثار السمية للسايبرميثرين ولذلك يوصي بتقليل التعرض للسايبرميثرين عن طريق الإنتباه لمصادر مثل المياة و الطعام وكذلك زيادة توعية المهنيين المعرضين لسايبرميثرين بأضراره وكذلك طرق الوقاية منه.