

Prevalence Antimicrobial Resistance and Pathogenicity of *Enterococcus* Spp. Isolated from Ducks

Mohamed S. Al-Gaiar ,Mohsen El Dimerdash , Dalia M. Hamed and Mohamed K. Moursi

Abstract:

The present study was undertaken during a period from 2013 to 2015 in different localities at Damietta Governorate to investigate the isolation prevalence of *Enterococcus* spp., antibacterial resistance patterns and their pathogenicity in Pekin ducks. Clinical cases from 46 duck flocks of different breeds suspected with bacterial infection (26 farms and 20 backyard), were examined for the prevalence, isolation and identification. *Enterococcus faecalis*. Suspected cases were confirmed after culturing on Bile esculin agar, biochemical testing either by conventional and bioMerieux Vitek. Prevalence were (7/26) and (4/20) in duckling farms and backyard respectively. Sensitivity testing of isolated enterococci from duck flocks to antimicrobial agents were tested using the disk diffusion method. *Enterococcus faecalis* showed multiple drug resistance patterns for different antibiotics, oxytetracycline, chloramphenicol, Erythromycin, Gentamicin, Ciprofloxacin, Neomycin, Kanamycin, Vancomycin, Nalidixic acid, and streptomycin while, susceptible to Ampicillin. Pathogenicity test for isolated *Enterococcus faecalis* was performed. Inoculated ducks showed mainly, general clinical signs respiratory manifestation, lameness, growth retardation and pathologically airsacculitis, perihepatitis, pericarditis, endocarditis, splenomegaly and necrosis of bone extremities (FHN) differ in severity according to the route of inoculation intravenous, intrathoracic, intranasal and orally respectively.

Key word: Enterococcus, bacterial diseases, Duck diseases, arthritis in ducks, pathogenicity test in duck.

Introduction

Enterococcus spp. in poultry can result in distinct clinical forms of disease, acute and subacute/chronic. In the acute form clinical signs are related to septicemia and include depression, lethargy, pale combs and wattles, ruffled feathers,

diarrhea, mild head tremors and often, only dead birds are found. In the subacute/chronic form, depression, loss of body weight, lameness and head tremors may be observed. Clinically affected birds eventually die if not treated **Joan and McNamee (2002)**. *E. faecalis*,

E. faecium, *Enterococcus durans*, *Enterococcus cecorum* and *Enterococcus hirae* have occasionally been associated with a variety of pathologies including endocarditis, septicaemia, central nervous disorders and lameness **Woodet al. (2002)**. *Enterococcus* spp(*faecalis* ,*durns*, *hairea*),were isolated by rate 52.5% from birds with the ascites syndrome from different farms at Ismailia province **Mohamed and Sohair(2008)**.The most frequent resistance properties were resistances to tetracycline (75.6%), erythromycin (56.8%) and ciprofloxacin (41.9%). No strains resistant to vancomycin and linezolid were detected (**Ruzauskaset al., 2009**). The experimental infection of *Enterococcus faecalis* causes arthritis at the rate of 100% in chickens (**Ciftci 2004**). High doses (1.5×10^9 CFU/bird) of *Enterococcus Cecorum* given intravenously and into air sac to 12-day-old ducks led to 100%, 67% mortality within 2 -4 days respectively (**Metzneret al., 2010**).

Material and Methods

Birds:

Twenty six , duck from different farms, ages and breeds (Pekin, *Muscovy* and *Mallard*)), suffering from high morbidity and increased mortality besides Twenty backyard cases, were examined during a period extended from 2013 to 2015 in different localities of Damietta Governorate. Complete clinical

signs and postmortem examination were performed

Samples:

A total of 213 samples (169 from duck farms and 44 from the backyard) as shown in tables (1) , were collected from internal organs (liver, heart, spleen, brain) and from bone marrow, synovial fluids of arthritic joints and hydro-pericardial fluids of diseased and freshly dead ducks. Then samples were transferred into nutrient broth and incubated at 37C for 24 hr and were subcultured on Bile esculinazidagar. The black colored colonies observed were subjected to morphological and biochemical examination as described by **Facklam and Sahn(1995)**

Isolation and species identification of enterococci

Isolated suspected colonies of *Enterococcus* spp. derived from visceral organs (liver, heart, spleen, hydropericardial fluids, and arthritic joints) were transferred to a selective medium containing bile, esculin and azide (Biokar Diagnostic) and to blood agar. Samples were incubated at $(37 \pm 1) ^\circ\text{C}$ for (48 ± 2) h. All isolated species were Gram-positive and hemolytic negative cocci. Based on native microscopical preparation (conformation, motility, cleanness of cultures), negative catalase and positive PYR test (PYRA test, Lachema, Brno, Czech Republic) and biochemical identification by (bio Merieux Vitek,).

Pathogenicity test .

Enterococcus faecalis challenge isolate was isolated from duck flocks with severe clinical disease positive isolates were identified to the species level by biochemical tests and the Automated Microbial Identification system (bioMerieux Vitek).

Inoculation of Pekin ducks. Done after Jung et al 2013 orally, intraasally, intra thoracic and intravenously respectively respectively

Experimental infection.

A total fifty pekin day old duck randomly divided into five separately housed groups 10 each. At 7 days of age, control group were inoculated intravenously with sterile physiological saline solution. The other groups (2-5) were inoculated orally, intra nasal, intra thoracic and intra venous with 0.5 ml *Enterococcus faecalis* suspension containing 2×10^9 colony-forming units (CFU) per bird. All ducks were monitored daily for clinical signs throughout the whole experimental period (21

day). All clinical signs and pathological changes were recorded and mortality was documented. Birds with severe signs such as apathy, reduced mobility or central nervous signs, which prevented the uptake of food and water, were euthanized. At days 7, 14 and 21 post infection (p.i.). For necropsy and recording pathological changes.

Re-isolation of *Enterococcus faecalis*.

For re-isolation, samples were cultured on Columbia sheep blood agar and Columbia CNA agar (Oxoid GmbH) for 24 h at 37°C under microaerophilic conditions. Colonies showing typical morphology of *Enterococci* including grey colour and slight α -haemolysis were subcultured and confirmed to be *Enterococcus faecalis* by positive Gram staining, negative catalase reaction, no growth at 45°C and 6.5% NaCl concentration, and by the commercial microorganism identification system

Table (1): Descriptive data of positive bacterial examined duck flocks (farms, backyard)

Locality	Breed	Flock no.	Average age in days	Flock capacity	Type of Specimen	No. of samples
Damietta	Muscovy, Pekin	20	3-60	2239	Live, freshly dead	60
zElzarka	Muscovy, Pekin, Muller	9	5-65	10800	Live Freshly dead	58
Kafersaad	Muscovy, Pekin	12	6-77	15452	Live Freshly dead	71
Faraskour	Muscovy, Pekin	5	11-60	2035	Live Freshly dead	24
Total				30526		213

Results

The diseased ducks showed, general signs of illness in the form of depression, anorexia, reduced water and feed consumption, ruffled feathers and body weight loss, inactivity and diarrhea. Others showed nervous manifestations, lameness and inability to stand. Sudden death of some birds were recorded. Postmortem findings of the examined duck revealed general congestion in all internal organs with signs of septicemia, hepatosplenomegaly, airsacculitis, pericarditis, perihepatitis, ascites, enteritis, hydropericardium, bone abnormalities, arthritis and brain congestion.

Prevalence of *Enterococcus faecalis* isolation from duck flocks

Enterococcus faecalis was isolated from duckling flocks with different rearing systems by 7/9 and 4/11 from farms and backyard respectively

While prevalence according to breed were illustrated in table (3).

Results of pathogenesis test

Clinical signs and mortality:

All ducks of the intravenous and intra thoracic inoculated groups showed severe clinical signs, including apathy, reduced mobility, diarrhoea and central nervous signs such as head tremor and opisthotonus at days 1 and 2 (p.i). Four birds 4/10 (40%) within the first 2 days (p.i).

A week later, all clinical signs were extended in addition to arthritis, respiratory manifestations (dyspnea

, lacrimation, abnormal respiratory sound) and abnormal characteristic gait (lameness) with twisted legs, drop in feed consumption, the ducks became very weak and cachexic unable to stand and lay down all the time with severe retardation of growth. Bilateral swelling of femoro-tibial and tibio-metatarsal joints were characteristically observed. The mortality rate were (30%) in intravenous and intra thoracic inoculation. Oral and intranasal inoculated ducklings showed mild clinical signs of illness, decrease food intake, relative increase in water intake and diarrhea with decrease activity at 3rd day post inoculation. At 4th day post inoculation in orally infected ducks showed nervous signs such as head tremor and opisthotonus before death. A week later, respiratory manifestations developed and growth retardation were detected. But intranasal severely affected than orally inoculated birds. Mortality rate in both inoculated groups was 20% along experimental period.

Gross pathology: Ducks that died showed septicemia including, severe congestion in all internal organs, muscles, ribs, brain, intestine, airsacculitis with the presence of hemorrhagic streaks on muscles. Intravenous and intrathoracic inoculated groups showed, enlarged pale liver with areas of congestions, peri hepatitis, pericarditis, enteritis, large

lobulated kidney ,enlarged spleen, air sacculitis, endocarditis but in sever stage, presence of cecal core in intravenous inoculated birds , pneumonia , arthritis(amyloid deposition) , necrosis of bone extremities with femoral head necrosis. Presence of bloody fluids in pericardial sac was developed at the end of 1st week. At second week all lesions were extended, but liver became atrophied but bone abnormalities (amyloid arthritis , necrosis of bone extremities , femoral head necrosis) were increased in severity .(Figure,1-4)

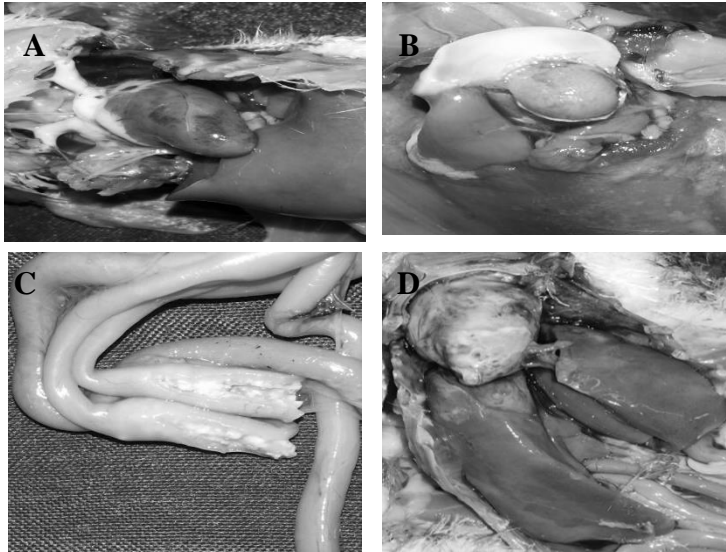
At day 7 post inoculation oral and intranasal inoculated groups showed, pneumonia, airsacculitis, pericarditis , enlarged pale liver and with areas of congestions, splenomegaly, enteritis, large lobulated kidneys and hydro pericardium with variable degrees. While cecal core was detected in intra nasal inoculated ducks. Mild bone abnormalities (necrosis in bone extremities, femoral head necrosis) were recorded in intra nasal inoculated group

Table (2) Prevalence of Enterococcus faecalis in examined ducks.

Duck flock	Duckling farms breed						Duckling backyard breed					
	Muscovy		Muller		Pekin		Muscovy		Muller		Balady	
Isolated Enterococcus	5/19	26.31%	1/4	25%	1/3	33.3%	1/11	9.09%	2/5	40%	1/4	25%

Table (3) lesion score of experimental Enterococcus faecalis infection 1st week post infection

Route of enterococcus inoculation	Number Of ducks	Macroscopic lesions										
		air sacculitis	Pericarditis	perihapatitis	splenomegaly	Lobulated enlarged kidney	Congestion of ribs	Lung congestion	Enteritis and /or Caecal core	Femoral head necrosis	Hydro pericardium	enterococcus positive duck re-isolation
Control	10	-	-	-	-	-	-	-	-	-	-	4/4
Oral	10	+	+	+	+	+	+	+	enteritis	-	-	4/4
Intranasal	10	+	+	+	+	+	+	+	enteritis	-	-	4/4
Intravenous	10	+	+	+	+	+	+	+	enteritis	-	-	4/4
Intrathoracic	10	+	+	+	+	+	+	+	enteritis	+	+	4/4



A- Duck experimentally infected with *Enterococcus Faecalis* by oral route showing hemorrhagic streaks on heart at (1st week post inoculation).

B- Femoral Head Necrosis (FHN) in 18 day old duck experimentally infected with *Enterococcus Faecalis* by intra thoracic route at (2 end post inoculation).

C- Cecal core of experimentally infected ducks with *Enterococcus faecalis* by intranasal route (3 week post inoculation).

D- Perihepatitis, pericarditis, airsacculitis of experimentally infected ducks with *Enterococcusfaecalis* (2end Week PI ,Oral route).

Discussion

This study was made to study the prevalence, pathogenicity and antimicrobial resistance of *Enterococcus* infection in farms and backyard ducks in Damietta providence .

Clinically diseased examined ducks showed, general signs of illness in the form of depression, anorexia, reduced water and feed consumption, ruffled feathers and body weight loss, inactivity and diarrhea. Others showed nervous manifestations, lameness and inability to stand. Sudden death of

some birds was recorded. While, the post mortem findings revealed ,general venous congestion in all internal organs with signs of septicemia , hepatosplenomegaly, airsacculitis, pericarditis, perihepatitis, ascites, enteritis, hydropericardium, bone abnormalities, arthritis and brain congestion. Similar clinical signs and post mortem lesion were recorded in ducks affected by bacterial pathogens in various degrees of morbidity and mortalities by *Gary (1997)*.

Tsai et al (2004) reported that, *Enterococci* belong to the lactic acid bacteria group and are widely distributed in nature, but they are not generally recognized as safe. On the contrary, *Moellering (1992), and Leclercq and Courvalin (1997)* showed that, the *Enterococcus Faecalis* considered to be a harmless commensal with very low pathogenic potential. *Enterococcus Faecalis* was isolated in a rate of 77.7%, 36.3% from duckling farms and backyard respectively rather than grower ducks. This result is nearly similar with that reported by *Saikia et al (1995)* who isolated *Enterococcus Faecalis* by (70.9%) from duckling less than eight weeks. Also, *Smyth and McNamee (2001)* demonstrated that, *E. faecalis*, *E. hirae*, and *E. durans* were the most common *Enterococcus* spp causing both septicaemia and localized infections in poultry. *Mette et al. (2011) and Olsen et al. (2012)* reported that *Enterococcus faecalis* was the most significant bacterial pathogens associated with first week mortality in poultry.

The isolated *Enterococcus faecalis* strains were found to be resistant to different antibiotics including Chloramphenicol, Ciprofloxacin, Gentamycin, Kanamycin, Nalidixic acid, Neomycin, Tetracyclin, Streptomycin and Vancomycin while, sensitive to Ampicillin. These results agreed with *Aarestrup et al. (2000)* who reported that *E. Faecalis* isolated

from broilers showed widespread resistance to chloramphenicol, macrolides, kanamycin, streptomycin and tetracycline. *Lukašova and Šustačková (2003)* reported that, *Enterococci* have been known to be resistant to most antibiotics used in clinical practice. They are naturally resistant to cephalosporins, aminoglycosides and clindamycin and may also be resistant to tetracyclines and erythromycin. They are moderately sensitive to penicillin, ampicillin and glycopeptides. On other hand *Saikia et al. (1995)* found that, the *Enterococci* isolated from duck intestines consisted of *E. faecalis* and *E. faecium* were resistant to several antibiotics; chloramphenicol and gentamycin sulphate were the only antibiotics of those tested which were moderately effective.

Experimentally, *Enterococcus faecalis* infection via intravenous route in Pekin ducks showed, severe clinical signs including apathy, reduced mobility, diarrhoea and central nervous signs such as head tremor and opisthotonus, birds died within the first 2 days p.i. At autopsy enlarged pale liver with areas of congestions, peri hepatitis, pericarditis, enteritis, large lobulated kidney, enlarged spleen, air sacculitis, endocarditis but in sever stage, presence of cecal core in intravenous inoculated birds, pneumonia, arthritis (amyloid deposition), necrosis of bone extremities with femoral head necrosis. These results agree with

Jung et al. (2013) with the exception that, the mortality rate were 40%, (4 out of 10) along the experimental period while in intravenously infected group showed 100% mortality after 2 days post infection which may be referred to the *Enterococcus* strain used *Enterococcus cecorum*. Also, *Metzner et al. (2010)* reported that, 12-day-old ducks intravenously inoculated with *Enterococcus* led to 100% mortality within 2 days. While, by air sac, 67% mortality within 4 days p.i. but surviving ducks showed clinical disease, pathological lesions and significantly lower body weight gain.

Oral and intra-nasal inoculated ducklings showed mild clinical signs of illness, decrease food intake, relative increase in water intake and diarrhea with decreased activity at 3rd day post inoculation. At 4th day post inoculation in orally infected ducks showed nervous signs such as head tremor and opisthotonus before death. Mortality rate in both inoculated groups were 20% (2 out of 10) along experimental period. Similar finding was reported by *Landman et al. (1999)* and *Leslie et al. (2011)*.

Conclusion

This study shows the importance of *Enterococcus* bacteria as a bacterial pathogen for young duckling, high resistance to antibiotics. Attention should be paid to improve biosecurity and need to find methods to counteract such diseases

References

- Aarestrup, F. M.; Agerso, Y.; Gerner-Smidt, P.; Madsen, M. and Jensen, L. B. (2000)**: Comparison of antimicrobial resistance phenotypes and resistance genes in *Enterococcus faecalis* and *Enterococcus faecium* from humans community, broilers, and pigs in Denmark. - *Diagnostic Microbiology and Infectious Disease*. 2000. 32: 127-137.
- Ciftci, A. (2004)**: The role of *Enterococci* virulence factors on experimental amyloid arthropathy in chickens. PhD thesis. Ankara University Health Sciences Institute, Ankara. 2004. (PhD thesis in Turkish, with an abstract in English).
- Facklam, R. R. and Sahn, D. F. (1995)**: *Enterococcus*. Pages 308–314 in *Manual of Clinical Microbiology*. 6th ed. P. R. Murray, E. J. Baron, M. A. Tenover, and R. H. Tenover, ed. Am. Soc. Microbiol., Washington, DC.
- Fisher, K. and Phillips, C. (2009)**: The ecology, epidemiology and virulence of *Enterococcus*. *Microbiol* 2009, 155:1749-1757.
- Gary A. W. (1997)**: *Diseases of Wild Waterfowl*. Springer; 2nd edition (March 31, 1997) Springer science business media, IIC
- Joan, S.A. and McNamee, P.T. (2002)**: Streptococci and Enterococci In: *Poultry Diseases* P. 163-169. 5th Edition Edited by: Jordan, F., Pattison M., Alexander, D. and Faragher, T.

- Jung, A.; Metzner, M.; Köhler-Repp, D. and Rautenschlein, S. (2013):** Experimental reproduction of an *Enterococcus cecorum* infection in Pekin ducks. *Avian Pathology*, 42(6), pp.552-556.
- Landman, WJM.;Feberwee, A.; Mekkes, DR.; Veldman, KT. and Mevius DJ. (1999):** A study on the vertical transmission of arthropathic and amyloidogenic *Enterococcus faecalis*. *Av Pathol.*1999, 28: 559-566.10.1080/03079459994344.
- Leclercq, R. and Courvalin, P. (1997):** Resistance to glycopeptides in *Enterococci*. *Clinical Infectious Diseases*, 24(4), 545-554.
- Leslie T. M.; Michael, P. M. and H. John Barnes, H. (2011):** Experimental Reproduction of Enterococcal Spondylitis in Male Broiler Breeder Chickens *Avian Diseases* June 2011, Vol. 55, No. 2, pp. 273-278 .
- Lukasova, J. and Sustackova, A. (2003):** Enterococci and antibiotic resistance. *Acta Veterinaria Brno*, 72, 315–323.
- Mette, F. E.; Olsen, R. H.; Bisgaard, M. and Christensen, H. (2011) :** ransmission and genetic diversity of *Enterococcus faecalis* among layer chickens during hatch. *Acta Veterinaria Scandinavica* , 53(1), 1.
- Metzner, M.; Köhler-Repp, D. and Köhler, B. (2010):** Neubakterielle Infektionserreger des Geflügels? *Enterococcus cecorum*, *Helcococcus*
- Moellering, R. C., Jr. (1992)** :Emergence of *Enterococcus* as a significant pathogen. *Clin. Infect. Dis.* 14:1173-1176.
- Mohamed, K.M. and Sohair, Y.M.(2008) :**Ascites syndrome in broilers with special reference to existence of bacterial etiology and alterations. *Assuite Vet Med . Journal* Vol 54 No 117:334-3356
- Olsen, R. H.; Schønheyder, H. C.; Christensen, H. and Bisgaard, M. (2012):** *Enterococcus faecalis* of human and poultry origin share virulence genes supporting the zoonotic potential of *E. faecalis*. *Zoonoses and public health*, 59(4), 256-263.
- Ruzauskas, M.; Virgil's, M.; Siugzdinine, R.; Suziedeliene, E.; Seputiene, V.; Dagelavicius, R.; Zienius, D.; Sengaut, J. and Pavidonis, A. (2009):** Antimicrobial resistance of *Enterococcus* spp. isolated from livestock in Lithuania. *Veterinarski Arhiv* 79(5):439-449.
- Saikia, P.K.; Devriese, L.A.; Kalita , C.C.; Haesebrouck, F. and Dutta, G.N. (1995)** :Composition of the Enterococcal intestinal flora of chicken in atropical area . *Letters in Applied Microbiology*
- Smyth, J.A. and McNamee, P.T. (2001):** Staphylococci, streptococci and Enterococci. In F. Jordan, M. Pattison, D. Alexander & T. Faragher (Eds.), *Poultry Diseases* , 5th edn (pp. 163 _ 169). London: W.B. Saunders.

Tsai C.C.; Liu T.H.; Chen M.H.; Tsai C.C. and Tsen H.Y. (2004): Toxicity evaluation for an *Enterococcus faecium* strain TM39 *in vitro* and *in vivo*. Food and Chemical Toxicology, **42**: 1601–1609.

Wood, A.M.; MacKenzie, G.; McGiliveray, N.C.; Brown, L.; Devriese, L.A. and Baele, M. (2002): Isolation of *Enterococcus cecorum* from bone lesions in broiler chickens. Vet. Rec., 2002; 150: 27.

الملخص العربي

أجريت هذه الدراسة خلال الفترة الممتدة من 2013 إلى 2015 في مناطق مختلفة من محافظة دمياط بهدف التعرف على بعض الأمراض البكتيرية التي تسبب النفوق في قطعان البط في المزارع والحيارات. وقد تم تجميع عدد 213 عينة بواقع (169 من مزارع البط و44 من التربية المنزلية)، واشتملت على الأعضاء الداخلية مثل (القلب والكبد والطحال والمخ) علاوة على نخاع العظام، وسوائل المفاصل من حالات تعاني من العرج والتهاب المفاصل وقد تم إجراء الفحص الظاهري والصفة التشريحية للبط المصاب والنافق حديثاً. وتم إجراء الفحص البكتيري لعزل المسببات المرضية.

تم إجراء اختبار الأمراض (العدوى الاصطناعية) لبعض المسببات البكتيرية المعزولة على النحو التالي:

أجريت العدوى الاصطناعية على عدد خمسون بطة بكيني عمر يوم وذلك لإجراء العدوى التجريبية لميكروب المكورات المعوية (الانتيروكوكسفيكالاس) وقد أسفرت الدراسة عن النتائج التالية:

1- عند إجراء الفحص الظاهري أظهرت النتائج أن طيور البط المريضة في المزارع أو التربية المنزلية تعاني من أعراض تمثلت في الالتهاب، وفقدان الشهية، وانخفاض استهلاك المياه العذبة وانتفاش الريش وفقدان الوزن والخمول والإسهال. كما أظهرت بعض الطيور أعراض عصبية وأخرى أظهرت العرج وعدم القدرة على الوقوف، بينما سجلت حالات نفوق فجائي لبعض الطيور.

2- وعند إجراء الصفة التشريحية أظهرت النتائج عن وجود احتقان عام في جميع الأجهزة الداخلية مع وجود علامات تسمم الدم، مع تضخم الكبد والطحال، والتهابات في الاكياس الهوائية وغشاء التامور مع وجود حالات استسقاء لبعض الطيور، وأخرى سجلت التهابات بالأمعاء وتشوهات بالعظام والتهاب المفاصل.

3- تم عزل المكورات المعوية (الانتيروكوكسفيكالاس) من الأعمار الصغيرة في مزارع البط والتربية المنزلية بنسبة (77.7%) و (36.3%) بالترتيب

4- تم عمل اختبار الحساسية للمضادات الحيوية لميكروب الانتيروكوكسفيكاليس ووجد أن ميكروب الانتيروكوكسفيكاليس لا يستجيب لمعظم المضادات الحيوية عدا الامبيسيلين