

Role of Endobronchial Ultrasound (EBUS) in Staging of Lung Cancer

EMAD H. HELAL, M.Sc.*; GAMAL A. EL-KHOLY, M.D.*; ADEL S. BEDIWY, M.D.*;
IBRAHIM S. IBRAHIM, M.D.*; MOHAMMED S. HANTERA, M.D.* and AYMAN M. EL-SAKKA, M.D.**

The Departments of Chest Diseases* and Pathology**, Faculty of Medicine, Tanta University, Tanta, Egypt

Abstract

Background: EBUS-TBNA represents a new technology in the field of bronchoscopy. The primary indications for EBUS-TBNA are staging NSCLC and the diagnostic assessment of mediastinal lymphadenopathy. EBUS-TBNA also has a diagnostic role in suspected benign disease, especially sarcoidosis and tuberculosis. It is a minimally invasive option as the first sampling staging procedure in suspected NSCLC with solitary hilar nodes, discrete N2 or N3 or bulky mediastinal diseases.

Aim of Study: The aim of the work is to estimate role of Endobronchial Ultrasound (EBUS) in staging of lung cancer.

Patients and Methods: It is a prospective experimental selected non cohort study that carried out on 20 patients with bronchogenic carcinoma admitted to Tanta University Hospitals from April 2016 till November 2016.

Results: In the current study, 20 patients (17 males & 3 females) were included to examine subcarinal, hilar and mediastinal lymph nodes (LN) in different stations. Among the 20 patients examined, 7 of them were under 60 years and 13 were above 60 years. 17 of them are smokers and 3 patients are non-smokers. According to type of lung cancer 4 patients were adenocarcinoma, 5 patients were large cell carcinoma, 6 patients were small cell carcinomas and 5 patients were squamous cell carcinomas. In the current study the lymph nodes staging of lung cancer were N1 (9 patients), N2 (8 patients) and N3 (3 patients).

Conclusions: Endobronchial ultrasound-guided transbronchial needle aspiration has a high diagnostic yield for the evaluation of mediastinal and hilar lymph node metastasis in lung cancer and has a high impact on patient management.

Key Words: Lung Cancer – Endobronchial Ultrasound – Elastography.

Introduction

LUNG cancer is one of the most common malignant tumors and the leading cause of cancer death, with a 5 year survival rate of only 16%. The appropriate treatment and outcomes of lung cancer depend on proper staging and diagnosis. Endobron-

chial ultrasound guided transbronchial needle aspiration (EBUS TBNA) was recently introduced as a novel tool for lung cancer staging. Under the guidance of ultrasound images, the safety, and accuracy of TBNA have been greatly improved. Consequently, EBUS TBNA has been recommended as an important tool for lung cancer staging by the National Comprehensive Cancer Network (NCCN) [1].

Ultrasound elastography technology has gradually been applied to the clinical setting. Elastography can be used to determine the elasticity of lesions and pathophysiological processes, such as malignancy, that make tissues stiffer or less deformable; thus, the technique exhibits potential application to the differential diagnosis of benign and malignant lesions [2]. EBUS elastography can be used for the noninvasive discrimination of benign and malignant thoracic lymph nodes as a guide for EBUS TBNA [3].

Patients and Methods

This prospective experimental selected non cohort study that was carried out on 20 patients with bronchogenic carcinoma admitted to our Hospitals from April 2016 till November 2016.

Inclusion criteria:

- a- Patients with bronchogenic carcinoma proved histopathological by taking biopsies from tumor either by bronchoscope, or CT guided biopsy.
- b- Presence of enlarged mediastinal and/or hilar lymph node in CT chest more than 1 cm.

Exclusion criteria:

- Metastatic tumor of lung.
- Other non neoplastic causes of mediastinal lymphadenopathy e.g sarcoidosis, tuberculosis,
- Patients unfit for bronchoscope.

Correspondence to: Dr. Emad H. Helal, The Department of Chest Diseases, Faculty of Medicine, Tanta University, Tanta, Egypt

The following was done for all patients:

Written informed consent was obtained from all patients included in this study, and the study protocol was approved by the Ethics Committee of our Institute.

1- History taking and physical examination.

2- *Investigations:*

- Arterial Blood Gases.
- Complete Blood Count.
- C T chest with contrast.
- Coagulation profile (INR, PTT).
- Urea and Creatinine level.

Device and technique:

EBUS-guided TBNA examinations were performed at our Hospital using Pantex EBUS probe and Hitachi ultrasound in the supine position under local anesthesia with lidocaine and conscious sedation through oral route for all patients.

Lymph nodes will be identified according to the Mountain's regional lymph node classification system. The lymph node stations of 2,4,7,10 and 11 were evaluated systematically. During the process for every detected lymph node; short and long axis diameters, and station of the lymph node was recorded for each patient. N3 nodes were sampled first and then N2 nodes to avoid contamination in lung cancer patients. The elastography mode was used for all examined lymph nodes. Lymph node scanning by the elastography mode gives more information about the elasticity which was reflected into a color signal that was overlaid on the B-mode image. The colors associated with hard, intermediate, and soft tissues were blue, green, and yellow/red, respectively.

Characters of lymph nodes to be sampled:

- More than 1 cm in diameter (lymph nodes less than 1 cm not accessible by EBUS).
- Distinct margin.
- Heterogeneous echogenicity and abundant blood flow.

The needle used in puncturing the lymph nodes was (ECHOHD 22-EBUS-P) which is single used. N3 nodes will be sampled first and then N2 nodes to avoid contamination in lung cancer patients. The materials obtained by EBUS-guided TBNA were smeared on slides. These slides were air-dried, stained with Diff-Quick stain and examined by the pathologist to do ROSE (Rapid On Site Examination)

and be sure that our lymph nodes biopsies are sufficient and determine if positive or negative. Aspiration specimen was considered "insufficient" if there were not an adequate number of lymphocytes on the smear. Then the pathologist collects all samples and revises it again to reach the final decision. After the procedure all patients were observed for 2 hours before discharge.

Statistical analysis:

Statistical Analysis Data was analyzed using SPSS (Statistical Package for Social Sciences) v16.0 (SPSS Inc., Chicago, USA). Qualitative data was presented as number and percent. Comparison between groups was done by Chi-Square test. Quantitative data was presented as mean \pm SD. Student *t*-test was used to compare between two groups. $p < 0.05$ was considered to be statistically significant.

Results

A- Demographic data:

The present study was carried out on 20 patients. 17 (85%) cases were male, 13 patients above 60 years (65%) and the mean age was 63.60.

B- Relations between smoking index and type of lung cancer:

There is a statistically significant correlation between smoking index and lung cancer, especially with squamous type (p -value 0.026).

C- Relations between lymph nodes staging by CT chest and EBUS:

There is no statistically significant change between lymph nodes staging by CT chest and EBUS-TBNA staging (p -value 0.072). According to CT chest staging 9 cases were N1 but during EBUS TBNA evaluation only 3 cases (33.3%) were N1 and 6 cases (66.7%) were N2, 8 cases were N2 by CT chest but by EBUS-TBNA one case was N1 (12.5%), 3 cases (37.5%) were N2 and 4 cases (50%) were N3 and by CT chest 3 cases were N3 but by EBUS-TBNA one case was N2 (33.3%) and 2 cases (66.7%) were N3.

D- According to number of lymph nodes examined by EBUS-TBNA and elastography strain ratio:

The total number of lymph nodes examined was 95.27 were benign, and 68 were malignant. The mean elastography strain ratio of the benign lymph nodes was 2.28 and the mean elastography strain ratio of the malignant lymph nodes was 20.30.

Table (1): Distribution of the studied cases according to demographic data (n=20).

	No.	%
Sex:		
Male	17	85.0
Female	3	15.0
Age (years):		
≤60	7	35.0
>60	13	65.0
Min.–Max.	48.0–75.0	
Mean ± SD.	63.60±6.71	
Median	64.0	

Table (2): Relation between nodal stage in CT chest and nodal staging by EBUS (n=20).

Nodal staging by EBUS	Nodal stage in CT ches						χ^2	MC _p
	N 1 (n=9)		N 2 (n=8)		N 3 (n=3)			
	No.	%	No.	%	No.	%		
N 1	3	33.3	1	12.5	0	0.0		
N 2	6	66.7	3	37.5	1	33.3	7.522	0.072
N 3	0	0.0	4	50.0	2	66.7		

Table (3): Descriptive analysis of the studied cases according to Number of LN and elastography strain ratio of malignant lymph nodes (n=20).

Elastotography, strain ratio of lymph nodes.		
Min.–Max.	12.90–27.20	0.50–5.10
Mean ± SD.	20.30±4.12	2.28±1.56
Median N 3	19.85	2.0

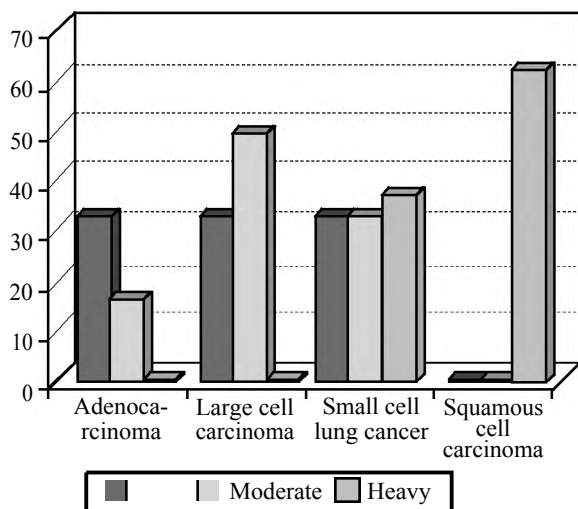


Fig. (1): Relation between smoking index and type of lung cancer (n=17).

Discussion

EBUS-TBNA represents a new technology in the field of bronchoscopy the primary indications for EBUS-TBNA are staging NSCLC and the diagnostic assessment of mediastinal lymphadenopathy. EBUS-TBNA also has a diagnostic role in suspected benign disease, especially sarcoidosis and tuberculosis. It is a minimally invasive option as the first sampling staging procedure in suspected NSCLC with solitary hilar nodes, discrete N2 or N3 or bulky mediastinal diseases [5].

In the study by Bediwy, et al., [6] ROSE has add-on advantages to EBUS-guided TBNA in many aspects; increasing diagnostic accuracy of TBNA by excluding suspicious or nondiagnostic specimens, increasing safety by decreasing the number of punctures, and providing sufficient samples for subsequent immunocytochemical and molecular analysis needed for meticulous pathological diagnosis and consequential treatment options.

Oki, et al., [7] showed that ROSE feeds back valuable information to the examiner on the adequacy of cytologic samples at the time of needle aspiration procedures, which indicates whether the procedure should be repeated or not. In conventional TBNA, many investigators have reported the usefulness of ROSE, but the role is controversial. For example, several authors have reported that ROSE increases the diagnostic yield. The examiner can modify the technique by changing the puncture site, puncture depth or angle based on the ROSE results, which might increase the diagnostic yield.

Study by Boyan [8] showed that rapid on-site cytologic evaluation (ROSE) during TBNA has been suggested as one such way. It has been reported to be effective, as it increases the diagnostic yield, decreases the number of needle passes, obviates the need for additional diagnostic procedures, reduces the complication rate of bronchoscopy and reduces the cost. Although its role is controversial, many investigators recommend the use of ROSE during TBNA.

Bediwy, et al., [9] showed that Strain ratio was found to be more accurate when compared to other findings of B-mode in comparing malignant and benign LNs with a cutoff value of 7.5 giving a sensitivity of 95.5% and a specificity of 91.67%. About 63% of malignant LNs were diagnosed from the first pass with the help of elastography.

In the current study agreement with this study as the results show that elastography of lymph

nodes range from 12.9 to 27.2, mean \pm SD. 20.30 ± 4.12 and median 19.85 which is above 7.5.

Hai Yan Heet al., [10] using endobronchial ultrasound for diagnosing of hilar and mediastinal lymph nodes showed that the best cut off point of the strain ratio for differentiating malignant from benign lymph nodes was 32.07.

Conclusion:

EBUS-TBNA was an accurate, safe and cost-effective tool in lung cancer staging. The selection of patients who had positive results of suspected lymph node metastasis in CT or PET may improve the sensitivity of EBUS-TBNA.

EBUS elastography can be effectively used to predict mediastinal and hilar lymph node metastases in lung cancer.

Recommendations:

Further studies on large number of patients to determine the diagnostic yield of the Endobronchial ultrasound-guided transbronchial needle aspiration (EBUS-TBNA) for the evaluation of mediastinal and hilar lymph node metastasis in lung cancer and its impact on patient management.

References

- 1- HOREWEG N. and de KONING H.: The importance of screening for lung cancer. *Expert. Rev. Respir. Med.*, 8: 597-614, 2014.
- 2- VAIDYA P.J., KATE A.H., YASUFUKU K. and CHHAJED P.N.: Endobronchial Chinese Medical Journal, October 20, Volume 128, Issue 20 ultrasound guided transbronchial needle aspiration in lung cancer diagnosis and staging. *Expert. Rev. Respir. Med.*, 9: 45-53, 2015.
- 3- ETTINGER D.S., WOOD D.E., AKERLEY W., BAZHE-NOVA L.A., BORGHAEI H., CAMIDGE D.R., et al.: Non small cell lung cancer, version 1, *J. Natl. Compr. Canc. Netw.*, 12: 1738-61, 2014.
- 4- NAKAJIMA T., YASUFUKU K., SAEGUSA F., FUJIWARA T., SAKAIRI Y., et al.: Rapid on-site cytological evaluation during endobronchial ultrasound -guided transbronchial needle aspiration for nodal staging in patients with lung cancer. *Ann. Thoracic. Surgeon.*, 95 (5): 1695-9, 2013.
- 5- VILMANN P., KRASNIK M., LARSEN S.S., JACOBSEN G.K., and CLEMENTSEN P.: Transesophageal endoscopic ultrasound-guided fine-needle aspiration (EUS-FNA) and endobronchial ultrasound-guided transbronchial needle aspiration (EBUS-TBNA) biopsy: A combined approach in the evaluation of mediastinal lesions. *Endoscopy*, 37 (09): 833-839, 2005.
- 6- BEDIWY A.S., ZAMZAM K., HANTIRA M., EL-SHARAWY D., ELSAQA A. and ZAMZAM Y.: The value of rapid on-site evaluation during endobronchial ultrasound-guided transbronchial needle aspiration in the diagnosis of mediastinal lesions. *Egyptian Journal of Bronchology*, 11 (4): 336, 2017.
- 7- OKI M., SAKA H., KITAGAWA C., KOGURE Y., MURATA N., ADACHI T. and ANDO M.: Rapid on-site cytologic evaluation during endobronchial ultrasound-guided transbronchial needle aspiration for diagnosing lung cancer: A randomized study. *Respiration*, 85 (6): 486-492, 2013.
- 8- BOYAN W.: On-site cytopathologic analysis of bronchoscopic needle aspiration: Con: On-site analysis is not indicated. *Journal of Bronchology & Interventional Pulmonology*, 10 (2): 152-154, 2003.
- 9- BEDIWY A.S., HANTIRA M.S., EL-SHARAWY D. and EL-SAQA A.: The role of endobronchial ultrasound elastography in the diagnosis of mediastinal lymph nodes. *Egyptian Journal of Bronchology*, 11 (3): 238, 2017.
- 10- HE H.Y., HUANG M., ZHU J., MA H. and LYU X.D.: Endobronchial ultrasound elastography for diagnosing mediastinal and hilar lymph nodes. *Chinese Medical Journal*, 128 (20): 2720, 2015.

دور الموجات فوق الصوتية من داخل الشعب الهوائية في ترتيب درجة سرطان الرئة

يعتبر سرطان الرئة أحد أشهر الأورام السرطانية المسببة للوفاة ومعدلات البقاء لمدة ٥ سنوات للمصابين به لا تتجاوز ١٦٪. وتحديد العلاج المناسب والاستجابة النهائية له تعتمد على التشخيص المناسب ودرجة سرطان الرئة. وتعتبر الموجات فوق الصوتية من خلال المنظار الشعبى بمساعدة أبرة أخذ العينات واحدة من أحدث أدوات ترتيب درجة سرطان الرئة. وقد أدى استخدام الموجات فوق الصوتية إلى تحسين معدلات الأمان ودقة نتائج أبرة أخذ العينات وبالتالي أصبحت الموجات فوق الصوتية من خلال المنظار الشعبى بمساعدة أبرة أخذ العينات أحد أهم الأدوات الموصى بها لترتيب درجة سرطان الرئة. وتعتبر تقنية الأيلاستوجرافى باستخدام الموجات فوق الصوتية تدريجياً أصبحت فى التطبيقات العملية.

تمت هذه الدراسة على ٢٠ مريض من المترددين على مستشفيات جامعة طنطا ممن يعانون من سرطان بالرئة فى الفترة ما بين أبريل ٢٠١٦ إلى نوفمبر ٢٠١٦. تم إجراء الدراسة باستخدام جهاز (EBUS pentex probe) وجهاز الموجات فوق الصوتية المستخدم هو (Hitachi) والأبرة المستخدمة لأخذ العينات من الغدد الليمفاوية هى (ECHO-HD 22-EBUS-P) وتستخدم هذه الأبرة مرة واحدة فقط ثم تستبدل بأخرى جديدة.

وقد أوضحت النتائج الدور الهام للموجات فوق الصوتية من داخل الشعب الهوائية فى الترتيب الدقيق لدرجة سرطان الرئة.